

**«ҚАЗАҚСТАН НЕЙРОХИРУРГИЯСЫ
ЖӘНЕ НЕВРОЛОГИЯСЫ» ЖУРНАЛЫ**

**ЖУРНАЛ «НЕЙРОХИРУРГИЯ
И НЕВРОЛОГИЯ КАЗАХСТАНА»**

**JOURNAL «NEUROSURGERY AND
NEUROLOGY OF KAZAKHSTAN»**

№3 (36), 2014
Научно-практический журнал
выходит 4 раза в год

Журнал издается с 2004 года

Адрес редакции:

г. Астана, пр-т Туран 34/1,
АО НЦН, 010000
Тел/факс: (7172) 51-15-94
E-mail: nsnkkz@gmail.com
www.neurojournal.kz

Свидетельство о постановке на
учет в Министерстве культуры и
информации РК
№ 10442-Ж от 30.10.09 г.

Учредитель журнала:

АО «Национальный центр
нейрохирургии».
Журнал находится под
управлением «Казахской
Ассоциации Нейрохирургов».

Зак. №1053/1. Тираж 300 экз.

Сверстано и отпечатано
в типографии «Жаркын Ко»,
г. Астана, пр. Абая, 57/1,
тел.: +7 (7172) 21 50 86
e-mail: info@zharkyn.kz
www.zharkyn.kz



Редакционная коллегия:

Главный редактор	С.К. Акшулаков
Зам. главного редактора	А.С. Жусупова
Ответственный секретарь	Е.Т. Махамбетов
Технический редактор	З.К. Шаймерденова
Члены редколлегии	Ч.С. Шашкин Н.Т. Алдиярова Б.Б. Байжигитов С.Д. Карибай Т.Т. Керимбаев А.З. Нурпеисов Т.Т. Пазылбеков М.Р. Рабандияров Н.А. Рыскельдиев А.М. Садыков

Редакционный совет:

М.Г. Абдрахманова, Ж.А. Арзыкулов,
Т.С. Нургожин, С.В. Савинов,
Н.И. Турсинов, А.В. Чемерис, А.Т. Шарман,
Г.Н. Авакян (Россия),
Г.М. Кариев (Узбекистан), А.Д. Кравчук (Россия),
В.А. Лазарев (Россия),
Л.Б. Лихтерман (Россия), А.А. Потапов (Россия),
А.К. Сариев (Россия),
В.А. Хачатрян (Россия), Г.Г. Шагинян (Россия),
М. Apuzzo (США),
S.Maimon (Израиль),
K.H. Mauritz (Германия), Н.М. Mehdorn (Германия),
N. Tribolet (Швейцария), Н.С. Игисинов,
V. Zelman (США), Y. Kato (Япония).



СОДЕРЖАНИЕ

ОРИГИНАЛЬНЫЕ СТАТЬИ3*Акшулаков С.К., Кисамеденов Н.Г.***САКРАЛЬНАЯ НЕЙРОСТИМУЛЯЦИЯ В ЛЕЧЕНИИ НЕЙРОГЕННОЙ ДИСФУНКЦИИ
МОЧЕВОГО ПУЗЫРЯ 3***Peev N.A., Kalevski S.K., Haritonov D.G.***ACUTE EPIDURAL HEMATOMA FORMATION AFTER VENTRICULO-PERITONEAL
SHUNT PLACEMENT 7***Мамбетова Г.Ш., Нургалиев К.Б., Сағатбекова Ж.Е., Имангожаева А.Т., Кисаев Е.В.***МЕТОДИКА ПОЭТАПНОГО ВОССТАНОВЛЕНИЯ ДВИГАТЕЛЬНЫХ НАВЫКОВ 11****СЛУЧАЙ ИЗ ПРАКТИКИ16***Бондарева И.В., Савинов С.В., Акчурина Я.Е., Михайлова Н.В., Утебеков Ж.Е.,
Ситников И.Ю., Синицына Т.Н., Абедимова Р.А.***АЛГОРИТМ НЕЙРОФИЗИОЛОГИЧЕСКОЙ И НЕЙРОВИЗУАЛЬНОЙ ДИАГНОСТИКИ
ПАЦИЕНТОВ С ФОКАЛЬНОЙ ФОРМОЙ ЭПИЛЕПСИИ 16****МАТЕРИАЛЫ X АЗИАТСКОГО КОНГРЕССА НЕЙРОХИРУРГОВ22**



ОРИГИНАЛЬНЫЕ СТАТЬИ

УКД:616.83:616.62-008.22

Акшулаков С.К. (д.м.н., Профессор), Кисамеденов Н.Г. (к.м.н.)
АО «Национальный центр нейрохирургии» г. Астана, Казахстан

САКРАЛЬНАЯ НЕЙРОСТИМУЛЯЦИЯ В ЛЕЧЕНИИ НЕЙРОГЕННОЙ ДИСФУНКЦИИ МОЧЕВОГО ПУЗЫРЯ

Цель исследования. Улучшение результатов лечения нейрогенной дисфункции мочевого пузыря.

Методы. В период с декабря 2013 г. по июль 2014 г. в условиях приемно-диагностического отделения АО «Национальный центр нейрохирургии» г. Астана, были обследованы 23 пациента, обратившихся с клиникой нейрогенной дисфункции мочевого пузыря различной вариации. В зависимости от применяемой методики лечения нейрогенной дисфункции мочевого пузыря, пациенты разделены на две группы – основную и контрольную. Основную группу составили пациенты, которым, проведено оперативное лечение в плановом порядке в объеме: Имплантация постоянного сакрального нейростимулятора с последующей нейромодуляцией. Контрольную группу составили пациенты, получавшие только традиционную консервативную терапию.

Критериями оценки эффективности проводимого лечения являлись улучшение параметров мочеиспускания зарегистрированные урофлоуметрией и дневниками мочеиспускания, по результатам опросников качества жизни SF-36.

Результаты. Результаты лечения больных основной группы (n=10) показало высокую эффективность. Так, при гипотонии и атонии мочевого пузыря положительные результаты лечения через 6 месяцев после проведения имплантации отмечены у 79% больных. Самостоятельное мочеиспускание возвратилось у 59% больных с нарушением опорожнения мочевого пузыря. Положительные результаты у контрольной группы (n=13) получавшие консервативную терапии наблюдалось всего у 2% больных.

Заключение. Сакральная нейростимуляция является высокоэффективным методом лечения больных с тяжёлыми формами нарушения акта мочеиспускания. Нейромодуляция сакральных нервов представляет собой альтернативный и нередко единственно возможный метод лечения больных с нейрогенными дисфункциями мочевого пузыря.

Ключевые слова: нейрогенная дисфункция мочевого пузыря, имплантация постоянного сакрального нейростимулятора, нейромодуляция

Введение

Заболевания нервной системы представляют существенную социальную и экономическую проблему во всем мире [6,7]. Это обусловлено возрастающей распространенностью патологии нервной системы и большими экономическими затратами, связанными с высокой инвалидизацией вследствие этой патологии. Согласно данным Всемирной организации здравоохранения (ВОЗ), в мире 25% функциональных расстройств обусловлено заболеваниями нервной системы (в 2,5 раза больше по сравнению с данными 1996 года). В Европе на заболевания нервной системы приходится 35 % от общего бремени болезней [4,5]. Травмы нервной системы, инсульт, деменция, эпилепсия и болезнь Паркинсона являются наиболее важными заболеваниями, определяющими смертность и заболеваемость населения земного шара.

В Республике Казахстан, как и в других странах мира, за последние годы отмечается рост неврологической заболеваемости. За 10 лет распространенность неврологических

заболеваний увеличилась почти в 2 раза [5,7]. Это обусловлено интенсивным влиянием факторов риска развития неврологических заболеваний на население страны.

В современном этапе развития нейрохирургической службы Республики Казахстан, одними из актуальных проблем остаются различные осложнения, возникшие вследствие неврологических заболеваний, проявляющиеся нарушениями акта мочеиспускания, дефекации и эректильной дисфункции, или нейрогенная дисфункция органов малого таза.

Отсутствие эффективных методов лечения и реабилитации данной категории пациентов, приводят к полной утери трудоспособности и снижению социальной адаптации. Возрастающая распространенность осложнений неврологических заболеваний обуславливает и высокую инвалидизацию вследствие нее.

Одним из часто встречающихся вариантов нейрогенной дисфункции органов малого таза является нейрогенная дисфункция мочевого пузыря. Лечение пациентов с данной патологией, по-прежнему представляет собой сложную и

во многом еще не решенную задачу. Одним из наиболее перспективных направлений в лечении нейрогенных нарушений мочеиспускания является моделирование утраченного механизма мочеиспускания при помощи прямой или опосредованной электростимуляции нервных волокон — метод постоянной сакральной нейромодуляции.

Впервые в Республике Казахстан оперативное лечение нейрогенной дисфункции мочевого пузыря методом сакральной нейростимуляции проводится в условиях АО «Национальный центр нейрохирургии» г. Астана с конца 2013 года.

Цель данной работы

Улучшение результатов лечения нейрогенной дисфункции мочевого пузыря.

Материалы и методы

В период с декабря 2013 г. по июль 2014 г. в условиях приемно-диагностического отделения АО «Национальный центр нейрохирургии» г. Астана, были обследованы 23 пациента, обратившихся с клиникой нейрогенной дисфункции мочевого пузыря различной вариации. У 16 из них, причинами возникновения нейрогенной дисфункции мочевого пузыря, являлись вследствие патологии спинного мозга. Диагноз устанавливался на основании клинко-лабораторных, ультразвуковых, рентгенологических и функциональных методов исследования. Все исследования были выполнены в плановом порядке в условиях приемно-диагностического отделения центра. Всем пациентам в условиях приемно-диагностического отделения проводилась комплексная консервативная терапия, направленная на восстановление или улучшение качества мочеиспускания.

В зависимости от применяемой методики лечения нейрогенной дисфункции мочевого пузыря, пациенты разделены на две группы – основную и контрольную. Основную группу составили пациенты, которым проведено оперативное лечение в плановом порядке в объеме: Имплантация постоянного сакрального нейростимулятора с последующей нейромодуляцией. Контрольную группу составили пациенты, получавшие только традиционную консервативную терапию.

Критериями оценки эффективности проводимого лечения являлись улучшение параметров мочеиспускания зарегистрированные урофлоуметрией и дневниками мочеиспускания, по результатам опросников качества жизни SF-36.

В исследование включено 23 пациента в возрасте от 18 до 60 лет. Основную группу составили 10 пациентов, из них женщин 4, мужчин 6. Контрольную группу – 13 пациентов, в том числе 8 женщин и 5 мужчин.

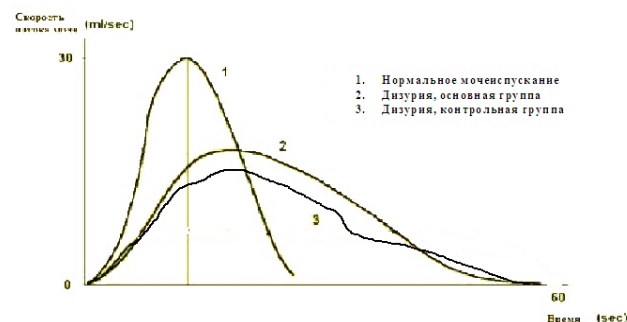


Рисунок 1 - Контрольная урофлоуметрия обеих групп до проведения лечения

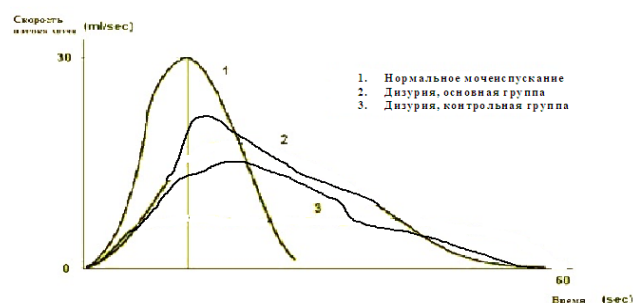


Рисунок 2 - Урофлоуметрия через 6 месяцев после проведенного лечения

Результаты лечения больных основной группы (n=10) показали высокую эффективность.

Так, при гипотонии и атонии мочевого пузыря положительные результаты лечения через 6 месяцев после проведения имплантации отмечены у 79% больных. Самостоятельное мочеиспускание возвратилось у 59% больных с нарушением опорожнения мочевого пузыря. Положительные результаты у контрольной группы (n=13) получавшей консервативную терапию наблюдалось всего у 2% больных.

Выводы

Таким образом, сакральная нейростимуляция является высокоэффективным методом лечения больных с тяжёлыми формами нарушения акта мочеиспускания. Важно понимать, что нейромодуляция сакральных нервов представляет собой альтернативный и нередко единственно возможный метод лечения указанных категорий больных. По нашему мнению сакральную нейростимуляцию необходимо проводить в тех случаях, когда медикаментозное и другие виды консервативного лечения оказываются неэффективными.



Список литературы:

1. Абдуллаев К.И. Возрастная динамика незаторможенного мочевого пузыря и его лечение. Автореф. Докт. Дисс. М, 1987, 43 с.
2. Аль-Шукри С. Х., Кузьмин И. В., Р.Э.Амдий. Комплексное лечение больных с нестабильностью детрузора. Журнал «Урология», №5, 2001.
3. Аль-Шукри С. Х., Кузьмин И. В. Метод биологической обратной связи в лечении больных с недержанием мочи // Урол. – 1999. – № 5. – С. 44 – 47.
4. Аль-Шукри С. Х., Кузьмин И. В. Гиперактивность детрузора и недержание мочи: Пособие для врачей. – Санкт-Петербург, 2001. – 40 с.
5. Аппенцеллер О., Аткинсон Р. Болезни вегетативной нервной системы: оценка и лечение // Заболевания периферической нервной системы / Под ред. А.К.Эсбери, Р.У.Джиллиата: Пер. с англ. М., 1987. – С.81-125.
6. Банников В.М., Рункова М.В. Нейрогенные дисфункции мочевого пузыря. М., 2004.
7. Богданов Э.И. Дисфункции мочевого пузыря при органических заболеваниях нервной системы (патофизиология, клиника, лечение) // Неврологический вестник. 1995. – Т. XXVII, вып. 3-4. – С.28-34.
8. Борисов В.В. Фармакоуродинамические исследования в диагностике заболелвших нижних мочевых путей. Всесоюзный симпозиум по уродинамике. – М., 1990.
9. Abrams P, Cardozo L, Fall M, et al. The standardization of terminology of lower urinary tract function: report from the Standardization Subcommittee of the International Continence Society. Neurourol Urodyn 2002;21:167-178.
10. Allen T.D., Bright T.C. Urodynamic patterns in children with dysfunctional voiding problems // J.Urol.-1978.-Vol.I 19,N 2.-P.247 249.
11. Allescher HD. Laxatives and prokinetics good or bad? In: Constipation and anorectal insufficiency. Falk Symposium 95. Kluwer Academic Publishers; 1997; p.121-129.
12. Andersson KE, Hedlund P. Pharmacologic perspective on the physiology of the lower urinary tract. Urology 2002;605:Suppl 1:13-21.

ТҰЖЫРЫМ

С.Қ. Ақшолоақов (м.ғ.д., Профессор), Н.Г. Кисамеденов (м.ғ.к.)
«Ұлттық нейрохирургия орталығы» АҚ, Астана қ., Қазақстан

ҚҰЫҚТЫҢ НЕЙРОГЕНДІ ДИСФУНКЦИЯСЫН ЕМДЕУДЕГІ СОКРАЛЬДЫ НЕЙРОСТИМУЛЯЦИЯ

Зерттеу мақсаты. Несептік қуықтың нейрогендік дисфункцияларының емдеу нәтижелерін жақсарту.

Әдістері. 2013 жылдың желтоқсан айы мен 2014 жылдың маусым айлары аралығында «Ұлттық нейрохирургия орталығы» АҚ қабылдау-диагностикалық бөлімшесі жағдайында клиникаға түрлі вариациядағы несептік қуықтың нейрогендік дисфункциялары бар 23 пациент қаралды. Қуықтың нейрогендік дисфункцияларын емдеудегі қолданылатын әдістердің түріне байланысты пациенттер екі топқа-негізгі және бақылаушы топ болып бөлінді. Негізгі топты жоспарлы түрде операция жасалған пациенттер құрды, оларға: келесі нейромодуляциясы бар тұрақты сакралды нейростимулятор имплантациясы. Бақылаушы топқа тек қана дәстүрлі консервативті терапия алатын пациенттер тобы құрды.

Өткізіліп отырған емдеудің тиімді бағалау критерийлері SF-36 өмір сапасы сауалнамасының қортындысы бойынша урофлометрия және несеп шығару күнделіктерінде тіркелген несепшығару параметрлерін жақсарту болып табылады.

Нәтижелер. Негізгі топтағы (n=10) науқастарды емдеу қорытындылары үлкен тиімділікті көрсетті. Бұл, несептік қуықтың гипотония және атониясы имплантация өткізуден кейін 6 айдан соң емдеудің нәтижелері жақсы екендігі 79% науқастарда байқалды. Өзіндік несеп шығару қуықты босату бұзылыстары бар 59 % науқаста байқалды. Консервативті терапия алған бақылаушы топта (n=13) емдеудің жақсы нәтижелері тек 2% науқастарда ғана байқалды.

Қорытынды. Сакралды нейростимуляция несеп шығару актісінің бұзылуындағы науқастарда ауыр формаларын емдеудегі жоғары тиімді әдіс болып табылады. Сакралды нервтердің нейромодуляциясы өзіндік альтернативті және несептік қуықтың нейрогендік дисфункциялары бар науқастарда сирек кездесетін жалғыз мүмкіндік емес.

Негізгі сөздер: несептік қуықтың нейрогендік дисфункциясы, тұрақты сакралды нейростимулятор имплантациясы, нейромодуляция.



SUMMARY

*Akshulakov S.K. (D.Med.Sci., Professor), Kisamedenov N.G. (Can.Med.Sci.)
JSC «National centre for Neurosurgery» Astana city, Kazakhstan*

SACRAL NEUROSTIMULATION IN TREATMENT OF NEUROGENIC DYSFUNCTION OF BLADDER

The purpose of the study. Improving results of treatment of neurogenic bladder dysfunction.

Methods. In the period from December 2013 to July 2014 in a receiving-diagnostic department of JSC "National Center for Neurosurgery", Astana, 23 patients who applied with clinic neurogenic bladder dysfunction of different variations were examined. Depending on the applied methods of treatment of neurogenic bladder dysfunction, patients were divided into two groups - the main and control. The main group consisted of patients who, after surgery routinely in content: Implantation of permanent sacral neurostimulator, followed by neuromodulation. The control group consisted of patients who received only traditional conservative therapy.

The criteria for evaluating treatment effectiveness is enhancement of bladder parameters registered with uroflowmetry and urination diary, by the results of the quality of life questionnaire SF-36.

Results. Main group patients' (n = 10) results of treatment showed high efficiency. There was noted that 79% of patients with hypotension and atony of bladder reached positive results of treatment in 6 months. Unaided urination recurred to the 59% of patients with impaired bladder emptying. Positive results in the control group (n = 13) treated with conservative therapy was observed in 2% of all patients.

Conclusion. Sacral nerve stimulation is a highly effective treatment for patients with severe forms of infraction of the urination act. Neuromodulation of sacral nerves is an alternative, and frequently the only possible method for the treatment of patients with neurogenic bladder dysfunction.

Keywords. neurogenic bladder dysfunction, implantation of permanent sacral neurostimulator, neuromodulation.



UDC: 616.831.959-003.315

Peev N.A. (M.D.), Kalevski S.K. (M.D., Ph.D.), Haritonov D.G (M.D.)

Department Of Neurosurgery

Medical University Of Varna, Bulgaria

St. Anna Multiprofile Hospital, Varna, Bulgaria

ACUTE EPIDURAL HEMATOMA FORMATION AFTER VENTRICULO-PERITONEAL SHUNT PLACEMENT

Background: Acute epidural hematoma is a common finding of the traumatic brain injury patients. However there are only a few cases of acute epidural hematoma formation after insertion of ventriculo-peritoneal shunt.

Case report: We present a rare case of acute epidural hematoma formation after insertion of ventriculo-peritoneal shunt.

A 28-year old man presenting with one year history of headache, dizziness, difficulties finding words, lower limbs weakness and urinary incontinence was admitted for CSF diversion. MRI investigation revealed excessive dilatation of the all four ventricles. Intracranial pressure measured in recumbent position pre-operatively revealed an ICP of 6mm Hg. The patient was operated and Strata programmable valve was used for the CSF diversion. CT scan on the sixth post-operative day showed an acute epidural hematoma that was evacuated urgently. The postoperative period went uneventfully. Patient was discharged with significant improvement.

Conclusion: Although the formation of subdural hematomas is not rare conditions resulting from the overdrainage of the VPS in the shunted patients with chronic longstanding ventriculomegaly, the acute epidural hematoma formation after VPS insertion is a rare entity. Our case however shows that it could be also expected as a complication among the over drained chronic hydrocephalus patients

Introduction

Subdural hematoma formation is a well known complication of the overdrained chronic longstanding hydrocephalus patients [1, 2]. The reason for that is the long standing ventriculomegaly that dramatically reduces the brain compliance [3]. However there are only a few cases reported of acute epidural hematoma formation after insertion of ventriculo-peritoneal shunt [4, 5].

Purpose: We present a rare case of acute epidural hematoma formation after insertion of ventriculo-peritoneal shunt, in order to prove the possibility of acute epidural hematoma formation due to overdrainage in the long standing chronic hydrocephalus patients.

Methods: The case is presented together with its clinical course, the diagnostic techniques, the surgical findings, and the treatment outcome.

Case report

A 28-year old man presented with one year history of headache, dizziness, difficulties finding words, lower limbs weakness and urinary incontinence. The conversation with his relatives revealed learning difficulties and mental retardation during the childhood. MRI investigation revealed excessive dilatation of the all four ventricles. (Figure 1) Intracranial pressure measured in recumbent position pre-operatively revealed an ICP of 6mm Hg. After clinical discussion it was decided the hydrocephalus to be treated with Strata Adjustable Valve. The valve was intra-operatively set at 1.0. CT scan on the sixth post-operative day showed an acute epidural hematoma (Figure 2) that was

evacuated urgently (Figure 3). The valve was set intra-operatively to 2.0. The postoperative period went uneventfully. Patient was discharged with significant improvement – no headaches and dizziness, improved word finding, improved gait and urinary control, which remained unchanged on the sixth month follow up visit.

Results

After the surgical treatment the patient's complaints were alleviated and no complaints were registered, during the next 6 months follow-up.

Discussion

A multitude of underlying etiological reasons can cause hydrocephalus (HC). Its classification and terminology is still controversial and a widely accepted consensus is still due to be achieved [2, 6, 7, 8].

The pathophysiology of hydrocephalus (HC) first started in the beginning of the previous century with the work of Dandy and Blackfan [9]. In 1913 they had first introduced the term "Internal Hydrocephalus" and also described the main features of the so called Communicating and Non-communicating Hydrocephalus. By 1919 Dandy [10] had developed an experimental animal model in order to study and develop treatment for HC. Since that first classification, there are numerous attempts at HC classifications, reflecting different aspects of the problem, but 100 years after the Dandy's and Blackfan's work, despite the many major achievements led to many classifications covering

different aspects of HC, the ideal comprehensive classification covering all the aspects remains elusive. Hence the term hydrocephalus generally represents a complex pathophysiological entity with one main characteristic - disturbed cerebrospinal fluid (CSF) turnover, with complex, not well understood and on many occasions intuitive treatment.

CSF circulation and turnover is a complex process and is described by many variables and is dependent on a multitude of factors which complicates attempts at a unifying classification system. Based on the systematic review of almost 10000 publications from the period of 1950 – 2008 in the HC area, and also based on his own experimental and clinical work, in 2010 Oi proposed "Multi-categorical Hydrocephalus classification, attempting to cover all the aspects of the HC [7]. Each HC case according to this classification is confronted to ten categories with multiple subcategories, with a final count of 54 HC subtypes listed. Hence if one would wish to cover all the possible combinations in this classification, there would be theoretically 72,576,000 patterns of hydrocephalus classified.

As classification dealing with specific forms of HC Oi points the Normal pressure hydrocephalus (NPH) [11], Longstanding overt ventriculomegaly in adult (LOVA) [12, 13], The syndrome of hydrocephalus in young and middle-aged adults (SHYMA) [14, 15], etc.

Longstanding overt ventriculomegaly in adult (LOVA) is a specific form of non-communicating hydrocephalus that often causes hydrocephalic dementia [16]. It is a unique category of hydrocephalus first presented by Oi in the mid-1990's. Before this new category was proposed, patients with LOVA might have been considered within the spectrum of normal pressure hydrocephalus (NPH) [15 17].

But descriptions of LOVA presentation in young and middle-aged adults have largely been restricted to obstructive hydrocephalus due to aqueductal stenosis. Because adults in this age range have been included in cohorts of predominately elderly patients with NPH [17, 18, 19] the clinical presentation of young adults has not been differentiated until Cowan et al. [14] described in 2005 a new subgroup of HC patients - hydrocephalus in young and middle-aged adults. They proposed the recognition of a single, clinically distinct syndrome of hydrocephalus in young and middle-aged adults (SHYMA), which is associated with ventriculomegaly and signs and symptoms that are age related and mostly similar, regardless of the aetiology of the hydrocephalus. So according to the authors, LOVA patient group – those with obstructive hydrocephalus due to aqueductal stenosis, appear to be a subset of SHYMA patient group, which comprise chronic HC patients not only with decompensated HC due to aqueductal stenosis, but HC due to obstruction elsewhere but

aqueduct, also non obstructive HC forms and also idiopathic HC.

SHYMA also adopts in a large scale the chronological concept [12] of the hydrocephalus dynamics that Oi accepts to explain the pathophysiology of LOVA, namely that the cause for the distorted CSF dynamics could be sought not necessarily in the immediate prior to diagnose period and also that the CSF dynamics varies with time. [12, 20, 21, 22].

The presented case demonstrates the typical feature of the longstanding chronic HC (SHYMA).

A Typical feature for the all chronic hydrocephaly cases is chronically enlarged ventricles and thinning of the brain mantle. [19] Because of longstanding severe ventriculomegaly, the involved brain parenchyma has lost its compliance. [3] That is the reason why these patients are susceptible to and usually form chronic subdural hematoma formation when over drained. Our case presented shows, that the reduced compliance could contribute also for acute epidural hematoma formation.

In a published series of patients with LOVA hydrocephalus, Oi reports on chronic subdural hematoma formation in all the patients treated with differential pressure valves and concludes that for the treatment of this subgroup of patients with hydrocephalus, the treatment options that should be considered should be or Endoscopic Third Ventriculostomy (ETV), or Programmable Pressure Valve (PPV) for flow diversion [13, 1, 23].

The choice to treat the patient reported with PPV was based mainly on the freedom that the programmable valves give to the treating physician to adjust the pressure settings of the valve according to the needs of the specific patient with a specific CSF dynamics. The protocol that we normally use when using PPV is to preoperatively set the valve to high pressure, usually 2.0 or 2.5 and then slowly reduce the pressure in the postoperative period until the symptoms of the patient settle down. Like this we try to assure slow decrease of the ICP until the patient becomes ideally free of symptoms (or at least to decrease significantly the severity of the symptoms) and in the same time to prevent overdrainage and hematoma formation.

In the case that we report we have a breach of the above mentioned protocol that resulted in epidural hematoma formation that had to be evacuated.

Conclusion

Although the formation of subdural hematomas is not rare conditions resulting from the overdrainage of the VPS in the shunted patients with chronic longstanding ventriculomegaly, the acute epidural hematoma formation after VPS insertion is a rare entity. Our case however shows that it could be also expected as a complication among the overdrained chronic hydrocephalus patients.



References:

1. Duplessis E, Deco P, Barat JL, et al: [The surgical treatment of chronic hydrocephalus in adults with a flow-regulated shunt: review of 46 patients. *Neurochirurgie* 37:40–43, 1991 (Fr)
2. Oi S, Shimoda M, Shibata M, Honda Y, Kogo K, Shinoda M, Tsugane R, Sato O. Pathophysiology of long-standing overt ventriculomegaly in adults. *J Neurosurg* 92:933–940, 2000
3. Oi S, Matsumoto S: Hydrocephalus in premature infants. Characteristics and therapeutic problems. *Childs Nerv Syst* 5:76–82, 1989.
4. Sengupta RP, Hankinson J: Extradural haemorrhage: A hazard of ventricular drainage. *J Neurol Neurosurg Psychiatry* 35: 297–303, 1972.
5. Shrestha R, Pradhan R, Yan J, Chao Y. Recurrent intracranial epidural hematoma following ventriculoperitoneal shunt in a child. *Romanian Neurosurgery* (2012) XIX 2: 116 – 119.
6. Mori K (1995) Current concept of hydrocephalus: evolution of new classifications. *Childs Nerv Syst* 11(9):523–531
7. Oi S (2011) Classification of hydrocephalus: critical analysis of classification categories and advantages of “Multi-categorical Hydrocephalus Classification” (Mc HC). *Childs Nerv Syst* 27:1523–1533.
8. Ransohov J, Shulman K. Fishman RA (1960) Hydrocephalus: A review of etiology and treatment. *J Pediatr* 56:499–511.
9. Dandy WE, Blackfan KD (1914) Internal hydrocephalus. An experimental, clinical and pathological study. *Am J Dis Child* 8:406–482
10. WE (1919) Experimental hydrocephalus, *Ann Surg* 70:129–142
11. Hakim S, Adams RD (1965) The special clinical problem of symptomatic hydrocephalus with normal cerebrospinal fluid pressure. Observations on cerebrospinal fluid hydrodynamics. *J Neurol Sci* 2:307–327
12. Oi S (1998) Hydrocephalus chronology in adults: confused state of the terminology. How should “normal-pressure hydrocephalus” be defined? *Crit Rev Neurosurg* 8:346–356
13. Oi S, Shimoda M, Shibata M, Honda Y, Togo K, Shinoda M (2000) Pathophysiology of long-standing overt ventriculomegaly in adults. *J Neurosurg* 92:933–940
14. Cowan JA, McGirt MJ, Woodworth G, Rigamonti D, Williams MA (2005) The syndrome of hydrocephalus in young and middle-aged adults (SHY-MA). *Neurol Res* 27:540–547
15. Bret P, Chazal J (1995) Chronic normal pressure hydrocephalus in childhood and adolescence. A review of 16 cases and reappraisal of the syndrome. *Childs Nerv Syst* 11:687–691
16. Toma A, Stapleton S, Papadopoulos M, Kitchen N, Watkins L. Natural history of idiopathic normal-pressure hydrocephalus. *Neurosurg Rev* (2011) 34:433–439
17. Barnett GH, Hahn JF, Palmer J (1987) Normal pressure hydrocephalus in children and young adults. *Neurosurgery* 20: 904–907
18. Larsson A, Wikkelso C, Bilting M et al (1991) Clinical parameters in 74 consecutive patients shunt operated for normal pressure hydrocephalus. *Acta Neurol Scand* 84:475–482.
19. Vanneste J, Augustijn P, Tan WF et al (1993) Shunting normal pressure hydrocephalus: the predictive value of combined clinical and CT data. *J Neurol Neurosurg Psychiatr* 56:251–256.
20. McComb JG: Recent research into the nature of cerebrospinal fluid formation and absorption. *J Neurosurg* 59:369–383, 1983
21. Johnston IH, Howman-Giles R, Whittle IR: The arrest of treated hydrocephalus in children. A radio-nuclide study. *J Neurosurg* 61:752–756, 1984
22. Whittle IR, Johnston IH, Besser M: Intracranial pressure changes in arrested hydrocephalus. *J Neurosurg* 62:77–82, 1985
23. Oi S, Hidaka M, Honda Y, et al: Neuroendoscopic surgery for specific forms of hydrocephalus. *Childs Nerv Syst* 15:56–68, 1999.

ТУЙІНДЕМЕ

Н.А. Пеев (м.ғ.д.), С.К. Калевски (м.ғ.д., Ph.D), Д.Г. Харитонов (м.ғ.д.)

Нейрохирургия бөлімшесі

Медицинский университет Варна, Болгария

Көпбейінді госпиталь Қасиетті Анна, Варна, Болгария

ВЕНТРИКУЛО-ПЕРИТОНЕАЛЬДЫ ШУНТТЫ ОРНАТҚАННАН КЕЙІНГІ ЖІТІ ЭПИДУРАЛЬДЫ ГЕМАТОМАНЫҢ ПАЙДА БОЛУЫ

Кіріспе. Жіті эпидуральды гематома мидың жарақатында жиі кездесетін жағдай болып табылады. Алайда, вентрикуло-перитонеальды шунтты орнатқаннан кейінгі жіті эпидуральды гематоманың пайда болуының бірнеше жағдайлары кездесті.

Клиникалық жағдайы. Біз вентрикуло-перитонеальды шунтты орнатқаннан кейінгі жіті эпидуральды гематоманың пайда болуының сирек кездесетін жағдайын ұсынамыз. Бір жыл бойы басы ауруы болған, басы айналуы, сөйлеуде қиналыстары бар, аяқтарының қозғалысы әлсіз,

кіші дәреті ұстамайтын 28 жасар ер кісі ОМҚ-мен келіп түсті. МРТ зерттеуі барлық төрт қарыншаның шамадан тыс дилатациясын көрсетті. Операцияға дейінгі бассүйекшілік қысымды өлшеу БІҚ 6 мм рт айқындады. Пациентке операция жасалынды және Strat бағдарламалы клапаны ОМҚ үшін пайдаланылды. Операциядан кейінгі алтыншы күні жасалған КТ жіті эпидуральды гематоманы көрсетті, тез арада алынып тасталынды. Операциядан кейінгі кезең ешқандай асқынуларсыз өтті пациент айтарлықтай жақсы нәтижемен ауруханадан шығарылды.

Қорытынды: шунт қойылған, созылмалы көп жылдық вентрикуломегалиялы науқастарда ВПШ артық дренажы әсерінен орын алатын субдуральдық гематомалар аса сирек нәтиже болып саналмағанмен, вентрикуло-перитонеальды шунтты орнатқаннан кейінгі жіті эпидуральды гематоманың пайда болуы сирек кездесетін жағдай болып табылады. Алайда, біздің жағдай бұл созылмалы гидроцефалияның артық дренаждалған пациенттер арасындағы асқынулар ретінде қарастырылуы мүмкін екендігін көрсетті.

РЕЗЮМЕ

Н.А. Пеев (д.м.н.), С.К. Калевски (д.м.н., Ph.D), Д.Г. Харитонов (д.м.н.)

Отделение нейрохирургии

Медицинский университет Варна, Болгария

Многопрофильный госпиталь Святой Анны, Варна, Болгария

ОСТРОЕ ЭПИДУРАЛЬНОЕ ОБРАЗОВАНИЕ ГЕМАТОМЫ ПОСЛЕ ВЕНТРИКУЛО-ПЕРИТОНЕАЛЬНОМ ШУНТИРОВАННОМ РАЗМЕЩЕНИИ

Введение. Острая эпидуральная гематома является частым случаем пациентов с травматическим повреждением мозга. Однако, есть только несколько случаев острого эпидурального образования гематомы после введения вентрикуло-перитонеального шунта.

Клинический случай. Мы представляем редкий случай острого эпидурального образования гематомы после введения вентрикуло-перитонеального шунта.

28-летний мужчина, представленный с годовой историей головной боли, головокружением, с трудностью речи, со слабостью нижних конечностей и недержанием мочи поступил для отведения СМЖ. Исследование МРТ показало, чрезмерную дилатацию всех четырех желудочков. Измерение внутричерепного давления в лежачем положении до операции выявило

6 мм рт ВЧД. Пациент был прооперирован и программируемый клапан Strata был использован для отвода СМЖ. КТ скан на шестой послеоперационный день показал острую эпидуральную гематому, которая была срочно эвакуирована. Послеоперационный период прошел без происшествий. Пациент был выписан со значительным улучшением.

Заключение. Хотя образование субдуральных гематом не редкий результат вытекающий из избыточного дренажа, ВПШ у шунтированных больных с хронической многолетней вентрикуломегалией, образование острой эпидуральной гематомы после введения ВПШ является редким явлением. Однако, наш случай показывает, что это может быть рассмотрено как осложнение среди пациентов с дренированным избытком хронической гидроцефалии.



УДК 616.832-001.2:616.89-0084

Г.Ш.Мамбетова, К.Б.Нурғалиев, Ж.Е.Сағатбекова, А.Т.Иманғожаева, Е.В.Кисаев
АО «Национальный центр нейрохирургии» г. Астана, Казахстан

МЕТОДИКА ПОЭТАПНОГО ВОССТАНОВЛЕНИЯ ДВИГАТЕЛЬНЫХ НАВЫКОВ

Предоставляется обзор картина эффективности применения методики поэтапного восстановления двигательных навыков в комплексе ЛФК как наиболее важный этап в процессе восстановления чувствительности и двигательных функций у спинальных больных.

Ключевые слова: спинальная травма, реабилитация, поэтапное восстановление двигательных навыков, ЛФК

Введение

Под позвоночно-спинномозговой травмой (ПСМТ) понимают механическое повреждение позвоночника и (или) содержимого позвоночного канала (спинного мозга, его оболочек, сосудов, спинномозговых нервов). Больные со спинальной травмой представляют собой наиболее тяжелый контингент реабилитационных учреждений. Наиболее тяжелой в прогностическом плане считается травма шейного отдела позвоночника. [1,2,10] У этого контингента больных динамика в двигательном плане имеет медленное и длительное течение. По статистическим данным ряда авторов из всех травм травма позвоночника и спинного мозга составляет 65%. Из них травма шейного отдела позвоночника составляет 10% случаев, травма поясничного отдела позвоночника-70%, травма грудного отдела позвоночника-55. травма грудопоясничного отдела позвоночника-10%, травма копчика-5%. Причем у мужчин ПСМТ встречается чаще, чем у женщин (у мужчин-85%, у женщин-15%). Основными задачами на раннем этапе реабилитации больных со спинальными травмами являются: профилактика трофических нарушений, пролежней, контрактур и тугоподвижностей в суставах, а также восстановление поверхностной и глубокой чувствительности, тонуса поперечно-полосатой мускулатуры, устранение атрофии мышц, пареза, что достигается применением пассивной гимнастики.[1,3]

Подключением на этом этапе методики поэтапного восстановления двигательных навыков мы достигаем раннего восстановления двигательных функций пациента, появления сгибательных движений в тазобедренных, коленных, голеностопных суставах вследствие спинального автоматизма, удержания туловища в положении сидя, на четвереньках, улучшение пространственной ориентации и координации пациента, удержания туловища в положении стоя с опорой, стимуляции произвольных движений, отработки элементов навыков самообслуживания [1,3,7].

В восстановительном лечении спинальных больных используются основные принципы

1. Принцип последовательности реабилитационных мероприятий [1,4,5]. В основу заложены этапы развития в онтогенезе. При восстановлении функций суставов движения начинают со сгибания и приведения, а затем производят разгибания и отведения. Верхние конечности восстанавливаются быстрее нижних конечностей. Восстановление движений начинают с крупных суставов.

2. Принцип постепенности [1,2,4,10].

Объем физической нагрузки должен нарастать постепенно в соответствии с улучшением состояния больного и повышением толерантности к физической нагрузке.

3. Принцип взаимосвязи структуры и функции [1,2,4,10].

Чем активнее идут реабилитационные мероприятия, тем быстрее идут регенерационные процессы во всех тканях и органах.

4. Принцип адекватного наращивания мышечной массы [1,2,5].

На нижние конечности силовые нагрузки должны быть больше чем на верхние конечности.

Цель исследования

Изучение результатов применения методики поэтапного восстановления двигательных навыков и определение ее эффективности в реабилитации спинальных больных.

Материалы и методы

В отделении нейрореабилитации АО «НЦН» на протяжении 1 года и 4 месяцев с ноября 2012 года по март 2014 года были проанализированы и исследованы пациенты с ПСМТ. В исследуемый контингент вошли больные с травмой шейного отдела позвоночника, травмой грудопоясничного отдела позвоночника, травмой поясничного отдела позвоночника с наиболее грубыми неврологическими нарушениями, с вялыми и спастическими парезами. Оценку результатов

осуществляли с помощью 5-балльной шкалы измерения мышечной силы, шкалы Ашворта, шкалы оценки чувствительных нарушений и визуальных критериев на появление каких-либо движений либо каких-либо двигательных навыков (перевороты со спины на живот и наоборот, стояние и передвижение на четвереньках, коленях, вставание с колен на ноги, передвижение с ходунками или у брусьев и т.д.)

Результаты

Возраст пациентов со спинальной травмой варьирует от 18 до 60 лет.

По половому признаку преобладают мужчины-34 (85%), женщины- 6 (15%).

90% случаев составляют лица трудоспособного возраста.

Все больные разделены на 2 группы: контрольную (15 пациентов) и основную (15 пациентов). Число больных с ранним периодом ПСМТ (давность травмы до 1 года) составило 7 пациентов (25%). Число больных с поздним периодом ПСМТ (давность травмы от 1 года и выше) составило 23 пациентов (75%). Контрольную группу составляли пациенты, получившие необходимый комплекс ЛФК (дыхательная гимнастика, пассивная гимнастика, лечение положением, упражнения на укрепление мышц тазовых органов и пресса, ортостатическая гимнастика) с включением сюда методики поэтапного восстановления двигательных навыков. Основную группу составляли пациенты, также получившие необходимый комплекс ЛФК, с акцентом на пассивную гимнастику, ортостатическую гимнастику и упражнения на укрепление мышц спины и конечностей без раннего включения методики поэтапного восстановления двигательных навыков. Число больных со спастическими парезами в контрольной группе составляло - 8 (53%), число больных с вялыми парезами составляло - 7 (47%). В основной группе число больных со спастическими парезами составляло - 9 (60%), число больных с вялыми парезами составляло - 6 (40%).

Таблица - 1

Распределение пациентов по локализации травмы

Локализация травмы, отдел позвоночника	Контрольная группа		Основная группа	
	Абс.	%	Абс.	%
Пациенты с травмой ШОП	1	7%	1	7%
Пациенты с травмой груднопоясничного отдела позвоночника	3	20%	3	20%
Пациенты с травмой поясничного отдела позвоночника	11	73%	11	73%
Пациенты с ранним периодом ПСМТ	2	13%	1	7%
Пациенты с поздним периодом ПСМТ	13	87%	14	93%
Всего	15	100%	15	100%

В процессе восстановительного лечения у пациентов с чувствительными нарушениями контрольной группы в среднем на 10-й день наблюдалось появление жжения, «ползания мурашек» по коже, а также появилась реакция на барораздражители и болевые ощущения в паретичных конечностях. К концу выписки у 10 пациентов из 15 пациентов контрольной группы отмечается начало восстановления чувствительности либо расширение зоны чувствительности, которое чаще всего проявлялось в виде покалывания, жжения, «ползания мурашек», появления болевых ощущений. В 2 случаях отмечается появление потливости на подошвенной поверхности стоп. В основной группе начало восстановления чувствительности отмечалось у 2 пациентов.

Таблица - 2

Оценка коррекции мышечной спастичности у пациентов контрольной и основной групп по шкале Ашворта

	Число пациентов со спастическими парезами	Среднее ариф.число в баллах мышечного тонуса к началу восстановительного лечения	Среднее ариф.число в баллах мышечного тонуса к концу восстановительного лечения
Контрольная группа	8 (53%)	3 балла	2 балла
Основная группа	9 (60%)	3 балла	2,5 балла

Уменьшение мышечной спастичности достигалось также комплексом реабилитационных мероприятий: медикаментозным лечением (мидокалм, баклофен), расслабляющих техник массажа, пассивной гимнастики, коррекцией положением, а также применением физиолечения.



Таблица - 3

Оценка результатов восстановления мышечной силы у пациентов с вялыми парезами по 5-ти балльной шкале оценки мышечной силы

	Число пациентов с вялыми парезами	Среднее ариф. число в баллах мышечной силы к началу восстановительного лечения	Среднее ариф. число в баллах мышечной силы к концу восстановительного лечения
Контрольная группа	7 (47%)	0 баллов	1,5 балл
Основная группа	6 (40%)	0 баллов	0 баллов

Как видно из таблицы № 3, у пациентов контрольной группы с вялыми парезами, которым проводилась методика поэтапного восстановления двигательных навыков в виде ранней активизации пациентов, обучение самостоятельным переворотам либо с поддержкой, подсаживание пациентов, обучение стоянию на четвереньках с поддержкой с удерживанием таза отмечается значительная динамика в улучшение мышечного тонуса и мышечной силы. У 5 (33%) пациентов отмечается появление произвольных движений, у всех 15 пациентов контрольной группы с вялыми парезами отмечаются произвольные сокращения

мышц конечностей к концу восстановительного лечения.

Пациенты с ПСМТ получали кроме ЛФК медикаментозное лечение (миорелаксанты, антихолинэстеразные средства, витамины, ноотропы по показаниям), различные виды массажа, физиопроцедуры в виде СМТ, лазера, различных токов, электростимуляций, гальванованн, жемчужных ванн, душа Шарко и т.д.

Таблица - 4

Распределение пациентов контрольной и основной групп по получению физиопроцедур и массажа

Название процедуры	Абс. (контрольной группы)	% (контрольной группы)	Абс. (основной группы)	% (основной группы)
СМТ	6	40 %	7	47 %
Лазер	4	27 %	3	20 %
Токи	5	33 %	4	27 %
УВЧ	6	40 %	5	33 %
Электро-стимуляция	7	47 %	6	40 %
Гальванованны	4	27 %	5	33 %
Жемчужные ванны	5	33 %	5	33 %
Душ Шарко	3	20 %	3	20 %
Массаж	15	100 %	15	100 %
Магнитотерапия	3	20%	6	40%
Всего	58	100 %	55	100 %

Таблица - 5

Результаты восстановительного лечения больных со спинномозговой травмой контрольной группы

Локализация травмы, отдел позвоночника	Число больных	Отсутствие переворотов	Не сидят	Не ползают	Не ходят	Самостоятельные перевороты со спины на живот и обратно	Сидят самостоятельно либо с опорой на руки	Стали стоять на четвереньках, удерживая таз	Передвигаются на четвереньках	Стали стоять с поддержкой	Стали ходить с поддержкой
ШОП	1	-	-	1	1	-	-	1 (100%)	1 (100%)	1 (100%)	1 (100%)
груднопоясничный	3	2	2	3	3	2 (100%)	2 (100%)	2 (67%)	2 (67%)	3 (100%)	2 (67%)
поясничный	11	-	2	6	11	-	2 (100%)	6 (100%)	6 (100%)	11 (100%)	5 (45%)
Всего	15	2	4	10	15	2 (100%)	4 (100%)	9 (90%)	9 (90%)	15(100%)	8 (72%)

Таблица - 6

Результаты восстановительного лечения больных со спинномозговой травмой основной группы

Локализация травмы, отдел позвоночника	Число больных	Отсутствие переворотов	Не сидят	Не ползают	Не ходят	Самостоятельные перевороты со спины на живот и обратно	Сидят самостоятельно либо с опорой на руки	Стали стоять на четвереньках, удерживая таз	Передвигаются на четвереньках	Стали стоять с поддержкой	Стали ходить с поддержкой
ШОП	1	-	1	1	1	-	-	-	-	-	-
груднопоясничный	3	1	1	3	3	-	1 (100%)	-	-	-	-
поясничный	11	-	-	3	11	-	-	-	-	-	-
Всего	15	1	2	7	15	0	1 (50%)	0	0	0	0

Как видно из таблиц № 5, № 6 значительная динамика в двигательном плане наблюдается у спинальных больных контрольной группы по сравнению с основной группой. Больные контрольной группы приобретали основные двигательные навыки, такие как: перевороты со спины на живот и с живота на спину, ползание, передвижение на четвереньках, на коленях, научились стоять у опоры и делать шаги с ортезами на нижних конечностях с поддержкой. Кроме того практиковалась ранняя вертикализация больных на ноги с целью разгрузки большого и малого круга кровообращения, устранения застойных явлений в кровеносных и лимфатических сосудах, улучшения кровообращения внутренних органов, улучшения тонуса и дренажной функции мочевого пузыря. Параллельно тренировалась пространственная координация и равновесие пациентов, отработывалась техника правильного шага, переноса тела. Методика поэтапного восстановления двигательных навыков проводилась больным инструкторами ЛФК в отделении нейрореабилитации. Штат инструкторов состоит из 4 единиц. Для вертикализации и тренировки шага использовались шведская стенка, параллельные брусья, ходунки, ортезы, тьютора на нижние конечности, стулья. Наглядно двигательную динамику контрольной и основной групп можно рассмотреть на ниже представленном графическом изображении.

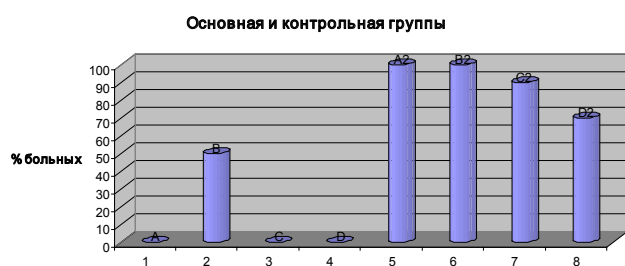

Рисунок 1 - Результаты применения методики поэтапного восстановления двигательных навыков в контрольной группе риска

A – процент больных основной группы, обучившихся самостоятельным переворотам.

A2 - (контрольной группы)
B - процент больных основной группы, научившихся самостоятельно сидеть.
B2 - (контрольной группы)
C - процент больных основной группы, научившихся ползать.
C2 - (контрольной группы)
D - процент больных основной группы, научившихся стоять либо ходить с поддержкой.
D2 - (контрольной группы)
 Учитывая хорошую результативность в двигательном плане целесообразно начало применения методики поэтапного восстановления двигательных навыков у больных с ПСМТ начиная с отделения реанимации, отделения спинальной нейрохирургии.

Заключение

1. Проведение реабилитации спинальных больных с учетом основных принципов реабилитации, раннего включения методики поэтапного восстановления двигательных навыков способствует значительной эффективности ЛФК.

2. Активный двигательный режим, силовые нагрузки способствуют улучшению кровообращения, устранению застоя, профилактике пролежней, контрактур, улучшению обменно-трофических процессов, укреплению сердечно-сосудистой системы, повышению толерантности больных к физической нагрузке, приобретению навыков самообслуживания, повышению качества жизни пациентов.

3. Необходима непрерывность поэтапного восстановления двигательных навыков с раннего этапа реабилитации (отделения реанимации, отделения спинальной нейрохирургии, отделения нейрореабилитации, на дому в амбулаторных условиях и т.д.).

4. Актуальными остаются вопросы дальнейшей реабилитации спинальных больных, направленные на тренировку ходьбы с акцентом на шаг, правильный перенос тела, выпад бедра, для которых требуется использование дополнительных приспособлений в виде ортезов, тьюторов на нижние и верхние конечности, фиксаторов коленных суставов, ходунков, вертикализаторов и т.д.

СПИСОК ЛИТЕРАТУРЫ

1. Качесов В.А. Основы интенсивной реабилитации. Травма позвоночника и спинного мозга / В.А.Качесов.- Санкт-Петербург, 2005.- 128с.
2. Качесов В.А. Скоростная реабилитация пациентов с тетраплегиями / СПб.: Тонэкс, 1998.
3. Карепов Г.В. ЛФК и физиотерапия в системе реабилитации больных с травматической болезнью спинного мозга. Киев.: Здоровье, 1991.- 131с.
4. Судаков К.В. Теория функциональных систем.- М.: НИИ им. П.К.Анохина, 1996.



5. Карлсон Б. Основы эмбриологии по Пэттену / Пер.с англ.- М.: Мир, 1983.
6. Белова А.Н. Нейрореабилитация: руководство для врачей / А.Н.Белова.-М.:Антидор, 2002.- 433с.
7. Гранди Д. Травма спинного мозга / Пер.с англ.- М.: 2008.-124с.
8. Епифанов В.А. ЛФК и спортивная медицина / В.А.Епифанов.-М.:Медицина, 1999.-304с.
9. Попов.В.А. Физическая реабилитация / В.А.Попов- изд.Феникс,2005.-608с.
10. Качесов В.А. Основы интенсивной реабилитации. Травма позвоночника и спинного мозга. М., 2002. Кн.1.126 с.
11. Леонтьев М.А. Лечение и реабилитация пациентов с травматической болезнью спинного мозга // Реабилитация инвалидов с нарушением функций опоры и движения / Под ред. Л.В.Сытина, Г.К.Золоева, Е.М.Васильченко. Новосибирск, 2003.с.299-335.
12. Иванова Г.Е., Цыкунов М.Б., Дутикова Е.М. Клиническая картина травматической болезни спинного мозга // Реабилитация больных с травматической болезнью спинного мозга; Под. общ. ред. Г.Е.Ивановой, В.В.Крылова, М.Б.Цыкунова, Б.А.Поляева.- М.,2010.-640с.

ТҮЙІНДЕМЕ

Г.Ш. Мамбетова, К.Б. Нургалиев, Ж.Е. Сағатбекова, А.Т. Имангожаева, Е.В. Кисаев
АҚ «Ұлттық нейрохирургия орталығы» Астана қ., Қазақстан

ҚОЗҒАЛУШЫ ДАҒДЫЛАРДЫ КЕЗЕҢІМЕН ҚАЛПЫНА КЕЛТІРУ ӘДІСТЕРІ

Арқа ауруларымен ауыратын науқастардың қозғалыс функциялары мен сезінулерін қалпына келтіру үрдістеріндегі маңызды кезеңдерде ЕДШ кешенді қалпына келтіруші қозғалыс

дағдыларының әдістерін кезеңімен қолданудағы тиімділік суретін сипаттау ұсынылады.

Негізгі сөздер: жұлын жарақаты, оңалту, қозғалушы дағдыларды кезеңімен қалпына келтіру ЕДШ.

SUMMARY

G.SH. Mambetova, K.B. Nurgaliyev, ZH.E. Sagatbekova, A.T. Imangozhayeva, E.V. Kisayev
JSC «National Centre for Neurosurgery», Astana city, Kazakhstan

METHODS OF THE GRADUAL RECOVERY OF MOTOR SKILLS

There is an overview picture of the effectiveness of methods of gradual restoration of motor skills in complex physical therapy provided as the most im-

portant step in the recovery and motor function in spinal patients.

Key words: spinal injury, rehabilitation, gradual recovery of motor skills, ETP.



СЛУЧАЙ ИЗ ПРАКТИКИ

УДК 616.831.31-009.24

И.В. Бондарева, С.В. Савинов, Я.Е. Акчурина, Н.В. Михайлова, Ж.Е. Утебеков, И.Ю. Ситников, Т.Н. Синицына, Р.А. Абедимова

Кафедра функциональной диагностики с курсом нейрофизиологии и реабилитологии КРМУ SVS Лаборатория изучения эпилепсии, судорожных состояний и семейного мониторинга им. В.М.Савинова, г. Алматы, Казахстан

АЛГОРИТМ НЕЙРОФИЗИОЛОГИЧЕСКОЙ И НЕЙРОВИЗУАЛЬНОЙ ДИАГНОСТИКИ ПАЦИЕНТОВ С ФОКАЛЬНОЙ ФОРМОЙ ЭПИЛЕПСИИ

В статье, на примере анализа ведения пациента и обобщения литературных данных, предложен алгоритм обследования и лечения фармакорезистентных форм фокальной лобной эпилепсии. Пациент наблюдался в «SVS Лаборатории изучения эпилепсии, судорожных состояний и семейного мониторинга им. В.М.Савинова». Пациенту неоднократно проводились рутинные ЭЭГ и МРТ, назначались базовые и резервные антиэпилептические препараты, но без эффекта. После поступления в SVS Клинику, на основании тщательного анализа семиотики приступов, проведенного длительного видео ЭЭГ с фиксированием иктакльной ЭЭГ, определения уровня концентрации противосудорожных препаратов, у пациента была заподозрена фокальная кортикальная дисплазия. После проведения высокоразрешающего МРТ с мощностью поля 3 Тесла и программой тонко срезного сканирования, функционального и спектрального МРТ, диагноз был подтвержден и пациент прооперирован.

Применение предложенного алгоритма поможет врачам избежать не нужных и малоинформативных исследований в отношении тяжелых форм эпилепсии.

Ключевые слова: фокальные (парциальные) приступы, лобная эпилепсия, видео ЭЭГ-мониторинг, высокоразрешающее МРТ

Простые и сложные фокальные судороги составляют 60-70% среди всех форм эпилепсий [9]. Височная эпилепсия – наиболее распространенная форма фокальных эпилепсий. По данным разных авторов составляет 56% всех идентифицированных случаев эпилепсии и 30-35% по данным Panayiotopoulos C.P. 2010. Лобно-долевая эпилепсия занимает второе место по распространенности среди фокальных форм эпилепсии, составляет 1-2% среди всех форм эпилепсии, среди всех парциальных эпилепсий от 20% до 40%. Наличие тесных связей лобной доли с лимбической системой при определении происхождения эпилептических приступов вызывает большие затруднения. В 27% случаев лобная эпилепсия сочетается с височной долей и с центральной сенсорно-моторной зоной в 32,5% случаев. Реже встречаются теменная – 6% и затылочная 5-10% эпилепсии [1,4, 7,9].

Этиология. Лобные эпилепсии могут быть симптоматическими, возможно симптоматическими и идиопатическими. Этиологией симптоматической лобной эпилепсии может быть нарушение формирования коры (57,4%), опухоли (16,4%), травмы и другие поражения (26,2%) [9]

Классификация. Выделяют следующие формы лобной эпилепсии:

- моторная
- оперкулярная

- дорсолатеральная
- орбитофронтальная
- передняя фронтальная
- цингулярная
- исходящая из дополнительной моторной зоны

Симптоматика

• Приступы, исходящие из моторной коры: Характерны Джексоновские приступы, развивающиеся контралатерально очагу, преимущественно клонического характера, в некоторых случаях со вторичной генерализацией. Паралич Тодда – нередкий феномен лобной эпилепсии.

• Оперкулярные приступы: Пароксизмы жевательных, сосательных, глотательных движений, причмокивания, облизывания, покашливание, характерна гиперсаливация. Возможно ипсилатеральное подергивание мышц лица, нарушение речи или произвольная вокализация.

• Дорсолатеральные приступы проявляются адверсивными приступами с насильственным поворотом головы и глаз, обычно контралатерально очагу. При вовлечении задних отделов нижней лобной извилины (центр Брока) возникают пароксизмы моторной афазии.

• Орбитофронтальные приступы проявляются различными вегето-висцеральными феноменами. Нередко фаринго-оральные автоматизмы с гиперсаливацией.



• Передние фронтополярные приступы сопровождаются ощущением «насилованных мыслей» или «провала» с потерей контакта, адверсия головы и глаз, при прогрессировании возможны контраверсивные движения и аксиальные клонии, падение и вегетативные симптомы.

• Цингулярные приступы: Парциальные приступы со сложными моторными жестовыми автоматизмами в дебюте. Часто вегетативная симптоматика, также изменения настроения, аффективные расстройства.

• Приступы, исходящие из дополнительной сенсомоторной зоны: Стереотипные гипермоторные приступы с билатеральной и асимметричной тонической установкой конечностей, часто с контраверсией глаз и головы, вокализацией или остановкой речи. Короткие с внезапным началом и окончанием приступа, преимущественно ночные, частые, обычно ночные [9].

Зачастую при височных формах эпилепсии ЭЭГ-мониторинги бывают малоинформативными, при наличии нескольких очагов в головном мозге необходимо проводить дифференциальную диагностику. К сожалению, на МРТ часто в нашей практике патологические изменения не выявляются [1, 2, 3, 9].

Представляем вашему вниманию клинический случай.

Пациент Н.Б., 8 лет, поступил в мае 2013 года с жалобами на приступы судорог. Приступы протекают в виде напряжения и abduction левой ноги. Левая рука сжимается в кулак и прижимается к себе. Голова поворачивается налево, глаза направо. Правая рука поднимается вверх и заводится за голову. Данное состояние длится около 15 секунд, после чего глаза смотрят перед собой и начинаются клонические подергивания. Продолжительность приступа около 30 секунд.

Раньше после приступа сознание не нарушалось, моментально восстанавливался и мог продолжить разговор, во время которого произошел приступ.

Приступы протекали сериями по 10-15 раз каждые 2 минуты. После чего был перерыв, спал около 30 мин. Приступы повторялись каждый час.

В 2007 году назначили депакин хроно и ламиктал. В июне 2007 отменили данные препараты и назначили топамакс. Во время отмены произошло ухудшение состояния – начался эпилептический статус. Приступы установились с частотой раз в 1,5 мес. Начали обращаться к целителям. Отменили прием препаратов. Снова начался эпистатус. Попали в реанимацию.

В реанимации назначили конвулекс, кеппру, топамакс и фенobarбитал. На фоне данного лечения улучшения не наблюдалось. Оставили кеппру по 500 мг 2 раза (вес на тот момент 26 кг). На этом фоне приступы прекратились, в течение

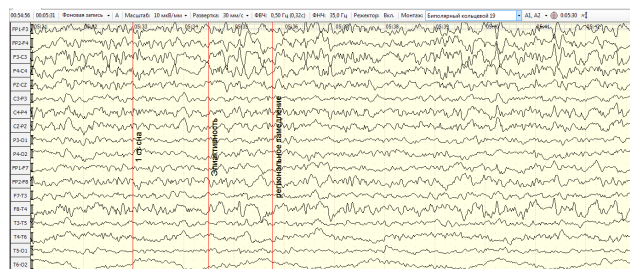
1,5 лет приступов не было. Через 1,5 года приступы возобновились.

В декабре 2012 отменили кеппру, назначили депакин хроно сфера по 500 мг 2 раза в день и гормоны – преднизолон 12,5 мг/сут. Приступы стали реже. Стали протекать вместо 70-100 раз в день до 5-10 раз. В феврале 2013г. начали отменять прием гормонов. После чего произошло ухудшение состояния.

В марте 2013 уровень тромбоцитов резко упал. Начались носовые кровотечения. Дозировку депакина уменьшили. Назначили кеппру.

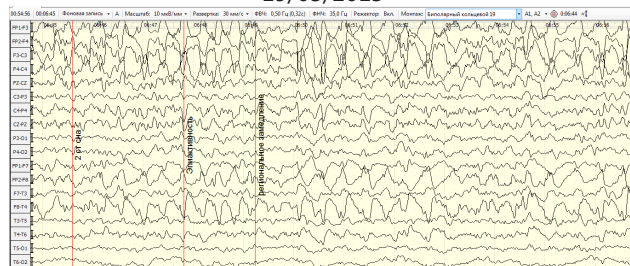
Сейчас перерывы между приступами до 30 минут. Могут протекать сериями до 10 раз. Также во сне.

В мае 2013 года прошли длительное ЭЭГ обследование в «SVS Лаборатории изучения эпилепсии, судорожных состояний и семейного мониторинга им. В.М. Савинова». За время ЭЭГ мониторинга было зарегистрировано 6 генерализованных тонико-клонических приступов с началом с правой лобно-центрально-передневисочной области. Во время ЭЭГ мониторинга в бодрствовании и во сне регистрировалось региональное замедление тета, дельта диапазона бифронтально с распространением на правые центрально-передневисочные отведения, в этих же отделах отмечалась эпилептиформная активность в виде комплексов пик-медленная, острая-медленная волна. Местами региональное замедление и эпилептиформная активность носят продолженный характер.



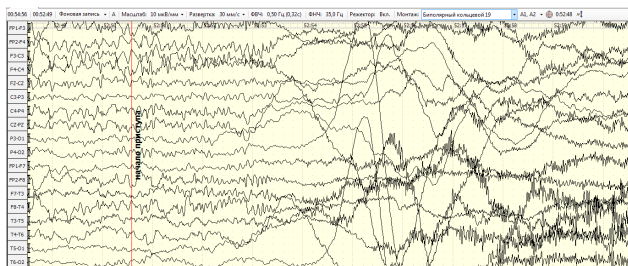
Эпилептиформная активность и региональное замедление на фоне первой стадии сна в правой лобно-височной области.

«SVS Лаборатория изучения эпилепсии, судорожных состояний и семейного мониторинга им В.М. Савинова»
19/03/2013



Продолженное региональное замедление и эпилептиформная активность в правых лобно-височных отведениях. Вторая стадия сна.

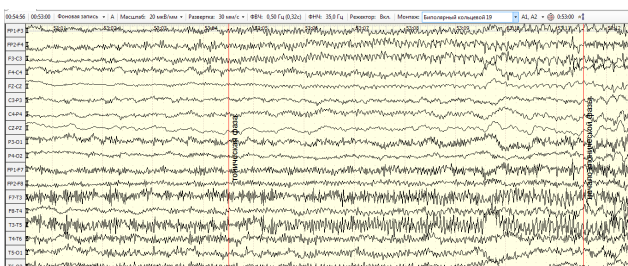
«SVS Лаборатория изучения эпилепсии, судорожных состояний и семейного мониторинга им В.М. Савинова»
19/03/2013



Иктальная ЭЭГ. Начало приступа с полипиковой активности в правых лобно-височных отделах.

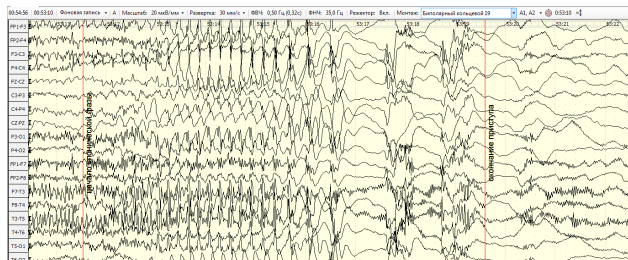Артефакты от миограммы и смещения электродов.

«SVS Лаборатория изучения эпилепсии, судорожных состояний и семейного мониторинга им В.М.Савинова»
19/03/2013



Иктальная ЭЭГ. Тоническая фаза сопровождается диффузной полипиковой активностью с акцентом по передним отделам.

«SVS Лаборатория изучения эпилепсии, судорожных состояний и семейного мониторинга им В.М. Савинова»
19/03/2013



Иктальная ЭЭГ. Клиническая фаза приступа сопровождается диффузными комплексами спайк-медленная волна. При окончании приступа наблюдается снижение амплитуды БЭА головного мозга.

«SVS Лаборатория изучения эпилепсии, судорожных состояний и семейного мониторинга им В.М. Савинова»
19/03/2013

Приступы исходят из дополнительной моторной зоны лобной области.

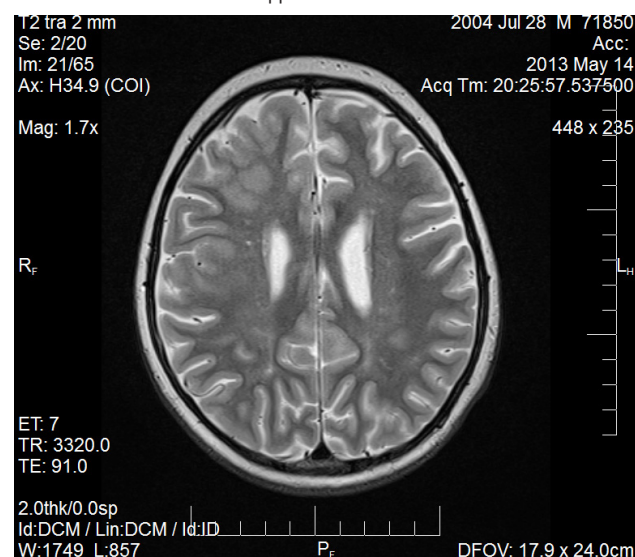
В 2012 г. прошли МРТ головного мозга в г.Алматы в «Региональном диагностическом центре», по данным МРТ выставлено заключение – Резидуальная энцефалопатия.

В 2013 г. сделали МРТ в г. Санкт-Петербург. Обследование проводилось на томографе Magnetom VERIO и индукцией магнитного поля 3,0 Тл с получением 3D изображений, взвешенных по T1 и T2 в сагиттальной плоскости с толщиной среза 1,0 мм с последующими многоплоскостными реконструкциями в коронарной и аксиальной плоскостях с толщиной среза 1,0 мм, аксиальной FLAIR с жироподавлением с толщиной среза 2,0 мм, T1 IRSPACEsag 3D, многовексельной

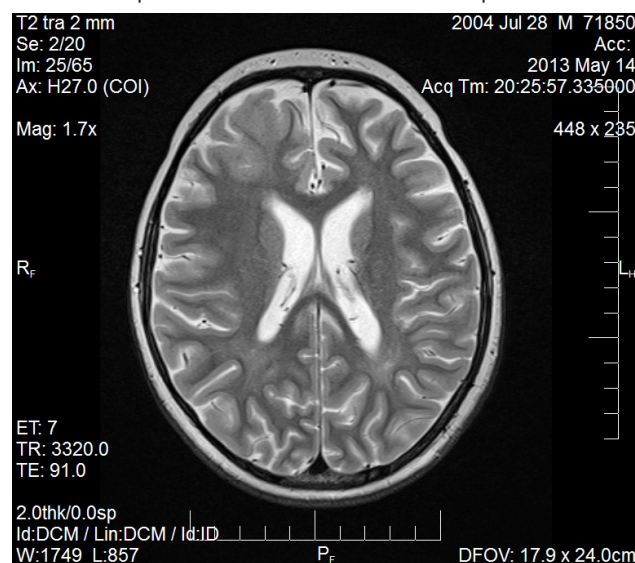
спектроскопии области гиппокампов (CSI, TE135 ms, voxel 10*10*15 mm), многонаправленными диффузно-взвешенными изображениями (MDDW, 20 направлений, b0, b1000) автоматическое картирование: ADC, Tensor (с построением 3D трактографии, TRACEW, FA). Получены результаты: МР картина нарушения нейрональной миграции (кортикальная дисплазия в проекции средней и нижней лобных извилин, а так же задних отделах верхней лобной извилины) правого полушария большого мозга. Признаки резидуальной лейкомаляции в лобных, а так же (в большей степени) теменных и затылочных долях – резидуального характера.

Структурные и метаболические изменения гиппокампов по типу атрофических явлений с латерализацией на правый.

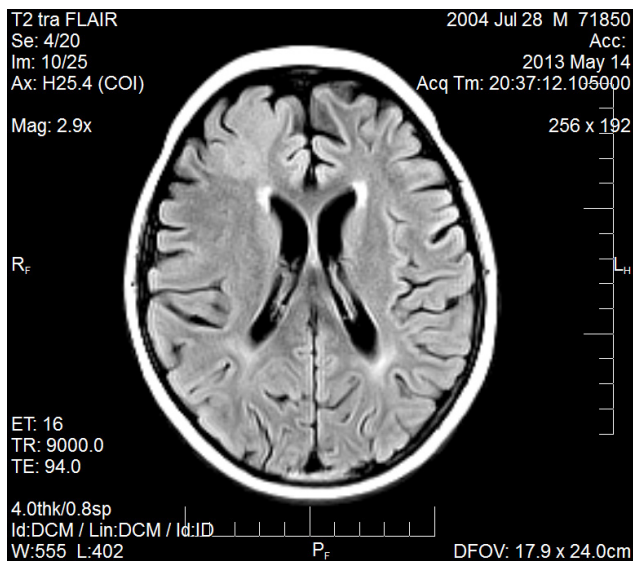
Снимки МРТ от 2013 года.



В проекции правой гемисферы - лобной доли белое вещество уменьшено в размерах, имеет повышенный сигнал вероятнее за счет скопления гетеротопионов.



Задние отделы верхней лобной извилины, а так же передние отделы средней и нижней лобных извилин неравномерно "утолщены".



Признаки изменения объема белого вещества лобных, теменных и затылочных долей за счет участков перивентрикулярной лейкомаляции.

Пациент консультирован профессором, д.м.н., руководителем 2 детского отделения Института нейрохирургии им. акад. Н.Н.Бурденко А.Г.Мелияном, рекомендовано оперативное лечение.

В связи с обнаружением у ребенка активного гепатита С, высоких показателей АсТ, АлТ, операция по поводу эпилепсии была отложена.

В «РНЦНХ» г.Астаны был проведен консилиум с участием профессора института им. А.Л.Паленова В.А.Хачатрян, заведующего отделением, к.м.н. М.Р.Рабандиярова, врача-невролога, к.м.н. Г.С.Ибатовой, А.М. Жарасова. Консилиумом решено: учитывая отсутствие эффекта от консервативной терапии рекомендовано оперативное лечение.

Была проведена операция в «РНЦНХ» г. Астаны: Костно-пластическая трепанация правой лобно-теменно-височной области. Функциональная (проводящая) гемисферотомия.

Гистологическое исследование: Очаговые субарахноидальные кровоизлияния. Множественные, местами обширные диапедезные кровоизлияния в веществе головного мозга. Неравномерно выраженный микроглиоз, сателлиоз. Неравномерно выраженный периваскулярный и перичеселлюлярный отек вещества мозга с микронекрозами на фоне острого полнокровия сосудов микроциркулярного русла. Продуктивный лептоменингит с геморрагическим компонентом.

По результатам длительного видео ЭЭГ-мониторинга через 4 месяца после операции наблюдается стойкая межполушарная асимметрия и асинхрония со снижением амплитуды по правой гемисфере. В бодрствовании и во сне регистрируется эпилептиформная активность по

левым, и менее выраженная, по правым лобно-центрально-височным отведениям.

После операции у ребенка приступы отсутствуют, отмечается парез левой руки. Наблюдается положительная динамика в развитии.

Выводы:

На примере клинического случая мы проанализировали логику обследования и лечения пациентов с фокальными эпилепсиями, не поддающихся лечению базовыми препаратами. Ошибки в тактике ведения пациента от момента обращения до конечного результата совершаются из-за отсутствия единого алгоритма диагностики и лечения фокальных эпилепсий. Используются методы диагностики, которые заведомо будут не информативными, такие как рутинные ЭЭГ и низкоразрешающее МРТ. Участковыми врачами не осознается конечная цель, которая может включать в себя хирургическое лечение.

На основе вышеперечисленного и данных литературы, предлагается алгоритм диагностики и лечения пациентов с приступами от момента обращения.

1. Необходим тщательный сбор анамнеза и определение семиологии приступов.
2. Длительный видео-ЭЭГ мониторинг, обязательно с записью икталной ЭЭГ.
3. МРТ с величиной индукции магнитного поля минимум 3 Тесла и толщиной срезов 1-3 мм.
4. Определение уровня кальция в крови.
5. Холтер ЭЭГ для дифференциальной диагностики с синкопальными состояниями.
6. Только после проведения всех исследований выставляется диагноз и назначается лечение в соответствии с формой эпилепсии.
7. Назначение адекватного лечения. При отсутствии эффекта от монотерапии в максимальных дозировках, должен быть введен второй антиконвульсант. При отсутствии эффекта от политерапии тремя препаратами и изменении комбинаций минимум два раза выставляется диагноз Фармакорезистентная эпилепсия.

8. При установлении Диагноза Фармакорезистентная эпилепсия, либо при наличии очага деструкции или нарушении архитектоники, при котором заведомо не будет эффекта от консервативной терапии, пациент должен быть направлен на хирургическое лечение.

Все наши действия должны быть направлены на правильное лечение и купирование приступов, ведь с течением времени возникают когнитивные нарушения, а так же происходят необратимые изменения личности.



ЛИТЕРАТУРА

1. Броун Т., Г.Холмс «Эпилепсия. Клиническое руководство» Пер. с англ. М. 2006г; 57-66.
2. Дзяк Л.А., Зенков Л.Р., Кириченко А.Г. «Эпилепсия», Киев 2001г; стр. 54-56.
3. Зенков Л.Р. «Клиническая электроэнцефалография с элементами эпилептологии» 3-е издание, М. 2004г; стр. 152-155.
4. Карлов В.А. «Эпилепсия у детей и взрослых женщин и мужчин» - М.2010г; стр. 311-410.
5. Карлов В.А., Петрухин А.С. «Эпилепсия у подростков» Журн. неврол. и психиат. 2002г. №9, стр. 9-14.
6. Королева Н.В., Колесников С.И., Воробьев С.В. «Электроэнцефалографический атлас эпилепсий и эпилептических синдромов у детей» - М. 2011; стр. 85-139.
7. Мухин К.Ю., А.С.Петрухин, Л.Ю.Глухова «Эпилепсия. Атлас электро-клинической диагностики» - М. 2004г; 364-415.
8. «Эпилептология детского возраста: Руководство для врачей» Под ред. С.С.Петрухина – М., 2000 г.; 105-159.
9. Panayiotopoulos C.P. «A clinical Guide to Epileptic Syndromes and their treatment» revised second edition 2010; 435-489.

ТҮЙІНДЕМЕ

И.В. Бондарева, С.В. Савинов, Я.Е. Акчурина, Н.В. Михайлова, Ж.Е. Утебеков, И.Ю. Ситников, Т.Н. Синицына, Р.А. Абедимова

Нейрофизиология және реабилитология функционалдық диагностика кафедрасы ҚРМУ курсымен SVS В.М.Савинов атындағы қояншықты, сіңір тартылудың күйін және отбасылық мониторингін байқау зертханасы, Алматы қ., Қазақстан

ҚОЯНШЫҚ АУРУЫНЫҢ ФОКУСТІК ТҮРІНЕ ШАЛДЫҚҚАН НАУҚАСТАРҒА НЕЙРОФИЗИОЛОГИЯЛЫҚ ЖӘНЕ НЕЙРОВИЗУАЛДЫҚ ДИАГНОСТИКА ЖҮРГІЗУ АЛГОРИТМІ

Мақалада науқасты емдеу барысын сараптан өткізу және әдеби мағлұматтарды жинақтау мысалында фокустік маңдай қояншығының дәрі-дәрмекке төзімді түрлерін зерттеу және емдеу алгоритмі ұсынылған. Науқас «В.М.Савинов атындағы қояншық ауруын, ауру ұстамасы жағдайларын зерттеу және отбасылық бақылауға алу SVS Зертханасында» дәрігерлік бақылауда болған. Науқасқа бірнеше рет стандартты ЭЭГ және МРТ жүргізіліп, қояншыққа қарсы негізгі және резервті дәрі-дәрмектер тағайындалғанымен, әсері болмаған. SVS клиникасына түскен соң, ауру ұстамасы белгілеріне мұқият сараптау жүргізу, сондай-ақ, иктальдық (талмалылық, ұстамалылық) ЭЭГ тіркей отырып жүргізілген созылмалы бейнелі

ЭЭГ және қояншыққа қарсы дәрі-дәрмектердің шоғырлану деңгейін анықтау негізінде, науқаста фокустік кортикальді диплазия болу ықтималдығы байқалды. Өріс қуаты 3 Теслалық және жұқа тілікті сканер бағдарламасы бар жоғары айқындықтағы МРТ, функциональдық және спектрлік МРТ жүргізу нәтижесінде диагноз расталып, науқасқа ота жасалды.

Ұсынылған алгоритмді пайдалану дәрігерге қояншық ауруына қатысты қажетсіз және аз мәліметті зерттеулер жүргізуден аулақ болуға көмектеседі.

Өзекті ұғымдар: фокустік (парциальдық) ұстамалар, маңдай қояншығы, бейнелі ЭЭГ-бақылау, жоғары айқындықты МРТ.



SUMMARY

I.V. Bondareva, S.V. Savinov, Y.E. Akchurina, N.V. Mikhailova, J.E. Utebekov, I.Y. Sitnikov, T.N. Sinitsyna, R.A. Abedimova

JSC «National centre for Neurosurgery»

Department of Functional Diagnostics with the course of neurophysiology and rehabilitation KRMU

SVS Epilepsy study, convulsions and family monitoring laboratory named after V.M. Savinova, Almaty city, Kazakhstan

NEUROPHYSIOLOGICAL AND NEUROVISUAL DIAGNOSIS ALGORITHM OF PATIENCE WITH FOCAL FORM OF EPILEPSY

Algorithm of examination and treatment of pharmacoresistent form of focal frontal lobe epilepsy is suggested in this article on example of patient management analysis and summarizing of literature data. Patient was observed in the SVS Laboratory of epilepsy, convulsive states study and family monitoring named after V.M. Savinov. Routing Electroencephalography and Magnetic Resonance Tomography were conducted for patient many times, core and reserve antiepileptic drugs were prescribed, but there was no effect. After admission to the SVS Clinic, it was suspected that patient has focal cortical dysplasia on the basis of careful analysis of seizure semiotics, conducted long-lasting Electroencepha-

lography video with fixation of ictal Electroencephalography, determination of antiepileptic drug concentration level. Diagnosis was confirmed and patient was operated after conduction of high resolution Magnetic Resonance Tomography with 3-Tesla field capacity and thin-cut scanning program, functional and spectroscopic MRT.

Appliance of suggested algorithm may help doctors to avoid needless and less informative researches with regards to severe forms of epilepsy.


Key words: focal (fractional) seizures, frontal lobe epilepsy, video Electroencephalography - monitoring, high resolution Magnetic Resonance Tomography.

МАТЕРИАЛЫ X АЗИАТСКОГО КОНГРЕССА НЕЙРОХИРУРГОВ



10th Asian Congress of Neurological Surgeons

*"Unique Science,
Unique City
let's meet in the heart
of Eurasia"*



September 9-12, 2014

**Rixos President Hotel
Astana - Kazakhstan**

acns2014.org



OP-001[Spine and Peripheral Nerve Surgery] CRANIOVERTEBRAL REALIGNMENT: CONCEPT, DESIGN AND TECHNIQUE

Atul Goel

Seth G.S. Medical College and K.E.M Hospital

INTRODUCTION - OBJECTIVE: The authors investigated the outcome of surgical treatment of basilar invagination by an alternative surgical strategy in 'selected' cases having basilar invagination. The surgery involved direct distraction of the facets of atlas and axis after opening of the atlantoaxial joint. The procedure resulted in realignment of the entire craniocervical junction and neck. The impact of the treatment in reversal of long-standing bone-architecture and the physical characters of the neck are studied.

METHOD: Cases having Group A basilar invagination (as per our described classification) were surgically treated during the period between the years 1999 to January 2013. The patients ranged from 9 to 74 years in age.

RESULTS: Following surgery, all patients showed a range of reduction of the basilar invagination, fixed atlantoaxial dislocation and alteration in other craniocervical parameters. All patients showed symptomatic, clinical and radiological improvement. Following surgical decompression of the region, there was remarkable recovery in craniocervical alignments and increase in neck size as ascertainable on physical and radiological measurements (maximum up to 42 mm) in 85 % cases. Minimum follow-up is of 3 months and the average follow-up is of 26 months.

CONCLUSIONS: Joint distraction and firm lateral mass fixation in Group A cases can obviate the need for translaminar decompression operation. It appears that a number of physical spinal changes characteristically associated with basilar invagination like short neck, exaggerated neck lordosis, torticollis, cervical spondylotic changes and fusions are potentially reversible following surgery that offers decompression and stabilization of the craniocervical junction.

OP-002[Miscellaneous] UNIVERSAL NEUROSURGICAL CHECKLIST EXAMINER (UNCLE) IN NEUROSURGERY

Yavor Enchev, Toni Kondev, Bogomil Iliev, Toni Avramov, Plamen Trendafilov

Department of Neurosurgery, University Hospital "St. Marina", Medical University of Varna, Varna, Bulgaria

INTRODUCTION - OBJECTIVE: Several years ago, World Health Organization (WHO) proposed to the global surgical community Surgical Safety Checklist (SSC). However, SSC did not achieve the expected wide application in the heterogeneous surgical units throughout the world and in particular the neurosurgical departments. Currently, totally adapted surgical safety checklist to the neurosurgical actuality and requirements does not exist.

METHOD: In response to this natural need, the authors developed and introduced into clinical practice their own neurosurgical safety checklist- Universal Neurosurgical Check-List Examiner (UNCLE).

RESULTS: UNCLE was routinely applied for safety control at every neurosurgical procedure since its introduction in 2012 up to date. Within this term UNCLE was used in more than 600 patients and complications like wrong-patient, wrong-side, wrong-level and wrong-procedure surgeries, with potentially devastating effects for the patients, were not registered. UNCLE prolonged the preoperative period with about 10 minutes and did not require additional expenses.

CONCLUSIONS: Based on our results we could conclude that UNCLE is simple, cost-effective and trustworthy tool for reduction or even eradication of most of the preventable neurosurgical errors

OP-003[Pediatric Neurosurgery] SURGERY OF BRAINSTEM TUMOR IN CHILDREN

William Khachatryan, Aleksandr Kim, Oleg Don

Department of Pediatric Neurosurgery, Polenov Russian Neurosurgery Research Institute, St. Petersburg, Russia

INTRODUCTION - OBJECTIVE: To demonstrate the prognostic factors of brainstem tumor surgery in children on the basis of the analysis of short- and long-term results of treatment.

METHOD: 357 children with brainstem tumors under 17 years-old from 1990 to 2009. Intra-axial brainstem (focal, exophytic-brainstem) tumors were at 176, a secondary-brainstem - 181. There were predominance of astrocytomas (3/4), malignant (II-IV Hg.) tumors (2/3). It was analyzed the prognostic value of 62 signs with χ^2 .

RESULTS: Total and subtotal removal was carried out in 3/4 cases. The postoperative mortality rate was 3.2%. Appearance or growth of neurological and cognitive deficits observed in 19.5% of cases. Early recurrence (continued growth) within 3-5 years after resection of the tumor was observed in 1/3 of patients. As a result, the negative factors for the possibility of total removal of the tumor were: intra-axial brainstem localization ($p < 0,01$), diffuse growth pattern ($p < 0,02$), malignant forms ($p < 0,05$), an isolated depression of acoustic or somatosensory evoked potentials, tumor localization lower trapezoid body, under triangles IX, X, XII and locus coeruleus. For early recurrence contributing factors were: malignant forms ($p < 0,02$), metastasis ($p < 0,01$), partial removal of the tumor ($p < 0,05$).

CONCLUSIONS: Diffuse blasomatous lesion and involvement of the vital zones of the brainstem worsen the prognosis. Intraoperative mapping of the brainstem and the registration of visual, acoustic, somatosensory evoked potentials, the allocation of lesser eloquent areas allows to expand the radicalism of manipulations without increasing the traumaticity. Hystobiological nature of the tumor was the determining factor for tumor recurrence.

OP-004[Neurooncologic Surgery] EXTRACRANIAL SURGERY (TRANSNASAL AND TRANSORAL) CHORDOMAS OF THE SKULL BASE AND OF THE CRANIOVERTEBRAL JUNCTION

Alexei Nikolaevich Shkarubo, Nikolai Alexandrovich Kononov, Dmitrii Nikolaevich Andreev
Burdenko Neurosurgical Institute

INTRODUCTION - OBJECTIVE: Putting into practice the simultaneous stabilization of the rear-simultaneous OSD and extracranial (transoral and/or transnasal) removing the pathological focus.

METHOD: From 1985 to 2013 operated 360 patients with skull base chordomas. Prior to 2006, was dominated by the transcranial approach (61%), from 2007-ventral approach (75%). 216 patients were operated extracranial (102 men, 114 women, 33 children) aged 2.7 to 69 years. In 145 cases was transnasal removal (microscopic-37; endoscopic-108). In 38 cases-transoral approach. In 13-done a simultaneous transoral and transnasal approach. In 23-OSD has been installed. We used the original, patented tools, devices, methods of surgical treatment.

RESULTS: Of patients operated transnasal approach 19,5 % cases-total removal, and in 55%-subtotal, 20%-partial, in 2% cases radicalism was less than 50% and 3,5 %-biopsy. Also in the group operated on transoral approach, total removal-18,5%, subtotal-55,5%, partial-26%. Resection in 92% of patients with simultaneous transoral+transnasal surgery-subtotal and 8%-partial. Only subtotal removed in the group with OSD+transoral approach, as well as supplemented transnasal. Complications of the whole group of patients accounted for 14% of patients. Postoperative CSF leakage was 5% of cases. Postop. mortality was in one event. Regression of clinical symptoms of the disease was in most patients.

CONCLUSIONS: The experience of the skull base and craniocervical junction and the use of new technologies in surgery chordomas can improve the results of surgical treatment to reduce the invasiveness of operations, speed up rehabilitation. Implementation in practice the simultaneous OSD improves radical removal of chordomas in patients who had previously considered in fact inoperable.

OP-005[Pediatric Neurosurgery] BRAIN TUMORS IN CHILDHOOD: AN OVERVIEW

Ioan Stefan Florian¹, Attila Kiss¹, Iulian Irimescu², Zorinela Andrasoni²

¹Department of Neurosurgery, University of Medicine and Pharmacy "Iuliu Hatieganu" Cluj-Napoca, Romania

²Department of Neurosurgery, Cluj County Emergency Hospital

INTRODUCTION - OBJECTIVE: Solid brain tumors are the most common form of neoplasia in children diagnosed with cancer, with significantly higher morbidity and mortality compared to other types of cancer which occur during pediatric age.

METHOD: This is a retrospective clinical study of 225 cases of pediatric brain tumors (age: from birth to 18 years) over a period of 10 years in which we analyzed epidemiological aspects, pathological dispersions, clinical features, diagnostic evaluation, treatment and outcome of these patients. Non-tumoral lesions, cysts and vascular malformations were excluded.

RESULTS: From a total number of 225 surgical interventions 65 were relapses. Mean age: 9.36 years. Gender distribution: male predominance. The number of children under 3 years: 40; between 4 and 18: 185. In the 0-3 age group supratentorial tumors were more frequent (22 cases - 55 %) with medulloblastoma being the most common histological type (6 cases - 15 %) followed by astrocytoma grade I (5 cases - 12.5 %), astrocytoma grade II (4 cases - 10 %) and mixed gliomas (4 cases - 10 %). Overall (0-18 age group) supratentorial tumors accounted for 59.5 % with astrocytoma grade I being the most frequent (54 cases - 24 %), followed by ependymoma (24 cases - 10.6 %) and medulloblastoma (23 cases - 10.2 %). Only one case died in immediate postoperative period (0.4%)

CONCLUSIONS: Radical surgery is the most important factor influencing median of survival. The greatest difficulty in surgery of tumors at the pediatric age is to find the balance between radical resection without additional morbidity.

OP-006[Spine and Peripheral Nerve Surgery] REDUCTION OF MODERATE TO HIGH GRADE SPONDYLOLISTHESIS AFTER CIRCUMFERENTIAL RELEASING TECHNIQUE UNDER THE MINI-OPEN POSTERIOR LUMBAR INTERBODY FUSION

Hyeun Sung Kim¹, Se Jin Jeong¹, Ki Hyun Jeon¹, Woo Jin Choi¹, Kwan Tae Kim¹, Kun Soo Jang², Chang Il Ju², Seok Won Kim², Seung Myung Lee², Ho Shin²

¹Department of Neurosurgery, Hurisarang Spine Hospital, Daejeon City, south Korea

²Department of Neurosurgery, College of Medicine, Chosun University, Gwangju City, South Korea

INTRODUCTION - OBJECTIVE: The purpose of this study was to achieve the safe and easy technique for minimizing the neurologic deterioration and maximizing the reduction of spondylolisthesis using mini-open, posterior-lumbar interbody fusion under circumferential releasing technique.

METHOD: This study involved 50 cases who received mini-open PLIF with percutaneous screwing, due to more than Mayerding Grade II spondylolisthesis. All patient received mini-open, posterior-lumbar interbody fusion under epidural anesthesia using the percutaneous screw system. A circumferential releasing technique was performed according to the following sequence: 1. Intraoperative postural reduction position; 2. facet joint mobilization decompression; 3. Segmental Mobilization by wide distraction of restricted disc space; 4. Increasing sacral slope by rod compression; and 5. Increasing the anterior disc height by angled lumbar interbody fusion cage. The clinical results were evaluated by

degree of slippage reduction, degree of disc height restoration, degree of lumbar lordosis restoration, degree of segmental angle restoration, and degree of postoperative neurological complications.

RESULTS: The degree of slippage rate preoperative was 37.98% to postoperative 9.3%. The degree of disc space was preoperative 5.5mm to postoperative 12.1mm. The preoperative lumbar segmental angle preoperative was 43.0 degree to postoperative 48.2 degree and focal segmental kyphotic angle was preoperative 10.1 degree to postoperative 15.9 degree. There was no definite motor weakness after operation.

CONCLUSIONS: According to the results, we could obtain maximal reduction of spondylolisthesis under minimal neurologic deterioration in the cases of a moderate to high grade of spondylolisthesis using the circumferential segmental releasing technique.

OP-007[Spine and Peripheral Nerve Surgery]

LUMBAR CANAL STENOSIS: A REVIEW OF DIFFERENT TYPES OF LUMBAR SPINE SURGERY

Abdul Hafid Bajamal, Eko Agus Subagio, Muhammad Faris Faz

Department of Neurosurgery, Dr Sutomo General Hospital, Medical Faculty of Airlangga University, Surabaya, Indonesia

INTRODUCTION - OBJECTIVE: Symptomatic Lumbar canal stenosis with radiculopathy have several treatment options include decompression alone open or microscopic, using inter or intra spine implant or fusions. There were literature explained the benefits diminish with long-term follow –up in some trials.

METHOD: Reoperations were at least as frequent after fusion, but the authors could not assess treatment efficiency in terms of pain relief or improved function. We have to choose which surgery have the most suitable for the patient.

RESULTS: Characteristics and the clinical conditions are very important in patient selection, such as single or multilevels, disc prolapse, spondylolisthesis, overweight, osteoporotic etc.

CONCLUSIONS: This presentation will review how to choose the treatment options.

OP-008[Spine and Peripheral Nerve Surgery]

MID-TERM POSTOPERATIVE CLINICAL AND RADIOLOGICAL OUTCOMES AFTER MICRODECOMPRESSION OF DEGENERATIVE LUMBAR SPINAL STENOSIS USING TRANSSPINOUS SPLIT LAMINECTOMY TECHNIQUE (TSSLT): EXPERIENCE OF 36 CASES

Erhan Emel¹, Anas Abdallah¹, Betül Güler¹, Müslüm Güneş¹, Mustafa Levent Uysal¹, Akın Gökçedağ², Ali Ender Ofluoğlu¹, İlhan Aydın¹, Sarper Polat¹

¹Bakırköy Research and Training Hospital for Neurology Neurosurgery, and Psychiatry, Department of Neurosurgery, İstanbul, Turkey

²Kanuni Sultan Süleyman Research and Training Hospital, Department of Neurosurgery, İstanbul, Turkey

INTRODUCTION - OBJECTIVE: Microdecompression of lumbar spinal stenosis (LSS) using TSSLT approach became popularized in last years. According to classic laminectomy, TSSLT is less invasive. In this study, postoperative clinical outcomes after microdecompression of 36 LSS cases using TSSLT have been presented.

METHOD: 36 patients operated between the years 2011 and 2013, on the lumbar spine for symptomatic LSS using high-speed drills under microscope to enter the spinal canal through spinous processes then fl. vectomy, foraminotomy and laminectomy may achieved bilaterally. Clinical outcomes were evaluated retrospectively using preoperative and postoperative VAS and ODI, walking capacity and surgical complications. The mean follow-up period was 25 months. The mean age of the patients was 63.76 years. The risk of postoperative instability was evaluated on the basis of dynamic radiographs.

RESULTS: ODI showed a mean improvement in symptoms from 61% to 18.8%, and VAS showed that the intensity of leg and back pain decreased from 8.6 and 8.1 to 2.24 and 2.82 points, respectively. Walking capacity increased from 3.6 to 1.67, 91.6% of patients indicated that they were satisfied. Dynamic radiographs revealed no postoperative instability after surgery. 3 cases of those complained of motor deficits did not improve. 4 patients had been reoperated for their persistent pain and they got recovery. Dural tear was seen in 6 patients and got treated.

CONCLUSIONS: Clinical outcomes 2.5 years postoperatively in patients who undergoing TSSLT showed a favorable maintenance of improvement in symptoms. Radiologically had been showed that this approach does not alter the stability of the spine.

OP-009[Pediatric Neurosurgery]

TETHERED CORD SYNDROME IN PAKISTAN

Salman Sharif

Liaquat National Hospital & Medical college, Karachi Pakistan

INTRODUCTION - OBJECTIVE: Tethered Cord Syndrome is a common Pediatric spinal problem seen in Pakistan because of large numbers of Spinal dysraphism.

METHOD: Forty four consecutive patients treated surgically for "tethered cord syndrome" over a 3-three year period were reviewed. The main presenting complaints were back and leg pain, progressive lower limb and spinal deformity and neurological deficits. Untethering of the cord was achieved in majority of the patients, in whom the filum terminale was divided in over half of these patients.

RESULTS: The mean post-operative follow up was 15 months in which we compared the surgical outcomes of between patients with different. Out of 44 patients, 85 % had tethering at L3-S2 level, 12 % had tethering at L1-L2 level and 3 % had it at Dorsal Level. Improvement of symptoms was seen in 56 % of the patients with L3-S2 level, 50% with L1-L2 level and stabilization was seen in 39 % of tethering at L3-S2, 50% with L1-L2, and 100% in dorsal tethering. 83.3% of the patients who had thickened filum showed improvement, while 63 %, 57 %, 44. % of the patients with diastematomyelia, lipoma meningocele showed improvement respectively. It was also noted that the patients who presented with paraparesis, two third had improved post-operatively, while 25% remained static. On the other hand the patients who presented with paraplegia, only one third showed improvement while 67% remained static.

CONCLUSIONS: Our series suggests that cord release in patients with "tethered cord syndrome" improves or arrests the progression of neurological deterioration.

OP-010[Spine and Peripheral Nerve Surgery]

THE SURGICAL TREATMENT OF POSTOPERATIVE SPONDILOLISTESIS IN LUMBAR DIVISION

Sokhib Saidov Saidmurodovich, Djumanov Komoliddin Nuriddinovich, Yuldashev Ravshan Muslimovich, Mirzabaev Marat Djumabekovich

Republican Scientific Center of Neurosurgery, Tashkent, Uzbekistan

INTRODUCTION - OBJECTIVE: The purpose of the given research is development of differentiated surgical treatment of postoperative spondilolistesis.

METHOD: Work is based on analysing results of examinations and surgical treatment of 32 patients with postoperative spondilolistesis. Women were - 20, men - 12. All patients passed the clinic-neurological, rentgenologic and MRI examination. Spondilolistesis of the I degree is diagnosed among 17 patients, II degree among 8, III degree among 4 sick people, IV degree among 2 patients and V degree among 1 patient. Herewith spondilolistesis VL3 was revealed in 4 events, VL4 in 12, VL5 was also revealed among 14 patients and the two levels of spondilolistesis were noted among 2 patients.

Monoradical syndrome is revealed among 11 patients, biradicular among 15 and polyradicular among 6 patients.

All patients were made an operative treatment. Decompressive laminotomy with the interbody spondilodosis cage was made among 4 patients, decompressive laminotomy with transpedicular fixation was made among 8 patients, decompressive laminotomy with transpedicular fixation and spondilodosis of outbone was made among 12 patients, decompressive laminectomy with transpedicular fixation and interbody spondilodosis cage was made among 6 sickmen. 2 patients with a high degree of spondilolistesis for the first time were made unusual operation of decompressive laminotomy with transpedicular-transcorporeal fixation.

RESULTS: The surgical treatment were characterized by following: good results were reached among 25 patients, satisfactory among 6 and nonsatisfactory among 1.

CONCLUSIONS: Wide decompression of contain formations of vertebral canal with interbody stabilized cage and/or reliable transpedicular fixation are methods of choice of the surgical treatment of postoperative spondilolistesis.

OP-011[Spine and Peripheral Nerve Surgery]

EFFECTS OF QUERCETIN IN THE ACUTE PHASE OF AN EXPERIMENTAL SPINAL CORD TRAUMA

Emre Hasan Aydın¹, Mesut Emre Yaman², Salim Senturk³, Zuhtu Ozbek⁴

¹Eskisehir State Hospital, Department of Neurosurgery, Eskisehir, Turkey

²Yenimahalle State Hospital,, Department of Neurosurgery, Ankara, Turkey

³Hitit University, Corum Hospital,, Department of Neurosurgery, Corum, Turkey

⁴Osmangazi University, Medical Faculty, Department of Neurosurgery, Eskisehir, Turkey

INTRODUCTION - OBJECTIVE: We have shown acute effects of the fl. vonoid quercetin significantly contributed to recovery of motor function after experimental spinalcord trauma. The present study was designed to investigate the antiapoptotic effects of quercetin in the early phase of spinal cord trauma.

METHOD: In this study, we divide the rats into four groups. In order to induce mid-thoracic spinal cord compression injury, a standard aneurysm clipping method (50 g calibrated aneurysm clip for 5 s) was used. Injured animals were given either 20 mg/kg quercetin intraperitoneally after trauma. Blood samples were taken in all groups two times, before and after trauma. We compare the effects of quercetin and the methylprednisolone by the using the Annexin V which is the early indicator of apoptosis and p53 with the ELISA procedure.

RESULTS: Statically, in quercetin and methylprednisolone treated animals, Annexin V levels was significantly decreased in serum after injury, compared with saline group.

CONCLUSIONS: We suggest that in the early phase of spinal cord trauma serum Annexin V levels show the degree of apoptosis in the trauma region. We may use this as an prognostic indicator of the trauma in the early phase. On the other hand, the quercetin might have a neuroprotective effect by preventing the apoptosis but we need additional advanced researches.

OP-012[Neurooncologic Surgery]

SURGERY FOR TRIGEMINAL SCHWANNOMA: IMPORTANCE OF UNDERSTANDING THE SURGICAL ANATOMY

Suresh Nair Narayanan Nair

Sree Chitra Tirunal Institute for Medical Sciences, Trivandrum, India

INTRODUCTION - OBJECTIVE: A retrospective analysis of 75 consecutive patients (36 males and 39 females) with trigeminal schwannoma surgically managed from January 1984 to June 2013 is carried out to determine the ideal surgical approach based on surgical anatomy

METHOD: While 36 tumours were located in a single compartment (Meckel's cave or interdural space of the middle cranial fossa (MF) in 24, and the subarachnoid space in the posterior fossa (PF) in 12), 34 were dumbbell-shaped (PF-MF in 29, MF-extracranial in 5). In one case, the tumour was totally extracranial and in four others it occupied all 3 compartments. All 8 patients managed until 1992 were operated on by conventional approaches. With the exception of the 12 patients with posterior fossa tumors and nine with dumbbell PF-MF tumors which were treated by the retromastoid route and three with MF tumor treated by the standard subtemporal approach, all other 43 cases managed since 1993 were operated on by the skull base approaches (frontotemporal craniotomy with or without zygomatic osteotomy (FTZ) and extra-interdural removal in 29, FTZ and intradural removal in 9, temporal craniotomy (TC) and extradural approach in one, combined posterior subtemporal-presigmoid/transigmoid in 3 and extradural total petrosectomy approach in one.

RESULTS: Tumour could be radically removed in 67 patients and decompressed in eight. The only operative mortality was in a patient with residual/recurrent tumour operated previously twice who died from meningitis. Five patients were operated for symptomatic recurrences.

CONCLUSIONS: Most multi-compartmental trigeminal schwannomas can be radically removed using a single-stage fronto-temporal interdural skull base approach

OP-013[Neurooncologic Surgery]

SURGICAL MANAGEMENT OF INTRAVENTRICULAR MENINGIOMA; 20 YEARS EXPERIENCE

Ali Ayyad, Firas Hammadi, Martin Glaser, Alf Giese

Department of neurosurgery, Johannes Gutenberg university

INTRODUCTION - OBJECTIVE: Intraventricular meningioma is a rare tumor, about only 2% of intracranial meningiomas in adults and about 10% in children.

Located mostly in trigone of the lateral ventricle with left Side preponderance 60%.

There is many surgical approaches for management of these tumors including: transcassal parietooccipital, transcortical superior parietal, transcortical middle temporal and transcortical inferior temporal approaches.

METHOD: In the period between 1991 and 2011 we operated 39 patients with intraventricular meningioma 24 females, 15 males. Age ranged from 9 to 76 years. Size ranged from 2.5 to 7 cm, 34 located in lateral ventricle, 3 in III ventricle and 2 in IV ventricle. Most patients presented with headache followed by signs of increased ICP, visual defects and hemiparesis. **RESULTS:** Total excision 97% No recurrence

No mortality

Karnosky score worse postoperatively in 2 patients

Improvement of preop. Symptoms occur in 80%

In 15% of patients there was no improvement.

CONCLUSIONS: Surgery is the best management when indicated.

Judicious preoperative plan, adequate knowledge of anatomy, and use of correct microsurgical techniques are fundamental in achieving complete resection with low morbidity

OP-014[Neurooncologic Surgery]

THE MANAGEMENT OF INTRINSIC GLIOMAS DURING PREGNANCY

Ekkehard Matthias Kasper¹, Erick Tarula¹, Lisa Barroiet¹, Anand Mahadevan¹, Rui Liu²

¹Division of Neurosurgery; Beth Israel Deaconess Medical Center; Department of Neurosurgery, Harvard Medical School, Boston (MA), USA

²6th Navy General Hospital, Beijing, China

INTRODUCTION - OBJECTIVE: Glial CNS tumors during pregnancy are very rare at about 3.6 per million live births. Evidence based recommendations regarding best management are largely anecdotal. Here we present five gliomas managed during pregnancy and analyze previously published results for pooled analysis.

METHOD: We reviewed 5 cases of gliomas managed during pregnancy. We also reviewed published data in MEDLINE from January through March 2013 with subject headings "pregnancy", "glioma", "brain neoplasm".

RESULTS: 20 reports appeared between 1990 and 2013 and with our 5 cases a total of 61 gliomas in pregnancy was identified. The median maternal age at the time of diagnosis was 29 years. In 16 cases a tumor was identified before pregnancy. In 5 cases the diagnosis was made postpartum. Remaining cases were identified during pregnancy with a mean fetal age of 26 weeks. Presenting signs and symptoms were headache, nausea, vomiting, seizures and focal deficits and seizures. 8 patients had stable disease while 17 others reported tumor progression. In 8 cases chemotherapy was used during pregnancy. Five fetuses were exposed to temozolomide and 3 were exposed to PCV with fetal outcome reported as

normal. In 5 cases radiation was used during pregnancy with infant outcome labeled as healthy in 4. Maternal outcome varied greatly across reported cases.

CONCLUSIONS: There are no prospective studies of maternal outcomes or fetal wellbeing during pregnancy. Some studies suggested no obvious difference in neurological outcomes, although there was an increase likelihood of Cesarean section. The optimal clinical management is discussed and should be individualized.

OP-015[Neurooncologic Surgery]

COMBINED ENDOSCOPIC-MICROSCOPIC SURGERY FOR BULKY TUMORS IN ANTERIOR SKULL BASE

Yugo Kishida, Taku Sato, Jun Sakuma, Kiyoshi Saito

Department of Neurosurgery, Fukushima Medical University, Fukushima, Japan

INTRODUCTION - OBJECTIVE: Combined surgery of endonasal endoscopic approach with transcranial microscopic approach increases the possibility of radical resection of widely-extended anterior skull base tumors. On the other hand, it has several issues such as troublesome setup, restricted head position, wide dural defect, and so on. We will introduce our practical techniques of combined endoscopic-microscopic surgery and skull base reconstruction.

METHOD: 6 combined endoscopic-microscopic surgeries except endoscope-assisted microscopic surgeries were performed for 5 patients (3 chordoma, 1 chondrosarcoma, and 1 prolactinoma with CSF rhinorrhea) between Jan 2010 and Dec 2013. Typically, posterolaterally-invaded parts of the tumors beyond the internal carotid artery were resected via transcranial route, and inferomedial part of clivus and contralaterally-extended lesions were resected by endonasal endoscopic approach. Wide skull base defect were closed by novel techniques using galeal flap.

RESULTS: Combined surgery using different surgical routes helped to identify the important structures, residual tumors and exact location of each surgical field. Gross total removal of the tumors were achieved in all cases except prolactinoma, whereas 2 severe complications were observed (1 brain stem infarction and 1 infectious complication). Reconstruction technique using galeal flap as helpful for covering of large dural defect.

CONCLUSIONS: Combined surgery is useful for safe procedures, more aggressive resection of the tumors, and orientation in the complicated skull base region, since endonasal endoscopic approach and transcranial microscopic approach complement each other's blind corners beyond the reachable area.

OP-016[Neurooncologic Surgery]

ELECTROMAGNETIC NEURONAVIGATION FOR INTRACRANIAL ENDOSCOPIC OPERATIONS

Frank Hertel, Ardian Hana, Nitish Gunness, Christophe Berthold

National department of Neurosurgery, Centre Hospitalier Luxembourg, Luxembourg

INTRODUCTION - OBJECTIVE: Neuronavigation has become a standard technology in cranial surgery. Whereas optical navigation (ON) is of well known, the electromagnetic navigation (EMN) has not been used that often.

Especially for endoscopic neurosurgery in the ventricles, but also for skull base procedures, EMN bears some advantages.

METHOD: Advantages of EMN are: Real time tip navigation, availability in narrow spaces, usability in the endoscopic trocar.

Furthermore, no rigid fixation is necessary for EMN.

We report about our experience in 38 cases with EMN.

RESULTS: In 6 cases, it was used for ventricular endoscopy, especially in child; in 32 cases, we used EMN for the navigation of endoscopic skull base procedures, such as pituitary adenomas, meningiomas and petrous bone cholesteatomas.

CONCLUSIONS: Neuronavigation has become a standard technology in cranial surgery. Whereas optical navigation (ON) is of well known, the electromagnetic navigation (EMN) has not been used that often. Especially for endoscopic neurosurgery in the ventricles, but also for skull base procedures, EMN bears some advantages.

Those are: Real time tip navigation, availability in narrow spaces, usability in the endoscopic trocar.

We will describe pros and cons of this technique, show cases and intraoperative video sequences.

OP-017[Neurooncologic Surgery]

TO STUDY THE FACTORS CAUSING DIFFERENCE OF OPINION IN DIAGNOSING BRAIN TUMORS BY RADIOLOGIST, NEUROSURGEON WITH RESPECT TO FINAL HISTOPATHOLOGY

Fahmida Arab Mallah

Department of Neurosurgery, Pakistan Institute of Medical Sciences Islamabad

INTRODUCTION - OBJECTIVE: Brain tumors are a diverse group of neoplasms arising from different cells, numerous imaging diagnosing modalities are used but CT scan and MRI are most important with accuracy 69-90%, still diversity among radiologist and neurosurgeon's diagnosis. We have compared both radiologist and neurosurgeons' opinion on the basis of CT scan and MRI, keeping histopathology as a final, also any factor that affects the difference of opinion among them and thought to suggest the ways and means to reduce the discrepancy.

objective; to study the opinion of a radiologist as compared to that of a neurosurgeon with respect to final histopathology and find reason for any discrepancy.

METHOD: This descriptive study we enrolled total of 100 cases of brain tumors in a period of one year. All patients suspected of brain tumors on radiology and planned for surgery of both sex who were willing for surgery were included and those above 70 years, unfit for anesthesia and having recurrent tumors were excluded.

RESULTS: Total 100 cases were enrolled with mean age of 3.8 ± 12.7 years ranging from 13-65 years with male and female ratio 1.5:1, out of 100 cases 27 were HGG, 18 LOW grade glioma, meningioma 12, CP < acoustic 6, METS and pituitary 5 cases.

CONCLUSIONS: As per study findings neurosurgeons are more likely to pick the type and site of brain tumors with great accuracy as compared to radiologist, radiologist accuracy can be enhanced if clinicopathological details, medical record will accompany, and availability of modern technology and communication within radiologist, neurosurgeon and histopathologist.

OP-018[Neurooncologic Surgery]

HYPOXIA, GLIOMAS AND HYPERBARIC OXYGEN THERAPY

Tolga Turan Dunder¹, Mehmet Hakan Seyithanoglu², Sefika Korpınar³, Sevet Evran², Serdar Cevik², Mehmet Yigit³, Raziye Atar⁴¹Department of Neurosurgery, The Association of Mus Public Hospital, Mus, Turkey²Department of Neurosurgery, Bezmialem Foundation University, Istanbul, Turkey³Department of Hyperbaric Oxygen Therapy, Istanbul University, Istanbul, Turkey⁴Department of Physiotherapy and Rehabilitation, Cardiology Institute, Istanbul University, Istanbul, Turkey⁵Department of Emergency Medicine, Bezmialem Foundation University, Istanbul, Turkey

INTRODUCTION - OBJECTIVE: Gliomas are the most common brain tumor in adults. Tumor related endothelial cells are of neoplastic nature and have malignant properties such as proliferation and invasion. Therefore, anti-angiogenic approaches have several advantages when compared to conventional chemotherapeutic approaches. The target of anti-angiogenic treatment to ensure a decrease in systemic side effects since there are endothelial cells and other supportive cells belonging to the vessel walls. The purpose of this study was to increase the oxygenation of the environment with HBOT and to prevent the angiogenesis effect of the factors being secreted by hypoxia. We also tried to prevent angiogenesis by using Sorafenib, which is the chemotherapeutic agent blocking the receptors of these factors. Also, this study compared the effect of these both and to put into for their effect. In this regard, the tumor size, vascularization rate, midline, apoptosis and angiogenesis related transcription nuclear factor kappa B (NF- κ B), HIF-1 α levels have been compared in the relevant groups.

METHOD: The study was planned as 4 main groups. 10 rats were included in each group.

G1- Control Group.

G2- Group Given HBOT

G3- Group Given SORAFENIB

G4- Group Given HBOT & Sorafenib

After two weeks the rats have been sacrificed. Hematoxylin- Eosin staining, ELISA, Western Blotting methods used.

RESULTS: HBOT increases the serum MK levels and that the SOR increased the MK levels. NF- κ B, HIF-1 α levels were reduced with HBOT and SOR was increased. **CONCLUSIONS:** There is a need for much more studies in relation to the correct time of application of HBO therapy.

OP-019[Neurooncologic Surgery]

CCR7 MEDIATED MIGRATION ACTIVITY OF MONOCYTE-DERIVED DENDRITIC CELLS IN HEALTHY INDIVIDUALS AND MALIGNANT GLIOMA PATIENTS

Sergey Mishinov¹, Vjacheslav Stupak¹, Tamara Tyrinova², Olga Leplina², Alexander Ostanin², Elena Chernykh²¹Institute of Traumatology and Orthopedics²Institute of Clinical Immunology SB RAMS

INTRODUCTION - OBJECTIVE: Presented in non-lymphoid tissues and organs immature dendritic cells (DCs) have a high capacity to capture antigens and low migration activity to draining lymph nodes. Inflammatory mediators and pathogens induce maturation of DCs which is accompanied by expression

chemokine receptor CCR7 and effective DC migration to the lymph nodes.

METHOD: The aim of the present study was to evaluate CCR7-mediated migratory activity of healthy donor dendritic cells generated ex-vivo from peripheral blood monocytes in the replacement of IL-4 by IFN- α and to analyze migratory activity of IFN-DCs in patients with brain tumors. The study included 11 healthy donors and 8 patients with high grade gliomas (HGG): anaplastic astrocytoma (n=2) and glioblastoma (n=6). Chemotaxis of DCs was measured by migration through a polycarbonate filter with 8- μ m pore size in 24-well transwell chambers.

RESULTS: Healthy donors showed that the migration index of IFN-DCs in cultures with CCL19 was twice higher than IL4-DC (4.3 ± 1.1 vs 1.6 ± 0.3 respectively; $pU = 0.018$). Moreover IFN-DCs were characterized by more pronounced migration towards CCL21 ($pU = 0.2$). Comparative analyses of IFN-DC migration activity in response of CCL19 between HGG patients and healthy donors showed 2.5 times lower level of migration in case of brain tumors ($pU = 0.045$). IFN-DC migration activity of HGG patients in response of CCL21 showed two times lower level in comparison with healthy volunteers.

CONCLUSIONS: Our data suggest that IFN-DC high grade glioma patients, despite maintained expression of the receptor CCR7, characterized by reduced migration activity in response of CCL19 and CCL21 ligands.

OP-020[Neurovascular Surgery]

APPLICATION OF STENT-ASSISTED COIL EMBOLIZATION FOR INTRACRANIAL ANEURYSMS

Qing Zhu, Ailin Chen, Yanming Chen, Chao Sun, Qing Lan

Department of Neurosurgery, Second Affiliated Hospital of Soochow University, Suzhou, China

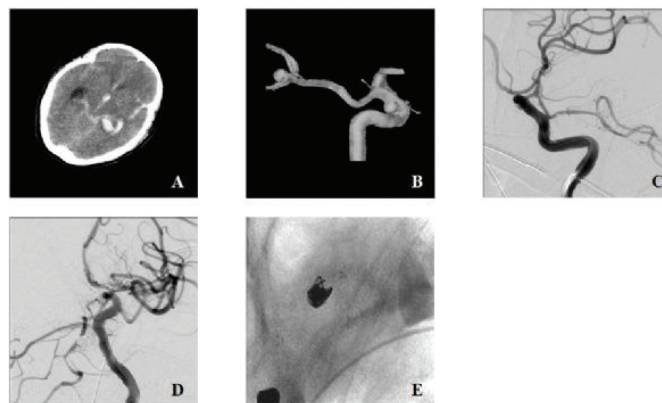
INTRODUCTION - OBJECTIVE: To evaluate the application of stent-assisted coil embolization for intracranial aneurysms.

METHOD: Clinical data of 20 patients with 22 intracranial aneurysms were analyzed retrospectively. Embolotherapy with stent-assisted Guglielmi detachable coiling was performed in all the patients, and the technique of stent-assisted included releasing before coiling in 7 patients, releasing after coiling in 8 and semi-releasing in 5.

RESULTS: All the stents were once implanted in place, and the success rate was 100%. Complete embolization was achieved in 16 aneurysms and partial embolization in 6. Acute in-stent thrombosis occurred in 1 case during operation and cured by arterial thrombolysis. CTA or MRA reexaminations were performed in 16 patients 3 months after the operation, and no aneurysm recurred. DSA reexamination was performed in 12 patients 6 months after the operation, and no aneurysm recurred in 9 aneurysms with complete embolization and the residual aneurysm neck disappeared in 3 aneurysms with partial packing.

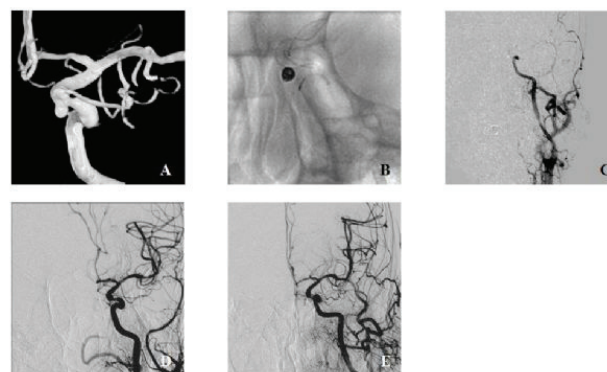
CONCLUSIONS: Stent-assisted coil embolization can improve the embolization density of aneurysmal cavities, and play a guiding role for blood flow, thus enhancing the therapeutic efficacy.

Picture 1. Case 14.



A.B.: Head CT and three dimension DSA before coiling. C.D.: Two aneurysms were coiled densely assisted with stents. E: The outline of parent artery was well described by the edge of coils.

Picture 2. Case 4.



A: Head three dimension DSA before operation. B: Aneurysm was coiled with stent. C: Acute in-stent thrombosis occurred during procedure. D: Recanalization was achieved after infusion of urokinase via microcatheter. E: Follow up in six months.

OP-021[Pediatric Neurosurgery]

INITIAL EXPERIENCE IN THE INDIRECT REVASCLARIZATION FOR MOYAMOYA DISEASE IN CHINESE CHILDREN

Wen Jun Shen¹, Bin Xu², Yuxiang Gu², Wei Shi¹, Rui Zhao¹, Hao Li¹

¹Department of Pediatric Neurosurgery, Children's Hospital of Fudan University, Shanghai, China

²Department of Neurosurgery, Huashan Hospital of Fudan University, Shanghai, China

INTRODUCTION - OBJECTIVE: As the incidence of moyamoya disease (MMD) in children is growing in China, our study aimed to evaluate the role of indirect revascularization in treating MMD. **METHOD:** 55 MMD children confirmed by DSA or MRA in our center were admitted in our center. The clinical manifestation was described as below: 4 with Cerebral hemorrhage history, 11 with transient Ischemic attack (TIA), 13 with frequent TIA, 21 with cerebral infarction history and 6 with both TIA and infarction. Among these patients, 30 ones were bilateral involved. We have done 85 encephalodurovascular anastomosis (EDMS) procedures for affected sides. **RESULTS:** There were 22 post-operative complications during 85 hospitalizations, while 13 aphasia occurred. The mean period of follow-up after surgery was 17.55 months, with a range of 6-45 months. Pre-existed neurological deficits relieved after 64 operations, while 6 operations resulted in aggravate symptoms post-operatively, and 15 operations stabilized perioperatively. **CONCLUSIONS:** EDMS is a safe, effective and simple treatment for MMD children, more efforts should be made on perioperative management to reduce complications.

OP-022[Pediatric Neurosurgery]

EXPERIENCE ON 143 CASES OF PEDIATRIC TETHERED CORD SYNDROME IN A SINGLE INSTITUTION

Selami Çağatay Önal¹, Yener Akyuva¹, Tuncay Ateş¹, Gökhan Reşitoğlu¹, Özcan Tarım¹, Ali Alper Takmaz¹, Celal Özbek Çakır¹, Ender Gedik²

¹Inonu University School of Medicine Department of Neurosurgery Malatya TURKEY

²Inonu University School of Medicine Department of Anesthesiology Malatya TURKEY

INTRODUCTION - OBJECTIVE: Tethered cord syndrome (TCS) is a disease with neurocutaneous, neuroorthopaedic, neurourologic, and pure neurologic manifestations. Timely surgical therapy is especially important in pediatric population whereas the growth spurt may cause many disabling processes including scoliosis, sphincter incontinence, and gait disturbances. Primary TCS (due to occult spinal dysraphism) includes lipomyelomeningocele, split cord malformation, thick-tight / fatty filum terminale, dermal sinus, and neurenteric cyst. Secondary TCS (due to apert spinal dysraphism) involves the cases with repaired meningocele/myelomeningocele and arachnoid adhesions related to trauma or infection.

METHOD: This presentation involves 143 consecutive pediatric tethered cord cases operated within the period January 2006 till May 2014 in Inonu University Turgut Özal Medical Center Department of Neurosurgery.

RESULTS: Relying on our experience it can be concluded that due to effective and timely surgery in TCS, preoperative pain is usually relieved, progression in scoliosis is controlled, fixed motor function loss and neurogenic bladder signs are rarely improved, gait disturbances related to slight motor loss are partially recovered. Due to diverse range and different morphological characteristics of anomalies that cause TCS and difficulty of sustaining objective criteria for neurological deficits of pediatric patients, the comparison and evaluation of results are difficult. In the pediatric age group - whether TCS is symptomatic or not - it is very likely to show clinical signs till adolescence.

CONCLUSIONS: It is strongly advised to operate on those patients as early as possible with adequate radiological and laboratory work-up. Lipomyelomeningoceles and intradural lipomas with intact neurological findings may be exceptions for early surgery.

OP-023[Pediatric Neurosurgery]

RELATIONSHIP BETWEEN LEVELS OF PROTEIN S100β IN CEREBROSPINAL FLUID WITH COGNITIVE AND PSYCHOMOTOR DEVELOPMENT OF CHILDREN'S CONGENITAL HYDROCEPHALUS BEFORE AND AFTER INSTALLATION OF INTERNAL SHUNT

Zainy Hamzah¹, Muhammad Arifin Parenrengi

Departement of Neurosurgery, Airlangga University, Surabaya, Indonesia

INTRODUCTION - OBJECTIVE: S100β is a cytosolic protein found predominantly in glia cells. The presence of this protein in the blood indicate malfunctioning or damage and blood-brain barrier.

METHOD: The type of research is longitudinal studies. The samples used were children <= 2 years of age who had been diagnosed clinically and radiologically hydrocephalus.

RESULTS: This study found that there is an inverse relationship between levels of S100β protein with psychomotor and cognitive developmental levels with increased ability discussion after the results of the analysis demonstrated the relationship was tested using Pearson's correlation where a significant association at (p = 0.021) with r = -0.240

CONCLUSIONS: There is an inverse relationship S100β protein levels at the time of insertion of internal shunt with psychomotor development and cognitive level

OP-024[Pediatric Neurosurgery]

WOUND CARE IN CHILDREN OPERATED FOR TETHERED CORD SYNDROME, A CLINICAL TRIAL

Farideh Nejat¹, Shima Shahjouei¹, Sara Hanaei

Tehran University of Medical Sciences

INTRODUCTION - OBJECTIVE: patients undergoing lumbosacral spine surgery could face post-operative complications including CSF collection, CSF leak, wound dehiscence or infection which could prolong hospitalization and impose additional costs and suffering on patients. Therefore, our trial attempts to investigate the effect of post-operative acetazolamide administration and/or prone positioning on reducing proposed complications. **METHOD:** Patients were placed in one of 4 intervention groups based on 6-random blocks. Our intervention groups include acetazolamide administration (group 1), prone positioning (group 2), both acetazolamide administration and prone positioning (group 3) and no intervention (group 4). Patients underwent intervention and observation of complications for 10 days. Other post-op conditions were the same for all patients.

RESULTS: Our ongoing results have indicated complication prevalence of 17.6%, 11.6%, 5.9% and 29.4% in groups 1-4 respectively. Detailed complication rates included CSF leak in 5.9% (1/17 patient) of group 1 and 23.5% (4/17 patients) of group 4, CSF collection in 17.6% (3/17 patients) of group 1, 5.9% (1/17 patient) of group 2 and 23.5% (4/17 patients) of group 4, wound dehiscence in 5.9% (1/17 patient) of group 3 and infection in 11.8% (2/17 patients) of group 2. The result has been significant for CSF leak among intervention groups. It should be noted that the rates and significance of complications could change in our ongoing trial as the sample size hasn't been completed yet.

CONCLUSIONS: Up to now, our result has indicated lower complication rates in post-operative acetazolamide administration and prone positioning. Moreover, prone positioning has been more effective than acetazolamide administration in reducing complications.

OP-025[Spine and Peripheral Nerve Surgery]

JOINT MANIPULATIONS AND ARTHRODESIS FOR STABILIZATION OF THE SPINE

Atul Goel¹, Atul Goel²

¹Seth G.S. Medical College and K.E.M Hospital, Mumbai, India

²Lilavati Hospital and Research Center, Mumbai, India

INTRODUCTION - OBJECTIVE: The author will present his philosophy on the manipulation of articular facet joint in the management of a number of complex anomalies of craniovertebral junction and rest of spine. An alternative strategy of treatment of degenerative spine will be presented.

METHOD: The experience is with over 800 cases of C1-2 fixation and with approximately 100 cases of cervical and lumbar spine where facet distraction and fixation of the spinal segment was done. Wide removal of the articular cartilage, stuffing of bone graft with or without a metal spacer provides a wide ground for bone fusion and for stabilization. Facet distraction was done using specially designed 'Goel' facet spacers.

RESULTS: Attempts at fixation of the joint, manipulation and distraction of the facets can result in restoration of the alignment of the craniovertebral junction and clinical recovery. Facet distraction of the subaxial spine (cervical, thoracic, lumbar) provide remarkable stability to the spinal segment, restores the intervertebral and spinal canal dimensions and results in immediate clinical recovery. The procedure ultimately results in arthrodesis of the spinal segment. No manipulation or resection of any part of the disc, ligament or bone is required.

CONCLUSIONS: Reduction of the joint cavity space, listhesis of the facets, arthritis of the cartilage, and destruction of the facets are the primary causes of a wide range of pathological entities that involve the craniovertebral junction and the spine. Facet treatment is effective and relevant.

OP-026[Spine and Peripheral Nerve Surgery]

INTERLAMINAR FENESTRATION APPROACH FOR MANAGEMENT OF SPINAL MENINGIOMAS

Ali Ayyad¹, Firas Hammadi¹, Alf Giese

Department of neurosurgery, Johannes Gutenberg university

INTRODUCTION - OBJECTIVE: Spinal meningiomas represent 25 to 46% of tumors of the spine. Typically located in the intradural extramedullary space. They most frequently occur in the thoracic region in middle-aged women. Patients typically present with pain, sensory loss, weakness, and sphincter disturbances.

There is many approaches to deal with these tumors, one of the approaches is the interlaminar fenestration with preservation of the Laminae, pedicles and spinous processes which account of preservation of spinal stability.

We present in this presentation our experience over 15 years using the interlaminar fenestration for excision of spinal meningiomas

METHOD: From 1995 till 2010 we operated 135 patients with spinal meningiomas, 97 females and 48 males, age ranged between 29 and 76 years. 70 located in thoracic, 37 in cervical and 25 in lumbar area. Presenting symptoms: 80% pain, 70% weakness, 75% sensory disturbances, and 40% sphincter dysfunction

RESULTS: 96% total excision. Recurrence in 5.2%. Complications as following: CSF leak 3%, wound infection 2% neurological deterioration 1.5%. 87 % improvement of preoperative deficits, 13% were stable, and 2% get worse.

CONCLUSIONS: Surgery is the preferred treatment in cases of spinal meningiomas because of its associated excellent functional improvement and low recurrence rate. Interlaminar fenestration give almost equal surgical exposure in comparison with laminectomy or hemilaminectomy with less approach related complication specially instability. Radiotherapy should be considered for the exceptional case involving recurrent and symptomatic spinal meningiomas

OP-027[Spine and Peripheral Nerve Surgery]

LONG-TERM SURGICAL TREATMENT OUTCOMES OF SPINAL SCHWANNOMA: EXPERIENCE OF 41 CASES

Erhan Emel¹, Anas Abdallah¹, Özden Erhan Sofuoğlu¹, Ali Ender Ofloğlu¹, Betül Güler¹, Akın Gökçedağ², İlhan Aydın¹, Rashid Ayyasov¹

¹Bakırköy Research and Training Hospital for Neurology Neurosurgery, and Psychiatry, Department of Neurosurgery, Istanbul, Turkey

²Kanuni Sultan Süleyman Research and Training Hospital, Department of Neurosurgery, Istanbul, Turkey

INTRODUCTION - OBJECTIVE: Spinal schwannomas are well-known benign spinal cord tumors that account for about 24% of intradural spinal cord tumors in adults. The total excision of the lesion, which is the generally reachable goal of surgery, allows for good results. In this study long-term surgical treatment outcomes of our 41 cases of spinal schwannomas have been evaluated.

METHOD: Medical records were retrospectively reviewed in 328 cases of spinal tumors who operated between the years 2006 and 2013. The 41 cases of schwannoma in 39(22women, 17men) patients which confirmed pathologically were obtained in this study. The mean age was 47.22 years. The mean follow-up period was 53 months. The clinical outcomes were evaluated using complaints, localizations, recurrence rate and complications. All patients underwent a laminectomy or laminotomy before neurosurgical tumor removal. Intraoperative neurophysiological monitoring were performed.

RESULTS: 9(I:5,E:4) cases were sited in cervical, 8(I:5,E:3) in thoracic, 21(I:18,E:3) in lumbar, and 3(I:0,E:3) in sacral. Twenty-seven cases were intradural-extramedullary, 13 cases were extradural, and one case was extra-intradural. Two cases (4.8%) showed recurrence in the same patient. In 3 patients intraoperative instability was seen, posterior instrumentation was performed in 2 patients. 5 cases of those complained of neurological deficits had not improved completely. Gross-total resection was achieved in thirty-five patients, subtotal resection in five patients, and one patient underwent biopsy. Surgical site infection was seen in three patients.

CONCLUSIONS: Spinal schwannoma is mostly benign and intradural-extramedullary tumor. Schwannoma is account for 12.6% of our series of spinal tumors. To avoid serious complications, we recommend intraoperative neurophysiological monitoring and laminoplasty.

OP-028[Spine and Peripheral Nerve Surgery]

A SINGLE STAGE POSTERIOR APPROACH WITH OPEN REDUCTION AND PEDICLE SCREW FIXATION IN SUBAXIAL CERVICAL FACET DISLOCATIONS

Jin Hoon Park¹, Sung Gun Lee¹, Sang Youl Lee¹, Moon Young Choi¹, Seung Chul Rhim²

¹Department of Neurological Surgery, Gangneung Asan Hospital, University of Ulsan College of Medicine, Gangneung, Korea

²Department of Neurological Surgery, Asan Medical Center, University of Ulsan College of Medicine, Seoul, Korea

INTRODUCTION - OBJECTIVE: The optimal treatment for cervical facet dislocations is controversial but the generally accepted process recommends initial closed reduction with the next step determined according to the success of the closed reduction and the presence of traumatic disc herniation.

OBJECTIVE: To show efficacy of posterior approach with open reduction and pedicle screw fixation with removal of disc particles if required, in the management of subaxial cervical dislocations.

METHOD: From March 2012 to September 2013, 21 consecutive patients with cervical facet dislocations were enrolled. The affected levels were: four C3-4, two C4-5, five C5-6, and ten at the C6-7 level. Seven patients had traumatic disc herniations. Closed reduction was not attempted, a prompt posterior cervical surgery was performed instead. After open reduction, pedicle screw fixation was performed. In cases with traumatic disc herniation, herniated disc fragments were excised by a posterolateral approach and successful decompressions were determined by postoperative magnetic resonance imaging (MRI). Clinical outcomes were assessed using the Frankel grading system. Radiological outcomes were assessed by comparing the degree of subluxation and the angle of segmental lordosis between pre- and postoperative computed tomography.

RESULTS: All patients improved neurologically. Mean segmental angles improved from $7.3 \pm 8.6^\circ$ to $-5.9 \pm 4.85^\circ$. Mean subluxation improved from $23.4 \pm 16.52\%$ to $2.6 \pm 7.19\%$. Disc fragments were successfully removed from the seven patients with herniated discs, as shown by MRI.

CONCLUSIONS: Open reduction followed by pedicle screw fixation or posterolateral removal of herniated disc fragments is a good treatment option for cervical facet dislocations.

OP-029[Spine and Peripheral Nerve Surgery]

MANAGEMENT OF OSTEOPOROTIC CERVICAL SPINE

Abdul Karim Msaddi, Sebouh Kassis, Loay Abukwedat, Catalin Majer, Walid Othman
Neurosurgical and Spinal Department, Neuro Spinal Hospital

INTRODUCTION - OBJECTIVE: Demonstrate the technical steps and efficiency of cement augmentation in osteoporotic cervical spine instrumentation

METHOD: 15 patients, osteoporotic, were operated over 6 years period for cervical spondylosis, they were all having significant osteoporosis, 6 of them had corpectomy with expandable cage and plating. In the remaining patients: 3 patients had cage fusion with plate, cage with TDR in 2 patients and all the rest received standalone cages only. All these patients had open vertebroplasty augmenting the vertebral bodies adjacent to the cages, artificial disc or expandable cage.

RESULTS: No post-operative complications in term of cement leak or per operative or adjacent fractures or screw loosening or others.

CONCLUSIONS: Cement augmentation in cervical spine was rarely reported, in spite of the well-known complications due to osteoporosis, our results showed that it is a good technique to avoid adjacent vertebral fracture or complications due to rigid implant in osteoporotic spine.

OP-030[Spine and Peripheral Nerve Surgery]

SURGICAL OUTCOME FOLLOWING DELAYED SHORT SEGMENT POSTERIOR FIXATION OF UNSTABLE THORACOLUMBAR JUNCTION INJURY

Dewan Shamsul Asif¹, Sk Sader Hossain²

¹Square hospitals Ltd

²National institute of Neurosciences

INTRODUCTION - OBJECTIVE: This prospective study was designed to evaluate neurological recovery and functional outcome following delayed short segment posterior fixation of thoracolumbar junction injuries classified according to TLICS system.

METHOD: Between January 2010 and December 2011 neurological recovery and functional outcome in 38 thoracolumbar junction fractures were studied after posterior short segment fixation. The unstable spine was fixed based on Thoracolumbar Injury Classification Score by posterior short segment instrumentation. Neurological recovery and functional status assessed by ASIA scale and ODI respectively.

RESULTS: 36 male and 2 female patients with average age 29.42 ± 8.11 years. Fall from a height was the most common (79%) cause. Most of them were day labour and came from lower income class group. Most frequent level fracture was at D12-L1 comprising 76.3%. 10(26.3%) patients had type A fracture and 28(73.7%) had type B type fracture. Pre-operatively 2(5.3%) patients with ASIA grade A, 3(7.9%) with ASIA grade B, 27(71.1%) with ASIA grade C and 6(15.8%) with ASIA grade D. No neurological deterioration after surgery. At final follow up 96.87% exhibited neurological improvement, at least one ASIA grade. At final follow up ODI mean score was 19.06 ± 6.67 .

CONCLUSIONS: In our society where a dependent person is more than a diseased itself and if these patients were not treated properly, they would not only lose their employment but could be a permanent burden and nuisance for their family. Although long term follow-up evaluation needs to be verified, the short term follow-up results suggest a favourable outcome for short-segment instrumentation.

OP-031[Neurotrauma and Intensive Care]

NEUROSURGEON'S ROLE IN DISASTER MEDICINE: LESSONS FROM RECENT EVENT IN JAPAN

Katsuji Shima

Department of Neurosurgery, National Defense Medical College, Tokorozawa, Japan

INTRODUCTION - OBJECTIVE: In recent decades, the world has faced an increasing number of natural and man-made disasters. Japan is one of the most disaster-prone countries in the world. The aim of this study is to learn a lesson from recent mega-disasters in Japan.

METHOD: Author summarized 5 natural and 3 man-made mega-disasters in the last 20 years in Japan. The natural mega-disasters include the Great Hanshin Earthquake (6400 died) of 1995 and the Great East Japan Earthquake (15800 died) of 2011. The man-made disasters include Tokyo subway Sarin attack (13 died, 6300 injured) of 1995 and Express railway crash in Amagasaki (107 died) of 2005.

RESULTS: In the Great Hanshin Earthquake, around 80%, craniocervical injuries (CCIs) were the most common cause of death (around 80%) and preventable disaster death has been estimated as more than 500. Based on these experiences, disaster medical system in Japan was established. In the 2005 Amagasaki rail crash in Japan, 53% of 100 victims performed autopsy suffered CCIs.

CONCLUSIONS: In most heavily affected areas after disaster events, the medical system was almost paralyzed, thus many patients were not able to receive immediate treatment due to delayed evacuation, transfer and rescue. In patients with CCIs resulting from disasters, neurosurgeons should take the initiative throughout the entire care of CCIs, including the initial triage and treatment.

OP-032[Neurotrauma and Intensive Care] POSTOPERATIVE COMPUTED TOMOGRAPHY ABNORMALITY AFTER SURGERY FOR TRAUMATIC BRAIN INJURY: A STUDY OF 306 PATIENTS

Satoru Takeuchi, Kojiro Wada, Naoki Otani, Kentaro Mori
Department of Neurosurgery, National Defense Medical College, Saitama, Japan

INTRODUCTION - OBJECTIVE: It is well known that intracranial lesions, which are already diagnosed on preoperative computed tomography (CT), often expand after surgery, and the risk factors have been investigated. On the other hand, we have experienced cases in which new lesions, which were not detected on preoperative CT, were found on postoperative CT. Here, we investigated the predictive factors of new findings (NFs) on CT early after surgery.

METHOD: From April 2003 to March 2014, 306 patients underwent surgery for TBI. We conducted a retrospective registry-based review of 306 consecutive patients who underwent surgery for traumatic brain injury and investigated the prognostic factors of NFs on CT early after surgery.

RESULTS: Mean age was 50 years and 65.3% were males. NFs on postoperative CT were observed in 39 patients (12.7%). A univariate analysis showed that Glasgow Coma Scale (GCS) score ≤ 8 ($P < 0.001$), subdural hematoma as the primary indication for surgery ($P = 0.012$), midline shift ($P < 0.001$), absence of basal cistern ($P < 0.001$), and decompressive craniectomy and craniotomy as the surgical procedures ($P < 0.001$, $P = 0.004$, respectively) were significantly associated with NFs on postoperative CT. A logistic regression analysis demonstrated that decompressive craniectomy as the surgical procedure ($P < 0.001$), GCS score ≤ 8 ($P = 0.002$), and absence of basal cistern ($P = 0.01$) were significant factors.

CONCLUSIONS: Early postoperative CT after surgery for head trauma appears to be warranted in patients presenting with the indicated predictive factors of NFs.

OP-033[Neurotrauma and Intensive Care] STUDY OF VALUES OF MAGNETIC RESONANCE SPECTROSCOPY IN OUTCOMES OF CRANIOCEREBRAL TRAUMA

Mansur Abdulkholikovich Aliyev
Neurosurgery Department, Samarkand State Medical Institute

INTRODUCTION - OBJECTIVE: The purpose of this study is to investigate informative MR spectroscopy of metabolic changes in the brain in different outcomes of CCT injury in vivo.

METHOD: It has been studied the results of MR spectroscopy in 13 patients with various outcomes of CCT treated at the Neurosurgery Clinic of SamMI during 2013 y. Prevailed males - 9 patients. Age of patients ranged from 6 to 48 years.

All patients underwent MR spectroscopy. In our studies we used univoxel and multivoxel MR spectroscopy. In the resulting data obtained the following main contents of the most stable brain metabolites: N-acetylaspartate (NAA), choline (Cho), creatine (Cr), lactate (Lac) and alanine (Ala). During comparing different spectra were used the relative intensity of the signals. Via the relative intensity of the signal it has been compared spectra, measured on one patient in a healthy and diseased tissue.

RESULTS: In 9 patients on the spectrum and images of color mapping, on a plot of cystic-scarry-atrophic degeneration, compared to the spectrum of unmodified brain matter in the contralateral side (univoxel (UV) and multivoxel (MV) MR spectroscopy) were marked increase in choline content and choline-creatine ratio, a slight increase of lactate and expressed decrease in creatine, N-acetylaspartate.

CONCLUSIONS: Thus, our modest experience shows, that MR spectroscopy allows to determine in vivo and mark in dynamics the main brain metabolites as creatine, N-acetylaspartate, choline, lactate and alanine, which can give information about the state metabolic processes of structures of the central nervous system.

OP-034[Neurotrauma and Intensive Care] MANAGEMENT OF DIFFUSE AXONAL INJURY, OUTCOMES AND A PROPOSED CARE PATHWAY

Sharad S Rajamani, Najim Us Saqib
Department of Neurosurgery, Khoul Hospital, Muscat, Oman

INTRODUCTION - OBJECTIVE: Head injury has a high mortality rate, with poor outcome amongst those who survive. The norm for treating severe head injury has been intubation, ventilation, ICP monitoring and treatment of raised ICP with chemical and decompressive techniques.

METHOD: We discuss our experience with such severe head injuries. We assessed around 246 adult patients with severe head injury, diffuse axonal injuries, and no associated major system injuries, in a prospective study over a 5 year period from 2008 to 2013.

RESULTS: These patients all were intubated in the Emergency services, and were investigated with a CT scan. All patients were sedated with Propofol primarily and an ICP inserted via an EVD, connected to pressure monitoring system. All patients had arterial lines and ETCO₂ monitoring. The primary line of management was drainage followed by hypertonic saline, and as a third line mannitol was used as bolus. Some patients required continuous dosing of mannitol due to persistent ICP and these were classified as patients who were given regular mannitol.

We had a mortality of 43 patients in the hospital. The average ICP was significantly higher than those who were salvaged. There was a high usage of mannitol amongst these patients, but this might be due to the fact that their ICP was not controlled with the routine measures, and required. The mortality was 18%.

CONCLUSIONS: We strongly recommend the use of ICP monitoring in severely head injured patients, and suggest an algorithm in the management of raised ICP.

OP-035[Neurotrauma and Intensive Care] PATIENTS WITH BRAIN CONTUSIONS: PREDICTORS OF OUTCOME AND RELATIONSHIP BETWEEN RADIOLOGICAL AND CLINICAL EVOLUTION

Reza Ghadirpour¹, Corrado Iaccarino², Edoardo Picetti³, Maria Luisa Caspani³, Davide Cerasti⁴, Francesca Fossi², Franco Servadei²

¹Emergency Neurosurgery, Neuromotor Department, IRCCS "ASMN" of Reggio Emilia, Reggio Emilia, Italy

²Neurosurgery Unit, Emergency Department, University Hospital of Parma, Parma, Italy

³Intensive Care Unit, Emergency Department, University Hospital of Parma, Parma, Italy

⁴Department of Neuroradiology, University Hospital of Parma, Parma, Italy

INTRODUCTION - OBJECTIVE: Traumatic parenchymal mass lesions occur in up to 8.2% of all of traumatic brain injuries (TBI) cases and 13%-35% of severe TBI cases, and up to 20% of surgical intracranial lesions. The aim of this study was to identify predictors of unfavorable outcome

METHOD: In a retrospective, multicenter study, patients with brain contusions were identified in patients from 11 hospitals from 2008 to 2011. Data on clinical parameters and course of the contusion were collected. Radiological parameters were registered by using CT images taken at the time of admission and at subsequent follow-up. Patients who underwent surgical procedures were identified. Outcomes were evaluated 6 months after trauma by using the Glasgow Outcome Scale-Extended.

RESULTS: the following were revealed reliable predictors of unfavorable outcome: 1) increased patient age, 2) lower Glasgow Coma Scale score at first evaluation, 3) clinical deterioration in the first hours after trauma, and 4) onset or increase of midline shift on follow-up CT images. Multivariate analysis identified statistically significant predictors of clinical deterioration during the first hours after trauma: 1) onset of or increase in midline shift on follow-up CT images ($p < 0.001$) and 2) increased effacement of basal cisterns on follow-up CT images ($p < 0.001$).

CONCLUSIONS: In TBI patients with cerebral contusion, the onset of clinical deterioration is predictably associated with the onset or increase of midline shift and worsened status of basal cisterns but not with hematoma or edema volume increase, with a most reasonable indication for surgery.

OP-036[Neurotrauma and Intensive Care] PROGNOSTIC VALUE OF CORTICAL MEMBRANECTOMY IN CHRONIC SUBDURAL HEMATOMA

Faruk Altinel¹, Cihan Altin², Esin Gezmis³, Nur Altinors⁴

¹Department of Neurosurgery, Baskent University, Izmir, Turkey

²Department of Cardiology, Baskent University, Izmir, Turkey

³Department of Radiology, Baskent University, Izmir, Turkey

⁴Department of Neurosurgery, Baskent University, Ankara, Turkey

INTRODUCTION - OBJECTIVE: Chronic subdural hematoma (SDH) is formed gradually by the hemorrhage from parasagittal veins following a head trauma. Parietal and visceral membrane occurs between 7 and 21 days respectively. The major symptoms of chronic SDH are headache, unconsciousness, confusion and neurological deficits (contralateral motor deficits). It may also present with mild symptoms mimicking dementia such as disorientation several weeks after a minor traumatic injury. One of the most popular surgical treatment of chronic SDH is burr hole drainage. However residual hematoma is common problem after the procedure. Subtotal cortical membranectomy via craniotomy is an excellent surgical procedure which ensures rapid improvement in neurological deficits and has minimal risk of and cerebral herniation.

METHOD: Herein we present two different chronic SDH cases, surgically treated with cortical membranectomy. Case1: 71-year-old male, with complaints of somnolence and progressive weakness in right upper and lower extremities. Case2: 74 year-old female patient with complaints of dysphasia, unreasonable crying and right hemiplegia.

RESULTS: In both cases; frontoparietal osteoplastic craniotomy was performed. After the duramater incision, cortical membrane was almost totally excised. In postoperative period neurological deficits of both patients including hemiplegia and dysphasia resolved significantly.

CONCLUSIONS: Different surgical procedures have been used in the management of chronic SDH. Nowadays treatment with burr hole is more preferable than craniotomy in most clinics. We assert that craniotomy and subtotal membranectomy may be a more adequate choice in such cases. This report underlined that craniotomy is still an acceptable, safe, efficient and even a better procedure in the patients with chronic SDH.

Figure 1

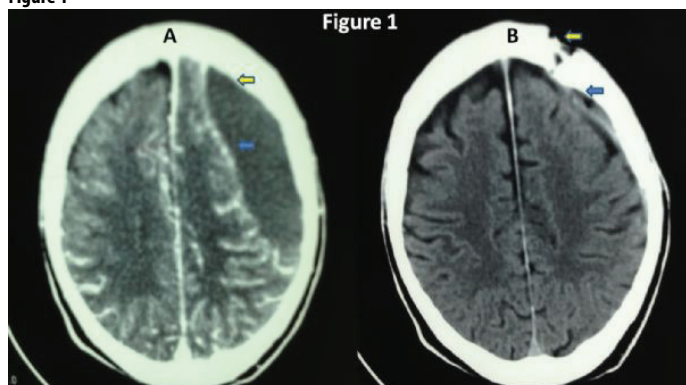


Figure 1 A: Axial NECT scan shows left frontoparietal, hypodense chronic subdural hematoma. Cortical membrane of hematoma (blue arrow), calvarial surface of hematoma (yellow arrow). B: In postoperative axial NECT scan craniotomy defect (blue arrow) and minimal residual hematoma (yellow arrow) are seen.

Figure 2

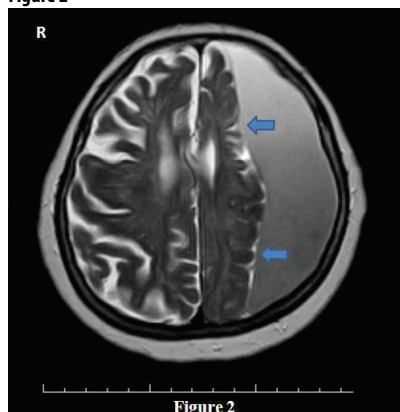


Figure 2. Axial T2 weighted MR image showing left frontoparietal chronic subdural hematoma which is hyperintense according to brain parenchyma. Arrow shows the cortical membrane.

Figure 3

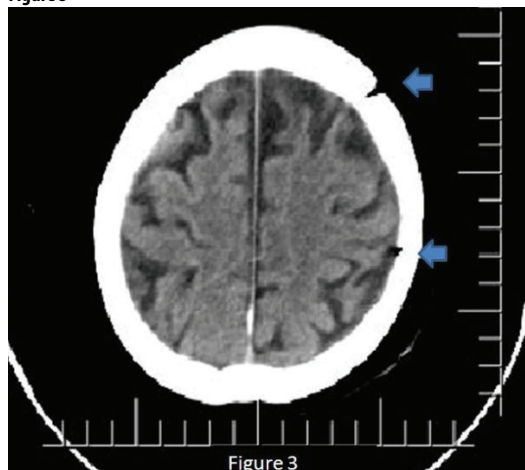


Figure 3. Postoperative Axial NECT scan shows reexpansion of brain parenchyma without any residual / recurrent subdural hematoma and arrows show craniotomy defects.

OP-037[Pediatric Neurosurgery] ENDOSCOPIC ASSISTED REMOVAL OF CHOROID PLEXUS PAPILLOMA OCCUPYING THE ATRIUM OF THE LATERAL VENTRICLE IN CHILDREN

Ehab Mohamed Eissa
department of neurosurgery, Cairo University, Cairo, Egypt

INTRODUCTION - OBJECTIVE: choroid plexus papilloma is the most common lateral ventricular tumour in the children with frequent location in the atrium surgical access to the this region remains one of the challenging procedures in the neurosurgery because of the deep location and relation to vital structures especially eloquent area of the brain. The vascular

nature of this tumour is an additional difficulty.

In this study, transcortical approach was used for microscopic removal of the tumours with endoscopic assistance to reach the tumour and identify its vascular and structural relation with minimal cortical incision.

METHOD: eight cases were approached transcortical either by 1-posterior parietal incision in the dominant side or small tumours in non dominant side or 2-parietotemporal junction incision in large tumours stretching the cortex in non dominant side.

Endoscopic access to the ventricle and navigation of the tumour were done through small incision which was followed by microscopic removal

RESULTS: Transcortical approach provide short and safe way to the atrium but with limited working area which compensated by endoscopic assistance for identification of tumour extension, vascular feeders, neural relation and also assist in tumour removal.

Total removal was done in six cases and in the remaining two cases, another surgical operation were needed to achieve total removal.

Two cases had postoperative visual deficit and one case transient motor deficit and one case had transient sensory aphasia.

CONCLUSIONS: endoscopic assisted transcortical (non eloquent) access to the atrium of the lateral ventricle enhance safe and total microscopic removal of this vascular tumor through small cortical incision

OP-038[Pediatric Neurosurgery] CEREBRAL PALSY AND SPASTIC DIPLEGIA;; UNDERSTANDING SELECTIVE DORSAL RHIZOTOMY(SDR) AND IT'S APPLICATION AND CLINICAL USEFULNESS

Muhammad Tariq Imtiaz, Aj Sabbagh, Ayman Al Banyan, Maqsood Ahmed
National Neurosciences Institute, King Fahad Medical City, Riyadh Saudi Arabia

INTRODUCTION - OBJECTIVE: SDR has been the main use of applying Rhizotomy techniques for neurosurgeons specializing in Cerebral Palsy(CP); performed with the assistance of a trained neurophysiologist. Approximately 200,000 new patients/year and an incidence rate of 2.5/1000 live births; CP can be extremely debilitating for physicians and communities worldwide due to its magnitude and involvement of multiple body systems.

METHOD: In SDR with Intra-operative neurophysiology, sensory nerve roots are first separated from motor ones at the conus (Park et al.) or in Cauda Equina (Peacock et al). Spastic sensory roots are then selectively identified via electromyography and divided into rootlets (3-8) at each level bilaterally from L2-S1/S2. Rootlets are then tested using an advanced EMG technique under 50 or 60 Hz then, selectively lesioned using a grading criteria (Park et al). These over-firing, non-GABA-absorbing (rootlets) generate unusual electrical activity during EMG testing phase and are considered to be the source of the patient's hypertonia.

RESULTS: Correct patient selection is most important -whereby spasticity is the main handicapping factor. (Peacock et al) published that Spasticity stayed reduced 10 years post op in all patients with 80% patients showed significant improvement in motor functions and <2% with bowel and bladder issues when SDR was performed with comprehensive Intraoperative Neurophysiology setup.

CONCLUSIONS: SDR is an outstanding technique, requires a team effort from different neurosciences professionals but produces outstanding results. With abundance of CP patients in Asia many presenting with Spastic Diplegia; It is pertinent that young neurosurgeons understand SDR and learn this state of the art but yet simple procedure.

OP-039[Neurotrauma and Intensive Care] HEAD TRAUMA IN INFANTS: EXPERIENCE OF A HIGH FLOW TERTIARY HOSPITAL IN A DEVELOPING COUNTRY

Mohamed Mamdouh Salama, Ahmed Abdullah Elfiki
Department of Neurosurgery, Faculty of Medicine, Cairo University; Cairo, Egypt

INTRODUCTION - OBJECTIVE: Head trauma in infants is a common health problem that has not been the focus of many research articles. The aim of this study was to describe the epidemiology, etiology, management and clinical outcome of head trauma in infants (<2 years) in a high flow tertiary hospital in Cairo, Egypt.

METHOD: This prospective study was conducted on 40 consecutive infants with head trauma admitted to the neurotrauma unit during the period between September 2013 and February 2014. The data of these patients including age, sex, mode of trauma, neurological status on admission, CT findings, operative details in surgical cases, clinical outcome, and length of hospital stay were documented and analyzed.

RESULTS: The study included 26 boys and 14 girls, with mean age of 12.5 months (range: 3 days- 23 months). The most common mode of trauma was falls (72.5%). Most of the patients had mild head injury (87.5%). Fourteen patients were operated upon, including 6 patients for evacuation of hematomas, 6 patients for elevation of depressed fractures, 1 patient for decompressive craniotomy and 1 patient for growing skull fracture. Excellent outcome followed in 36 patients. There was a single mortality. Mean length of stay was 5 days (range: 1 - 30 days).

CONCLUSIONS: Most of head injuries in infants are mild. The commonest etiology is falls, which is a preventable cause in many circumstances. The majority of these patients do not require surgical intervention. Excellent outcome is the rule in most of these infants with low mortality rates.

OP-040[Neurooncologic Surgery]

TRANSFERRIN-MODIFIED DOXORUBICIN-LOADED BIODEGRADABLE NANOPARTICLES EXHIBIT ENHANCED EFFICACY IN TREATING BRAIN GLIOMA-BEARING RATS

Liu Guo Dong¹, Lan Qing¹, Sun Tao², Shen He³, Zhang Zhijun³¹Neurosurgery Department, The Second Affiliated Hospital of Soochow University²Department of Biological Sciences, Xi'an Jiaotong-Liverpool University³Suzhou Key Laboratory of Nanobiomedicine, Division of Nanobiomedicine, Suzhou Institute of Nanotech and Nano-bionics, Chinese Academy of Sciences

INTRODUCTION - OBJECTIVE: Doxorubicin (Dox) is widely used for the treatment of solid tumors but its clinical utility on glioma is limited. In this study we developed a novel nano-scale drug delivery system employing biodegradable nanoparticle as carriers to load Dox. Tf was conjugated to the surface of nanoparticle to specifically target the nanoparticle to glioma.

METHOD: Tf-NP-Dox was prepared via emulsification-solvent evaporation method, and characterized for the size, Drug loading capacity (DLC), entrapment efficiency (EE), and Tf number on the surface. The anti-tumor efficiency in vitro was evaluated via CCK-8 assay. The transmembrane transportation was evaluated via HPLC assay. The anti-tumor efficiency in vivo was assessed in C6 glioma intracranial implant rat model. **RESULTS:** The average diameter of Tf-NP-Dox was 100 nm with approximately 32 Tf molecules on the surface. DLC was 4.4%. CCK-8 assay demonstrated much stronger cytotoxicity of Tf-NP-Dox to C6 glioma cells compared to NP-Dox or Dox. HPLC assay showed that Tf-NP-Dox transported Dox into C6 cells with high efficiency. In vivo, Tf-NP-Dox could transport Dox into tumors compare to contralateral part, with tumor inhibitory ratio and survival higher than NP-Dox or Dox.

CONCLUSIONS: Taken together, our results suggest that Tf-NP-Dox exhibits better therapeutic effect against glioma both in vitro and in vivo, and is a potential nano-scale drug delivery system for glioma chemotherapy.

OP-041[Neurotrauma and Intensive Care]

HOW TO TREAT SYNDROME OF THE TREPHINED WITH HYDROCEPHALUS FOLLOWING DECOMPRESSIVE CRANIECTOMY? NEUROSURGEONS' PERSPECTIVE

Mohammad Jaweed¹, Boon Seng Liew², Teak Sheng Gee², Azmin Kass Rosman², Saiful Azli²¹School of Medicine Taylors University, Lakeside Campus No.1 Jalan Taylor's, 47500 Subang, Kulalumpur, Malaysia²Department of Neurosurgery, Hospital Sungai Buloh, Selangor, Malaysia

INTRODUCTION - OBJECTIVE: High intracranial pressure (ICP) is the leading cause of death and disabilities after severe traumatic brain injury (TBI). Decompressive craniectomy (DC) is an effective method of controlling rising intracranial pressure (ICP) refractory to medical treatment. The altered pathophysiology found following (DC) converted from a closed box to an open box cranium carries its benefits and risk. In some craniectomy patient, the forces of atmospheric pressure and gravity overwhelm intracranial pressures, and the brain appears sunken despite presence of hydrocephalus. The sinking skin flap syndrome also called the syndrome of the trephined. The treating physicians must set aside the Monro-Kellie doctrine and recognize the new pathophysiological state of these 'open box' patients.

METHOD: This is a cross-sectional descriptive study. A structured questionnaire was administered to neurosurgeons during the 15th WFNS Congress 2013. This questionnaire was prepared in relation to management of syndrome of the trephined with hydrocephalus following Decompressive Craniectomy.

RESULTS: Response was received from 75 Neurosurgeons from 29 countries at consultant and registrar level, in regards to management of sinking skin flap syndrome post decompressive craniectomy, 53 respondents (70.7%) preferred concurrent CSF diversion and cranioplasty only 22 participants (29.3%) preferred CSF diversion and cranioplasty procedures in different occasion. **CONCLUSIONS:** Despite the fact that syndrome of the trephined with hydrocephalus occurred most frequently post decompressive craniectomy. Our survey revealed that majority of the neurosurgeons treat this pathology simultaneously. But still one third of practicing neurosurgeons preferred CSF diversion and cranioplasty on different occasion.

OP-042[Stereotactic and Functional Neurosurgery]

DEEP BRAIN STIMULATION – PERSONAL EXPERIENCE IN 489 CASES AT 3 DIFFERENT INSTITUTIONS

Frank Hertel¹, Rainer Rink², Robert Mandler², Andreas Husch², Florian Bernard²¹National Department of Neurosurgery, Luxembourg²SHG Kliniken, Idar-Oberstein

INTRODUCTION - OBJECTIVE: Deep Brain stimulation is nowadays a widespread method for the treatment of a variety of diseases.

METHOD: This report shows the technique and the results of 489 DBS interventions which have been performed between 2000 and 2014 in a consecutive series.

The patients ranged from 5,5 to 89 years in age (mean: 64.9).

RESULTS: 249 patients were suffering from Parkinson's disease, 13 from MSA, 6 multiple sclerosis, 5 OCD, 2 cluster headache, 2 atypical facial pain, 129 of dystonia and 83 of tremors (predominantly essential tremor).

467 have been implanted framebased and 22 frameless procedures at 3 institutions.

We used CT / MRI matching for planning.

All dystonia patients and 28 Parkinson's patients were implanted under general anesthesia, whereas the rest was under local anesthesia.

Microrecording was performed for all PD, Dystonia, OCD and cluster headache, whereas the others were implanted with macroelectrode testing.

We had only one intracerebral bleeding, whereas 3 acute postoperative subdural bleedings, which had to be evacuated in emergency.

Among the Parkinson's patients, we had 2 suicides, committed 1.5 years and 3 months postoperatively. Those were not clearly related to the DBS procedure.

The overall infection rate was 10.5%. Those latter occurred typically as late infections between 1 month and 12 years after the operation. That far, we had no proven meningitis or intracerebral abscess, respectively.

CONCLUSIONS: Our results show, that DBS has become useful in different kinds of disease and has become a very safe procedure, when used in the appropriate way.

OP-043[Stereotactic and Functional Neurosurgery]

THE NOBLE ART OF LESIONING FOR MOVEMENT DISORDERS; A REVIEW OF 54 CASES IN MODERN ERA

Khalid Mahmood Sukhera, Rizwan Ahmed Khan

Department Of Neurosurgery General Hospital Lahore

INTRODUCTION - OBJECTIVE: For last 2 decades, DBS is routine and preferred treatment modality for movement disorders in west. However Stereotactic lesioning also yields favorable results. Objective of our study was to assess outcome of SL for various movement disorders

METHOD: It was a single institution based prospective study conducted at department of Neurosurgery General hospital Lahore (Pakistan); from June 2012 to March 2014. For rigidity and dystonias, GPI Pallidotomy was done, while for tremors, VIM thalamotomy was done. Pallidotomy was done either unilateral/bilateral; while for tremors unilateral thalamotomy was done

RESULTS: Total 54 patients were treated; 43 male & 11 female. There were 30 cases of Parkinsonian tremors, 1 essential tremors and 1 post traumatic; 10 cases with rigidity and 13 cases of dystonias. Follow-up duration was 3-21 months. Patients with tremors and rigidity had pre op UPDRS score of 7-24 (mean 17) while dystonia patients had pre-op score of 18-74 (mean 43). 63 procedures were performed in 54 patients. There was significant improvement in symptomatology post op & on follow-up with an average 65% reduction in UPDRS (for Parkinsonian subgroup) and 57 % score reduction in Marsden scale for dystonia patients. Complications observed were; 2 patients had mild dysphonia, 2 had transient dysphagia & 2 had mild hemiparesis, 1 patient had wound infection and in 1 postop hematoma was seen on MRI scan (both managed conservatively).

CONCLUSIONS: SL procedures are safe, efficient and economical alternate (for DBS) treatment modality for movement disorders in underdeveloped countries with limited health resources

OP-044[Stereotactic and Functional Neurosurgery]

STEREOTACTIC NEUROMODULATION TECHNIQUES IN TREATMENT OF PARKINSON'S DISEASE

Evstafiy Melidi, Oxana Gavronina, Elena Khabarova

Department of functional neurosurgery, FBSI "Federal Neurosurgical Center" of the Russian Ministry of Public Health, Novosibirsk, Russia

INTRODUCTION - OBJECTIVE: To set out the results of stereotactic thermodestruction and neurostimulation of deep brain structures (DBS) with the use of neurophysiologic navigation and microelectrode analysis in treatment of patients with Parkinson's disease.

METHOD: Over a period of 2013 starting from the launch of the Functional division of the Federal Neurosurgical Center in Novosibirsk there were 90 patients with extrapyramidal pathology. The main group consisted of 73 patients with lateralized form of Parkinson's disease to whom stereotactic destructions of deep brain structures were performed. 17 patients from the 2nd group were offered DBS for management of ambilateral semiology with such nosology.

RESULTS: Unilateral thermal destructions of basal ganglia were performed on 73 patients (33 ventrodorsal pallidotomy and 40 ventro-intermediate thalamotomy to stop dyskinesia, rigidity and tremor respectively). Intracerebral electrodes were stereotactically implanted into subthalamic nucleus of 17 patients from both sides with single-step installation of Activa PC (Medtronic) generator into the left subclavicular area. This allowed significant life quality improvement in this category of patients (PDQ-39 scale) by means of tremor and rigidity regress contralaterally at the average of 87% (UPDRS scale), dyskinesia decrease and reduction of fluctuation for 75%. In the group of neuromodulation associated with zero mortality there were neither perioperative complications, no problems with implanted devices in the course of monitoring.

CONCLUSIONS: The usage of neurophysiological navigation allows performing more safety for all types of neuromodulation operations on submillimeter accuracy level reaching the maximum clinical effect during decrease of complications risk for each patient.

OP-045[Stereotactic and Functional Neurosurgery] DEEP BRAIN STIMULATION FOR PARKINSON DISEASE

Chingiz Shashkin, Serik Akshulakov, Yerbol Makhambetov, Azat Spekov
National Center for neurosurgery, Astana, Kazakhstan

INTRODUCTION - OBJECTIVE: Parkinson disease (PD) is chronic progressive degenerative disease of the central nervous system with prevalence 72 to 258,8 for 100 thousand people. We expect up to 20000 PD patients in Kazakhstan.

METHOD: 23 PD patients were operated in the National center for neurosurgery in period 2013-2014. We used international selection criteria.

We stimulated subthalamic nucleus in 22 cases and globus pallidus interna in 1 case. There were 11 male and 12 female. The average age of the patients was 51 y.o. The average duration of disease was 10 years. Severe fluctuations and dyskinesias were in 75% of cases.

We implanted DBS therapy Activa PC system from Medtronic (USA), which were consisted from two leads, extension cables and IPG.

RESULTS: Improvement of motor functions was in 80% of cases. Postural instability, gait problems and autonomic symptoms less regressed. We decrease the dosage of dopaminergic drugs for 30% and more thereafter the drug induced dyskinesia regressed in all cases moreover in two cases we postponed medication completely. We had complications in 5 cases: 1 bleeding, 1 stroke, 1 infection and 2 tromboembolism (1 of them died).

CONCLUSIONS: Deep brain stimulation is effective treatment of PD and can decrease main symptoms of the disease: rigidity, tremor and bradykinesia and sometimes postural instability and gait problems. The right patient selection is a key for good result of this procedure. There are all possibilities to treat Parkinson disease using DBS in Kazakhstan.

OP-046[Spine and Peripheral Nerve Surgery] STRUCTURAL PRESERVATION PERCUTANEOUS ENDOSCOPIC LUMBAR INTERLAMINAR DISCECTOMY: LIGAMENTUM FLAVUM SPLITTING TECHNIQUE + FISSURE FRAGMENTECTOMY AND SEALING TECHNIQUE

Hyeon Sung Kim¹, Se Jin Jeong¹, Ki Hyun Jeon¹, Woo Jin Choi¹, Kwan Tae Kim¹, Kun Soo Jang², Chang Il Ju², Seok Won Kim², Seung Myung Lee², Ho Shin²

¹Department of Neurosurgery, Hurisarang Spine Hospital, Daejeon City, South Korea

²Department of Neurosurgery, College of Medicine, Chosun University, Gwangju City, South Korea

INTRODUCTION - OBJECTIVE: We proposed the new surgical technique for achieving the sufficient preservation of segmental structures, in spite of sufficient removal of pathologic disc in the L5-S1 percutaneous interlaminar discectomy using the ligamentum flavum splitting technique and fissure fragmentectomy and sealing technique (LFS and FFS).

METHOD: We retrospectively analyzed 80 cases who underwent percutaneous endoscopic lumbar discectomy for L5-S1 herniated lumbar discs, using the LFS and FFS between May 2010 and November 2012.

Surgical procedure performed was as follows: 1) epidural anesthesia, 2) ligamentum flavum splitting (unilateral middle part ligamentum flavum splitting using the bevel type working cannula), 3) axillar approach, and 4) Fissure fragmentectomy and sealing.

To evaluate the structural Preservation, we check the immediate postoperative MRI for all patients.

RESULTS: The surgical results are as follows: 65 cases were complete (81.25%), 15 cases were sufficient (18.75%), and 0 case of incomplete (0%). The mean pain score (VAS) prior to surgery was decreased at the last follow-up, from 7.91 ± 0.73 to 1.14 ± 0.61 . During the follow-up period, 4 cases (5.00%) (1 CASE: early: less than 6 months, 3 case: delayed: more than 6 months) of recurrence were occurred.

CONCLUSIONS: According to the result, we obtained excellent clinical results using the structural preservation technique of percutaneous endoscopic interlaminar lumbar discectomy for L5-S1 herniated discs. In this result, we could obtain the sufficient annulus and structural restoration near to normal in spite of sufficient removal of pathologic discs using the combination approach of ligamentum flavum splitting technique and fissure fragmentectomy and sealing technique.

OP-047[Neurotrauma and Intensive Care] DISASTER RESPONSE: AN OPPORTUNITY TO IMPROVE GLOBAL HEALTHCARE IN THE 21ST CENTURY

Russell J Andrews¹, Leonidas Quintana²

¹Nanotechnology & Smart Systems, NASA Ames Res Ctr, Moffett Field, CA, USA

²Department of Neurosurgery, Valparaíso University Medical School, Valparaíso, Chile

INTRODUCTION - OBJECTIVE: Earthquakes alone often kill more than 200,000 people annually, and the universal humanitarian and medical response to disasters removes political, cultural, and socioeconomic barriers that often hinder the response to other global medical issues. Improved disaster response requires resources be "on-site" within 24 hrs - not the days to weeks of current disaster response.

METHOD: Trauma and stroke centers (TSC) evolved when evidence showed that immediate "24/7" treatment resulted in dramatic improvements in morbidity/mortality. TSCs (e.g. academic medical centers - university hospitals - in the US) are part of the "mainstream" ongoing healthcare system - not a separate system. All physicians, nurses, and allied health personnel (both senior and in-training) are

part of the TSC team - seamlessly integrated into the overall healthcare system. Equipment is presently available (e.g. military portable operating rooms) for a mobile trauma center to be in full operation anywhere worldwide less than 24 hours after a disaster strikes.

RESULTS: To date disaster response has remained separate from the ongoing healthcare system, e.g. UNOCHA (United Nations Office for the Coordination of Humanitarian Affairs) and the Red Cross. We propose that disaster response - like TSCs - be integrated into ongoing healthcare systems worldwide (governmental/nongovernmental, national/international). This global "mega trauma center system" would improve disaster response and also be a platform for establishing universal training, certification, and research standards. **CONCLUSIONS:** There are substantial political, cultural, and socioeconomic benefits - in addition to healthcare benefits - of integrating disaster response globally into the ongoing healthcare system.

OP-048[Miscellaneous] HUMANITARIAN NEUROSURGERY

Safi Ur Rehman

Retired Neurosurgeon

INTRODUCTION - OBJECTIVE: The aim of this presentation is to raise awareness and encourage neurosurgeons, both young and retired, to dedicate time and pay training & educational visits to underserved countries, provide neurosurgical services and engage in teaching and training.

WFNS, FIENS, AANS, ACNS and other organizations are trying to bridge the gap between affluent and deprived countries and raise the standard of neurosurgery in the developing countries.

But a lot more needs to be done to lessen the burden of neurosurgical diseases globally.

METHOD: Since retirement, I have been actively involved in volunteer services as neurosurgeon, mostly in Africa and associated with and liaising with above organizations.

I spent a total of 16 months in Addis Ababa, Ethiopia and provided full time neurosurgical service, operating with basic and inadequate facilities and teaching and training the local trainees.

Some eyeopening and interesting pathologies and their management, rarely seen in the developed world will be presented.

RESULTS: There are many countries in the world, particularly Sub Saharan Africa with no neurosurgeon, or very few with very basic inadequate facilities, limited postoperative and ICU care and no rehabilitation.

Facilities for vascular neurosurgery are lacking.

There is shortage of volunteers, especially for long term visits.

The Africa 100, initiated by Professor Samii, training the local neurosurgeons is very encouraging.

CONCLUSIONS: Humanitarian neurosurgery has tangible benefits and should receive greater attention to diminish global disparities and aiming at creating independent and sustainable neurosurgical facilities in the developing countries.

Africa lags far behind and deserves special attention.

OP-049[Neurovascular Surgery] SURGICAL STRATEGIES IN MULTIPLE ANEURYSMS

Ioan Stefan Florian¹, Adriana Baritchii², Andrei Farcas Rotariu², Zorinel Andrasoni²

¹Department of Neurosurgery, University of Medicine and Pharmacy "Iuliu Hatieganu" Cluj-Napoca, Romania

²Department of Neurosurgery, Cluj County Emergency Hospital

INTRODUCTION - OBJECTIVE: Based on our experience during the last decade, the aim of this paper is to add some arguments in favor of single-stage single opening procedure. We strongly recommend not to operate these cases in emergency, but to delay 3 to 4 days in order to obtain a good brain relaxation.

METHOD: The study is based on 749 aneurysms operated by the main author at the Department of Neurosurgery. From the total number of 660 patients, 57 cases harboured 146 aneurysms. We analyzed localization, age, gender, risk factors and postoperative complications associated with multiple aneurysms.

RESULTS: Patients with multiple aneurysms represent 8,6%, with a male to female ratio of 1:3.

Regarding the number of aneurysms, 70,1% of the patients with 2, 15,7% with 3, 5,2% with 4 and 5% with 5 aneurysms; 2 patients with 6 aneurysms. Meanwhile the most affected was MCA, the ACoA aneurysms were the most frequent location for ruptured aneurysms and for postoperative complications (p value < 0,05). We also compared surgical results related to unilateral or bilateral location, with no significant difference regarding the complications, outcome or mortality.

CONCLUSIONS: Patients with multiple aneurysms have a higher morbidity and mortality. Whenever possible, multiple aneurysms should be treated in a single stage single opening procedure.

The most difficult combinations for single stage single opening are mirror PCoA aneurysms, where this procedure is not always recommendable. In our opinion the most important factor-influencing outcome is neurological status at the time of surgery.

OP-050[Neurooncologic Surgery]

CAVERNOUS HEMANGIOMAS OF THE CAVERNOUS SINUS: REPORT OF AN EXPERIENCE WITH 27 CASES

Atul Goel

Seth G.S. Medical College and K.E.M Hospital, Mumbai, India

INTRODUCTION - OBJECTIVE: The clinical, radiological, and surgical issues concerning cavernous hemangiomas located within the dural confines of the cavernous sinus were analyzed on the basis of an experience with 27 cases.

METHOD: The clinical and surgical outcome of one of the most benign and most vascular tumors is analysed. The feasibility of radical resection by an entirely extradural approach using a temporal surgical route to this relatively rare and formidable surgical problem was investigated. Twenty seven patients, 9 males and 18 females were treated between the years 1992 to 2011. The patients ranged from 15 to 55 years. Headaches and deficits of the cranial nerves coursing through the cavernous sinus were the principal symptoms at presentation. Vision was affected in 7 cases. The radiological features were similar with a characteristic pattern of extension and encasement of internal carotid artery. The maximum size of the tumor was 21 to 73 mm (mean 42 mm). An entirely extradural route using the basal temporal approach was used.

RESULTS: Total resection was achieved in 22 cases. Two patients died following surgery. The follow-up ranged from 9 months to 17 years. The outcome of extraocular movements was poor in our series, possibly due to the massive sizes of the tumor encountered. There was no recurrence or growth of the residual tumor and all surviving patients are leading active lives.

CONCLUSIONS: Radical surgery can be safe and effective but can be difficult and life threatening. Extradural surgical route is the most rationale option.

OP-051[Neurooncologic Surgery]

OPERATIVE TECHNICAL PEARLS IN LARGE VESTIBULAR SCHWANNOMA SURGERY: SUBPERINEURAL VS EXTRAPERINEURAL DISSECTION FOR FACIAL NERVE PRESERVATION

Suresh Nair Narayanan Nair

Department of Neurosurgery, Sree Chitra Tirunal Institute for Medical Sciences, Trivandrum, India

INTRODUCTION - OBJECTIVE: An understanding of the mechanism of formation of arachnoid fold around vestibular schwannoma is crucial in preserving the anatomical integrity of 7th nerve.

METHOD: The author, who has an operative experience of 700 cases of vestibular schwannomas, describes the technical pearls for preservation of facial nerve by video demonstration of the dissection techniques of cases of large vestibular schwannoma operated by him. A total of 725 cases were operated in the department over a period of 16 years from 1st Feb 1998 till 15th May 2014. The essential initial step is peeling of the double layer of arachnoid from the posterior tumor surface. After reduction of the tumor volume, continued dissection of the arachnoid fold toward the brainstem can be achieved without opening the arachnoid over the fifth and lower cranial nerves, which are in separate cisterns. The key element in successful vestibular schwannoma is understanding that flattened facial and cochlear nerves do not have an arachnoid separating them from the tumor capsule which is essentially the perineurium of the vestibular nerve from which tumor has grown. If the tumor cannot be dissected from 7th nerve easily, a sub-perineural dissection is advised. The intracanalicular component of the tumor is removed by doing tailored drilling of internal auditory canal.

RESULTS: The seventh nerve can be anatomically preserved in many of large and giant vestibular schwannomas

CONCLUSIONS: Acoustic neuroma surgeons should strive to keep anatomical integrity of 7th nerve even in large acoustic tumors and the edited videos of pertinent cases will be shown

OP-052[Neurovascular Surgery]

MICROSURGICAL EXPERIENCE USING KEYHOLE EYEBROW APPROACH ON ANTERIOR CIRCULATION ANEURYSMS

Asra Al Fauzi, Nur Setiawan Suroto, Abdul Hafid Bajamal

Department of Neurosurgery, Airlangga University, Surabaya, Indonesia

INTRODUCTION - OBJECTIVE: The keyhole eyebrow approach has been proposed and developed for treating cerebral aneurysm in anterior circulation. This approach has the advantages in combining the minimally invasive principle with cranial base surgery technique.

METHOD: We used this keyhole eyebrow approach in 32 cases of anterior circulation aneurysm surgery in 2009-2014, including 26 ICA aneurysms, 5 AComA aneurysms and 1 patient with distal ACA aneurysm. All cases were ruptured aneurysms with SAH, except two patient with unruptured one. In this technique, an incision is made in lateral eyebrow line and a limited supraorbital craniotomy is performed with a width of 30 to 35 mm and a height of 20 to 25 mm. Through the subfrontal opening, microdissection and clipping of the aneurysms were done precisely.

RESULTS: In all cases, the aneurysms were successfully clipped. All patients outcome were successful, except one patient died because of other serious illness in ICU and three patients died because of vasospasm and brain infarction. No serious complications from surgical techniques occurred.

CONCLUSIONS: The keyhole eyebrow approach is an effective technique for gaining access to and treating the anterior circulation cerebral aneurysm. The small craniotomy and direct supraorbital approach to the lesion, makes the technique safe for the patient and comfortable for surgeon. In our experiences, this technique allows a wide exposure and offers equal surgical possibilities with less approach-related morbidity.

OP-053[Stereotactic and Functional Neurosurgery]
STEREOLITHOGRAPHY IN CRANIOPLASTYA. Kravchuk¹, A. Potapov¹, V. Panchenko², V. Okhlopkov¹, M. Novikov², E. Ippolitov², Y. Latyshev¹, S. Chobulov¹¹The Burdenko Neurosurgical Institute, Moscow, Russia²The Institute of Problems of Laser and Information Technology of Russian Academy of Sciences, Shatura, Russia

INTRODUCTION - OBJECTIVE: Stereolithography (STL) is modern CAD-CAM technology in cranioplasty.

METHOD: STL in cranioplasty was used in 336 patients (1999-2014 yy) with extensive complicated skull defects. STL - rapid prototyping technology (24-72 hour) was adapted to real model of the skull, implants and their moulds. Our technology- implants were hand made (pre or intraoperative) based on their STL models of moulds. PMMA for an implant was used in 309 pts and in 27 pts titanium mesh. Any intraoperative modification of the PMMA-Titanium implants was possible. Our technology based on SNL models is less expensive than custom made implants and easily used.

RESULTS: Good functional and cosmetic results - 314(93.4%) pts. Satisfactory cosmetic results - 17(5.1%) (atrophic changes in soft tissues of the scalp). Infection - 5(1.5%) pts.

CONCLUSIONS: Stereolithography in cranioplasty improves quality of reconstructive surgery

OP-054[Neurooncologic Surgery]

SURGICAL TREATMENT OF PATHOLOGICAL PROCESS OF THE SKULL BASE AND C1-C2 SEGMENTS OF THE SPINE ACCOMPANIED BY CRANIOVERTEBRAL INSTABILITY

Alexei Nikolaevich Shkarubo, Nikolai Alexandrovich Kononov, Dmitrii Nikolaevich Andreev, Petr Vladimirovich Zelenkov

Neurooncological Department, Burdenko Neurosurgical Institute, Moscow, Russia

INTRODUCTION - OBJECTIVE: To develop an optimal method of surgical treatment of patients with pathological processes of the skull base and C1-C2 by craniocervical instability – occipitospinal dysplasia (OSD) and anterior stabilization of C1-C2 combined with simultaneous extracranial (transoral and / or transnasal) removal of the pathological process.

METHOD: 56 patients was surgery (32 male, 24-women) aged from 2,5 to 61 years: 22-chordomas of the skull base and C1-C2, 1-meningioma, 3-MTS kidney cancer, 1-MTS breast cancer, 1-MTS of lung cancer, 1-plasmacytoma, 2-histiocytosis X, 3-a giant cell tumor, 1-osteoblastoma, 1-lymphoma, 1-malignant histiocytoma, 1-os odontoid C2, 12-basilar impression and invagination of the C2, 1-had bone cyst body C2, 4-translateral fracture-dislocation C2, 1-inflammation of the C0-C1-C2. 38 cases had craniocervical instability. In the 50 cases used transoral; 4-transnasal+transoral, 2-endoscopic transnasal removal of invaginated odontoid process C2. To perform OSD we used autologous and metallic wire-1, "Ventrofix"-2; "CCD"-10, "Vertex"-38, "Stryker"-1, "Synaps"-1, "Neon"-1, 3-anterior spondilolysis with individual plate made with the use of stereolithographic models.

RESULTS: In 34 (60,7%) total removal, in 10 (17,9%)—subtotal; in 12 (21,4%)—partial. Intraoperative CSF leakage was in 13 cases (23,2%), in 3 (5,4%)—postoperative. CSF leakage. Mortality was in 2 (3,6%).

CONCLUSIONS: Anterior stabilization of C1-C2 reduces the invasiveness of surgery compared to traditional OSD, does not limit the amount of active movements of the cervical spine. It is reasonable to enlarge the list of surgical indications for this category of patients who earlier were considered practically inoperable.

OP-055[Neurooncologic Surgery]

DETECTION OF SERUM ALU ELEMENT HYPOMETHYLATION FOR THE DIAGNOSIS AND PROGNOSIS OF GLIOMA

Gong Mingjie, Shi Wei, Chen Jian, Shi Jinglong, Ni Lanchun

Department of Neurosurgery, Affiliated Hospital of Nantong University, Nantong, Jiangsu Province, China

INTRODUCTION - OBJECTIVE: Despite recent advances in medical and surgical treatment, glioma still remains one of the deadliest human tumors. It is desirable to have accurate and non-invasive biomarkers for the early diagnosis and prognosis of gliomas. The aim of our study was to investigate the feasibility of Alu elements hypomethylation in serum and its clinical utility.

METHOD: We examined tumor tissue and matched serum specimens from 65 glioma patients, and 30 serum samples from healthy controls for Alu elements hypomethylation by bisulfite sequencing (BSP) which has been regarded as a gold-standard technology for the DNA methylation detection, because it could qualitatively and quantitatively explore the genomic DNA methylation status.

RESULTS: The median serum methylation level of Alu elements was 47.30% and 57.90% in patients and healthy controls, respectively ($P < 0.01$). Moreover, the median methylation level of Alu elements in tumor samples was 40.30%, we found good concordance of Alu elements hypomethylation between tumor and serum samples ($r = 0.882$, $P < 0.01$) in the study group. The low-grade glioma group have higher methylation level than high-grade group both in tumor and serum samples ($P < 0.01$, $P < 0.01$). The patients with high methylation level appeared to have a longer survival time than those with low level in tumor ($P < 0.01$) and serum ($P < 0.01$) analyses. ROC curve showed the area-under-curve (AUC) for diagnosis was 0.861 and indicating that Alu elements hypomethylation in serum may be of diagnostic value.

CONCLUSIONS: The detection of Alu elements hypomethylation in serum may be clinically useful for the diagnosis and prognosis of glioma

OP-056[Neurooncologic Surgery] MENINGIOMAS OF CLIVUS: SURGICAL STRATEGY

Oleksandr Voznyak, Andriy Lytvynenko, Oleg Maidannyk
Hospital "Feofaniya", Kyiv, Ukraine

INTRODUCTION - OBJECTIVE: Meningiomas of clival region (CM) are still the most challenging for surgical removal. Approach choice, radicalism of surgery, postop follow up and role of adjuvant treatment are discussable.

METHOD: Overall 33 patients with CM operated on in one clinic by one neurosurgeon from 2009 to 2013. CM were presented according to location: upper and middle clivus- 26 (82%); anterior foramen magnum - 7 (18%). Ratio F/M was 23/10. Age of patients ranged from 34 to 67 (mean 48). Retrosigmoid, transcondylar, anterior transpetrosal, combined petrosal approaches were applied for CM removal. Radiosurgery was performed in 2 cases after partial removal of CM.

RESULTS: All of the lower clivus meningiomas were removed totally. Seven (37%) of 19 petroclival meningiomas were removed completely, 9 (47%) sub-totally, and 3 (16%) partially. In group of seven sphenopetrosal meningiomas 3 (43%) removed sub-totally, and 4 (57%) partially. New neurological deficit (IV, V, VI n. disorders) observed after 4 interventions. In 2 cases CSF leakage required surgeries. None lethal case reported. There were no surgeries because of progression of incompletely removed CM during follow up time.

CONCLUSIONS: Patients postop QOL was the leading factor predisposed the surgical strategy. So far we came to usage of not traumatic simple and tailored approaches that may assure safe and adequate tumor removal with good functional result.

OP-057[Neurooncologic Surgery] INFRA-TENTORIAL SUPRA-CEREBELLAR APPROACH FOR PINEAL REGION TUMORS: LONG-TERM FOLLOW-UP

Hossam Ibrahim Maaty
Benha Faculty of Medicine-Benha University-Egypt

INTRODUCTION - OBJECTIVE: Tumors of the pineal region are histo-pathologically heterogeneous but often associated with severe progression of clinical manifestations. 75% of these tumors prove to be both malignant and radio sensitive and underwent only biopsy via stereotactic procedures, so the surgical intervention was done only in the remaining tumors.

OBJECTIVE: To study and analyze the data obtained from long-term follow-up of the cases with pineal body tumor hom's operated upon by the infratentorial supra-cerebellar approach (ITSC).

METHOD: This is a prospective study of 52 patients treated micro surgically for pineal region tumors. The ITSC route was used for removal of the tumor in all patients. They were 28 males and 24 females. Most of them were under the age of 20 years. Mean follow up period was 58 months.

RESULTS: : the leading symptoms and signs were those of increased intracranial tension. The pineal tumors were removed completely in 46 cases (85%) there was one surgical mortality. 11 patients developed postoperative complications in the form of 2 epidural hematoma, 4 transient parinaud's syndrome, 2 wound infection, 1 CSF fistula and 2 transient memory disturbance. The histopathological diagnosis were glial in 32 cases (61.6%), pineal parenchymal tumor in 13 cases (25%), germ cell tumors in 3 cases (5.7%) and others in 4 cases (7.7%). During the follow up period, 6 patients developed delayed surgical morbidities and 4 patients died.

CONCLUSIONS: : The ITSC route is a safe and effective surgical approach, associated with low morbidity, complete removal of the tumor and definitive histopathologic diagnosis.

OP-058[Neurovascular Surgery] INTERMEDIATE RESULTS OF ENDOVASCULAR TREATMENT FOR ANTERIOR CIRCULATION ANEURYSMS

Pavel Seleznev, Kirill Orlov, Alexey Krivoshepin, Dmitry Kisilitsin, Anton Gorbatykh, Vadim Berestov, Timur Shayakhmetov
Academician E.N.Meshalkin Novosibirsk State Research Institute of Circulation Pathology

INTRODUCTION - OBJECTIVE: Retrospective analysis of the results of endovascular treatment of anterior circulation aneurysms.

METHOD: In the department of neurosurgery of NRICP, from January 2011 to January 2014 494 patients with cerebral aneurysms of various locations underwent endovascular treatment. Analysis of the intermediate treatment results of 417 patients with 534 aneurysms (84,4% of total) was performed.

RESULTS: 102 patients (24,46%) had multiple aneurysms of the anterior circulation. Aneurysm size varied from 2,5 up to 32 mm. 183 (43,9%) patients had unruptured aneurysms. Among patients with ruptured aneurysms 62 patients (26,5%) were operated during acute stage of SAH (1-21 day), the rest were treated during posthemorrhagic period (over 21 days).

Coiling was performed in 219 cases (41,1%). Stent-assisted techniques were implied in 79 (14,8%), 173(32,4%) cases required balloon-assistance. 63 aneurysms (11,7%) were treated with fl w-diverting devices. Immediate radicalism: total embolization was achieved for 471(88,2%) aneurysms. 64 (11,8%) aneurysms were occluded subtotally. 24 patients (5,7%) had hemorrhagic complications. Morbidity and mortality comprised 9(2,15%) and 8 (1,92%) cases respectively.

CONCLUSIONS: Analysis of the data shown above revealed that more than half cases of aneurysm

embolization require use of assisted-methods or fl w diverting stents due to complex anatomy and geometry of aneurysms.

OP-059[Neurovascular Surgery] APPROACHING ANTERIOR COMMUNICATING ARTERY ANEURYSM WITH DOMINANT LEFT A1 FROM THE RIGHT SIDE

Waleed Abbass Ahmed
Departement of neurosurgery,cairo university,cairo,Egypt

INTRODUCTION - OBJECTIVE: Anterior communicating artery aneurysm is the common among aneurysms, it counts for 20% of all aneurysms and 30% of all ruptured aneurysms.

METHOD: 16 patients were included in this study, 10 males and 6 females with age ranging from 13 to 64. All cases are ruptured aneurysms. Computed Tomography reveals sub arachnoid hemorrhage in 11 cases and frontal, inter hemispheric, inter ventricular hemorrhage in 5 cases. Computed Tomography angiography were done to all cases and revealed the following, anteroinferior direction in 7 cases, posterior direction in 3 cases, superior direction in 5 cases and inferior direction in 1 case. 14 cases with Hunt and Hess scale grade 1 and 2 and 2 cases with grades 3 and 4. All cases operated by right Frontotemporal approach. Premature rupture occurred in 5 cases and temporarily clipping was done.

RESULTS: Diabetes insipidus occurred in 2 cases which was temporarily, 5 cases needed ventriculoperitoneal shunt (2 before clipping and 3 after clipping). Seizures occurred in 4 cases and were controlled, cerebral salt wasting occurred in 1 case and was controlled. Occlusion of the left A1 occurred in 1 case due to massive bleeding and the patient is hemiplegic. Death in 3 cases (mainly due to vasospasm in 2 cases and Deep venous thrombosis in 1 case).

CONCLUSIONS: Although approaching the anterior communicating artery aneurysm was done from the dominant side but in our study we have found that approaching the aneurysm with dominant left A1 from right side is safe easier especially to right handed surgeon and avoids the complications that occurs from retracting among left frontal lobe as personality and behavioral changes.

OP-060[Neurovascular Surgery] APPLICATION OF EVOKED POTENTIAL MONITORING DURING ENDOVASCULAR TREATMENT OF CAROTID CAVERNOUS FISTULAE BY DETACHABLE BALLOON

Qing Zhu, Liang Xu, Ailin Chen, Yanming Chen, Chao Sun, Qing Lan
Department of Neurosurgery, Second Affiliated Hospital of Soochow University, Suzhou, China

INTRODUCTION - OBJECTIVE: To evaluate the efficiency of evoked potential monitoring during endovascular treatment of carotid cavernous fistulae by detachable balloon.

METHOD: 10 cases of carotid cavernous fistulae were experienced evoked potential monitoring during endovascular treatment by detachable balloon under local anesthesia, including the occlusion of fistulae only or parent artery, in order to detect the ischemic changes and adjust the operative strategy in time.

RESULTS: 8 cases were treated successfully by detachable balloons for the sake of occlusion of fistulae and preservation of parent artery, and one of them were retreated in the same way because of the recurrence of fistulae due to unexpected shrinkage of balloon one week later. The ischemic change in evoked potential monitoring during balloon occlusion test occurred in one case, who was recommended occlusion of internal carotid artery in virtue of failure of occlusion of fistulae by detachable balloon, and cured by covered stent in one stage. Another ischemic change in evoked potential monitoring was detected in another case due to the occlusion of internal carotid artery by over-expanded balloon, who was cured by adjusting the position and volume of balloon. All cases were followed-up from 2 to 23 months, and there were no recurrence of symptoms and ischemic manifestations.

CONCLUSIONS: As an ideal technique, occlusion of fistulae by detachable balloon is suitable for treatment of carotid cavernous fistulae. The complications can be minimized and prognosis can be enhanced by adjusting the therapeutic strategy based on the evoked potential monitoring which is prominently sensitive to ischemic changes of brain tissue.

OP-061[Neurovascular Surgery] SURGICAL TREATMENT OF GIANT INTERNAL CAROTID ANEURYSMS IN THE INTRACAVERNOUS

Assylbek Kaliyev, Yerbol Makhambetov, Azat Shepkov, Faizulla Smagulov, Mynzhylky Berdikhodjayev
Department of vascular and functional neurosurgery, National Centre for Neurosurgery, Astana, Kazakhstan

INTRODUCTION - OBJECTIVE: The objective of the present study is to review results of surgical treatment of intracavernous giant aneurysm of the internal carotid artery (ICA) operated at the National center for neurosurgery.

METHOD: A retrospective analysis was conducted of the preoperative and postoperative history in 14 consecutive patients (3 male and 11 female) who underwent surgical treatment of a giant intracavernous aneurysms between February 2010 and October 2013. The role of sex, age, size, shape, clinical and neurological presentation, surgical approach and technique, preoperative and postoperative imaging were evaluated. The mean follow-up period was 12 months (range 3-24 months).

RESULTS: All patients underwent DSA with assessment of collateral cerebral blood flow. Of the fourteen patients undergoing surgery, five patients (36%) underwent proximal parent artery occlusion. In three cases (22%) endovascular embolization with coils was performed. Two patients (14%) underwent flow diverter deployment in the cavernous portion of the ICA. Preliminary bypass surgery between superficial

temporal artery and distal branches of middle cerebral artery with further proximal artery occlusion was performed in four cases (28%). Postoperative cerebral ischemia did not occur in any patient in the early postoperative and over a follow-up period. One patient (7%) had total postoperative third nerve palsy. There was no mortality in the postoperative period.

CONCLUSIONS: Preoperative precise assessment of the cerebral collateral blood flow plays a main role in the surgical treatment of giant intracavernous aneurysm.

OP-062[Neurovascular Surgery]

SPONTANEOUS INTRACEREBRAL HEMORRHAGE - A 2 YEAR EXPERIENCE AT A TERTIARY CARE HOSPITAL IN NORTH INDIA

Priyamvada Kovai, Yashbir Dewan, Sanjeev Dua, Anil Kumar Singh

Department of Neurosurgery, Max Institute of Neurosciences Dehradun, Max Super Speciality Hospital, Dehradun, Uttarakhand, India

INTRODUCTION - OBJECTIVE: This study aims to retrospectively analyse the data of all cases who presented to us with spontaneous intracerebral hemorrhage and study the incidence of various factors that are associated with the occurrence of intracerebral hemorrhage and the Glasgow Outcome Score (GOS) of our patients.

METHOD: All patients who presented to our hospital with spontaneous intracerebral hemorrhage over a period of two years have been included in the study. Retrospective analysis of the incidence of various factors associated and the GOS of the patients was done. Exclusion criteria: Patients who had history of trauma, aneurysmal and non-aneurysmal subarachnoid hemorrhage and patients operated outside our hospital were excluded from the study. Medical records were obtained through the Computerised Patient Record System of our hospital. Statistical analysis of the various associated factors and their correlation with the final outcome (GOS) is done using SPSS software.

RESULTS: Glasgow Outcome Score was used as an endpoint of our analysis. Out of 57 patients, GOS 1 score was seen in 21%, GOS 2 in 12% and GOS 3 in 35%, GOS 4 and 5 in 32% of our patients. The statistical analysis of the various factors and their correlation with final outcome is presented.

CONCLUSIONS: Early operative intervention should be initiated in all spontaneous intracerebral bleeds with volume of more than 30 cc. Timely surgical intervention and good intensive care monitoring are crucial to ensure better outcomes in spontaneous intracerebral bleeds.

OP-063[Neurovascular Surgery]

INDOCYANINE GREEN ANGIOGRAPHY IN VASCULAR NEUROSURGERY: A REPORT FROM AND FOR DEVELOPING COUNTRIES

Mohsen Nouri¹, Yoko Kato², Amir Azarhomayoun³, Abbas Amirjamshidi³

¹Department of Neurosurgery, Razi Hospital, Zahedan University of Medical Sciences, Saravan, Iran

²Department of Neurosurgery, Fujita Health University, Toyoake, Aichi, Japan

³Department of Neurosurgery, Sina Hospital, Tehran University of Medical Sciences, Tehran, Iran

INTRODUCTION - OBJECTIVE: Though less than one decade since the introduction of indocyanine green (ICG) video-angiography (VA) into the field of neurosurgery has passed, it has become a common practice in neurovascular procedures and its applications in other neurosurgical setting are increasing day by day. However, the expensive apparatus required for ICG-VA such as advanced microscopes and infra-red cameras make availability of this modality limited in developing or under developed countries.

METHOD: In the first phase of the study, a custom made camera was designed and tested on mouse to detect mesenteric arteries. After making appropriate changes, the device was tested in human subjects.

RESULTS: The camera could detect arteries on a real time basis both in animal and human subjects.

CONCLUSIONS: In this presentation, we make a short review on the biophysics of this imaging and introduce a cheap and custom-made camera which can be assembled and used even in remote cities in developing countries with impressive results. Also, we briefly show various applications of this technique in neurosurgery and the utility of the commercially available software for such video angiographies. Finally, we demonstrate how with small changes this camera can be used to help surgeons with tumour resection by detecting 5-amino-levulinic acid fluorescent illumination.

OP-064[Neurovascular Surgery]

SURGERY FOR CEREBRAL ARTERIOVENOUS MALFORMATIONS: SURGICAL NUANCES, SAFE SOLUTIONS AND PERMANENT CURE

Harjinder Singh Bhatia

Max Super Speciality Hospital PPG, New Delhi 110092

INTRODUCTION - OBJECTIVE: Cerebral cortical arteriovenous malformations (AVMs) are regarded as challenging pathologies. Most of these lesions however, can be treated safely and effectively by microneurosurgery.

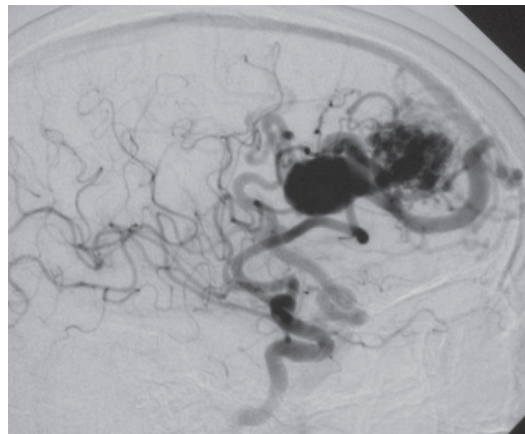
METHOD: Author operated upon 55 patients with cerebral cortical and subcortical AVMs over a period of 22 years. Forty four of these were grade I/II, eight were grade III and three were grade IV. All patients were evaluated by initial CT, MRI and transfemoral DSA. Three patients had undergone embolization 12 months prior to surgery: two of these had recurrence of hemorrhage, and one presented with brain abscess.

RESULTS: Complete extirpation could be achieved in all. Intraoperative blood loss ranged from 200 to 400 ml. Intraoperative brain swelling occurred in five patients, and breakthrough bleeding occurred in two patients. All these intraoperative problems could be managed successfully. There was one postoperative death, while recovery was uneventful in 54 patients, without neurological worsening.

Postoperative angiography was done in thirty two patients (after 2000), which showed complete excision of the AVM in thirty one, and small residual AVM in one patient. None of the operated patient ever had recurrence of hemorrhage or seizures. Review over a period of 6 months to ten years showed neurological improvement in 43 patients, and twenty of these patients were off their anti-epileptic medication.

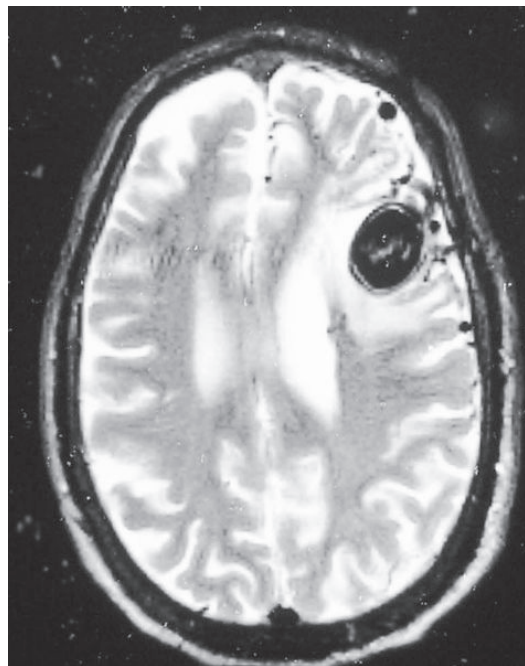
CONCLUSIONS: Surgical excision should be the first line of management for cerebral AVMs. A definite plan can be made based on integration of the imaging appearances, with clinical profile and intended surgical approach. Special attention needs to be paid to venous anatomy.

Fig 1



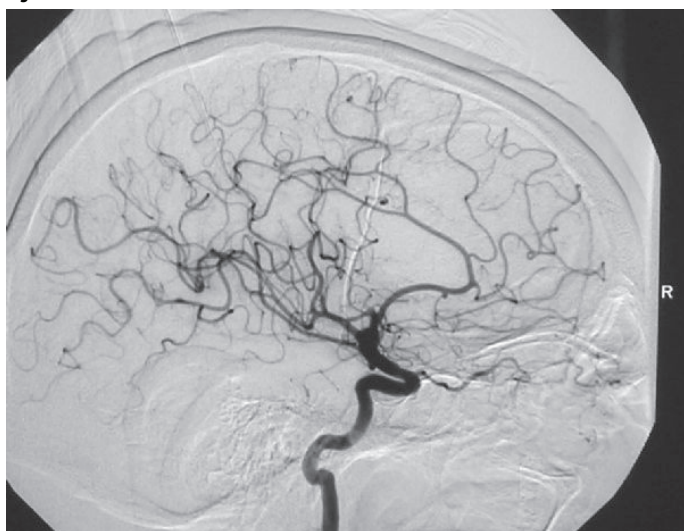
DSA showing Grade II AVM with giant venous aneurysm

Fig 2



MRI (T2-weighted) showing giant venous aneurysm

Fig 3



Postoperative DSA showing complete extirpation of AVM and venous aneurysm.

OP-065[Neurovascular Surgery]

ANTERIOR CLINOIDECTOMY THROUGH THE TRANS-SUPERIOR FISSURE APPROACH: EXPERIENCE WITH 75 CONSECUTIVE PATIENTS

Satoru Takeuchi, Kojiro Wada, Naoki Otani, Hideo Osada, Satoshi Tomura, Arata Tomiyama, Kimihiro Nagatani, Kazuya Fujii, Hideaki Ueno, Kentaro Mori
Department of Neurosurgery, National Defense Medical College, Saitama, Japan

INTRODUCTION - OBJECTIVE: Anterior clinoidectomy is one of the essential skull base techniques to treat many lesions including deeply situated aneurysms and skull base tumors. We have recently described that extradural anterior clinoidectomy via the trans-superior orbital fissure (SOF) approach (dura propria mini-peeling) can provide extensive exposure of the anterior clinoid process (ACP). The aim of this study was to investigate the usefulness of this technique.

METHOD: Between September 2009 and March 2014, 75 patients with neoplastic and vascular lesions underwent extradural anterior clinoidectomy with the trans-SOF approach. We reviewed surgical techniques, complications, and final results of anterior clinoidectomy.

RESULTS: Fifty-nine patients were treated for aneurysms, 15 patients for intraorbital, parasellar and suprasellar tumors, and one patient for optic canal injury. The entire removal of the ACP was performed in 72 patients (96%), and a partial clinoidectomy was performed in three patients. The temporopolar approach was performed in 65 patients. The optic canal was opened widely in 46 patients. The falciform ligament was cut in 31 patients. The dural ring was incised in 26 patients. The preoperative visual acuity worsened in two patients (2.7%), and 11 patients (14.7%) experienced a worsening of visual field function. One patient suffered cerebrospinal fluid leakage. Postoperative outcome was good recovery in 68 patients (90.7%), moderate disability in five, severe disability in one, and dead in one (due to re-ruptured aneurysm). There was no operation-related mortality in the series.

CONCLUSIONS: The extradural anterior clinoidectomy via the trans-SOF approach is useful and safe.

OP-066[Surgical Neuroanatomy]

"TRANSIENT PARA/QUADRIPLÉGIA" AFTER BRAIN AND SPINAL CORD TUMOR RESECTION SURGERIES; UNDERSTANDING THE NEUROPHYSIOLOGICAL BASIS BEHIND TRANSIENT MOTOR SYSTEM CHANGES

Muhammad Tariq Imtiaz, Yasser Ismail Orz, Mahmoud Al. Yamany
National Neurosciences Institute, King Fahad Medical City, Riyadh Saudi Arabia

INTRODUCTION - OBJECTIVE: Intraoperative neurophysiology monitoring (IOM) of the sensory and motor pathways offers opportunities in applying basic neurophysiological principles to clinical practice. Through IOM, we have learned the mechanisms behind changes in the postoperative neurological outcome of patients operated on brain or spinal cord tumors. Similarly, clinical importance of the term "transient quadri/paraplegia" phenomenon has been identified and explained using neurophysiological techniques (Deletis et al).

METHOD: Somatosensory Evoked Potentials (SSEP) and Motor Evoked Potentials (MEPs) are an integral component of monitoring during central nervous system (CNS) tumor surgeries. Not only it provides information about the integrity of dorsal column and corticospinal tracts in real time but also serves as a quick litmus test to identify ischemia during a procedure. (Epstein et al 1993).

RESULTS: As suggested by (Sala et al., 2006) benefit of IOM becomes evident only a few months after surgery; while early neurological outcomes are similar in monitored and non-monitored patients; Monitored patients had better long term results. Data reflected light on the "transient paraplegia" phenomenon.

While presence of signals (SSEPs and MEPS) assures surgeons about the integrity of major sensory and

motor pathways but also sheds light on some "indirect pathways" (Neuromodulation, propriospinal and other brain-spinal relay pathways). These indirect pathways provide the extra "juice" to the direct pathways and is likely the rationale behind transient paraplegia. They are sensitive to mechanical intervention and can be temporarily disengaged resulting in transient weakness.

CONCLUSIONS: There is more to motor function besides motor cortex and corticospinal tracts. Understanding the neurophysiology behind those indirect systems can help us understand the transient quadri/paraplegia phenomenon.

OP-067[Miscellaneous]

NORMAL PRESSURE HYDROCEPHALUS: LESSONS LEARNED FROM 53 PATIENTS UNDERGOING LUMBOPERITONEAL SHUNT

Russell J Andrews

Nanotechnology & Smart Systems, NASA Ames Res Ctr, Moffett Field, CA, USA

INTRODUCTION - OBJECTIVE: Normal pressure hydrocephalus (NPH) is a common cause of dementia, gait disturbance, and/or incontinence in elderly individuals. The high complication rate of ventriculoperitoneal shunt (VPS) makes an alternative treatment for NPH desirable.

METHOD: From 12/2001 - 12/2012, 53 patients - 29 M, 24 F (mean age 74.5) - underwent lumboperitoneal shunt (LPS) for NPH. Patients suspected of NPH by history underwent brain MRI and a formal testing battery (gait, coordination, neuropsychology) before and after lumbar puncture and drainage of 30-40 cc CSF ("Tap Test"). The peritoneal slit valve was removed for CSF pressure > 20 mm Hg. No valve (programmable or non-programmable) was placed initially. For low-pressure headache, patients gradually increased time sitting or standing over several weeks.

RESULTS: Clinical+MRI+Tap Test Mean CSF Opening Pressure* CSF OP < 11 mm Hg

LPS placement for NPH 16.9 mm Hg 3/45 patients

no LPS placement (failed testing) 11.0 mm Hg 9/12 patients

* P < 0.01 by t-test for difference between means

Condition/Complication Number of Patients

Elective removal of LPS 2

Elective ligation of LPS 3 (one later chose unligation)

Revision (all for peritoneal cath migration) 6 (only 2 patients after 2004)

Placement of valve for low pressure headache 1

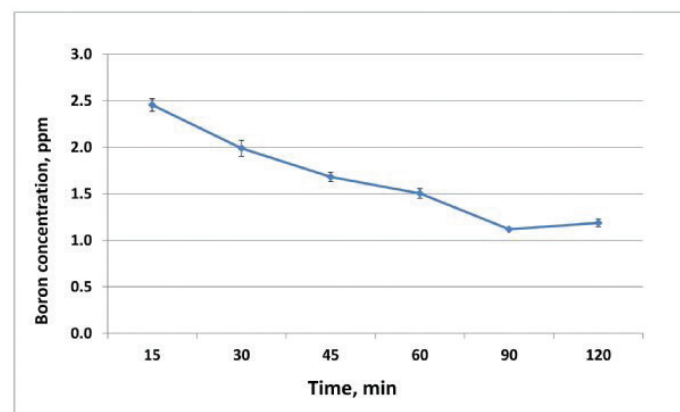
Later removal slit valve of peritoneal cath 4

Superficial abdominal incision infection 1 (resolved w/ p.o. ABx)

Subcut abdominal incision hematoma 1 (postop error - patient given ketorolac)

CONCLUSIONS: NPH is likely a form of mild hydrocephalus in the elderly. LPS is a safer, more cost-effective alternative than VPS for NPH. The relevant literature is reviewed.

Boron concentration in C6 rat glioma after BHA injection



OP-068 [Neurotrauma and Intensive Care]

TIMING OF SURGERY IN COMPOUND DEPRESSED SKULL FRACTURES IN HIGH FLOW CENTERS

Ahmed El Fiki

Department of Neurosurgery, Cairo University, Cairo, Egypt.

INTRODUCTION - OBJECTIVE: A compound depressed fracture is a neurosurgical emergency because of the risk of bacterial infection of the cranial cavity. The initial surgery is performed within 24 hours and usually within the first 12 hours. Surgery OBJECTIVES include removal of contaminated bone fragment, foreign material and water tight dural closure. The aim of the work is to evaluate the risk of delayed timing for surgery in cases of compound depressed fracture with special consideration of complications that may occur. [1]

METHOD: prospectively, we collected the data of 55 patients with depressed skull fractures in our department from November 2013 to March 2014. [2]

RESULTS: forty five cases were males and ten were females, hospital presentation time ranged from 5 to 36 hours after the trauma. And all cases were operated after 6 hours with seventeen patients had done

surgery after 10 hours. All cases had clean wound postoperatively except one case with superficial wound infection and 73% of patients discharged before the third day from admission.[1]

CONCLUSIONS: Neurological complications related to delayed surgery in cases of compound depressed skull fractures can be lowered when early surgery done. but timing for surgery can be delayed with low risk in certain situation as in high flow centers especially if broad spectrum antibiotic cover was taken.[1]

OP-069[Miscellaneous]

MINI INVASIVE SURGERY(CRANIOTOMY) FOR CHRONIC SUBDURAL HEMATOMA: APPLIED RESEARCH

Ahmad Fawad Pirzad

1. Department of Neurosurgery, Aliabad University Hospital, Kabul Medical University (KMU), Kabul, Afghanistan

OBJECTIVE: To evaluate the results of surgical treatment options for chronic subdural hematoma in Mini invasive craniotomy vs Classic surgical Methodes (Craniotomy) Applied Research

METHOD: A prospective study on patients with chronic subdural Hematoma surgically treated by Mini-invasive method (5mm incision and 2mm drill for craniotomy) vs retrospectively other invasive methods. The study focused on duration of operation, Incision, Anesthesia, Bleeding during operation, Stay duration in Hospital, cost and accompanying disease. recommendation applied Mini-invasive method

RESULTS: 200 cases were reviewed (100 prospective and 100 retrospectiv). Evaluation of the results showed that twist drill and burr hole craniotomy are safer(98%); than craniotomy. Irrigation lowers the risk of recurrence in twist drill craniotomy and does not increase the risk of infection. Drainage reduces the risk of recurrence in burr hole craniotomy, and a frontal position of the drain reduces the risk of recurrence. Drainage reduces the risk of recurrence in twist drill craniotomy, and the use of a drain does not increase the risk of infection. Burr hole craniotomy appears to be more effective in treating recurrent haematomas than twist drill craniotomy Also the study showed effective on duration of operation, Incision, Anesthesia, Bleeding, cost and accompanying disease.

CONCLUSIONS: Twist drill and burr hole craniotomy can be considered first tier treatment, while craniotomy may be used as second tier treatment. results on duration of operation, Incision, Anesthesia, Bleeding during operation, Stay duration in Hospital, cost and accompanying disease. craniotomy should be considered the treatment of last choice for recurrences.

OP-070[Miscellaneous]

GAMMA KNIFE RADIOSURGERY OF ARTERIOVENOUS MALFORMATIONS: SUMMARY OF EXPERIENCE IN 401 CASES FOLLOW UP IN 6 YEARS

Nguyen Thanh Binh, Nguyen Minh Tu

Gamma Knife unit, department of Neurosurgery, Cho ray hospital, Ho Chi Minh city, Vietnam

INTRODUCTION - OBJECTIVE: The authors analyzed the clinical, neuroimaging outcomes and complications that occur in 6 years of patient with AVM after GKRS, focusing on the analysis of the obliteration rate depending on the AVM volume and long – term complications

METHOD: Between 2007 and 2012, 730 patients AVMs were treated Gamma Knife radiosurgery (GKRS) at our unit, 401 prospective patients with cerebral AVMs were treated GKRS more than 20 months and follow up by Microsoft Office Access, R statistical analysis. The mean age was 30,476 ± 13,48 years (6-76), the mean volume 8,957 ± 13,257 cm3 (0,0187- 135,00 cm3), the mean marginal dose was 21,379 ± 3,04 Gy (13-26), and the mean follow up duration was 41,829 ± 13,59 months (21,43-72,67).

RESULTS: The angiographic obliteration rate was 77,2% overall, and it was 88,8%, 59,7%, and 22% for small, medium and large AVMs. Respectively, obliterated time 17,186 ± 7,63 (10-48) months. Have 9 patients hemorrhage, the overall bleeding rate was 2,25%. The bleeding rate was 1,2%, 2,7% and 11,1% for small, medium and large AVMs. Have 11 patients with severe brain edema, the brain edema rate overall is 2,7%, this is 1,2%, 6,3% and 0% for small, medium and large AVMs,

CONCLUSIONS: Gamma Knife radiosurgery is a safe and effective treatment for selected patients with AVMs, and it carries a low risk of first hemorrhage from brain arteriovenous malformations and damaging adjacent critical vascular structures. Complications are acceptable. However, need follow up along time to appreciate obliteration rate and complications.

OP-071[Spine and Peripheral Nerve Surgery]

NATURAL COURSE AND RISK FACTORS FOR PROGRESSION OF MILD TRAUMATIC BRAIN INJURY ASSOCIATED INTRA-CRANIAL HEMORRHAGE: A COHORT STUDY FROM A TRAUMA CENTRE

Amir Azarhomayoun¹, Mohsen Nouri², Rouzbeh Shams Amiri¹, Ibrahim Ketabchi¹, Abbas Amirjamshidi¹

¹Department of neurosurgery, Sina hospital, TUMS, Tehran, Iran

²Sina trauma & surgery research center, TUMS, Tehran, Iran

INTRODUCTION - OBJECTIVE: Intra-cranial bleeding takes place in about 15% of patients with mild traumatic brain injury (mTBI). The risk factors for progression and expansion of hematoma and their natural course is not well known. This study was designed to elucidate the natural course, risk factors, and time interval for progression or regression of the post-mTBI intra-cranial hemorrhages (ICH).

METHOD: Eighty two patients with mTBI suffering intra-cranial hematoma on their initial brain CT scan

were prospectively enrolled in a cohort study and data including accident characteristics, past medical history, and physical examination were registered. They all underwent initial and repeat brain CT scans according to the protocol in our institute. Natural course of hematoma was demonstrated and data analysis of the patients' characteristics and their CT scan findings was performed to elucidate risk factors associated with hematoma progression or the need for intervention.

RESULTS: Age, sex, anti-coagulants, diabetes, associated trauma, type of the accident, initial GCS, signs of skull base trauma, para-clinical measures and primary size of hematoma were not associated with increased risk of hematoma progression ($p > 0.05$). Sub-arachnoid and subdural hemorrhages resorbed after 6 days while epidural hematoma resorbed after 16 days from the accident.

CONCLUSIONS: In this study, hematoma progression was preceded by clinical decline in all cases. It may be safe to discharge patients with normal sensorium after 24 h who do not show evidence of hematoma progression on repeat brain CT scan. However, further studies to externally validate these findings are warranted

OP-072[Spine and Peripheral Nerve Surgery]

LONG-TERM SURGICAL TREATMENT OUTCOMES OF SPINAL EPENDYMOMA: EXPERIENCE OF 23 CASES

Anas Abdallah, Erhan Emel, Murad Asiltürk, Mustafa Levent Uysal, Ali Ender Ofluoglu, Özden Erhan Sofuoğlu, Müslüm Güneş, Hasan Burak Gündüz, Betül Güler, İlhan Aydın, Rashid Avyasov, Sarper Polat Bakırköy Research and Training Hospital for Neurology Neurosurgery, and Psychiatry, Department of Neurosurgery, İstanbul, Turkey

INTRODUCTION - OBJECTIVE: Spinal ependymomas are the most common third intradural tumors that account for about 23% of intradural spinal cord tumors in adults. In this study long-term surgical treatment outcomes of our 23 cases of spinal schwannomas have been evaluated.

METHOD: Medical records were retrospectively reviewed in 23 cases of ependymoma operated between the years 2007 and 2013. 23 cases of spinal ependymoma in 22 (11 women and 11 men) patients. The mean age was 34.81 years. The mean follow-up period was 41 months. The long-term clinical outcomes were evaluated retrospectively using patients compliant, the periods of first compliant and surgery, localizations, recurrence rate and complications. All patients underwent a hemilaminectomy, laminectomy or laminotomy before neurosurgical tumor removal.

RESULTS: The most common complaints were radicular pain (74%). Cervical(5), thoracic(1), lumbar(16), and One case was multifocal. Seventeen cases were intradural-extramedullary type and six cases were intradural-intramedullary type. One case showed recurrence after 3 years of the first surgery. The mean of the time between the first compliant and surgery was 26.85 months. 2 cases of those complained of neurological deficits had not improved completely. GTR was achieved in Fifteen patients and STR in eight patients. 3 patients were involved with CSF fistula and they got treated successfully. Histologically, 14:WHO Grade I and 9:WHO Grade II.

CONCLUSIONS: High-grade of ependymoma histological grade may be associated with female hormonal. Dysfunction of thyroid, DM, HT, Smoking, and obesity were considered as risk factors. To reduce the recurrence of spinal ependymoma, total excision of tumor mass should be done.

OP-073[Spine and Peripheral Nerve Surgery]

MINIMALLY INVASIVE TLIF USING BONE CEMENT AUGMENTED PEDICLE SCREWS FOR LUMBAR SPONDYLOLISTHESIS IN PATIENTS WITH OSTEOPOROSIS

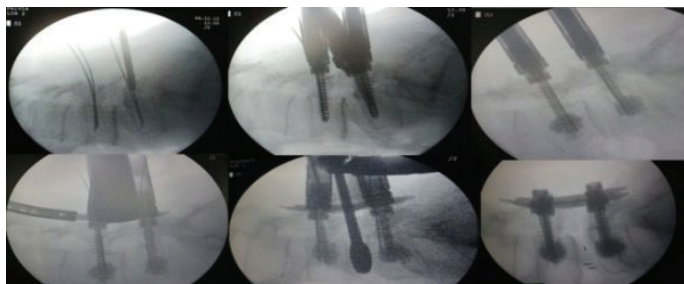
Venkata Ramesh Chandra Vemula, Chandramowliswara Bodapati, M.a. Jagadish
Department of Neurosurgery, SVIMS, Tirupati, Andhra Pradesh, India.

INTRODUCTION - OBJECTIVE: Percutaneous TLIF in the management of lumbar spondylolisthesis in patients with osteoporosis using bone cement augmented, canulated, fenestrated pedicle screws has rarely been reported. We present our clinical and radiological results of this technique in a cohort of 15 patients.

METHOD: A consecutive prospective series of 15 patients with osteoporosis with degenerative spondylolisthesis underwent MIS posterior pedicle arthrodesis with interbody fusion with PMMA cement augmented canulated, fenestrated pedicle screws. Patients were evaluated preoperatively and postoperatively by means of VAS pain score, Oswestry disability score and radiologically by plain radiography and CT scan performed one day after surgery and 6 months thereafter.

RESULTS: A total of 15 patients were included in the study. twelve females and three males with average age 55 yrs with major symptoms being low back pain, radiating pain to lower limbs and with average T score of -2.6 were studied. All the patients were clinically and radiologically followed and there was statistically significant reduction of pain and had improvement in quality of life. No radiological loosening or pulling out of screws was observed.

CONCLUSIONS: Fenestrated pedicle screw fixation with bone cement augmentation in patients with osteoporosis is a safe technique to increase the pullout strength of screws placed in osteoporotic spines. The safety and efficacy of this technique to prevent the short-time complications associated with fusion surgeries performed in aging populations is confirmed by our study. The ultimate safety of using this technique needs to be confirmed in a larger series with a longer followup period. 1



brief procedure explained through fluoroscopy images

OP-074[Spine and Peripheral Nerve Surgery] MODIFIED TRANSPEDICULAR APPROACH FOR TREATMENT OF SEVERE THORACOLUMBAR BURST FRACTURES: A TECHNICAL NOTE

Sim Khairun Nabi Khan, Robert Ahmed Khan, Moshir Rahman, Md. Ruhul Kuddus
department of neurosurgery, BSM Medical University, Dhaka, Bangladesh.

INTRODUCTION - OBJECTIVE: To describe a modification of transpedicular approach by which neural canal decompression can be done with minimal disruption of the spinal stability after burst fracture.

METHODS: In this technique a hand controlled drill is used percutaneously from the lateral side in such a trajectory that the tip of the hand controlled drill reaches the retro pulsed fragment anterior to the cord through the intervertebral foramina or posterior part of the body adjacent to the base of the pedicle. A small part of the pedicle is resected and only the retro pulsed portion of the fractured vertebral body is removed. Stabilization with pedicle screw and reconstruction of the vertebral body by packing bone chips were done after this decompression procedure in all the 32 patients included in this study.

RESULTS: All the patients showed different degrees of neurological improvement. Post operative imaging showed decompression of the canal in all the cases. Conventional transpedicular decompression of the neural canal requires a considerable amount of lamina, facet joint and pedicle resection. This procedure requires larger bone graft or cage to reconstruct the vertebral body. By the modified transpedicular approach it is possible to remove the retro pulsed bone fragment with minimal destruction of the vertebral elements contributing to spinal stability.

CONCLUSIONS: The modified transpedicular transforaminal approach is a new, simple and less-traumatic technique for treatment of thoracolumbar fracture through posterior approach with good outcome.

OP-075[Spine and Peripheral Nerve Surgery] EVALUATION OF MEDIAN NERVE MOTOR FUNCTION IN CTS USING LOAD CELL – OBJECTIVE ASSESSMENT OF POSTOPERATIVE RECOVERY

Hee Jin Yang, Sung Bae Park, Sang Hyung Lee, Young Je Son, Yeong Seob Chung
Department of Neurosurgery, Seoul National University Boramae Hospital, Seoul, Korea

INTRODUCTION - OBJECTIVE: Motor deficit of carpal tunnel syndrome (CTS) impedes patients' functional status of hand, although major complaints are sensory components. The objective evaluation of median nerve motor function is not easy, contrary to evaluation of sensory function.

METHOD: Objective motor function of median nerve was evaluated was done by load cell and personal computer-based measurement system. All of the measurement was done in patients diagnosed as having CTS by clinical features. The strength of thumb abduction and index finger flexion was measured in each hand three times, and the average value was used to calculate thumb index ratio (TIR). The measurement was done before operation and postoperative follow-up. **RESULTS:** A total of 128 measurements were done in 36 hands of 30 patients. Postoperative follow-up measurement was done from 1 month to 35 months (mean 7.2 months). Preoperative TIR was from 0.046 to 0.784 (mean 0.531). Increased TIR was observed in postoperative follow-up, which was more conspicuous in low preoperative TIR. Prognostic factor for TIR improvement was evaluated by time response analysis. Thenar atrophy was significant negative factor in univariate analysis. Gender (female) and abnormal electromyographic findings of abductor pollicis brevis was significant negative factor in multivariate analysis.

CONCLUSIONS: Measurements of median nerve motor function using load cell is a valuable evaluation tool in CTS. It is helpful in detecting improvement of motor function after operation. The measurement can be done repeatedly without any discomfort accompanying in EDS.

OP-076[Spine and Peripheral Nerve Surgery] MICRODISCECTOMY AND INTERSPINOUS DEVICE VERSUS MICRODISCECTOMY ALONE FOR LUMBAR HERNIATION RECURRENCE: A COMPARATIVE EFFECTIVENESS STUDY

Carlo Antonio Todaro
Neurospine Center, Istituto Clinico San Siro, Milano, Italy

INTRODUCTION - OBJECTIVE: BACKGROUND CONTEXT: Currently no studies directly compare effectiveness between interspinous devices (IDs) and discectomy (D) in lumbar herniation recurrence (LHR) patients.

PURPOSE:

To compare reoperations, complications, and costs between LHR patients undergoing D and IDs placement versus D alone.

METHOD: STUDY DESIGN:

Retrospective comparative study.

PATIENT SAMPLE:

The Sansiro database (2009-2011) was queried for adults with LSS undergoing D and IDs placement as a primary inpatient procedures.

OUTCOME MEASURES:

Reoperation rates, complication rates, and costs.

RESULTS: Among 498 inpatients that underwent D+ IDs placement between 2009 and 2011; the average age was 73 years. The cumulative reoperation rates after D+IDs at 12 and 18 months were 21% and 23%, respectively. The average inpatient hospitalization lasted 1.6 days with an associated cost of \$17,432. Two propensity-matched cohorts of 174 patients that had undergone D+ IDs versus D were analyzed. Longer length of stay was observed in the D cohort (2.5 days vs. 1.6 days, $p < .0001$), whereas IDs patients accrued higher costs at index hospitalization (\$17,674 vs. \$12,670, $p = .0001$). Index hospitalization (7.5% vs. 3.5%, $p = .099$) and 90-day (9.2% vs. 3.5%, $p = .028$) complications were higher in the D cohort compared with the D+IDs cohort. The D+ ID patients had significantly higher reoperation rates than D patients at 12 months follow-up (12.6% vs. 5.8%, $p = .026$) and incurred higher cumulative costs than D patients at 12 months follow-up (\$39,173 vs. \$34,324, $p = .289$).

CONCLUSIONS: Twelve-month reoperation rates and index hospitalization costs were significantly higher among patients who underwent D+IDs compared with D for LHR.

OP-077[Spine and Peripheral Nerve Surgery] SURGERY FOR LUMBAR DISC HERNIATION: RESULTS IN 114 PATIENTS

Keneshbek Yrysov, Bakytbek Turganbaev
Kyrgyz State Medical Academy, Dpt. Neurosurgery

INTRODUCTION - OBJECTIVE: In this study were analysed results of clinical and diagnostic examinations, and neurological treatment of 114 patients with Lumbar Disc Herniation (LDH). The aim of the present study was to assess clinical outcome in patients with LDH; to investigate whether there is a difference in outcome with regard to the surgical approach (interlaminar, hemilaminectomy, laminectomy).

METHOD: Between 2001 and 2013, 114 patients were diagnosed with LDH and operated on using posterior approaches. Among these patients were 64 men and 50 women. Patient's age varied from 20 to 60 years, more persons are within 25-50 years, mainly men. In their clinical picture prevailed symptoms of neurological complications.

RESULTS: The patients had posterolateral LDH in 98, paramedian in 30, and central in 33 cases. The surgery was performed using interlaminar approach in 53, hemilaminectomy in 52, and laminectomy in 9 patients. Recent follow-up studies were obtained by standardized questionnaires. Long-term follow-up was available for 75 of the 114 patients (66%) at mean of 4 years. Twenty-four patients had an excellent result (32%), thirty patients had a good result (40%), fifteen patients a fair (20%), and six patients had a poor result (8%). Overall, the operation was considered successful in 72% of the patients.

CONCLUSIONS: There was statistically significant difference in outcome in patients with enlarged surgical approach as compared with those with interlaminar removal (72% versus 34.2%). Postoperative outcome of LDH presenting with neurological complications is poorer as compared with other types of LDH.

OP-078[Spine and Peripheral Nerve Surgery] TOTAL SPONDYLECTOMY. A NEW SURGICAL TECHNIQUE FOR VERTEBRAL TUMORS

Viktor Aleinikov, Talgat Kerimbayev, Yermek Urunbayev, Yermek Kissayev, Baurzhan Yerezhepekov
Department spinal neurosurgery, pathology of PNS, National Centre for Neurosurgery, Astana, Kazakhstan

INTRODUCTION - OBJECTIVE: A new surgical technique of total spondylectomy for complete, resection of primary spinal malignant and secondary (metastatic) tumors for oncologic curability is given in this report.

METHOD: The study of thirty five patients with primary malignant or benign aggressive and second (metastatic) tumors who underwent a new aggressive surgical technique termed "total spondylectomy" is reported. The goal of total spondylectomy is to remove the entire segment of the spine along with the tumor. Assessment of the results performed with ASIA / Frenkel scale and Karnofsky scale. Mean follow-up was 18 months, 6 months to 3 years.

RESULTS: All patients, except one, attained significant clinical improvement after surgery with no major complications. One patient with atypical Ewing's sarcoma was operated twice due to recurrence. Histologically, the margins were wide or marginal except for the pedicles, and occasionally the spinal canal and the posterior, where they were accepted to be intralesional. There was no local recurrence in other cases.

CONCLUSIONS: Our experience shows the importance of the total removal of the entire segment of the spine along with the tumor. The advantages of total en bloc spondylectomy include resection of the involved vertebra(e) in two major blocs, rather than in a piecemeal pattern, and completion of the procedure during one surgical session posteriorly. This technique allows removing of the tumor radically, with low recurrence rates and spinal cord protection. The "total en bloc spondylectomy" offers one of the most aggressive modes of therapy for primary spinal malignancy.

OP-079[Pediatric Neurosurgery]

MANAGEMENT OF RECURRENT CEREBRAL NEUROEPITHELIAL TUMORS IN CHILDREN

Aleksandr Kim

Russian Neurosurgery Research Institute named after A.L. Polenov, St. Petersburg, Russia

INTRODUCTION - OBJECTIVE: Maximized tumor resection and minimized surgical morbidity are extremely important in the treatment of children with neuroepithelial tumors. However, the indications for repeat surgery for these tumors remain unclear. Nowadays there are some alternatives in regrowth of neuroepithelial tumors management.

Aim: To investigate the clinical significance and limitations of repeat resection for neuroepithelial tumors.

METHODS: The results of examinations and treatments of 182 patients aged less than 18 years were analyzed. In these patients recurrent tumor removal, decompressive treatment, radiotherapy, and chemotherapy were carried out.

RESULTS: A retrospective analysis found out that the effectiveness of different methods depends on histostructure, size, location, types of neoplasms growth, constitutional features of patients, peculiarities of previous operation and its results, severity and course of hypertension-hydrocephalic-dislocation syndrome.

CONCLUSIONS: Radical surgery is effective and advisable for nodular neoplasms, in the absence of metastasis, in cases of benign or relatively benign tumors (I-II grade), and in the absence of brainstem or basal ganglia involvement.

Palliative treatment was reasonable in case of hydrocephalus and/or hypertension-dislocation syndromes in patients with decompensation, infants and the elderly. Radiotherapy is effective in small neoplasms and in neoplasms remote from the eloquent structures. Oncological therapy is indispensable for malignant tumors, especially in radiosensitive tumors and in the presence of metastasis.

OP-080[Pediatric Neurosurgery]

MANAGEMENT OF SHUNT INFECTION IN CONGENITAL HYDROCEPHALUS

Mohamed Natheer Saeid

department of neurosurgery, ibn-sina teaching hospital, mosul, iraq

INTRODUCTION - OBJECTIVE: To analyze etiology, clinical features, pathogens, mortality, morbidity and modalities of treatment of ventriculo-peritoneal (VP) shunt infections in congenital hydrocephalus

METHOD: Prospective case series descriptive study was carried out in the department of Neurosurgery, mosul teaching hospital, from jan 2011 to Jan 2013, the patients with vp shunts infection was studied Once infection was suspected, a cerebrospinal fluid (CSF) sample was taken and once infection confirmed, The management protocol consisted of:

- The removal of the infected shunt and EVD system putted and antibiotic
- Or without removal of v-p system just antibiotic and tapping if needed
- Use of IV antibiotic and wound debridement, re-stitching and dressing without shunt removal in patients presented with wound infection

RESULTS: • The incidence of age: 69.44% below 1year. and 30.6% were between the age of 1-2 years
• Time between the surgery and the shunt infection: 61.11% were presented within 6 months of surgery and 38.88% presented between 6 months to 2 years.
• 13.8% (No. 5) died.

CONCLUSIONS: The most common bacteria isolated were gram positive organisms (staph. aureus). In cases with VP shunt infection it is essential to remove VP shunt and start systemic antibiotics and put new VP shunt after 3 free samples of CSF

VP shunt should be inserted under strict aseptic techniques

OP-081[Neurooncologic Surgery]

RATHKE'S CLEFT CYST: CHARACTERISTICS BASED ON THE CYST LOCATION WITH PRIMARY FOCUS ON RECURRENCE

Silky Chotai, Yi Liu, Pan Jun, Songtao Qi

Nanfang Hospital, Southern Medical University, Guangzhou, China

INTRODUCTION - OBJECTIVE: Rathke's cleft cyst (RCC) are benign lesions located entirely intrasellar (IS), IS with suprasellar extension (IS+SS) and purely suprasellar (SS) location. The present study was conducted to analyze the predictors of squamous metaplasia (SM) and recurrence in RCC.

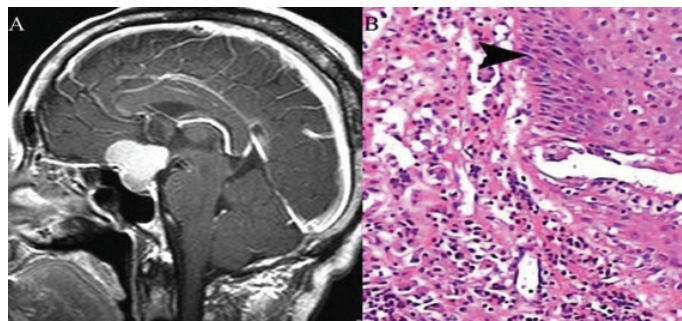
METHOD: A retrospective review of medical records was conducted for 87 patients with symptomatic RCCs. The effect of SM on recurrence in each location was analyzed.

RESULTS: Sixteen patients had an IS RCC, 21 SS, and 50 IS+SS RCC. Mean cyst diameter was 3.1 ± 0.9 cm. Transphenoidal approach was employed for all IS and (33/50) IS+SS RCCs and transcranial for all SS and (17/50) IS+SS RCCs. SM was present in 27/87, which was associated with SS location ($P=0.003$), size ($P=0.023$), hypointensity on T1 (16/27, $P=0.005$) and isointensity on T2-weighted (19/27, $P=0.002$), and ring enhancement on gd-enhanced MRI ($P=0.001$). The SS location ($P=0.018$, OR=3.4, CI-1.2-9.5), size >3.5 cm ($P=0.03$, OR=0.4, CI=0.2-0.93) and ring enhancement on MRI ($P=0.002$, OR=5.2, CI=1.8-14.9) were predictors of SM. The time to recurrence (7/87, figure) was 14 ± 6 months. The RFS was 84.5% at mean 98.2 ± 4.6 months. The age group ($P=0.02$, OR=3.8, CI-1.1-12.2) isointensity on T2-weighted MRI ($P=0.031$, OR=0.097, CI-0.012-0.8), SM ($P=0.001$, OR=34.7, CI-4.1-290.6), SS RCC ($P=0.018$, OR=4.8, CI=1.3-18.1), SS and IS+SS RCC with SM ($P=0.003$, OR=16.1, CI=2.5-101.3) ($P=0.02$, OR=4.9,

CI=1.2-18.9) were predictors of recurrence.

CONCLUSIONS: The SS location and the ring enhancement on the MRI were predictors of SM. Age group (<18 years), isointensity on T2-weighted MRI, the SM, SS RCC with and without SM, IS+SS RCC with SM were predictors of recurrence. The extent of resection and type of surgical approach used was not associated with recurrence.

Figure



a) T1-weighted gadolinium enhanced sagittal MRI showing recurrent RCC, b) Photomicrograph of cyst wall showing squamous metaplasia (black arrowhead).

OP-082[Pediatric Neurosurgery]

ENDOSCOPIC THIRD VENTRICULOSTOMY: DOES IT REPLACE VENTRICULOPERITONEAL SHUNT IN OBSTRUCTIVE HYDROCEPHALUS?

Muhammad Usman, Mumtaz Ali

Department of Neurosurgery, Postgraduate Medical Institute, Lady Reading Hospital, Peshawar-PAKISTAN

INTRODUCTION - OBJECTIVE: The objective of this study is to analyze whether endoscopic third ventriculostomy (ETV) has replaced ventriculoperitoneal (VP) shunt for treating obstructive hydrocephalus or not.

METHOD: This observational study was conducted in Neurosurgery Department of Post Graduate Medical Institute, Lady Reading Hospital Peshawar from May 2010 to April 2012. Patients with obstructive hydrocephalus due to aqueductal stenosis, tectal and non-tectal tumor were included in the study, while patients with blocked shunt, congenital hydrocephalus and post-infectious were excluded. The choice of CSF diversion procedure, either ETV (Group A) or VP shunt (Group B) was randomly assigned. A minimum follow up of 6 months was done. Data was analyzed using SPSS software version 17.

RESULTS: There were 155 patients, 72 males and 83 females in Group A, while total of 147 patients in Group B. Success rate in terms of clinical and/or radiological improvement was 71% and 67% in Group A and Group B respectively. Complications were seen in 18 patients including mortality in 3 patients in Group A, while in group B the complication rate was 15%.

CONCLUSIONS: ETV has replaced VP shunt; furthermore it is effective, safe, economical and successful procedure in patients with obstructive hydrocephalus as an initial line of management.

OP-083[Pediatric Neurosurgery]

ENDOSCOPIC MANAGEMENT OF THIRD VENTRICULAR ARACHNOID CYST MIMICKING AQUEDUCTAL STENOSIS

Bilal Khan Afridi, Mohammad Idris Khan, Mumtaz Ali

Department of Neurosurgery, Govt. Lady Reading Hospital, Peshawar, Pakistan.

INTRODUCTION - OBJECTIVE: to know about endoscopic management of third ventricular arachnoid cysts (AC) presenting as Aqueductal Stenosis (AS)

METHOD: this cross sectional study was conducted in our department between May 2010 and February 2014. All the patients who had undergone Endoscopic treatment for Hydrocephalus were reviewed regardless of gender and age. Those patients who had an AC of the third ventricle treated endoscopically were included and those with primary stenosis were excluded from the study. The clinical sheets were reviewed and the mode of diagnosis i.e. whether pre-op imaging or per-op endoscopy were recorded. Operative notes were also retrieved and type of the procedure and complications if any were also recorded on a designed proforma. Data was expressed in the form of frequency and percentages.

RESULTS: of the total 218 patients treated endoscopically for AS during the study period 13 (5.96%) were harboring an AC. Age range was from 3 to 14 years and there were 8 males and 5 females with a male to female ratio of 1.6:1. Pre-op imaging in the form of CT or MRI was done in all (100%). AC was diagnosed on pre-op imaging in 8 (61.53%) while in 5 (38.47%) it was diagnosed per-operatively. All patients (100%) undergone ventriculostomy with coagulation of the cyst wall and cystosternotomy (CC). The patients remained admitted for 2 days and one patients developed meningitis (7.69%) who succumbed to it.

CONCLUSIONS: AC can mimic AS in a small but considerable number of patients and AS should be preferably treated endoscopically to prevent diagnostic dilemma and management pitfalls.

OP-084[Pediatric Neurosurgery]

VENTRICULOSUBGALEAL SHUNT FOR TEMPORARY CEREBROSPINAL FLUID DIVERSION IN TREATING PEDIATRIC TUBERCULOUS HYDROCEPHALUS: A SINGLE CENTRE EXPERIENCE AND REVIEW

Vinodh Vayara Perumall, Rahmat Harun Haron, Pulivendhan Sellamuthu
Department of Neurosurgery, Hospital Queen Elizabeth II, Kota Kinabalu, Sabah, Malaysia.

INTRODUCTION - OBJECTIVE: Hydrocephalus can develop in cases of pediatric tuberculous meningitis and has high morbidity. CSF diversion is usually indicated due to rapid deterioration.

OBJECTIVE:

1. Proving that ventriculosubgaleal shunt (VSGS) is a better temporary CSF diversion method in treating pediatric tuberculous hydrocephalus.
2. Reducing number of surgical procedures and hospital stay duration.

METHOD: 1. Pediatric patients presenting with hydrocephalus secondary to tuberculous meningitis are enrolled over one year period.

2. VSGS using a standard technique with a subgaleal pocket size of 10x10cm is done.

3. Patient follow up done at two weeks after discharge and subsequently at first and third month before deciding for permanent shunt.

RESULTS: Total of 16 patients were enrolled. Mean duration of patients on VSGS is 53.8 days. VSGS was used as an alternative in three patients presenting with infected ventriculoperitoneal shunt (VPS) which allowed a shunt free period of two months temporarily before VPS reinsertion. 10 patients needed permanent VPS after a mean duration of 49.7 days while VSGS rendered three patients free from VPS. Mean duration of hospital stay is 7.4 days. Four patients developed complication with VSGS. Two patients had persistent hydrocephalus and VPS was done in less than 15 days. One patient developed tense subgaleal pocket which led to CSF leakage and another patient developed early fibrosis and closure of the subgaleal pocket requiring VPS for both.

CONCLUSIONS: VSGS is a better temporary CSF diversion technique and can be used even in the presence of infection. Repeated surgeries not needed as such done for external ventricular drainage (EVD).

OP-085[Neurovascular Surgery]

USING LOW-FLOW AND HI-FLOW ANASTOMOSES IN SURGERY OF GIANT AND COMPLEX CEREBRAL ANEURYSMS

Andrei Vladimirovich Dubovoy, Vladimir Guzhin, Shalinder Aul, Konstantin Sergevich Ovsyannikov, Artem Michalvich Perfilov
Federal Neurosurgical Center, Novosibirsk, Russia

INTRODUCTION - OBJECTIVE: to improve the results of microsurgical treatment of patients with complex and giant cerebral aneurysms

METHOD: During 2013 in our clinic 25 patients underwent surgery with giant and complex aneurysms of the cerebral arteries. The study group included patients with aneurysms that have broad or atherosclerotic calcification of neck, partially thrombosed aneurysms, with perforating or daughter branches arising from the aneurysmal sac, giant aneurysm (more than 25 mm in diameter).

RESULTS: During the surgery of above mentioned aneurysms it is often necessary to use a temporary parent artery clipping, sometimes it can be lengthy. In cases where you cannot use fractional temporary clipping, in order to provide collateral artery perfusion subjected to temporary clipping, using the imposition of low-fl w anastomosis most often between one or two branches of the superficial temporal artery and the cortical segment of the middle cerebral artery was used. In neither case, clipping for a long time did not cause any focal neurologic deficits, although its duration was 38 minutes. In cases of low-lying anterior circulation aneurysms, we used full (proximal and distal) trapping of the portion of artery with aneurysm, pre-creating hi-fl w bypass anastomosis between the cervical carotid artery (external or common) and middle cerebral artery (M2 or M3 segment). Basin of ipsilateral anterior cerebral artery in these cases perfused through the anterior communicating artery.

CONCLUSIONS: Using techniques of preventive revascularization of distal arterial bed in the surgery of complex and giant aneurysms of the cerebral arteries, helps prevent ischemic complications associated with prolonged temporary artery clipping.

OP-086[Neurovascular Surgery]

MANAGEMENT OF INTRA-OPERATIVE ANEURYSMAL RUPTURE - IS THERE A WAY TO PRACTICE / SIMULATE IT IN THE LAB?

Firas Hammadi¹, Ali Ayyad¹, Phillip Dodier², Emad Aboud³

¹Mainz University Hospital

²Medical School of Vienna

³ANI Arkansas Neurological Surgery Institute

INTRODUCTION - OBJECTIVE: Intraoperative rupture of intracranial aneurysm represents unexpected and sometimes disastrous complication.

The incidence rates vary between 6-40% of, recent studies referred to rate of 9.2% the risk of intraoperative rupture is affected by aneurysm location, SAH, temporary arterial occlusion and of course certainly to surgeon experience & technical skills. We present cadaveric training model to teach residents on how to manage intra-operative aneurysmal ruptures.

METHOD: Artificial aneurysms were made and placed in anterior circulation (MCA, ICA bifurcation, PcomA & paraclinoid region) on cadaver heads prepared according to the Live Cadaver (Perfused Cadaver). 40 residents were trained how to deal with artificial aneurysm rupture, each resident put to follow a sequence of actions on how to clip aneurysm in many different options then the aneurysm forced to bleed on him while dissection in similar fashion of what might happen during surgery.

RESULTS: Artificial aneurysms modeled in the anterior circulation on cadaver heads prepared according to the Perfused Cadaver technique. Primarily in theory, different clipping tenets and technical strategies were demonstrated and practised. The next practical steps consisted in approaching and dissecting the cadaveric aneurysm model. The latter eventually ruptured in a realistic fashion.

CONCLUSIONS: Most of residents performed the clipping procedure correctly. Even less experienced residents who never did it before. Their microsurgical skills were not at the level needed, after training session residents felt more confident clipping an aneurysm, realize how important is to practice microsurgical skills in labs using simulation. The Live Cadaver is unique and efficient training and simulation tool for the management of intra-operative vascular injuries and aneurysmal rupture.

OP-087[Neurovascular Surgery]

URGENT SURGICAL TREATMENT OF ACUTELY RUPTURED MCA ANEURYSM WITH HEMATOMA IN POOR GRADE PATIENTS

Sailike Duishanbai, Zengliang Wang, Kai Zhou, Bo Liu, Yongxin Wang, Dangmurenjiafu Geng
Department of Neurosurgery, First Teaching Hospital of Xinjiang Medical University

INTRODUCTION - OBJECTIVE: To discuss possible treatment regimen for the acutely ruptured MCA aneurysm with hematoma formation in 38 patients.

METHOD: All ruptured MCA aneurysm with hematoma patients (Hunt -Hess Grade III - V) were received microsurgical clipping at emergency basis from July, 2012 to December, 2013. Operative procedures included clipping the aneurysm, evacuation of intracerebral hematoma and ipsilateral frontotemporal craniectomy. Clinical outcomes were evaluated with GOS score and Glasgow Outcome Scale (GOS).

RESULTS: Good recovery were achieved in 34 cases, moderate morbidity in 3 cases, severe morbidity in 1 case evaluated by Glasgow Outcome Scale (GOS). There were no patient leave in vegetative state or death.

CONCLUSIONS: Concurrent Hematoma evacuation, ipsilateral frontotemporal craniectomy and clipping acutely ruptured MCA aneurysm is the best treatment regimen for the acutely ruptured MCA aneurysm with hematomas in poor grade patients.

OP-088[Neurovascular Surgery]

MINIMAL INVASIVE NEUROSURGERY TECHNIQUE FOR A BRAIN REVASULARIZATION AND ITS NEUROBIOLOGICAL BASIS IN NON-ATHEROSCLEROTIC / MOYA-MOYA DESESES

Slavodsky Alexander
Department of Neurosurgery, Alexandria Clinic, Moscow, Russia

INTRODUCTION - OBJECTIVE: To study possibility of carrying out minimum invasive technique for a Brain Revascularization in non-atherosclerotic/moya-moya patients and also to try to find out neurobiological bases underlying indications to such surgeries.

METHOD: In total 32 patients with neurologic/psychiatric pathologies. Men 23, women-9. Age from 4 months to 33 years. Studied anamnesis, complaints and their communication with transferred perinatal hypoxic-ischemic injury of brain injury (GI-BI). Besides routine researches, conducted research of CBF using TCD. On MRI precisely studied in FLAIR a condition of periventricular space, white matter (WM), ventricular system (VS) and their communication with a clinical picture, results of CBF researches, existence in anamnesis of hypoxemic factors. All patients were subjected to neurosurgery treatment according to own patent method, applying minimum invasive technique of brain revascularization (BR). It consists in one-stage consecutive ligation of all branches of external carotid arteries on periphery of edges of hairy part of head. Thus there is redirection of part of arterial blood fl w in system of internal carotid arteries pool. Unsuccessfulness of earlier carried out therapy was indication to surgery as whole.

RESULTS: In this series most patients the transferred perinatal GI-BI. TCD revealed signs of ischemia of brain. Studying MRI data showed various phenomena in periventricular space and in WM closely connected with VS were defined. Especially well it was visible on FLAIR. At all patients of undergone BR positive clinical symptomatology after carried-out surgery is noted.

CONCLUSIONS: It is obvious that not only patients with occlusive defeats of main arteries of a brain need in BR, but also other neurologic/psychiatric pathology

OP-089[Neurovascular Surgery]

THE "NO-DRILL" TECHNIQUE OF ANTERIOR CLINOIDECTOMY: A CRANIAL BASE APPROACH TO THE PARAOLINOID AND PARASELLAR REGION

Dongwoo John Chang
Illinois Neurological Institute/OSF Healthcare System

INTRODUCTION - OBJECTIVE: A high-speed power-drilling technique of anterior clinoidectomy has been advocated in all publications on paraclinoid region surgery. The entire shaft of the power drill is exposed in the operative field; thus, all neurovascular structures in proximity to any portion of the rotating drill bit are at risk for direct mechanical and/or thermal injury. Ultrasonic bone removal has

been developed to mitigate the potential complications of power drilling techniques. However, ultrasound-related cranial neuropathies are recognized complications of its use along with cost issues thereof.

METHOD: A retrospective review of a cerebrovascular/cranial base fellowship-trained neurosurgeon's 80 consecutive cases of anterior clinoidectomy using the "no-drill" technique is presented. Clinical indications have been primarily aneurysms, but also included neoplastic lesions and other miscellaneous cases. A bony opening is made in the mid-to-posterior orbital roof after the initial pterional craniotomy. Periorbital is dissected off the bone from inside the orbital compartment. Subsequent piecemeal resection of the medial sphenoid wing, anterior clinoid process, optic canal roof, and optic strut is performed with bone rongeurs of various sizes via the bony window thus made.

RESULTS: No power drilling was used in this surgical series of anterior clinoidectomy. Optimal exposure was obtained in all cases to complete aneurysm clippings and lesionectomies. There were no cases of direct injury to surrounding structures with this technique. Illustrative cases and images are presented along with surgical technique.

CONCLUSIONS: Power drilling is generally not necessary for anterior clinoidectomy. The no-drill technique is arguably the gentlest and most efficient method for exposing the paraclinoid/parasellar/pericavernous region.

OP-090[Neurovascular Surgery]

CLINICAL OUTCOMES OF VASCULAR MALFORMATIONS MICROSURGICAL RESECTION: EXPERIENCE OF 127 PATIENTS

Anas Abdallah, Murad Asiltürk, Erhan Emel, Betül Güler, Hasan Burak Gündüz, Mustafa Levent Uysal, Müslüm Güneş, Özden Erhan Sofuoğlu, İlhan Aydın, Rashid Avyasov, Fatih Cesur
Bakırköy Research and Training Hospital for Neurology Neurosurgery, and Psychiatry, Department of Neurosurgery, İstanbul, Turkey

INTRODUCTION - OBJECTIVE: The past 2 decades have seen great advances in understanding of the pathophysiology, classification, nomenclature, and treatment of intracranial vascular malformations. Surgical choice is microsurgical resection. In this study microsurgical resection treatment outcomes of 127 patients have been presented.

METHOD: Medical records were retrospectively reviewed in 127 (62 women, 65 men) consecutive of intracranial vascular malformation who operated between the years 2006 and 2013 have been evaluated. Patients' complaints, localization, pre-postoperative neurological examination, grades of Spetzler-Martin scale, surgical outcomes and complications were analysed. All patients underwent a craniotomy then microsurgical total resection after undergoing DSA, if there is suspicion of residue parts, control DSA was performed. If the lesion is in deep localization stereotactic guide was used. After resection had classified them as histological examination.

RESULTS: The mean age was 37 (7-85) years. Patients classified in four groups: Arteriovenous malformation (80), Cavernous hemangioma (39), Venous angioma (3), Arteriovenous fistula (2), and one patient thought to be CH but histological examination showed that was malign melanoma. The most common complaints were generalized seizure and headache. The most common localization of AVM is frontal (32). The most common grade is Spetzler-Martin 3 (35). The most common localization of CH is frontal (15). Mortality rate of AVM was 6.25% (5), morbidity rate of AVM was 30% (24).

CONCLUSIONS: The primary treatment of choice for the majority of intracranial vascular malformation especially those presented with clinical symptoms is gross-total resection. If the localization of lesion is deep and eloquent of adjacent brain stereotactic guide is recommended.

OP-091[Spine and Peripheral Nerve Surgery]

PREVENTION OF MOTONEURON DEATH AND MITOCHONDRIAL DYSFUNCTION AT SPINAL VENTRAL HORN AFTER C7 SPINAL ROOT AVULSION IN RATS WITH TAXOL

Sze Kiat Sim, Yew Chin Tan, Jong Huat Tee, Abdul Aziz Yusoff, Jafri Malin Abdullah
Department of Neurosciences, Universiti Sains Malaysia, Kelantan, Malaysia

INTRODUCTION - OBJECTIVE: Functional outcome following surgical repair in brachial plexus avulsion injury remains poor. Post-injury oxidative damage with spinal motoneuron death and mitochondrial dysfunction has been identified as the neurobiological barrier to functional restitution. This study was designed to evaluate the neuroprotective effect of intrathecally infused Taxol, a diterpene alkaloid, in the prevention of motoneuron death and mitochondrial dysfunction following brachial plexus avulsion injury.

METHOD: Sprague-Dawley rats were divided into Treatment and Control groups (each group N=32). Brachial root avulsion injury was induced in each rat. Treatment group received 5 days intrathecal infusion of Taxol (256ng/day) via a micro infusion pump, whereas Control group received normal saline. Cervical cord was harvested at survival interval of 1 week, 2 weeks, 4 weeks and 6 weeks (n=8 in each subgroup). Number of surviving motoneurons and nNOS-positive motoneurons at injured ventral horn were determined with NADPH-d histochemistry with neutral red counterstaining. Mitochondrial function at the injured ventral horn was measured with CcO histochemistry and densitometer. Independent t-test was applied to detect differences between the study groups at specific survival interval.

RESULTS: Compared to Control group, the Taxol treated group showed significant reduction in the nNOS expression at 2 weeks, 4 weeks, and 6 weeks, and significantly improved mitochondrial functions at 4 weeks and 6 weeks. The motoneurons survival rate was significantly increased at 2 weeks, 4 weeks, and 6 weeks in Taxol treated rats.

CONCLUSIONS: Taxol has the neuroprotective effect to prevent spinal motoneuron degeneration following brachial plexus avulsion injury by inhibiting nNOS expression and reduced mitochondrial dysfunction.

OP-092[Spine and Peripheral Nerve Surgery]

SURGICAL TREATMENT OF FBSS AFTER LUMBAR DISCECTOMY

Shuhrat Halikov Ashurovich

Department of Pathology of spine and spinal cord. Republican Scientific Centre of Neurosurgery. Tashkent. Uzbekistan.

INTRODUCTION - OBJECTIVE: To determine optimal ways of surgical treatment of failed back surgery syndrome (FBSS) after lumbar discectomy.

METHOD: FBSS is a long or repeated chronic pain in a lower part of back and/or legs after a successful from anatomical point of view operation on spine. In the research there were comprised 36 patients, operated on recedives of pain syndromes. Repeated surgical interventions were decompressive and decompressive-stabilizing spine interbody spondilodesis, with cage and intraspedicular systems. The results of recedives' treatment were studied in period from 6 to 24 months. The dynamics of neurologic status, intensity of pain syndrome were judged by visual-analog scale.

RESULTS: Basic reason of FBSS's recedives were hernia of operated discs (52,8%) and their combination with degenerative stenosis (9,7%). In an isolated degenerative stenosis is a reason of recedives (21,6%). FBSS often became the reason of pain syndrome in the first two years after operation. Degenerative stenosis, as in an isolated, also in combination with the hernia of operated disc, often happened in the later period. Pathomorphologic substrate of stenosis was hypertrophic facet joint, arcus of vertebra, osteophytes, thicken yellow ligament, peridural fibrosis. The results of treatment were better within patients, who were performed decompressive-stabilizing operations. Repeated recedives of pain syndromes after performance of decompressive operations appeared in 9,8% cases, but after decompressive-stabilizing (posterior lumbar interbody spondilodesis) in 1,4%.

CONCLUSIONS: Decompressive-stabilizing operations with the performance of posterior lumbar interbody spondilodesis are considered optimal and technically adequate type of surgical treatment of FBSS after lumbar discectomy.

OP-093[Spine and Peripheral Nerve Surgery]

SURGICAL OUTCOME OF SPINAL TUMORS: A SERIES OF 124 CASES

Gopal Raman Sharma

Department of Neurosurgery, NAMS, Bir Hospital, Kathmandu, Nepal

INTRODUCTION - OBJECTIVE: This is the largest series of spinal tumor surgery produced in Nepal. Aim of this study is to discuss the results of spinal tumors after surgical resection.

METHOD: This is a retrospective study of 124 patients who were operated for spinal tumors from May 1999 to December 2012 at Department of Neurosurgery, Bir Hospital. Follow up period ranged from 15 months to 14 years.

RESULTS: There were 71 male and 53 female and age ranged from 6 to 79 years.

Out of 124 spinal tumors, 36 were extradural (ED), 66 intradural extramedullary (IDEM) and 22 intramedullary (IM). Among ED tumor Ewing's sarcoma, neurofibroma, metastatic lesions and angiolipoma were common. Schwannomas and meningiomas were common IDEM tumors. Common IM lesions consisted of ependymoma and astrocytoma.

On admission, 52 patients presented with pain, 88 with motor weakness, 43 with sensory deficit and 26 with sphincter dysfunction. Common location of lesions were thoracic, cervical and lumbar. Total excision of tumor was possible in 76.6% and partial excision in 23.4%.

14.5% suffered postoperative complications.

No surgery related death occurred in our series, however, 12 patients died within 6 months to 2 years period after surgery who had malignant pathologies.

Recurrence rate was 17.7%.

Regarding neurological outcome, 69.3% had improved neurological status, 20.2% remained stable and 10.5% deteriorated after surgery.

CONCLUSIONS: Surgical excision is best available treatment option for spinal tumors which provides histological verification, prevents further neurological deterioration, improves quality of life and directs further modalities of treatment if required.

OP-094[Spine and Peripheral Nerve Surgery]

CERVICAL ARTHROPLASTY- PRELIMINARY SINGLE CENTRE 6 YEAR STUDY

Ram Kumar Menon

Elite Mission Hospital

INTRODUCTION - OBJECTIVE: There is an ongoing debate about cervical arthroplasty or fusion in the treatment of single and bi-level cervical disc disease. This is mainly because long term results have to be available to justify the intended advantage of arthroplasty in the prevention of adjacent segment disease

METHOD: I present a short series of arthroplasty at 8 levels including two bi-level. The longest follow up was of 6 years and the shortest follow up was 3 months with a mean follow-up of 34 months. The primary outcomes measured in terms of arm pain, neck pain, patient satisfaction, and neurological outcome were excellent. The secondary outcome was measured in terms of fusion, revision surgery at treated level, secondary surgery at adjacent level, segmental mobility of treated and adjacent levels, and work status.

RESULTS: All of my patients achieved the primary & secondary goal.

CONCLUSIONS: As in the database studies published in literature my clinical results are in favour of arthroplasty as there is high quality evidence that the goal of segmental preservation of mobility is met but I need a larger and bigger series especially in the long term series (5 year and longer follow up)

Case distribution and follow up

Id/age/sex	level	Indication	Type of disc	Follow up (year)
S/27/m	C5-6	radiculopathy	P-LP	6
v/49/m	C6-7	radiculopathy	P-LP	4
s/42/f	C4-5/5-6	radiculopathy	P-LP	3
U/38/m	C5-6	myelopathy	P-LP	3.8
V.T/34/f	C5-6	radiculopathy	P-LP	1
B.S/38/f	C5-6/6-7	radiculopathy	PD-C	3/12

Table indicating case distribution

OP-095[Spine and Peripheral Nerve Surgery] INSTRUMENTATION IN SPINAL TUBERCULOSIS

Harjinder Singh Bhatoe
Max Super Speciality Hospital PPG, New Delhi 110092

INTRODUCTION - OBJECTIVE: Tuberculosis of the spine is the commonest form of extrapulmonary and skeletal tuberculosis. The severity of illness and spinal column involvement is varied, and the presentation is in the form of disabling axial pain, radicular pain, and varying severity of myelopathy. Myelopathy is due to compression of spinal cord in majority of the patients, and results from compression due to cold abscess, spinal deformity and angulation, spinal instability due to ligamentous involvement and granulations or sequestrum. Unusually, myelopathy is due to cord ischaemia and demyelination, or formation of an intramedullary abscess.

METHOD: This review is based on our experience in managing spinal tuberculosis over the last twenty five years. Tuberculosis can involve any segment of the spinal cord. While antituberculous chemotherapy remains the mainstay in management, spinal instrumentation is indicated for pain relief, ensuring early ambulation, prevention and correction of deformity, and obtaining a histopathologic confirmation in doubtful cases. Reexploration and definitive treatment can be carried out in patients who have undergone only abscess drainage and continue to have neurological deficits. Chemotherapy is instituted for 12-18 months.

RESULTS: Patients are seen to be pain free early, and can be mobilized out of bed within 3-5 days. There is distinct improvement in myelopathy with reversal of neurological deficits. In our experience there was no instance of implant failure or infection at the operated segment.

CONCLUSIONS: Early surgery and spinal instrumentation are recommended in patients with spinal tuberculosis, especially those with persistent pain, immobility, spinal deformity and neurological deficits.

OP-096[Spine and Peripheral Nerve Surgery] ANALYSIS OF THE CAUSES OF REVISION SURGERIES IN PATIENTS WITH DEGENERATIVE DISEASES OF THE LUMBAR SPINE

Evgeny Loparev, Vladimir Klimov, Alexey Evsukov, Djamil Rzaev, Roman Halepa, Ivan Vasilenko, Angelika Razmahina
FSBI "Federal Neurosurgical Center"

INTRODUCTION - OBJECTIVE: To study the structure and the reasons for reoperation in patients with recurrent clinical manifestations of degenerative diseases of the lumbar spine.

METHOD: 83 patients were operated for recurrent pain with neurological disorders in patients previously operated on for degenerative diseases of spine during one year. Average age of patients was 45 ± 7.4 years, duration of the previous surgery $\mu = 3.4$ (25%, 75%) = 0.8, 7.3 years. Neuroimaging techniques: X-ray in standard projections and functional tests, MRI and MSCT myelography.

To assess instability we used criteria by White, Panjabi, Modic, degree of stenosis on a scale Cschizas, degree of epidural fibrosis on classification of Ross. Allocated three dominant clinical neurological syndromes: neurogenic claudication, radiculopathy, instability of FSU. VAS of pain, ODI scales were applied before surgery, in 6 months after operation to assess the patient state.

RESULTS: Three groups of patients were formed:

1 - degenerative stenosis (47 patients (56.6%), of which 37 (44.6%) with true recurrent disc herniation, 5 (6.02%) with disease adjacent level 5 (6.02) with interspinous spacers. Osteoligamentary decompression was executed.

2 - with instability of FSU 33 (39.6%), recurrence of disc herniation 30 (36.1%), 2 (2.4%) after removal of disc herniation and PLIF, 1 (1.2%) after ALIF. Decompression was performed. PLIF, TPF were executed.

3 - (3.6%) combination of degenerative stenosis and instability, patients with interspinous clamps (DIAM 1 (1.2), Cofl x 2 (2.4%).

CONCLUSIONS: In 56.6% of cases, the main indication for a revision procedure is compression of the spinal canal structures.

OP-097[Spine and Peripheral Nerve Surgery] ANTERIOR DECOMPRESSION AND FUSION IN CERVICAL TUBERCULOSIS

Mumtaz Ali, Zahid Khan, Seema Sharafat
Department of Neurosurgery, PGMI, Lady Reading Hospital, Peshawar, Pakistan

INTRODUCTION - OBJECTIVE: To assess the results of anterior decompression and fusion in patients with cervical spine tuberculosis

METHOD: This Observational study was conducted in the Department of Neurosurgery Lady Reading Hospital, Peshawar from January 2011 to December 2013 (3 years). Adult Patients who underwent anterior decompression and fusion for cervical tuberculosis were included in the study. Those who were unfit for surgery, recurrent surgery or involvement of multiple non adjacent levels were excluded from the study. All patients were given anti tuberculous drugs for 18 months and were followed up for 2 years after surgery.

RESULTS: Twenty one patients underwent anterior decompression and fusion for cervical tuberculosis during the study period. They all presented with neck pain and 71.4% patients had preoperative neurodeficit of which 26.7% had complete motor weakness. Almost 80% of patients had neurological improvement after surgery. Iliac bone graft was taken in all patients and bony fusion was observed in all cases that completed follow up. One patient had donor site infection and one transient dysphasia.

CONCLUSIONS: Anterior decompression and fusion is one of treatment options in selected number of patients with cervical tuberculosis. it is safe having good results with few complications.

OP-098[Spine and Peripheral Nerve Surgery] OUR EXPERIENCE OF TREATING EXTRADURAL TUMORS OF THORACIC AND LUMBAR SPINE

Jamshid Mardanov Jahongirovich
Republican Scientific Center of Neurosurgery Uzbekistan, Tashkent

INTRODUCTION - OBJECTIVE: Urgency of the problem due to the high risk of pathologic fracture of the spine with the occurrence of neurological disorders (70%), the complexity of establishing an accurate morphological diagnosis (Zubarev A.JL, 1999; Myshkin OA 2002; Kallistov VE, 2003; Durov, OV, 2004).

METHOD: The work is based on the experience of the treatment of 120 patients operated on in the clinic spinal pathology Tashkent RSCN in 2008-2013. extradural tumors at the thoracic and lumbar spine. Among them were 62 (52%) men and 58 (48%) of women aged 16 to 68 years. All operations were carried out over the tumor from the posterior spinal access laminectomy - 119 (99.2%) and emilaminectomy - in one case (0.8%). Decompressive operations were performed in 52 (43.3%) and decompression- stabilizing - in 68 (56.7%) cases.

RESULTS: Performing decompression- stabilization operations provided the best in comparison with operations decompression treatment results. Unsatisfactory outcomes after decompressive operations occurred in 4.2%, and after stabilizing after decompressive- stabilizing - only 2.5% of cases. Results decompressive- stabilizing operations with the implementation of posterior lumbar and thoracic pedicle fusion in 97.5% of cases were assessed as good and satisfactory, and only 2.5% - as unsatisfactory.

CONCLUSIONS: 1. Decompressive- stabilizing operations with the performance of pedicle posterior fusion provides the ability to perform a full decompression of the neuro-vascular lesions and in 95% of cases of radiologically confirmed the stability of the operated spinal segments in the immediate and late postoperative period.

OP-099[Spine and Peripheral Nerve Surgery] RELATION BETWEEN CLINICAL AND RADIOLOGICAL OUTCOMES AFTER POSTERIOR FOSSA DECOMPRESSION FOR CHIARI 1 MALFORMATION TYPE

Ahmed Abdullah El Fiki, Hazim Mostafa Kamal
Department of Neurosurgery, Cairo University, Cairo, Egypt.

INTRODUCTION - OBJECTIVE: Chiari malformations are four different types of hind brain malformations; it was firstly described by Chiari in 1891. clinical presentation can start in childhood or adulthood and it is related to the area of compression. If cerebellar tonsils are primarily affected, patients will present with cerebellar signs and dural irritation, while cervical cord compression will result in long tract affection. the aim of this work is to evaluate the impact of post-operative clinical condition on follow up radiological images in Arnold-Chiari Malformation type 1.

METHOD: twenty two patients with chiari malformation type 1 including 16 patients with sryngomyelia were operated upon by posterior fossa decompression and duroplasty between January 2011 and February 2013, clinical evaluation pre & postoperative was observed at three and six months. Radiological signs including tonsillar size, retrocerebellar space and sryngomyelia reduction were evaluated in relation to clinical outcome.

RESULTS: improvement of effort and suboccipital headache was about 92%, patients presenting with sryngomyelia were improved in 72%. and there was direct relation between better outcome and radiological signs especially smaller tonsillar size, enlarged retrocerebellar space and reduction in sryngomyelia size.

CONCLUSIONS: tonsillar decent down to the cervical region was found to be a major cause of sryngomyelia. there is direct relation between clinical improvement and tonsillar shrinkage and enlargement of retrocerebellar space, dysesthetic upper limb pain and effort headache are the best

complain to improve while limb weakness and swallowing difficulties were among the latest finding to respond. Follow up radiologically gives satisfactory impression about outcome but long term evaluation is needed.

OP-100[Spine and Peripheral Nerve Surgery]

NON-SURGICAL MANAGEMENT OF PROGRESSIVE PARAPARESIS DUE TO DIFFUSE EXTRAMEDULLARY HEMATOPOIESIS (EMH) IN BETA-THALASSEMIA INTERMEDIA

Amir Azarhomayoun, Abbas Amirjamshidi, Saeed Saeednia

Department of neurosurgery, TUMS, Tehran, Iran

INTRODUCTION - OBJECTIVE: Thalassemia intermedia is mild form of thalassemia that usually present later in life and transfusion is occasionally needed in these patients. Erythropoiesis is increased in thalassemia causing erythroid marrow hyperplasia as well as EMH which is a common compensatory mechanism for chronic anemia found in such patients. EMH usually occurs in liver, spleen, kidneys and as paravertebral region. It is observed in 30%–60% of patients with thalassemia intermedia while involvement of the paraspinal region has a prevalence of about 11%–15% among these cases

METHOD: A 26 year old man with beta thalassemia intermedia developed pain in low back region with progressive paresthesia because of multifocal EMH which occurred all around the spinal canal with compression over the cord. This case was a recurrent one who had a previous episode of disease 6 years ago. The patient could be managed with repeated episodes of radiation to the spine and all the lesions disappeared in the last follow up.

RESULTS: Reporting this unique case and its characteristics, different aspects of a better treatment protocol in similar cases will be discussed. Management of recurrent neurological deficit due to EMH compressing the spinal cord has not been discussed in the literature previously

CONCLUSIONS: recurrent EMH can be managed either by radiotherapy, surgery, transfusion alone or a combination of them. decision may be individualized for each case.

OP-101[Spine and Peripheral Nerve Surgery]

ENHANCEMENT OF MANAGEMENT OF PATIENTS WITH SPINAL INJURIES COMPLICATED WITH INFLAMMATION OF URINARY PATHWAYS

Saydullo Sharifbaev¹, Rakhmon Egamberdiev², Zakhrudin Ashurov¹, Obidkhon Ismoilov¹, Ibrohim Jijanov¹, Ulugbek Haydarov¹, Athamjon Ismoilov¹, Komiljon Abdusattarov¹, Shuhrat Karimbaev¹

¹Namangan branch of Republican Research centre of Emergency Medicine, Namangan, Uzbekistan

²Republican research centre of neurosurgery, Tashkent, Uzbekistan

INTRODUCTION - OBJECTIVE: As a starting mechanism - bladder dysfunction contributes development of infectious-inflammatory complications in urinary pathways at patients with spinal traumas. One of the most serious complications is acute posttraumatic pyelonephritis.

METHOD: In the research 32 patients with spinal injuries with urinary complications were observed.

Infectious-inflammatory complications of urinary pathways have been caused by development of super infections, decrease in the general resistance and immunity of an organism, and also severity of traumatic injury that was accompanied by infringement of bladder innervations and decrease in its contractile functions. At 27 (84,3%) patients, despite conservative therapy, an acute urinary retention was not possible to relieve and epicystostomy operation has been performed.

RESULTS: As the result of complex treatment at 5 patients the improvement of urination and bacteriuria is noted. The volume of residual urine in these cases managed to be reduced to 150 ± 50 ml ($p < 0,05$). Clinical signs of acute pyelonephritis have been completely regressed, despite leukocyturia is preserved for a long time till 20 cells in one fields of vision ($p < 0,05$). During the dynamic inspection, at 5 patients the volume of residual urine has been completely eliminated. At 17 patients with acute urinary retention, despite epicystostomy and conservative treatment, acute pyelonephritis is developed.

CONCLUSIONS: Using complex treatment including stimulators of bladder contraction provides preventive maintenance of inflammatory displays and full sanitation of urinary pathways that in turn allows reduction of the period of hospitalization of patients.

OP-102[Miscellaneous]

EXPERIMENTAL RESEARCH OF HOST MACROPHAGE CANCERATION INDUCED BY GLIOMA STEM PROGENITOR CELLS

Liang Xing Dai, Jun Dong, Qing Lan, Qiang Huang

Department of neurosurgery, the second affiliated hospital of Soochow University, Suzhou, China

INTRODUCTION - OBJECTIVE: To explore whether the growth-promotion effects of macrophage towards tumors in the aggressive stage would work on its own canceration.

METHOD: Human glioma stem/progenitor cells transfected with red fluorescent protein gene (SU3-RFP) were seeded inside the abdominal cavity of transgenic nude mice, which all nucleated cells could express green fluorescent protein (GFP), forming the tumor model with RFP/GFP double-color fluorescent tracer. Cultured ascites and tumor nodules from tumor-bearing mice, then screened out the GFP+ cells for the clonal culture. Further, SU3-RFP and peritoneal macrophages were co-cultured in vitro. Both GFP+ cells and GFP+/RFP+ cells which were fused by tumor cells and host cells were cloned as before. Related phenotypic characterization and tumorigenicity tests were performed.

RESULTS: GFP+ cells, isolated from ascites and solid tumors, exhibited unlimited proliferative potential; the monoclonal cells were mouse-original, had a cancer cell phenotype and could express macrophage

marker protein CD68. And GFP+/RFP+ cells not only express macrophage marker CD68, but also express glioma stem cell marker nestin. And GFP+ cells were derived from GFP+/RFP+ cells by time-lapse observation.

CONCLUSIONS: In the abdominal tumor model with double-color fluorescent tracer, macrophages recruited by tumor cells not only could promote tumor cell growth, but also exhibited its own canceration. And fusion of the tumor cells and stroma cells maybe the mechanism of the malignant transformation. This discovery was important for the further study of tumor tissue remodeling and tumor microenvironment.

OP-103[Neurooncologic Surgery]

CLINICAL FEATURES AND IMAGING OF CSF PATHWAYS OBSTRUCTION AT DEEP BRAIN TUMORS

Ulugbek Asadullaev, Gayrat Kariev, Uygun Altibaev, Jahogir Yakubov, Javlon Tuhtamurodov, Bakhodir Babahanov, Bekzod Saidov, Rakhmon Egamberdiev

Republican Research centre of neurosurgery, Tashkent, Uzbekistan.

INTRODUCTION - OBJECTIVE: Introduction of endoscopic techniques has allowed to perform two step operations directed on liquidation of hypertensive hydrocephalus syndrome with subsequent removal of tumor after improvement of general condition of patient. The purpose is to improve results of surgical treatment of brain tumors by application of endoscopic techniques.

METHOD: Within 2007 – 2013, In The Republican Research Center of Neurosurgery 97 patients were observed. Depending on the methods of operative treatment patients were divided into 3 groups: 1-group: Endoscopic third ventriculostomy (ETV) with subsequent tumor removal. 2-group: ETV and Tumor removal after 7 – 30 days after stabilization of patient's conditions. 3-group: Tumor removal with the subsequent establishment of ventriculo-cisternostomy by Torkildsen.

RESULTS: At all 92 patients operated with the given method, after the first stage – ETV the condition of patients improved, because of liquidation of an intracranial hypertension. At 16 patients it was possible to perform radical removal of a tumor, 47 patients a subtotal resection. Good outcomes were received at 35 patients who had been discharged from hospital for 10-15 days after operation in good condition. At 12 patients because of instability of hemodynamics and respiratory infringements it was necessary to carry out intensive therapy within 5-7 days after which there has come positive dynamics, and patients also had discharged in a satisfactory condition.

CONCLUSIONS: Preliminary ETV at the tumors of posterior cranial fossae complicated with hydrocephalus, is an effective method and it can be applied as the first stage of operation to liquidation of an intracranial hypertension.

OP-104[Neurooncologic Surgery]

MANAGEMENT OF MALIGNANT TUMOURS OF PARANASAL SINUSES

Maryam H Esfehani¹, Maziar Motiee¹, Mohsen Nouri²

¹Cancer Research Centre, Cancer Institute of Iran, Tehran University of Medical Sciences, Tehran, Iran

²Department of Neurosurgery, Razi Hospital, Zahedan University of Medical Sciences, Saravan, Iran

INTRODUCTION - OBJECTIVE: Treatment of malignant lesions of the paranasal sinuses is always a challenge to the physicians addressing these lesions. Although chemotherapy and radiotherapy are important adjuncts in treating these lesions, the mainstay of treatment is still surgery. Due to covert growth of these tumours, many of them have invaded various compartments including intra-cranial fossa at the time of diagnosis requiring a multi-disciplinary surgical approach to them.

METHOD: Here, we present our experience over the last years from the only cancer institute in Iran which is a referral centre for such patients and discuss management of the cases that invade skull base, orbit, or intra-cranial compartment.

RESULTS: Patients with malignant tumors of paranasal sinuses were treated according to their location, extent of invasion, pathology, systemic burden of the disease, and life expectancy of the patient. Whenever indicated neoadjuvant or adjuvant chemo-radiation were applied.

CONCLUSIONS: Although, minimal invasive surgery has replaced radical operations in most surgical aspects, being less invasive to these tumours equals earlier recurrence, less survival, and more re-operations. Despite all the advances in their management at head and neck departments, most neurosurgeons are unfamiliar with their treatments.

OP-105[Neurooncologic Surgery]

5 YEARS OF ROUTINE INTRAOPERATIVE MRI APPLICATION IN ENDONASAL PITUITARY ADENOMA SURGERY

David Netuka¹, Václav Masopust¹, Daniel Horinek¹, Tomas Belsan², Vladimír Benes¹

¹Dept. of Neurosurgery, Central Military Hospital, Charles University, 1st Medical faculty, Prague, Czech Republic

²Unit of radiology, Central Military Hospital, Prague, Czech Republic

INTRODUCTION - OBJECTIVE: Endoscopic techniques seem to enable more radical endonasal resections of pituitary adenomas. Intraoperative MRI seems to help to increase the radicality as well. Many studies present selected cases with intraoperative MRI. We present almost non-selected series of pituitary adenomas treated endoscopically endonasally with intraoperative MRI.

METHOD: Prospective database, all sellar and parasellar lesions included. For evaluation histologically

proven adenomas treated in period 2009-2013 were selected. Altogether, 9 pituitary adenomas were resected transcranially, 437 endonasally. Intraoperative MRI was not performed in 24 cases (5,5%) due to various reasons (in majority of cases due to non-compatible pacemaker or other implant, extreme obesity, emergent night surgery, failure of transportation system, etc.). Altogether, 413 pituitary adenomas were resected endonasally with intraoperative MRI. The goal of the surgery (either radical or subtotal resection) was set before the day of surgery.

RESULTS: Radical resection was planned in 244 cases. Subtotal resection was planned in cases of cavernous invasion lateral to ICA, in parasellar of pituitary adenoma invasion, complex recurrent or multilobulated adenoma.

In 200 cases out of 413 any residual adenoma was disclosed on iMRI. Resection after intraoperative was performed in 104 cases (26%). Final rate of radical resection was 262 (63%). Complications: CSF leakage in 4,3%, unilateral amaurosis 0,4%, mortality 0,4%.

CONCLUSIONS: Routine application of intraoperative MRI is fully justified, enables to increase the rate of radical resections. Routine application of intraoperative MRI shows more clearly the value of this technique than highly selected series of intraoperative MRI. Supported by IGA 14256.

OP-106[Neurooncologic Surgery]

EPIDERMOID AND DERMOID CYSTS OF THE CENTRAL NERVOUS SYSTEM: SURGICAL RESULTS

Taras Havryliv¹, Volodymyr Smolanka²

¹Regional Clinical Center of Neurosurgery and Neurology, Uzhhorod, Ukraine

²Uzhhorod National University, Ukraine

INTRODUCTION - OBJECTIVE: Epidermoid and dermoid cysts of the central nervous system are usually developmental, benign tumors that arise when retained ectodermal implants are trapped by two fusing ectodermal surfaces. Together they comprise 1 - 1.5% of all brain tumors. The aim of the current study was to define the clinical course and results of surgical treatment of dermoid and epidermoid cysts, depending on their location and tumor type.

METHOD: A retrospective analysis of 16 consecutive surgical interventions on brain epidermoids and dermoids (4 dermoid cyst, 12 - epidermoid cysts) that were treated at the Uzhhorod Regional Clinical Center of Neurosurgery in the period from January 2009 to February 2013. Localization of the tumours: epidermoids (cerebellopontine angle - 6 patients, lateral sulcus - 4 patients, parietal lobe and spinal cord - 1 patient each); dermoid cysts (suprasellar - 3 patients, IV ventricle - 1 patient).

RESULTS: 13 patients underwent total removal of dermoid and epidermoid cysts, which was confirmed by control MRI, in 3 - a small part of the tumor capsule, closely linked with one of the large vessels of the brain was left. The median follow-up of the study was 3.1 years. The results of the treatment were assessed according to Karnofsky scale: more than 60 points - 16 patients.

CONCLUSIONS: The only effective treatment for epidermoid and dermoid tumors is surgical removal. Careful microsurgical removal of these tumors can achieve satisfactory results and long-term remission. There is no influence of tumor localization on surgical results of the treatment.

OP-107[Neurooncologic Surgery]

TRANSCRANIAL ENDOSCOPIC SKULL BASE SURGERY: OUR EXPERIENCE AND RESULTS

Yuri G. Shanko, Andrey L. Tanin, Arnold F. Smejanovich, Vitali A. Smejanovich, Eduard N. Vasilevich, Andrey I. Chuhonskij, Sergey K. Stankevich, Vladimir A. Zhuravlev, Ekaterina V. Odnobludova
Republican Research and Clinical Center of Neurology and Neurosurgery

INTRODUCTION - OBJECTIVE: To develop and to implement fully endoscopic transcranial techniques in skull base surgery.

METHOD: During the period from June 2013 to April 2014, we have developed and implemented a number of surgical approaches for fully endoscopic transcranial interventions in skull base surgery. Surgical procedures were carried out under monoportal access video monitoring using neuroendoscopic racks "Carl Storz" (Germany) with 0°, 30°, 45° optics; skin incision and soft tissues up to 5.0 cm, osteoplastic craniotomy between 1.5x2.0 cm (anterior and middle cranial fossae) to 2.0x2.0 cm (posterior fossa)

RESULTS: Using fully endoscopic transcranial technique we operated on 60 patients, among them there were 27 patients with tumors in the anterior cranial fossa (25 meningiomas and 2 craniopharyngiomas), 2 patients with nasal liquororrhea, 14 patients with meningiomas of the sphenoid bone wings, 14 patients with tumors of the posterior fossa (10 vestibular schwannomas, 4 pyramid rear surface meningiomas), 2 patients with trigeminal neuralgia and 1 - with sphenopetroclival meningioma (partial removal of the tumor in 72 year old patient).

Lethal outcome or inflammatory complications were not observed. Patient's rapid recovery took place after surgical interventions.

CONCLUSIONS: Initial experience in fully endoscopic transcranial interventions in skull base surgery indicates that this minimally invasive technology might become an alternative to standard microsurgical operations.

OP-108[Neurooncologic Surgery]

CRANIOPHARYNGIOMA REMOVAL VIA SUPRAORBITAL KEYHOLE APPROACH

Qing Zhu, Ailin Chen, Guodong Liu, Liang Xu, Qing Lan

Department of Neurosurgery, Second Affiliated Hospital of Soochow University, Suzhou, China

INTRODUCTION - OBJECTIVE: For anterior surgical approaches to the suprasellar lesions, a relative larger craniotomy was always required in order to facilitate illuminating deeply several years ago. The improvement of surgical techniques, as well as the development of diagnostic imaging and the introduction of neuroendoscope, allows us to manage various intracranial lesions through a small keyhole. Although the supraorbital keyhole approach has nowadays gained ground in the surgeries of aneurysms and pituitary adenomas at suprasellar region, there are few descriptions of craniopharyngioma removal via such approach.

METHOD: 17 patients with craniopharyngiomas were experienced 18 surgeries to remove lesions via the keyhole approaches, including 17 supraorbital and 1 pterional keyhole approaches. The head MRI, ophthalmological and endocrinological assessments were conducted pre- and postoperatively to evaluate therapeutic effects.

RESULTS: Total resection of craniopharyngioma in 12 surgeries and subtotal resection in 6 surgeries were achieved. Obstructive hydrocephalus in 5 cases was resolved in one session after removal of lesions. Visual acuity and visual field improved in 7 cases after operations, aggravated in 3 cases however, and 2 of them alleviated after hyperbaric oxygen therapy. 8 patients experienced postoperative electrolyte disorder and diabetes insipidus temporarily, and 1 patient suffered from disturbance of consciousness for two days after resection of lesion.

CONCLUSIONS: The supraorbital keyhole approach offers surgical possibilities with effective resection of lesion and less approach-related morbidity compared with the conventional craniotomy approaches in the surgery of craniopharyngiomas. It is most beneficial to remove lesions infiltrated into the third ventricle on account of recanalization of the obstructive cerebrospinal fluid pathway.

OP-109[Neurooncologic Surgery]

AMYGDALAEORIGINATED TUMORS A FORMIDABLE SURGICAL ENTITY, MICROSURGICAL TECHNIQUE TO SAVE FUNCTION AND CURE EPILEPSY LOCATED IN AMYGDAL REGION

Guive Sharifi, Seyed Ali Mousavinejad, Cooroush Gharegozli, Mohammad Samadian, Reza Jabbari, Omidvar Rezaie

department of neurosurgery, loghman hospital, shaheed beheshti university, tehran, iran

INTRODUCTION - OBJECTIVE: Mesial temporal structures are notorious causes of epilepsy and although they have placed in strategic anatomical location they have been removed ending to epilepsy control and even cure.

Amygdala well known element in limbic system has documented role in epileptogenesis located across the temporal horn just above the hippocampus and despite its famous neighbor has no clear and anatomically reliable boundary to its nearby indispensable neural structure like internal capsul basal ganglia and optic pathway

METHOD: among the mesial temporal surgeries (113 cases)

During 2005-2013 46 cases for MTS and 67 cases temporal lobe tumors involving mesial structures 4 cases can be considered primary amygdal tumors and one cases due to autohippocampectomy by temporal horn epidermoid which has made amygdal region the only culprit of epilepsy etiology has been selected.

RESULTS: in this regards we discuss fully surgical strategy and approach to this very rare lesion and especially crucial role of neuronavigation in reaching this deepest epileptogenic focus in human brain. And anatomical relationship and how the epilepsy surgeon should care about them will be demonstrated

CONCLUSIONS: although primary amygdal tumors are rare they are one of most challenging neurosurgical task and its safe treatments demand careful and well judgmental surgical decision making and practice.

Profound Knowledge of anatomy mastering microsurgical skill and use of modern neuronavigation tools will help the surgeon end up with beautiful surgery, saving important neural structure and cured and well saved patient.

OP-110[Neurooncologic Surgery]

FEATURES OF CLINICAL PRESENTATION AND SURGICAL TREATMENT OF BRAIN CONVEXITY TUMORS

Dilshod Mamadaliev¹, Zamira Makhmudova²

¹Tashkent Medical Academy, Tashkent. Uzbekistan

²Department of neurooncology, Republican Scientific Center of Neurosurgery. Tashkent. Uzbekistan

INTRODUCTION - OBJECTIVE: Postoperative neurological complications in patients with brain tumors are remaining as an actual problem, which brings social, economic and moral damage to society. Various electrophysiological modalities can be used to detect subtle signs of neurological compromise before they become fixed deficits. The use of intraoperative monitoring can reduce significant neurological deficits in the appropriate circumstances.

METHOD: We have observed 50 patients with convexital localized brain tumors in our scientific center. Age of patients ranged from 18 to 60 years, there were 30 females (60%) and males - 20 (40%). Patients were divided into 2 groups, 1st group received surgical treatment under control of EMG of somatosensory and motor evoked potentials, 2nd group of patients were operated without EMG monitoring.

RESULTS: Postoperative outcome in 21 patients (84 %) were not observed any neurological deficit and merely 4 (6 %) patients had transient pyramidal disorders, manifesting as a hemiparesis with muscle

strength 4 points, rare sensori-motor Jackson's partial seizures lasting up to 2 weeks. In control group 12 patients (48 %) had pyramidal disturbances in the form of hemiparesis, muscle strength up to 3 points, and hypo or paresthesia persisting more than 1 month.

CONCLUSIONS: 1. Intraoperative monitoring of motor and sensory cortex during operations of convexital brain tumors is an effective way to prevent postoperative deep neurological disorders, thereby reduces the socio-economic costs of post-operative rehabilitation treatments and improve quality of life. 2. Use of EMG-monitoring enhances to choose a safe angle of attack in removing brain tumors and save cortical centers as possible.

OP-111[Neurooncologic Surgery]

ANALYSIS OF CAUSES OF INTRACRANIAL HEMATOMAS AFTER CRANIOTOMY IN PATIENTS WITH INTRACRANIAL TUMORS AND EVALUATION OF INITIAL COMPUTER TOMOGRAPHY

Zhenghe Chen, Zhongping Chen, Jian Wang, Ke Sai

Department of Neurosurgery, Cancer Center, Sun Yat-sen University, Guangzhou, P. R. China

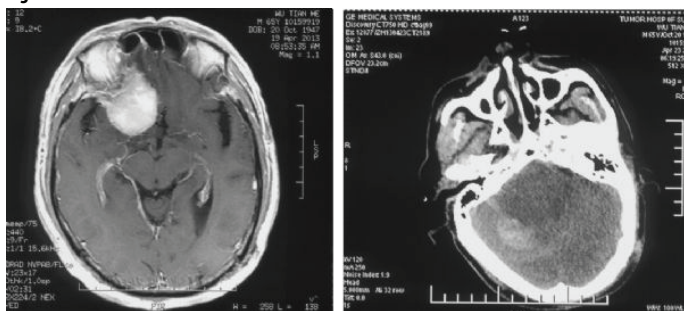
INTRODUCTION - OBJECTIVE: To explore the causes of intracranial hematomas after craniotomy in patients with intracranial tumors and investigate the clinical values of initial computer tomography.

METHOD: We analyzed the data of 216 patients with cranial tumors after craniotomy retrospectively. All had initial computer tomography test in 3 hours after operation.

RESULTS: 9 patients in 216 had intracranial hematomas, while 4 owned positive signs in initial computer tomography. The types of hematomas included ecchymoma (1/9), epidural hematoma (3/9), subdural hematoma (2/9), intracerebral hemorrhage (2/9, 1 distant brain hemorrhage), and intraventricular hemorrhage (1/9). These tumors of the 9 patients were classified to 5 meningiomas, 1 medulloblastoma, 1 pituitary adenoma, 1 metastatic tumor (squamous carcinoma), 1 oligodendroglioma, pathologically. 6 of 9 patients underwent second operations to remove hematomas. All 9 patients recovered.

CONCLUSIONS: Not downright hemostasis, quickly dropping of intracranial pressure, typical tumor with marked vascularity like meningioma, and brain tissue damage during the operation and reperfusion injury after operation are the essential causes of intracranial hematomas after craniotomy in the patients with intracranial tumors. The key points of prevention and treatment are that the relevant measures should be taken before and during operation, intensive care should be given after operation, and earlier diagnosis should be done. Initial computer tomography shows its unique clinical value.

Figure 1



Initial pre-operation computer tomography shows distant brain hemorrhage (right hemisphere of the cerebellum) in a patient with sphenoid ridge meningioma underwent craniotomy.

Table 1

Hemorrhage period	Case	Proportion (%)
Hyperacute cerebral hemorrhage	4	1.85
Acute cerebral hemorrhage	2	0.92
Subacute cerebral hemorrhage	3	1.39
Total	9	4.17

Classification of 9 cases of intracranial hematomas in 216 patients after craniotomy for intracranial tumors, grouped by bleeding time.

Table 2

Hemorrhage type	Case	Proportion (%)
Ecchymoma	1	0.46
Epidural hematoma	3	1.39
Subdural hematoma	2	0.92
Intracerebral hemorrhage/Distant brain hemorrhage	2/1	0.92/0.46
Intraventricular hemorrhage	1	0.46
Total	9	4.17

Classification of 9 cases of intracranial hematomas in 216 patients after craniotomy for intracranial tumors, grouped by types of hemorrhage.

Table 3

Pathological type	Case	Case with initial CT evidence
Meningiomas	5	2
Medulloblastoma	1	1
Pituitary adenoma	1	1
Oligodendroglioma	1	0
Metastatic tumor (Squamous carcinoma)	1	0

Classification of 9 cases of intracranial hematomas in 216 patients after craniotomy for intracranial tumors, grouped by pathological types.

OP-112[Miscellaneous]

BRAIN HYDATIDOSIS SURGICAL OUTCOME

Mohamad Zohair Shakir

department of neurosurgery, mosul teaching hospital, mosul, iraq

INTRODUCTION - OBJECTIVE:

BACKGROUND: Brain Hydatidosis is one of common parasitic brain diseases accounted in Iraq. This is prospective study done in mosul teaching hospital in iraq during 2007-2014.

METHOD: All patient data had collected from the records of 10 patients admitted to Mosul center with hydatidosis, including clinical features and imaging investigation in addition to operative record. Follow up of all included patient was achieved.

RESULTS: ten patients were included, seven male and three female. two patients got liver and one patient got lung hydatidosis at same time. Nine patients were of intracerebral hydatidosis while one was extracerebral. six patients were in parietal lobe and one in frontal and one in occipital and one in suboccipital. Age ranged 5-45 years where five patients were children. Three patients get multiple cysts while the other seven get solitary hydatid cyst. Follow up period where 6 months to five years. All patients were treated by craniotomy and total excision (delivery) of hydatid cyst(s) while rupture occurred on one case and albendazole had given for all of patients postoperatively. All patients except two get return to normal neurological function while one still in deficit the other one died due to postoperative infection.

No recurrence was seen.

CONCLUSIONS: Brain hydatidosis is still seen in our country and early surgery provide good treatment in addition to use of albendazole while mortality and morbidity are not uncommon postoperative events

OP-113[Miscellaneous]

METABOLIC ALTERATIONS IN THE BRAIN STEM CAUSED BY ITS COMPRESSION BY ADJACENT EXTRACEREBRAL TUMOR: PROTON MRS STUDY

Galina Moisa¹, Victor Olyushin², Mikhail Chernov³

¹Department of Neuro-Oncology, Federal Center of Neurosurgery, Novosibirsk, Russia

²Department of Surgical Neuro-Oncology, Russian Polenov Neurosurgical Institute, Saint Petersburg, Russia

³Faculty of Advanced Techno-Surgery, Tokyo Women's Medical University, Tokyo, Japan

INTRODUCTION - OBJECTIVE: The objective of the present study was spectroscopic characterization of the metabolic alterations in the brain stem caused by its compression by adjacent extracerebral tumor.

METHOD: Short-echo (TR: 1500 ms, TE: 30 ms) proton magnetic resonance spectroscopy (MRS) of the brain stem was performed during preoperative clinical examination of 16 patients (11 women and 5 men; mean age, 51 years) with newly-diagnosed vestibular schwannomas (9 cases) or petroclival meningiomas (7 cases). In all patients the tumor caused compression (8 cases) or dislocation (8 cases) of the brain stem. Its edema was presented in 6 cases. The Karnofsky performance scale score of the patients varied from 60 to 90 (mean, 73±12). Spectroscopic examination was directed on analysis of the metabolite signals from mobile lipids (Lip), lactate (Lac), N-acetylaspartate (NAA), creatine (Cr), and choline-containing compounds (Cho), centered at 0.8, 1.3, 2.0, 3.0, and 3.2 ppm, respectively.

RESULTS: In 15 cases proton MRS of the brain stem was abnormal. It was mainly reflected in appearance of Lac peak (mild, 2 cases; moderate, 8 cases; prominent, 3 cases) and Lip peak (mild, 4 cases; moderate, 3 cases). Mean values of NAA/Cr, Cho/Cr, and NAA/Cho ratios were 2.94±1.69, 1.47±0.60, and 1.94±0.65, respectively.

CONCLUSIONS: Proton MRS may effectively reveal metabolic alterations in the brain stem caused by its compression by the adjacent extracerebral tumor. In the present series the most common spectroscopic abnormality was appearance of Lac peak, which was identified in 81% of cases.

OP-114[Neurovascular Surgery] SURGICAL TREATMENT OF BRAIN CAVERNOMAS

Andriy Smolanka¹, Mykola Polishchuk², Volodymyr Smolanka³

¹Regional Centre of Neurosurgery and Neurology, Uzhhorod, Ukraine

²National Medical Academy of Postgraduate Education, Kyiv, Ukraine

³Uzhhorod National University, Uzhhorod, Ukraine

INTRODUCTION - OBJECTIVE: To determine effectiveness and safety of surgical treatment of brain cavernomas.

METHOD: We retrospectively reviewed our own series of 30 patients with brain cavernous malformations, treated during last 6 years (January, 2008 – January, 2014). 12 of them (40%) were male and 18 (60%) were female. Mean age of the patients was 31.9 years. Mean follow-up was 20 months. Patients with supratentorial cavernomas (15 patients, 50%) presented with seizures (8 patients) or focal neurological deficit (4 patients). 3 patients were asymptomatic but insisted on surgical treatment. All 15 patients (50%) with brainstem cavernomas had an acute onset due to extraleisional hemorrhage. 8 patients had 2 hemorrhages, 5 patients had 2 hemorrhages, 1 patient had 3 hemorrhages and 1 patient had 1 hemorrhage.

RESULTS: Patients who had 2 to 5 seizures (n=6) preoperatively are seizure-free on last follow-up. In patients with drug resistant epilepsy (n=2) the frequency of seizures declined significantly. 3 out of 4 patients (75%) with focal neurological deficit improved or didn't decline after surgery and were stable on last follow-up. Asymptomatic patients haven't declined after surgery. Brainstem cavernomas were classified depending on their location and most appropriate surgical approach was used. In all patients total resection was carried out, which was confirmed on MRI. In 2 patients neurological deficit worsened compared to preoperative level – surgical morbidity 6.7%. 1 patient died – surgical mortality 3.3%.

CONCLUSIONS: Microsurgical resection is safe and effective treatment method of brain cavernous malformations.

OP-115[Neurooncologic Surgery] HYDATID DISEASE OF THE BRAIN: OUR EXPERIENCE OF THE DIAGNOSIS AND TREATMENT

Gayrat Maratovich Kariev, Laziz Aminovich Usmonov

Republican Scientific Center of Neurosurgery Ministry of Health of the Republic of Uzbekistan

INTRODUCTION - OBJECTIVE: Echinococcosis is a widespread disease and the most common sites of infection are liver (75%), lungs (15%), and brain (2-4%). Vertebral involvement in hydatid cyst diseases occurs in 0.2-1% of all patients

METHOD: under our supervision in the RNSC RUZ were 60 patients between 2005 and 2011.

RESULTS: Age distribution: 50% to 75 % of echinococcosis cases involves nervous system and occur in the pediatric age group. 65% occur in patients between the ages of 7 and 13. Up to 5 % of patients there were demonstrated other organs involvement (among them liver (2) lungs (1) and kidneys (1)). Sex distribution: in our series the sex ratio was predominant for males - 44 cases. Cerebral hydatid cysts are usually single and supratentorial (parietal lobe- 86,6 %, temporal lobe 57,3 %, frontal lobe 31,7 %, occipital lobe 23,2 %.) and tend to occur in the middle cerebral artery distribution. Only 3 % are seen in the cerebellum. Surgical removal of the cyst is the only effective treatment and successful operative treatment depends upon complete removal of the unruptured cyst. The method of choice is Dowling and Orlando method - continuously pumping of warm saline solution stream into the space between the cyst and the brain, with gradually recovering of hydatid cyst from the bed.

CONCLUSIONS: Although it is a very rare disease, it must be taken into consideration in areas of low level of social and economic development. Sometimes echinococcosis appears with less common clinical course, which makes the differential diagnosis more difficult.

OP-116[Miscellaneous] ASSOCIATION OF STERILE EMPYEMA WITH THE USE OF BIOGLUE

Adnan Khan, Ghanem Salman Al Sulaiti, Abdul Nasser Khader Omer Thabet

Department of Neurosurgery, Hamad General Hospital, Doha, Qatar

INTRODUCTION - OBJECTIVE: A watertight closure of the dura to prevent cerebrospinal fluid leakage is a critical component of most intracranial and intradural spinal procedures. It is frequently difficult to obtain a direct primary closure of the dura and often a dural graft is necessary in order to obtain satisfactory closure. Tissue glues, such as BioGlue have been reported as aiding in dural closure. We describe our clinical experience with the use of biogluue in 3 patients who had wound complications after implantation of biogluue.

METHOD: All clinical information was reviewed for the patients who had wound complications after implantation of BioGlue. Data collected included diagnosis, type of original surgery, clinical presentation of the wound complication, culture results and management.

RESULTS: In our experience, among the patients in whom BioGlue was placed as a means of preventing a postoperative CSF leak, we have had 3 patients who returned with wound complications necessitating revision surgeries to decompress/evacuate collection that returned no organism on microbiological analysis.

CONCLUSIONS: We think this occurs because of an intense inflammatory response that is initially sterile but can expand and weaken the surrounding tissue. Treatment consists of debriding the wound,

removing the BioGlue, and treating the patient with appropriate antibiotics if necessary. Based on our experience, we do not recommend the use of this product in neurosurgical procedures as it has been associated with wound complications. A report of 3 cases with adverse events may sound trivial, but these reports might be the tip of the iceberg.

OP-117[Miscellaneous] SYNERGISTIC ANTITUMOR EFFECT OF ING4/PTEN DOUBLE TUMOR SUPPRESSORS MEDIATED BY ADENOVIRUS MODIFIED WITH RGD ON GLIOMA CELLS

Yaodong Zhao

Department of neurosurgery, Shanghai 10th People's Hospital, Tongji University School of Medicine

INTRODUCTION - OBJECTIVE: Gene therapy is a promising therapeutic modality for cancers and adenovirus is one of the most frequently used vectors. However, because of the absence or decrease of coxsackievirus and adenovirus receptor on the surface of many kinds of tumor cells, the infection efficiency of adenovirus into target tumor cells may be low. Meanwhile, gene therapy by a single vector carrying two or more anti-oncogenes can improve treatment effect, reduce side effects from vectors. In this research, we aim to detect the anti-tumor effect of ING4/PTEN double tumor suppressors mediated by adenovirus modified with arginine (R)-glycine (G)-aspartate (D) (RGD) on glioma cells.

METHOD: We treated U87 glioma cells with PBS, blank adenovirus or adenovirus carrying RGD, ING4, PTEN, or both ING4 and PTEN, then detected and compared the U87 cells growth, apoptosis, and invasion. Moreover, we established U87 glioma transplantation tumor models, to study the anti-tumor effect in vivo by measuring the volumes and weights of tumor masses in each condition. In addition, we analyzed the transcriptions of related genes (p53, Bax, Bcl-2, p21, Cyclin-B, Caspase-3 and HIF-1α) by fluorescent quantitative PCR and detected their expressions by immunohistochemistry staining to explain the underlying mechanisms.

RESULTS: The double tumor suppressors ING4/PTEN could inhibit the growth of U87 glioma cells with a synergistic antitumor effect, and the RGD modification also acts as an anti-oncogene to inhibit U87 cells invasion and tumor angiogenesis.

CONCLUSIONS: The ING4/PTEN double tumor suppressors mediated by adenovirus modified with RGD had a significantly synergistic antitumor effect on glioma.

OP-118[Surgical Neuroanatomy] ESSENTIAL TECHNICAL TIPS IN SKULL BASE SURGERIES

Hidehito Kimura, Eiji Kohmura

Department of Neurosurgery, Kobe University Graduate School of Medicine, Kobe, Japan

INTRODUCTION - OBJECTIVE: Recent advances in skull base surgery have decreased surgical morbidity and mortality not only in removing skull base tumors but also treating deeply situated vascular lesions. There should be various kinds of technical tips to be learned and inherited. Some of them, of course, may be learned from textbooks, practical surgeries, and operative videos, in which the experts demonstrate the cutting edge of skull base surgery. Additionally, we think the most effective way to acquire skull base technique is to perform a simulated surgery using a cadaver head, which plays an important role not only in understanding micro-skull base anatomy but also mastering surgical techniques. We have annually cadaver dissection course for skull base surgery at our university hospital in order to educate young neurosurgeons.

METHOD: In this presentation, various technical tips will be demonstrated in performing basic skull base surgeries, such as anterior clinoidectomy, exposure and drilling of middle fossa rhomboid, and mastoidectomy showing both in the cadaver head and actual surgery.

RESULTS: Cadaver head always gives us clear bloodless surgical field, which facilitates us to visualize and understand the normal microanatomy. Unfortunately this leads us to misunderstanding as if we became a skillful surgeon. However, we can never obtain clear surgical field in the practical surgery without indomitable maneuver for hemostasis. The technical tips for hemostasis may be learned only by the practical surgery.

CONCLUSIONS: Accurate understanding of skull base microanatomy and precise maneuver are essential for the safe and reliable skull base surgery.

OP-119[Surgical Neuroanatomy] LATERAL TRANSZYGOMATIC MIDDLE FOSSA APPROACH: 3D ANATOMY

Silky Chotai, Varun Kshetry, Alex Petrak, Mario Ammirati

The Ohio State University, Department of Neurosurgery, Dardinger Skull Base Lab, Columbus, Ohio

INTRODUCTION - OBJECTIVE: Various approaches to lesions involving the middle fossa and cavernous sinus (CS), with and without posterior fossa extension have been described. In the present study, we highlight relevant 3D anatomy and present illustrative cases

METHOD: Simulations of the lateral transzygomatic middle fossa approach and its extensions were performed in four silicon-injected formalin fixed cadaveric heads. The step-by-step description and relevant anatomy is documented with 3D photographs.

RESULTS: This approach incorporates direct lateral positioning of patient, frontotemporal craniotomy with zygomatic arch osteotomy, extradural elevation of the temporal lobe, and delamination of the outer layer of the lateral CS wall. Extradural drilling of the sphenoid wing and anterior clinoid process allows entry into the CS through the superior wall and exposure of the subclinoid ICA. Posteriorly,

drilling the petrous apex allows exposure of the ventral brainstem from trigeminal to facial nerve and can be extended to the interpeduncular fossa by division of the superior petrosal sinus

CONCLUSIONS: This approach allows wide access to different topographic areas (subdural space, the entire CS, and the posterior fossa from the interpeduncular fossa to the facial nerve) via a lateral trajectory. Precise knowledge of technique and anatomy is necessary to properly execute this approach.

OP-120[Surgical Neuroanatomy]

MIDLINE SUBOCCIPITAL SUBTENSILLAR APPROACH (STA) TO THE CEREBELLOMEDULLARY CISTERN AND THE CRANIOCERVICAL JUNCTION AND ITS STRUCTURES: ANATOMICAL CONSIDERATIONS AND CLINICAL APPLICATION

Florian Roser¹, Stephan Herlan², Bernhard Hirt³, Florian H Ebner², Marcos S Tatagiba²

¹Department of Neurosurgery, Neurological Institute, Cleveland Clinic Abu Dhabi

²Department of Neurosurgery, University Hospital Tuebingen, Germany

³Department of Clinical Anatomy, University Tuebingen, Germany

INTRODUCTION - OBJECTIVE: Lesions lateral to the lower brainstem are rare and harbor different pathologies. No consensus with regard to the surgical approach of choice for the treatment of these lesions exists. We describe the anatomy of the STA, which provides a straight and wide angle view to various types of pathologies in the cerebellomedullary cistern and the craniocervical junction.

METHOD: The microsurgical features of the STA were examined in three ETOH fixed specimens in semi-sitting position using neurosurgical standard equipment. Distances were measured using a caliper rule. Additionally thirty-one patients who underwent surgery using the STA from 2006-2012 were examined and evaluated.

RESULTS: The anatomical studies showed a distance between external-occipital-protuberance and Foramen magnum of 5cm (SD+/-0.7cm), between the occipital condyles of 3.4cm (SD+/-0.26cm). After retracting the tonsils 0.3cm (SD+/-0.08cm) we gain vision of PICA. Retraction to 0.35cm (SD+/-0.17cm) exposed spinal root of CNXI. Hypoglossal canal got visible after 0.9cm (SD+/-0.09cm), the root exit zone of glossopharyngeal nerve after 1.29cm (SD+/-0.15cm), the jugular foramen after 1.59cm (SD+/-0.3cm), the inner acoustic canal after 2.42cm (SD+/-0.2cm) of tonsil retraction.

In 31 cases using the STA types of pathologies contained plexus-papillomas, hypoglossal-schwannomas, cysts, aneurysms, hemangioblastomas and vascular confluents. The STA approach from skin incision to dural opening was 40min (+/-10min). The mean duration of surgery was 295min (SD+/-115min).

CONCLUSIONS: The STA provides a straightforward view to the lateral premedullary cistern with moderate degree of tonsil retraction. Compared to other approaches we see clear benefit in the concept of the STA as a time- and morbidity sparing approach.

OP-121[Neurovascular Surgery]

THROMBOSIS OF THE CEREBRAL VEINS AND SINUSES

Rajiv Kumar Jha¹, Prakash Bista¹, Gopal Raman Sharma¹, Pawan Kumar¹, Nilam Khadka¹

¹Bir Hospital

²Om Hospital

INTRODUCTION - OBJECTIVE: Cerebral venous sinus thrombosis (CVST) is a rare and potentially deadly condition. Common etiologies include hypercoagulable diseases, low flow states, dehydration, adjacent infectious processes, oral contraceptives, hormonal replacement therapy, pregnancy, and puerperium. Anticoagulation is the mainstay of treatment.

Objective – To describe the features of a series of patient with CVST treated in the department of Neurosurgery, Bir hospital and OM hospital, and to discuss the risk factors, presentation, and outcome of the disease process.

METHOD: This is a retrospective and prospective study which was carried out in the department of Neurosurgery, Bir hospital and OM hospital during the year September 2008 to January 2014. Demographic features like age, sex were analyzed.

RESULTS: 72 Patients were identified over a period of about 4 1/2 years. The presenting symptoms included headache (68 patients), vomiting (32 patients), loss of consciousness (28 patients), focal neurological deficit (12 Patients), seizure (12 Patients) and neck pain (4 patients). Signs found included papilloedema (16 patients), fever (8 patients), slurring of speech (4 Patients) and focal neurological signs (8 patients). The most common underlying condition was dehydration and use of estrogen containing contraceptives. All cases received heparin/ LMWH followed by Warfarin. One patient who had CVST associated with pituitary adenoma died.

CONCLUSIONS: CVST is not an uncommon disease, but needs extreme degree of suspicion. CVST has non-specific presenting features and a high risk of significant morbidity. CVST is typically found in association with a predisposing condition. Although heparin is the mainstay of treatment, However, there is insufficient evidence to recommend the routine use of thrombolysis at present.

OP-122[Stereotactic and Functional Neurosurgery]

REUSE OF INTERNAL PULSE GENERATOR IN INFECTED CASES AFTER DEEP BRAIN STIMULATION SURGERY

Selçuk Göçmen¹, Özkan Çeliker¹, Abdullah Topcu¹, Aikaterini Panteli², Göksemin Acar³, Feridun Acar¹

¹Department of Neurosurgery, Pamukkale University, Denizli, Turkey

²Department of Neurosurgery, Red Cross Hospital, Athens, Greece

³Department of Neurology, Pamukkale University, Denizli, Turkey

INTRODUCTION - OBJECTIVE: Deep brain stimulation (DBS) hardware-related infection is one of the most serious complications, and may need additional interventions. DBS is part of a growing group of expensive implantable devices. We improved this study to reuse the internal pulse generator (IPG) after DBS infection, and to reduce the economic costs.

METHOD: A database of 102 patients who underwent DBS surgery was used in the study. Incidence, clinical characteristics and management of infections while reusing the IPG after DBS infection were analyzed and reported.

RESULTS: The overall infection rate was 5.9% (6 of 102 patients) of the patients. The median time of infection was 3.5 months (range 1-6 months). The management consisted on total hardware removal followed by intravenous antibiotics. These patients recovered with no clinical signs of infection. In all patients, the IPG was infected. Staphylococcus was the causative organism. These patients underwent reimplantation surgery at least 3 months after completion of antibiotic treatment to reimplant the devices. Explanted IPGs were used in all cases and no hardware related infection or other complications were observed after reimplantations. The mean follow-up period was 14 months (range 6 month-24 months).

CONCLUSIONS: Management of hardware-related infections can be challenging. Removal of the infected device is generally needed to establish cure of infection of the DBS. The medical and economic cost of these infections is enormous. The IPG can often be saved in infected patients. Thus, a significant cost burden is eliminated. Properly executed, reuse of IPG should markedly reduce the cost of these devices.

Table 1.

Patient (Age/ Sex)	Diagnosis	Surgery	Time to infection, months	Site of infection	Culture	Time to replacement of hardware, weeks
F/63	Parkinson Disease	STN-DBS	5	chest, frontal, postauricular	MRSA	24
F/54	Parkinson Disease	STN-DBS	2	chest, postauricular	coagulase-negative Staphylococcus	16
M/59	Parkinson Disease	STN-DBS	6	chest	No	12
M/72	Parkinson Disease	GPI-DBS	2	chest	No	16
M/66	Parkinson Disease	STN-DBS	2	chest	No	12
F/57	Parkinson Disease	GPI-DBS	4	chest, frontal, postauricular	MRSA	16

The summary of 6 patients

OP-123[Stereotactic and Functional Neurosurgery]

MANAGEMENT OF THE TUMORS IN THE PINEAL REGION

Mehrnoush Gorjian¹, Ladislau Steiner¹, Chun Po Yen²

¹Department of Neurosurgery, International Neuroscience Institute, Hannover, Germany

²Department of Neurosurgery, University of Virginia, VA, USA

INTRODUCTION - OBJECTIVE: Pineal region tumors originating from the pineal parenchymal, neuroectodermal, or germ cells may feature a wide gamut of histological structures. Very early following the advent of Gamma Knife Surgery (GKS), it was used to treat tumors in this region if they were relatively small.

METHOD: Steiner treated six pineocytomas, two pineoblastomas, two astrocytomas, two germinomas, one hemangioblastoma, and three tumors with unknown histology located in pineal region. In all the cases the diagnosis was established after a stereotactic biopsy from the tumor. Prescription doses ranging from 12 to 20 Gy were used in 12 patients treated with Gamma Knife alone. Prescription doses ranging from 6 to 15 Gy were used for four cases where GKS was used as a booster treatment.

RESULTS: With a median follow-up of 24 months, thirteen tumors decreased in size and no side effects have been observed.

CONCLUSIONS: For the tumors with benign histology, GKS is the treatment of choice while malignant tumors need fractionated radiation targeting brain and neuraxis. Boost therapy with radiosurgery should be also considered in germ cell tumors and pinealoblastoma.

OP-124[Stereotactic and Functional Neurosurgery]

MICROVASCULAR DECOMPRESSION OF MEDICALLY REFRACTORY TRIGEMINAL NEURALGIA

Vladimir Tsikarishvili¹, Irakli Toidze¹, Mirza Khinikadze², George Shalashvili², Marine Janelidze¹¹Neurosurgery Department, S. Khechinashvili University Hospital, Tbilisi, Georgia²Neurosurgery Department, PSP New Hospital, Tbilisi, Georgia

INTRODUCTION - OBJECTIVE: We have analyzed perioperative and short-term clinical outcome data of 30 patients with medically refractory trigeminal neuralgia after microvascular decompression.

METHOD: During 2010-2013 thirty (30) patients with classic trigeminal neuralgia were identified and microvascular decompression was performed in all cases. There were 18 female and 12 male. Mean age was 59 years (37-82 years). In most cases pain was localized on the right side, V2 and V3 roots were affected more often. Pre and postoperatively severity of the pain was evaluated by Barrow Neurological Institute Pain Scale.

RESULTS: After surgery significant improvement of pain scores was achieved in all patients. Complications were observed in two (2) cases. Cerebellar swelling was occurred in one case and suboccipital decompression was performed. In another case VII and VIII nerves palsy were developed which significantly recovered in a three month. In a follow-up period (up to 2 years) one reoperation was performed. During the follow-up period in 27 cases (90%) Barrow Neurological Institute Pain Scale score was 1 or 2 and in three cases (10%) score was 3.

CONCLUSIONS: Microvascular decompression is a highly effective procedure for the treatment of classic trigeminal neuralgia.

OP-125[Neurovascular Surgery]

ENDOSCOPIC ASSISTED MICROVASCULAR DECOMPRESSION OF THE TRIGEMINAL AND FACIAL NERVE

Firas Hammadi¹, Philipp Dodier², Alf Giese¹, Ali Ayyad¹¹Mainz University Hospital²Vienna Medical School

INTRODUCTION - OBJECTIVE: Microscopic vascular decompression became the gold standard for surgical treatment of neurovascular compression syndromes in the posterior fossa since it has been introduced by Jannetta. The introduction of the endoscope in neurosurgical procedures has brought a further new dimension into the field of intraoperative visualization. It provides, in contrast to the microscope, a panoramic view of the cerebellopontine angle (CPA) anatomy (especially with angled endoscopes) and shows exactly the differences between the pathological and the normal anatomy.

METHOD: during a 10 years from 2002 till 2012 We performed endoscopic assisted microvascular decompression in 77 patients with symptomatic trigeminal and facial nerve compression syndromes; 41 trigeminal neuralgia, 34 Hemifacial spasm and 2 patients with both syndromes. They were 40 females and 37 males. Surgery was performed in all cases under endoscope-assisted keyhole conditions. All 43 patients with trigeminal neuralgia received preoperative medication treatment and experienced failure with it. 20 patients out of 34 with hemifacial spasm had been previously treated with botulinum toxin injections.

RESULTS: 75 of the 77 patients became symptom free after surgical treatment; one revision surgery was performed. 4 patients developed hearing deterioration, 2 facial palsy. No mortalities. **CONCLUSIONS:** A precise planned keyhole craniotomy and the simultaneous use of the microscope and the endoscope render the procedure of the decompression less traumatic.

OP-126[Stereotactic and Functional Neurosurgery]

DIFFERENTIAL APPROACH TO THE TREATMENT OF DRUG-RESISTANT FACIAL PAINS: SIBERIAN EXPERIENCE

Dzhamil Rzaev¹, Elena Kulikova², Evstafy Melidi³, Oksana Gavronina³, Elena Khabarova³, Dmitry Rogov³¹Federal Neurosurgical Center, Novosibirsk, Russia²Reception ward, Federal Neurosurgical Center, Novosibirsk, Russia³Functional Department, Federal Neurosurgical Center, Novosibirsk, Russia

INTRODUCTION - OBJECTIVE: Objective is to define the algorithm of chronic facial pain management and to evaluate efficiency of different treatment methods.

METHOD: From January 2013 till March 2014, 101 patient with drug-resistant (high doses of Carbamazepine and anti-depressants) facial pains for a long time (more than 5 years) had been treated (VAS >8). A cohort of patients was divided into 3 groups of conducted therapy. The first group included 43 patients with typical trigeminal neuralgia, they were undergone microvascular decompression. The second group consisted of 46 patients with chronic facial pain with prevalence of neuropathic component (s.c. atypical neuralgia). They were treated by transcutaneous selective radiofrequency rhizotomy. The third group consisting of 12 patients with facial pains with prevalence of sympathalgic component was undergone radiofrequency destruction of pterygopalatine ganglion.

RESULTS: Microsurgical vascular decompression was performed on all 43 patients of the first group, 2 patients were operated on the 2-3 day after the surgery because of non-control pain after

primary procedure. Complete pain control just after transcutaneous selective radiofrequency rhizotomy was noted by 44 patients from the 2nd group (95,6%), VAS <3 point. Radiofrequency destruction of pterygopalatine ganglion provided all 12 patients of the 3rd group significant (VAS <4) with regress of pain syndrome practically without creation of hypalgesia zones.

CONCLUSION: Differential approach to treatment of chronic facial pains allows offering optimal algorithm of facial pains treatment.

OP-127[Stereotactic and Functional Neurosurgery]

SURGICAL TREATMENT OF TRIGEMINAL NEURALGIA

Irakli Otashvili¹, Giorgi Ingorokva²¹Irakli Otashvili²Giorgi Ingorokva

INTRODUCTION - OBJECTIVE: Trigeminal neuralgia is the pathology which characterized by paroxysmal homolateral facial pain. Patients often describe this pain as "the most severe pain that human can suffer". It is considered proved, that a principal cause of trigeminal neuralgia is vascular compression of a trigeminal nerve directly near brainstem. The basic pathogenetic method of trigeminal neuralgia treatment is vascular decompression of trigeminal root, which allows to eliminate the cause of disease and to reach full recovery.

METHOD: A substantiation of indications for vascular decompression and estimations of its efficiency at TN. 44 patients with trigeminal neuralgia were operated in high technology medical center university clinic in the period from 2009 till 2013. Among which women rate was 27(61%) patients, men 17 (39%). Mean age was 51 years. Right sided pain syndrome was in 31 patients, left sided – 13. MRI data with signs of neurovascular conflict was observed in 91% of cases. Diagnosis of TN was definite when the patient had 4 of 5 criteria that were proposed by International Pain Society in 1994.

RESULTS: Regression of pain syndrome in the nearest postoperative period was achieved in all patients. Recurrence of pain syndrome within one year after surgery had two patients. Two patients underwent additional surgery - readjustment of the displaced pad. There was no mortality in our study, and the overall complication rate in the late postoperative period was less than 1,5%.

CONCLUSIONS: Vascular decompression of the trigeminal nerve is the most effective pathognomonic method of treatment of the trigeminal neuralgia.

OP-128[Spine and Peripheral Nerve Surgery]

ANALYSIS OF THE RESULTS OF OPERATIVE TREATMENT OF THE PATIENTS WITH THORACOLUMBAR SPINAL FRACTURE

Gayrat E. Eshkuvatov

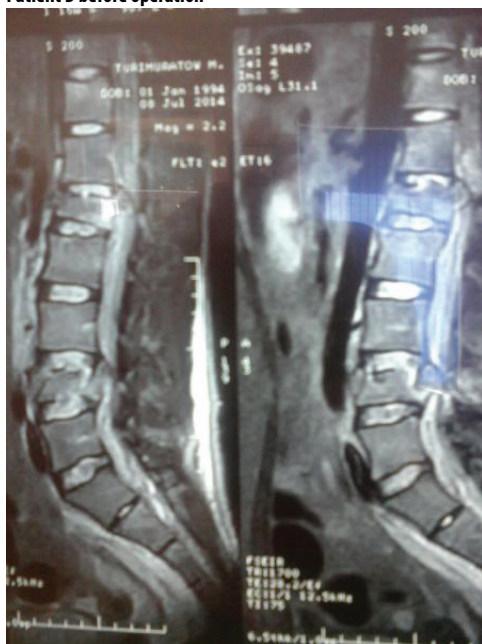Tashkent Regional Center of Emergency Medicine Chirchik city, Uzbekistan

INTRODUCTION - OBJECTIVE: There are 25(100%) patients with thoracolumbar spine fracture was evaluated in this study: 8(32%) patients admitted in a period of the 1st 8 hours after trauma and other 17(68%) patients after 24 hours. All of them evaluated by AO classification: A2-8(32%), A3-9(36%), C1-4(16%), C2-2(8%) and B2-2(8%) cases. Neurological deficiency evaluated by Frankel scale: A-13(52%), B-10(40%), C-2 (8%) cases. All patients was admitted with urinary difficulty. In 17 cases have used laminectomy with transpedicle stabilization, other 8 patients operated by anterior approach with stabilization by plates. Neurological deficiency of 7 patients admitted in 1st 8 hours at the time of discharge from the hospital was C by Frankel and in 2 cases of them the urinary difficulty was improved partly. In one case, by the reason of severe injury of spinal cord with damage of roots the positive results was not registered. In six patients operated by anterior approach the recovery period was prolonged due to the respiratory complication. In all patients admitted after 24 hours neurological deficiency was without improvement.

RESULTS: CONCLUSIONS: 1. The most positive results is observed in patients operated in a period of 1st 8 hours.

2. Anterior approach may account for respiratory complications and prolong of recovery period.

3. Transpedicle stabilization is the most reliable and safe method of operative technique.

Patient D before operation

burst fracture of VL1 and VL4 bodies

Types of fracture and neurologic deficit

	A1	A2	A3	B1	B2	B3	C1	C2	C3
A		4 (16%)	6 (24%)					1 (4%)	
B		2 (8%)	3 (12%)		2 (8%)		3 (12%)		
C	1 (4%)	2 (8%)							
D									
E									

13 patients admitted with A according to FS and 5 of them in 1st 8 hours. 10 patients admitted with B according to FS and 3 of them in 1st 8 hours. 3 patients admitted with C according to FS and 1 of them in 1st 8 hours.

OP-129[Neurotrauma and Intensive Care]**THE COMPLEX TREATMENT OF POSTTRAUMATIC CYSTS OF THE BRAIN**

Mansur Abdukholikovich Aliev

Neurosurgery Department of Samarkand State Medical Institute, Samarkand, Uzbekistan

INTRODUCTION - OBJECTIVE: The aim of this study is to reduce the trauma of surgical access, increasing its efficiency by enabling possibility of constant outflow of cerebrospinal fluid from the cyst, the prevention of repeated formations of arachnoid cysts and scar-adhesion process.

METHOD: We have studied 43 patients with cystic posttraumatic cerebral arachnoiditis undergoing surgical treatment in the neurosurgical department of the SamMI clinic in the period of 2007 – 2013 years. From them 75.8% were male and 24.2% were female. By the age composition patients from 1,5 to 15 years old were 12.1%, patients from 15-30 years old were 33.3%, 48.5% of patients were at the 30-40 years old and patients at the 40-50 years old were 6.1%.

RESULTS: All patients have been performed surgical operation by the method of drainage of arachnoid cysts elaborated by us including dissection and excision of the cyst wall and connection it with subarachnoid and subdural spaces and the introduction into a cystic cavity vinyl chloride or silicone catheter for ozone injection, catheter is inserted through the ozone medical syringe in an amount of 10-30 cm3 depending on the size of the cyst, the catheter is left for 3-5 days for the re-introduction of ozone.

CONCLUSIONS: The study of patients' catamnesis after 6 months have been showed that in 82,6% of cases epileptic seizures stopped, in 13,1% of cases convulsions went into mild degree and the frequency of seizures have been decreased and in 4.3% of cases seizures continued at the same frequency.

OP-130[Spine and Peripheral Nerve Surgery]**PEDICLE SCREW WITH LATERAL APPROACH IN MEDIAN LINE PATHOLOGIES**

Atilla Yilmaz

Department of Neurosurgery, Bayburt State Hospital, Bayburt, TURKEY

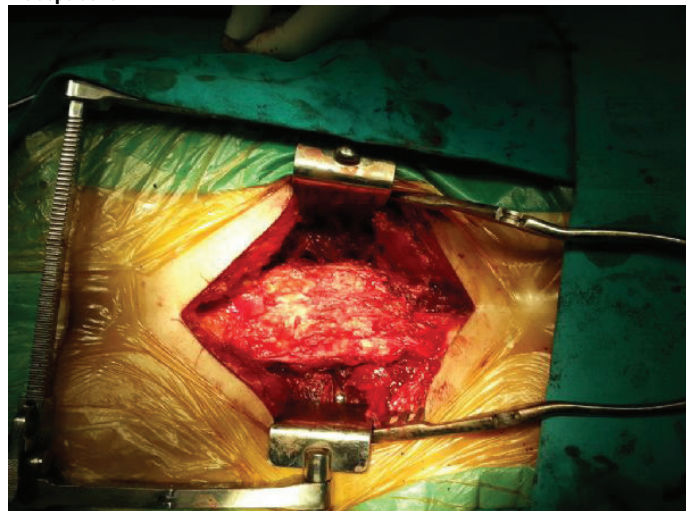
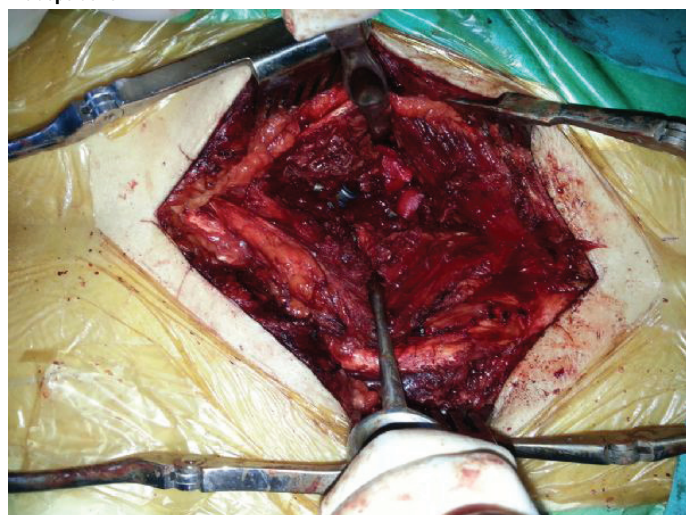
INTRODUCTION - OBJECTIVE: The first descriptions of the use of bone screws to obtain internal spinal fixation at the time of fusion were by Tournay in 1943 and King. Over the years, pedicle fixation systems

proved to be biomechanically superior for segmental fixation.

METHOD: The patient was 42 year old female complaining with low back and leg pain increasing with movement. She was being diagnosed and undergone surgery for lumbar disc herniation in Iran 12 years ago. Physical examination showed no motor deficit and SLR was positive in 45 degrees. Radiologic assessments showed that; in the previous surgery she was undergone L5 total laminectomy and having grade two spondylolisthesis. There was also a lesion suspected to be a pseudomeningocele between L4-S1. The patient was undergone to surgery. In order to avoid complications while dealing with the pseudomeningocele suspected lesion a different approach was planned. Under C-arm, after finding L3 pedicle lateral edge of transverse process was identified. L4,L5 transverse processes and S1 posterolateral crest was found with dissecting between Musculus multifidus and Musculus Longissimus without getting closed to the median line. Posterior stabilization was performed with bilateral pedicle screws applied to L5 and S1.

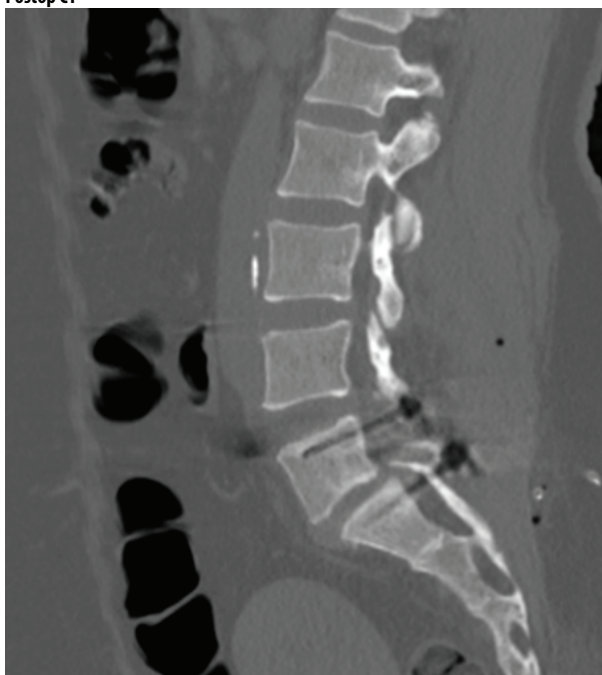
RESULTS: The complaints of the patient ceased after surgery. Postoperative radiologic assessment showed the reduction of the spondylolisthesis. The pseudomeningocele suspected lesion was intact.

CONCLUSIONS: Pedicle screw fixation can be achieved with the approach between Musculus multifidus and Musculus Longissimus in patients who have median line pathologies. This method can be also helpful for gaining sufficient angle in sacral pedicle screw.

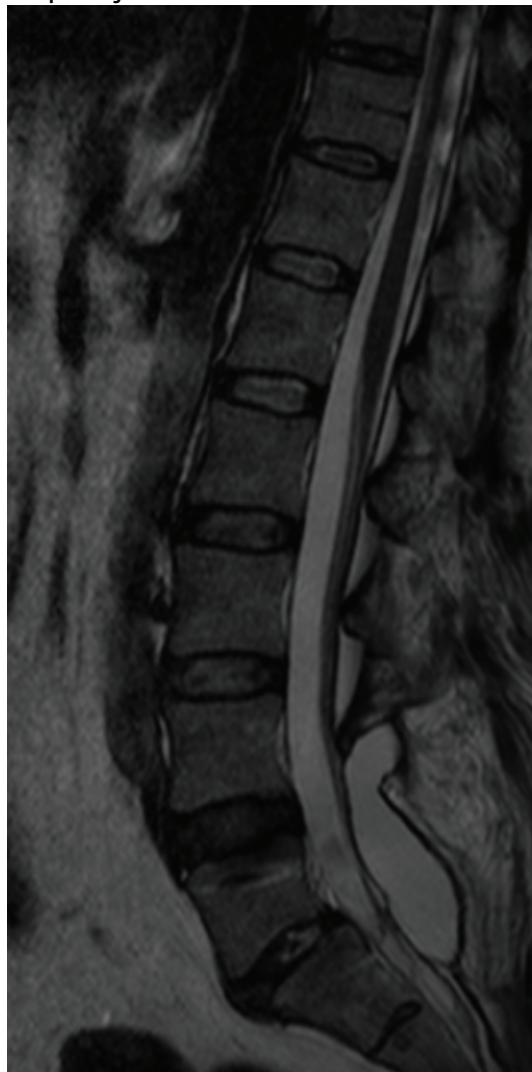Intraoperative - 1**Intraoperative - 2**



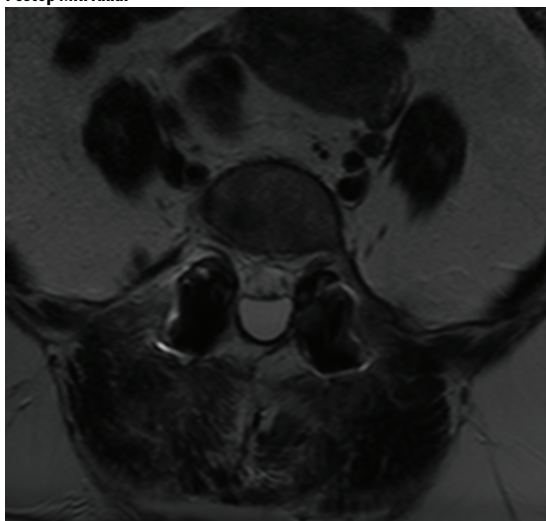
Postop CT



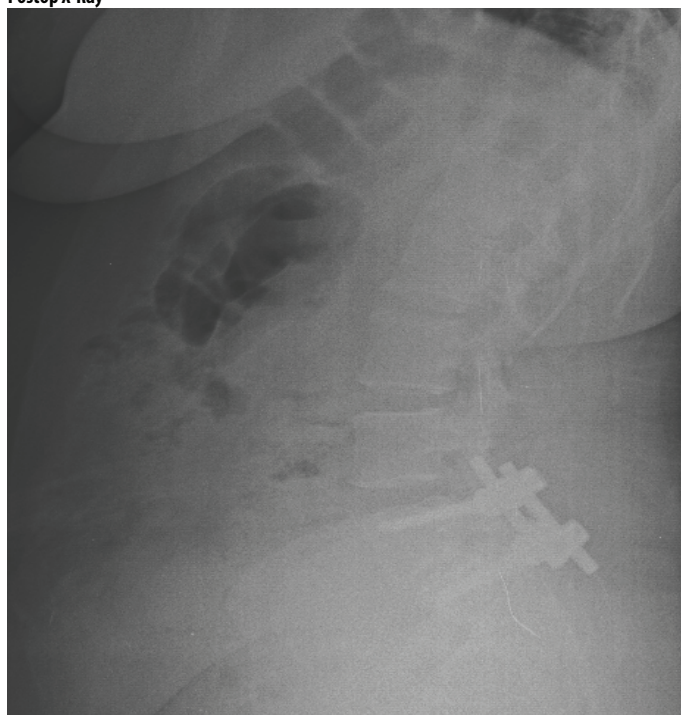
Postop MRI Sagittal



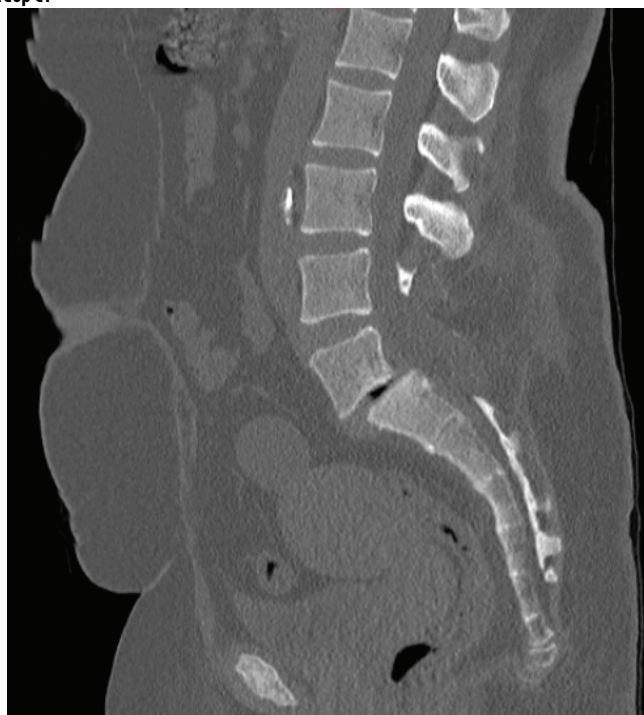
Postop MRI Axial



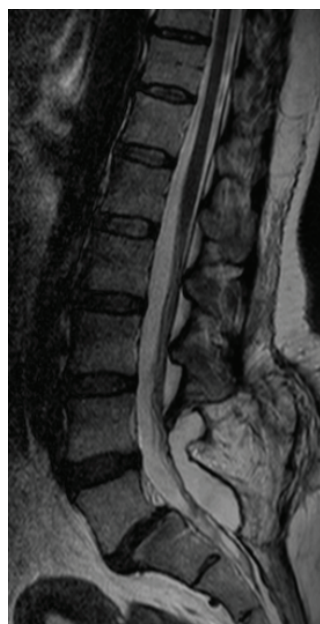Postop X-Ray



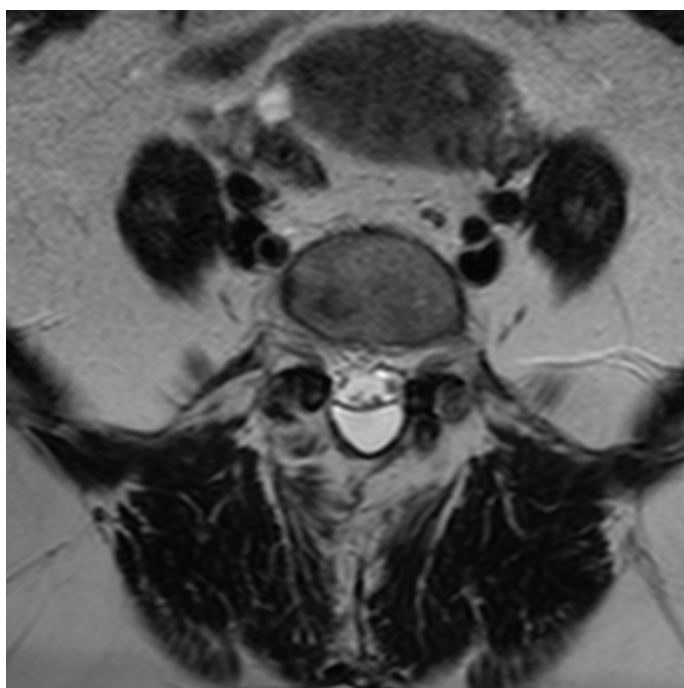
Preop CT



Preop MRI Sagittal



Preop MRI Axial

**OP-131[Spine and Peripheral Nerve Surgery]****APPLICATION OF TRANSCUTANEOUS RADIOFREQUENCY DESTRUCTION OF FACET NERVE COMBINED WITH PERCUTANEOUS DISC LASER NUCLEOTOMY FOR TREATMENT OF LUMBAR SPINE OSTEOCHONDROSIS SYNDROME**

Ramil Tankacheyev, Serik Karibay, Ibragimbek Galiev, Kanat Akhmetov, Yuri Dikhtyar
General Neurosurgery Department, Nacional Center of Neurosurgery, Astana, Kazakhstan

INTRODUCTION - OBJECTIVE: Comparing outcomes of pain syndromes of lumbar osteochondrosis, using two combined minimally invasive methods for treatment of disc herniation.

METHOD: 12 patients (7 women, 5 men) with protrusion of intervertebral discs and with signs of spondylarthrosis aged from 28 to 46 years cases have been selected and operated. 2 groups of patients allocated: group 1 - 15 patients which was subjected to laser vaporization of the intervertebral disc using laser product type Nd-YAG, Dornier, 2nd group - 12 patients with laser vaporization in conjunction with RF destruction of the facet nerves with RF generator COSMAN RFG-12 under local anesthesia and X-ray control.

RESULTS: Treatment outcome following data were obtained: in group 1, the outcomes on a scale Mac Nub: excellent in 8 patients, good in 6, satisfactory in 1. On a Nurick scale: excellent in 8, improved in 2, no changes in 3, deterioration in 2. In the 2nd group outcomes on a scale Mac Nab: excellent in 11, good in 1. On a Nurick scale: excellent in 10, improved in 2.

CONCLUSIONS: Fulfillment of two combined minimally invasive ways to treat herniated discs is an effective treatment of pain syndrome in comparison with isolated using of laser vaporization.

OP-132[Spine and Peripheral Nerve Surgery]**SURGICAL OUTCOME OF UNILATERAL APPROACH IN LUMBAR SPINAL STENOSIS; REPORT OF 32 CASES**

Md Moshir Rahman
Holy Family Red Crescent Medical College Hospital

INTRODUCTION - OBJECTIVE: Degenerative stenosis in lumbar spine is the most frequently observed type of spinal stenosis and is common among the elderly who present as low back pain and sciatica. Age associated degeneration involves disc height reduction, bulging of disc, osteophyte formation, facet hypertrophy and sometimes listhesis. Various procedures are described in the literature to relieve the symptoms. Aim of this study is to assess whether microscopic decompression of both sides from one side is helpful or not.

METHOD: A prospective study of 32 cases were observed of whom 22 were male and 10 were female. A single surgical procedure of unilateral approach to decompress the both sides in lumbar spinal stenosis was studied. Patients having cauda equina syndrome or spinal instability were excluded from the study.

RESULTS: Out of 32 patients 2 were not improved, 1 had CSF leak and 1 had discitis. 28 patients were pain free.

CONCLUSIONS: The unilateral approach from one side for lumbar spinal stenosis is safe and effective. Correct level diagnosis prior to surgery is essential. There should be no instability. It should be done

under microscope/endoscope. There are risk of injury to neuronal structures which can be eliminated by skillness and prior pathological concept.

OP-133[Spine and Peripheral Nerve Surgery] DISC ARTHROPLASTY VERSUS FIXATION FOR SINGLE LEVEL ANTERIOR CERVICAL DISC DISEASE

Sharad S Rajamani

Department of Neurosurgery, Khoula Hospital, Muscat, Oman

INTRODUCTION - OBJECTIVE: Anterior cervical discectomy followed by implantation has been performed for around 20 years now. The more recent addition has been preservation of the motion at the level of the discectomy using a disc replacement or disc arthroplasty.

METHOD: We evaluated a series of patients in which a single surgeon had performed either a disc arthroplasty or a fixation of the spine for a single level disc - osteophyte spondylotic disease over a 6 year period. This was done in retrospect. We compared the results of the two groups.

RESULTS: A total of 70 patients were studied. Fifty three males and seventeen females. The average age was around 49 years, with an average follow up of around 47 months. The two groups consisted of patients who underwent disc arthroplasty or fixation at the levels. The patients had either a C4-5, 5-6, or a 6-7 level surgery. 23 patients underwent a disc replacement and 47 had fixation done. There was no significant difference in the surgical times between the two patients. Seven of our patients who had mobility of the disc level at the end of one month and one year post operatively had lost movement in their second year. Eight patients out of 70 had recurrence of symptoms, and three had adjacent level pathology - one from the arthroplasty and two from the fixation group.

CONCLUSIONS: We found no difference in the Adjacent level disease between the two groups, and the recurrence rates were also similar.

OP-134[Spine and Peripheral Nerve Surgery] SURGICAL MANAGEMENT OF HANGMAN'S FRACTURE

Robert Ahmed Khan¹, Ruhul Quddus¹, Abu Saleh Md Abu Obaida¹, Md Moshir Rahman², S I M Khairun Nabi Khan¹

¹Department of Neurosurgery, Bangabandhu Sheikh Mujib Medical University, Dhaka, Bangladesh

²Department of Neurosurgery, Holy Family Red Crescent Medical College Hospital, Dhaka, Bangladesh

INTRODUCTION - OBJECTIVE: Hangman's fractures have been used to describe traumatic spondylolisthesis of C2 since it was initially noted in 1965 by Schneider et al. There are two kinds of it, i.e. (i) one of a hyperextensive-distraction mechanism with the very severe neurological lesion leading to the classical injury due to hanging and (ii) one of a hyperextensive-compressive mechanism without neurological lesion of current traffic injuries or with slight neurological symptoms. The latter more often occurring type of injury encompasses a relatively wide range. The optimal therapy for traumatic fractures of the neural arch of the axis is still controversial. Indications for surgery depend on the type of hangman's fracture and/or additional injuries of the intervertebral disc or ligaments. Here we shall share our experience of surgical management of hangman's fracture with review of literature.

METHOD: 6 patients were operated between 2005 and 2013. 4 patients presented with severe neck pain and 2 with neurological deficit. 5 patients were treated with transpedicle screw and one with anterior stabilization by plate and screw between C2-3.

RESULTS: All the patients had good post surgical outcome with satisfactory consolidations of the fractures.

CONCLUSIONS: Surgery provides plausible results. Compared to conservative treatment, it can offer significant benefits: 1) immediate, better and stable reposition; 2) high fusion rate; 3) shortening of the treatment period with better quality of life. Though technically difficult, transpedicle screw fixation is the best option as it preserves the motion more than other techniques.

OP-135[Spine and Peripheral Nerve Surgery] CLINICO-EPIDEMIOLOGICAL STUDY OF SPINAL INJURIES IN A WESTERN NEPAL TEACHING HOSPITAL

Balgopal Karmacharya, Binod Gharti

Neurosurgery Unit, Department of Surgery, Manipal Teaching Hospital, Pokhara, Nepal

INTRODUCTION - OBJECTIVE: Spinal injuries are one of the devastating injuries that has high physical, psychosocial and financial burden to the society. Such injuries in a developing country like Nepal are difficult to manage where health care facilities are scarce. We studied the demographics, causes and types of spinal injuries, their management and short term outcome in regional referral center in western region of Nepal.

METHOD: This is a prospective data analysis of all patients who were admitted in the Neurosurgery Unit, Department of Surgery, Manipal Teaching Hospital, Pokhara with diagnosis of spinal injuries. Demographics, modes of injuries, clinical and neurological features, level and types of injuries, hospital stay and type of treatment provided were noted.

RESULTS: Over a period of two years from January 2012 to December 2013, 268 patients were admitted with spinal injuries. Male:female ratio was 1.6:1. Mean age of patients was 38.2 years. Falls from trees was the commonest cause of spinal injuries. Thoracolumbar region was the most commonly injured region followed by cervical, thoracic and lumbar areas. Only one third of patients were neurologically

intact on presentation. About two thirds of patients underwent non-operative treatment.

CONCLUSIONS: Spinal injuries are common among young adults and result in long term disability. Fall from trees was the most common cause for such injuries.

OP-136[Neurooncologic Surgery] IS INTERHEMISPHERIC TRANSCALLOSAL APPROACH THE MOST MINIMALLY INVASIVE APPROACH FOR COLLOID CYSTS: AN INSTITUTIONAL EXPERIENCE OF 311 CASES

Suresh Nair Narayanan Nair

Sree Chitra Tirunal Institute for Medical Sciences & Technology, Trivandrum, India

INTRODUCTION - OBJECTIVE: To analyze presentation, surgical approaches and outcome of 311 cases of colloid cysts surgically managed between Jan 1980 to November 2012.

METHOD: Age range was between 9 to 66 years. Raised ICP headache was the most common initial presenting symptom in 74% followed by visual blurring in 7%, memory disturbance in 5.5%, intermittent headaches in 7.5%, drop attacks, gait unsteadiness in 4% and incidental in five patients (2%). Imaging with CT scan done showed the cyst to be hyperdense in 64%, isodense in 27% and hypodense in 4% of patients. Shorter duration of symptoms correlated with MRI T2 hyper intensity changes. While an interhemispheric transcalsal approach was used in 289, it was trans-cortical in 22 (endoscope assisted in 6 & endoscopically in 2).

RESULTS: Out of the 289 patients operated through the transcalsal approach, the cyst was removed through transforaminal route in 243, interforaminal route in 25, subchoroidal in 14 and suprachoroidal in seven. Twenty two patients underwent emergency surgery. Twenty eight patients had CSF diversionary procedure (14 patients referred with preoperative shunt done elsewhere and 14 required postoperative CSF diversion). Complications included impaired memory in 35, hemiplegia/hemiparesis in 9 and seizures in ten. There was an operative mortality of 1% (3 cases). All the eight patients who had symptomatic recurrence got reoperated and six out of these 8 had total excision at first surgery.

CONCLUSIONS: These potentially life threatening lesions can be removed safely through the interhemispheric transcalsal approach. Periodic follow-up with MR imaging is necessary as recurrence can occur even after total excision.

OP-137[Neurooncologic Surgery] MONO- AND MULTI PORTAL ENDOSCOPICAL APPROACHES IN THE TREATMENT OF INTRAVENTRICULAR BRAIN TUMORS

Albert Akramovich Sufianov

Federal center of neurosurgery, Tyumen, Russia

INTRODUCTION - OBJECTIVE: The endoscopic resection of intraventricular tumors represents a unique challenge to the neurosurgeon. These neoplasms are invested deep within the brain parenchyma and are situated among neurologically vital structures.

METHOD: We analyzed 36 patients with intraventricular brain tumors who underwent mono- and multiportal endoscopic approaches in the treatment. All patients were operated using endoscopic technique (rigid endoscopes, flexible videoscope) and neuronavigation techniques. Follow up period was 2.5 years.

RESULTS: All patients had surgery without intraoperative complications and mortality. We performed an endoscopic biopsy tumor and/or a ventriculostomy (n=16) (medulloblastoma - 4, astrocytoma - 6, ependymoma - 3, cavernoma - 2, unknown - 1). We performed an endoscopic biopsy and a partial tumor resection (n=4) (ependymoma, astrocytoma, craniopharyngioma, cavernous angioma). And we performed an endoscopic total removal tumor (n=16) (chorioid papilloma - 3, astrocytoma - 3, colloid cyst - 5, breast cancer metastasis - 1, pineocytoma - 1). Multiportal approach we performed after surgery, we observed transient complications in the form of growth of ventricular size, paresis of the cranial nerves, seizures.

CONCLUSIONS: Mono- and multiportal endoscopic approaches in the treatment of intraventricular brain tumors is a minimally invasive, safe and effective surgical method. Carefully planned access using neuronavigation is extremely important for endoscopic treatment. Surgeons learning curve!

OP-138[Neurooncologic Surgery] THE APPLICATION OF CONTACT LASER KNIFE IN MICROSURGERY FOR INTRACRANIAL TUMORS

Qing Zhu, Ailin Chen, Guodong Liu, Qing Lan

Department of Neurosurgery, Second Affiliated Hospital of Soochow University, Suzhou, China

INTRODUCTION - OBJECTIVE: To discuss the advantages and experiences of microsurgery for intracranial tumors by using contact laser knife.

METHOD: Nineteen cases of intracranial tumors were treated by microsurgery with LaserPro laser system (Photomedex Co., USA) during the period from December 2010 to August 2013, including 11 meningiomas, 2 neurilemmomas, 2 craniopharyngiomas, 2 lipomas and 2 gliomas (1 astrocytoma and 1 subependymoma).

RESULTS: Total resection was achieved in 15 cases (78.95%) and subtotal in 4 cases (21.05%). Thirteen of them had alleviated from symptoms postoperatively, and no improvement in 2 cases. Dysfunction of cranial nerves occurred in 3 cases, and intracranial hematoma occurred postoperatively in one case that resulting left paralysis. All of the cases were followed up from 2 to 34 months, and no recurrence was discovered from MR images. According to the Glasgow Outcome Scale, 13 cases in 5 points, 5 cases in 4 points, 1 case in 3 points.

CONCLUSIONS: The contact laser knife can precisely dissect and vaporize the intracranial tumors so as to facilitate the lessening of blood loss, the avoiding of unexpected injury, the shortening of surgical duration and the improving of total resection of lesions.

OP-139[Neurooncologic Surgery]

ENDOSCOPIC TRANSSPHEOID TRANSNASAL SURGERY OF PITUITARY ADENOMA

Daniyar Teltayev, Serik Akshulakov, Nurgan Ryskeldyev, Khalit Mustafin
National Center of Neurosurgery, Astana, Kazakhstan

INTRODUCTION - OBJECTIVE: To report the efficacy and safety of endoscopic transsphenoid transnasal surgery in our series of patients with pituitary adenoma.

METHOD: Four hundred thirty three patients undergoing endoscopic transsphenoid resection of pituitary adenoma at our center from November 2008 through March 2014 were included in our study. In all cases, we used endoscopic transsphenoid transnasal approach using a rigid endoscopes "Karl Storz" with 00, 300, and 450 visual angles. The access was carried out on both sides, allowing the operator and assistant to work simultaneously in almost all cases. Radical surgery was achieved by a careful revision of the operative field with 0° and 45° rigid Karl Storz endoscopes.

RESULTS: The total tumor removal was performed in 303 (69.98%) cases. In 130 cases (30.02%) we made subtotal resection. The main complications of the postoperative period were secondary hypopituitarism – 7 (1.62%) cases, postoperative rhinorrhoea – 5 (1.15%) cases, diabetes insipidus – 5 (1.15%) cases.

CONCLUSIONS: Transsphenoid transnasal approach is a less traumatic minimally invasive approach for surgery of pituitary adenoma. Endoscopic technique provides adequate vision field with satisfactory surgical manipulation.

Radicality of tumor removal with a decrease of intraoperative complications were achieved by clear visualization of the operative field in the application of 0° and 45° endoscopes, simultaneous operation of surgeons through both nostrils. Endoscopic transsphenoid transnasal surgery is an effective and safe treatment for patients with pituitary adenomas.

OP-140[Neurooncologic Surgery]

SAFE SURGICAL EXCISION OF CEREBELLOPONTINE ANGLE LESIONS

Mumtaz Ali, Bilal Khan Afridi

Department of Neurosurgery, Govt. Lady Reading Hospital, Peshawar, Pakistan

INTRODUCTION - OBJECTIVE: to know about the outcome of safe total removal of the cerebellopontine (CP) angle lesions

METHOD: this cross sectional study was conducted in our Department between January 2009 and December 2013 (5 years). Patients of any age with either sex harboring a CP angle lesions were included. Patients with a repeat surgery were excluded from the study. The patient age, sex, side and size of the lesions, any co-morbidity, neurological status and post-op conditions were recorded on a designed proforma. Pre-operative work up was done and operative record was kept. Patients were kept in intensive care unit and observed for any neurological deficit or mortality. All data was entered and analyzed using SPSS version 17. Data was expressed in form of charts and tables.

RESULTS: a total of 83 patients (n=73) were operated in the study period. The age range was from 16 years to 73 years, there were 31 males and 52 females with a male to female ratio approaching 1.5:1. The mean size in the largest dimension was 3.1 cm. there were 54 (65.05%) acoustic neuromas, 19 (22.89%) meningiomas, 8 (9.64%) epidermoid and 2 (2.7%) arachnoid cysts. Total removal was possible in 70 (84.93%) cases. Surgical complications were observed in total 13 (15.66%) including facial nerve palsy 4 (4.81%), shunting and explorations for hematoma. Mortality in our series was in 5 (6.8%) patients.

CONCLUSIONS: total removal of the CP angle lesions is possible in majority of patients with comparable morbidity and mortality.

OP-141[Surgical Neuroanatomy]

FULL-ENDOSCOPIC SUPRAORBITAL KEYHOLE APPROACH TO THE ANTERIOR CRANIAL BASE: A CADAVERIC STUDY

Mehmet Osman Akcakaya¹, Yavuz Aras¹, Pulat Akin Sabanci¹, Alican Tahta¹, Ozcan Gayretli², Aydin Aydoseli¹, Altay Sencer², Ilke Ali Gurses², Kemal Hepgul¹, Adnan Ozturk², Nail Izgi¹

¹Department of Neurosurgery, Istanbul School of Medicine, Istanbul University

²Department of Anatomy, Istanbul School of Medicine, Istanbul University

INTRODUCTION - OBJECTIVE: The supraorbital keyhole approach for anterior cranial base lesions has been increasingly used in clinical practice. The aim of this study is to describe the anatomical features and surgical exposure provided by the endoscopic supraorbital keyhole approach using quantitative measurements.

METHOD: Nine formalin-fixed human cadavers from the inventory of the Anatomy department were used. A total of 18 supraorbital keyhole craniotomies were conducted. The distances between the target anatomical structures and the dura mater at the craniotomy site, and the distances between deep anatomical structures were measured with purpose-designed hooks.

RESULTS: The mean size of craniotomy was 26.5 x 14.3 mm. The distance between the dura mater and optic canal was measured as 69.5 ± 6.7 mm; optic chiasm as 76.2 ± 5.4 mm; anterior communicating artery as 82.6 ± 6.1 mm; internal carotid artery (ICA) bifurcation as 74.7 ± 6.0 mm and the basilar tip as 94.9 ± 7.0 mm. The mean diameter of the optic canal was 7.4 ± 1.3 mm whereas the mean diameter of diaphragma sellae was measured as 8.4 ± 1.1 mm. The distances between the two optic canals and between ICA bifurcation and chiasma opticum was recorded respectively as 13 ± 1.7 mm and 11.3 ± 1.9 mm.

CONCLUSIONS: The results of this study showed that the anterior and medial aspects of the anterior cranial fossa can be visualized properly. Dissection of the ipsilateral arteries of Circle of Willis can be performed easily using an endoscopic "supraorbital keyhole" approach.

OP-142[Miscellaneous]

CONTROL STUDY OF MAGNETOENCEPHALOGRAPHY AND INTRAOPERATIVE MOTOR EVOKED POTENTIAL MONITORING FOR MAPPING PRIMARY MOTOR CORTEX

Yang Kun, Zou Yuanjie, Liu Hongyi

Department of Neurosurgery, Brain Hospital affiliated to Nanjing Medical University

INTRODUCTION - OBJECTIVE: To evaluate the accuracy of preoperative primary motor cortex mapping with magnetoencephalography (MEG).

METHOD: Twenty six consecutive patients with gliomas in the central area was conducted. Preoperative MEG was performed in each patient. The motor task paradigm is index-finger button pressing in a repeating pattern. The results of MEG were overlaid on the MRI, and registered to the neuronavigation system. The MEG activations were compared to intraoperative MEP monitoring. The compound muscle action potentials of forearm flexor and hand muscle responses were recorded during electrical stimulation.

RESULTS: MEG imaging were performed on 26 cases, failed on 2 cases. Every case had 1 ~ 5 activations. Direct cortical electrical stimulation (DCES) was performed at 41 activations, and transcranial electrical stimulation (TCES) was performed at 6 activations. Overall, the intraoperative MEP monitoring showed 24 positive targets, 1 activation of 1 case. The positive targets of the cases with obvious occupying effect are all at the ipsilateral central areas of the focus, and the targets of the cases with no occupying effect are at the ipsilateral M1 areas of the focus.

CONCLUSIONS: MEG is a high sensitive and reliable technique to locate the position of the primary motor cortex, and can be used for the presurgical planning in patients with central area gliomas.

OP-143[Miscellaneous]

THE FEASIBILITY OF PRODUCING PATIENT SPECIFIC ACRYLIC CRANIOPLASTY IMPLANT WITH A LOW COST 3D PRINTER

Eddie Tan, Ji Min Ling, Shree Kumar Dinesh

National Neuroscience Institute, Singapore

INTRODUCTION - OBJECTIVE: Decompressive hemicraniectomy is a commonly performed neurosurgical procedure worldwide. The resulting calvarial defect predisposes the underlying brain to injury from even trivial trauma and is cosmetically disfiguring. Commercially available preformed patient specific implants are anatomically accurate but costly. The authors investigate the feasibility of producing patient specific acrylic cranioplasty implants with the aid of a low cost 3D printer.

METHOD: With the fine slice brain CT scan data of a patient with a calvarial defect post hemicraniectomy, a skull phantom and a mold was designed with computer software and fabricated with a commercial low cost 3D printer utilizing the fused deposition modeling method. The mold was used as a template to shape the acrylic implant formed via a polymerization reaction. The implant was then fitted to the skull phantom. Cranial symmetry index was determined. The cosmetic outcome was assessed by an independent neurosurgeon and plastic surgeon.

RESULTS: The skull phantom and mold were successfully fabricated with the 3D printer. The application of acrylic bone cement to the mold was simple and straightforward. The resulting implant did not require further adjustment or drilling prior to being fitted to the skull phantom. The cranial symmetry index was 96.2% (cranial symmetry index of 100% for a perfectly symmetrical skull). The cosmetic result was satisfactory.


CONCLUSIONS: This study demonstrates that a low cost 3D printer may be used to fabricate a mold for use in the production of patient specific acrylic cranioplasty implant. Further studies are required to determine applicability in the clinical setting.

Mold

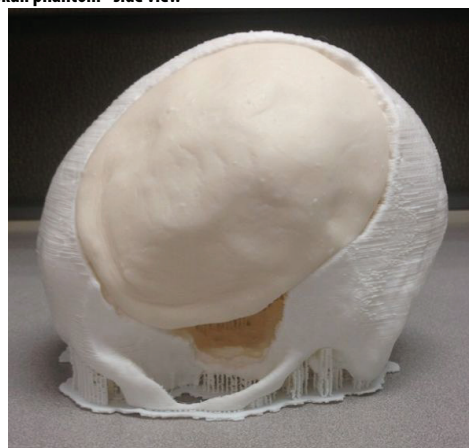Acrylic bone cement is placed on the mold to obtain the desired shape.

Mold with acrylic implant

The bone cement hardens in the desired shape.

Skull phantom - front view

Front view of the skull phantom with implant.

Skull phantom - side view

Side view of the skull phantom with implant.

Skull phantom - top view

Top view of the skull phantom with implant.

OP-144[Miscellaneous] HOW EVOLUTION INFORMS MODERN HUMAN NEUROCRANIAL FORM

Alexandra R Kunz¹, Andras Csokay²

¹Harvard University Extension

²St. John Hospital, Department of Neurosurgery

INTRODUCTION - OBJECTIVE: Neurocranial anatomical changes underlie major/adaptive vertebrate-history transitions, are diagnostic of hominin remains/lineages, reflect population history; endocranial windows reflect neurological organization.

METHOD: This paper addresses evolutionary aspects modern humans' neurocranium: prenatal "tinkering": small/embryonic regulatory-gene shifts; hominin vault stability, cemented through time; modularity/morphological-integration duality.

RESULTS: Prenatal hominin cranial base (CB) is key to understanding modern human neurocranial form origin; replacing skeletal CB growth pattern was a neural growth pattern: interspecies differences in CB/petrous-bone angulations, established embryonically before 10-week fetal intramembraneous-bone formation, associated with growth regulation at hierarchical levels linking genes with modules. Thus, species-specific distinctive/non-overlapping cranial architectural growth patterns would be present in its neonate, $p < 0.01$.

Longterm evolutionary stability was timely achieved by temporal/frontal/parietal bones to give selective advantage force shaping hominin fitness; dramatic temporal bone height increase, it's highly-arched squamosal suture retained/diagnostic, great-apes vs Homo erectus, 1.9Mya, $p < 0.001$; frontal bone's inner median sagittal profile's unexplained/extensive stability, invariant among all pre-modern-culture Homo species, over half million years; upper parietal bone height increase, discrete/rapid evolutionary organization change for higher integration, a dorsal bending/"convolution", overriding positional allometric instability, 500Kya.

Modularity denotes dissociability of developmental/functional/evolutionary processes: human modular variation, 33% increase gene-duplication driving force for cranial morphological change. Morphological-integration represents a suit of co-varying/correlated traits, inherited/selected together, a statistically quantifiable pattern; most important, overlapping residual co-variation matrixes expose hidden/orthogonal CB-sets' integrative factors, modular suits unique to human neurocranial vault.

CONCLUSIONS: These prenatal genetic shifts, hominin cranial stability forces, and unique modular suits may be responsible for most aspects of modern human neurocranial form.

OP-145[Miscellaneous] THE EFFECT OF SCIATIC NERVE INJURY OVER SOMATOSENSORY CORTIX

Murat Şakir Eksi¹, Ayça Arslanhan², Tüychiboy Mansurhonovich Abdullaev³, Zafer Orkun Toktaş³, Yaşar Bayrı², Deniz Konya³

¹Department of Orthopedics, University of California, San Francisco, California, Turkey

²Department of Neurosurgery, Marmara University Medical School, Istanbul, Turkey

³Department of Neurosurgery, Bahçeşehir University Medical School, Istanbul, Turkey

⁴Marmara University, Institute of Neurological Sciences, Istanbul, Turkey

⁵Sema Hospital, Almaty, Kazakhstan

INTRODUCTION - OBJECTIVE: Peripheral nervous system is responsible for mediating autonomic functions, conducting sensorial input from environment to the central nervous system, and relaying motor-response from the central nervous system to muscles and joints. Peripheral nerve injury has a high morbidity ratio. Injury in both macro- and micro-environment are both considered while planning the treatment. Nerve function can be evaluated with electrodiagnostic tests. Many electrodiagnostic tests have been used for monitoring central nervous system, especially the response of somatosensory cortex to peripheral nerve injury. But functional magnetic resonance imaging studies are scant in literature. Our aim was to evaluate the functional magnetic resonance imaging changes in somatosensory cortex after sciatic injury.

METHOD: Our study was done in Marmara University Animal Research Lab in 2013. Institutional Review Board approved our study protocol. Ten similar weighted and sized rats were enrolled. All rats were male. After peritoneal anesthesia, sciatic nerve injury was performed with meticulous surgical techniques in 5 rats' right hindpaws, in 5 rats' left hindpaws. During the experiment, rats were followed in the same room within different cages. During fMRI period, electrical stimulation under general anesthesia, was given in the same amplitude.

RESULTS: All rats' somatosensory cortex were active before the surgery. Post-op 2nd day, this number decreased to 9 rats, on post-op 15th day there were only 2 rats with active somatosensory cortex. Finally on post-op 30th day, we observed no activation in the presumed cortical area.

CONCLUSIONS: Somatosensory cortex metabolic activation level decreases due to disruption of sensorial inputs from injured peripheral nerves.

OP-146[Miscellaneous] TEMPORALIS TRANSPOSITION FOR FACIAL REANIMATION

Dalia Mofreh Elsakka, Fouad Mohamed Ghareeb

plastic and reconstructive surgery, Menoufiya university, Egypt

INTRODUCTION - OBJECTIVE: Permanent facial paralysis is one of the most important functional and aesthetic handicaps among the sequelae observed in plastic and maxillofacial surgery. The affected patient is deprived of one of the essential means of mental and affective expressions.

METHOD: Lengthening Temporalis Myoplasty done in 7 patients with facial paralysis

The technique presented here is a dynamic one; it makes it possible to regain a lost movement

RESULTS: Results are summarized in Table II, and they were noted by a third person who was not the surgeon. The traction on the upper lip is done on an anchorage zone of 3 to 4 cm wide, which gives a good definition of the nasolabial crease. The rate of morbidity was very low. We only had one infection that necessitated a revision

of the lip insertion and left no sequelae

CONCLUSIONS: facial reanimation of late facial paralysis can be achieved by temporalis reposition

OP-147[Neurotrauma and Intensive Care] SURGICAL CORRECTION OF DISLOCATION SYNDROME IN ACUTE SEVERE CRANIO CEREBRAL TRAUMA

Mirlan Jeenbekovich Sulaimanov¹, Mitalip Mametovich Mamytov², Kochkor Tolonovich Mendibaev³

¹The President of the Kyrgyz Association of neurosurgeons, Academician of NAS of the KR., Professor, MD,

head of the Neurosurgery Department of Medical Academy Mamytov Mitalip Mametovich. Kyrgyz Republic, Bishkek

²Head of the Neurosurgery Department of the №2 National hospital MSGR. CMN Mendibaev Kochkor Tolonovich. Kyrgyz Republic, Bishkek

³The doctor-neurosurgeon of the Neurosurgery Department of №2 National hospital 4 years Student extramural department of KRSU., Sulaimanov Mirlan Jeenbekovich. Kyrgyz Republic, Bishkek

INTRODUCTION - OBJECTIVE: to determine methods of surgical correction DS in acute period SBTI.

METHOD: surgical treatment of 135 patients with SBTI has been held in the clinic of neurosurgery for 2010-2012. The operation carried out in three ways: decompressive craniotomy (DC) with the plastic Dura and the excision of the lesion of the brain, bone-plastic craniotomy (BPC) and resection craniotomy (RC) with excision of the lesion in the brain.

RESULTS: BPC with removing hematoma was held for 32 patients with an epidural and subdural hematomas without focal lesions of the brain ($n = 51$), and RTC 19 patients with fractures of the skull bones. When analyzing the results significant difference has not been found statistically after operation between the 2 ways craniotomies. Patients with contusion of brain DS with intracerebral hematomas ($n = 84$) operation DC 51 patients and 17 patients had KPTC and 16 patients RC to remove the rest of the crush zone and intracerebral haematomas. After surgery patients showed statistically significant positive results in DC to remove lesions injury and bruises and duroplastics where in satisfactory condition discharged 43% of patients and death was 24%. Among the patients operated by the way of KPTC to remove lesions injury and bruises mortality rate was 47%, and RC ($n = 16$) 39%, respectively in satisfactory condition discharged 11% after BPC, and after RC 21% of the patients.

CONCLUSIONS: DC with the plastic Dura and the excision of the lesion brain is a more reliable solution dislocation of the brain in focal lesions of the brain tissue.

OP-148[Neurotrauma and Intensive Care] EXPLORING THE RELATIONSHIP BETWEEN ROTTERDAM COMPUTED TOMOGRAPHY SCORE AND SURGICAL OUTCOMES OF TRAUMATIC BRAIN INJURY

Muhammad Waqas, Muhammad Shahzad Shamim, Syed Faaiz Enam, Mohsin Qadeer, Iqra Patoli, Saqib Kamran Bakhshi, Khair Ahmed

The Aga Khan University Hospital Karachi

INTRODUCTION - OBJECTIVE:

OBJECTIVE: To explore the role of RCTS in predicting unfavorable outcomes, including mortality in patients undergoing DC for head trauma.

METHOD:

METHODS: This was an observational cohort study conducted from January 1, 2009 to March 31, 2013. CT scans of adults with head trauma prior to emergency DC were scored according to RCTS. A receiver operating characteristic curve analysis was performed to identify the optimal cutoff RCTS for predicting unfavorable outcomes (Glasgow outcome scale (GOS) = 1-3). Binary logistic regression analysis was performed to evaluate the relationship between RCTS and unfavorable outcomes including mortality.

RESULTS: 197 patients (mean age: 31.4 ± 18.7 years) were included in the study. Mean GCS at presentation was 8.1 ± 3.6 . RCTS was negatively correlated with GOS ($r = -0.370$, $p < 0.001$). The area under the curve was 0.687 (95% CI 0.595-0.779, $p < 0.001$) and 0.666 (and 95% CI 0.589-0.742; $p < 0.001$) for mortality and unfavorable outcomes, respectively. RCTS independently predicted both mortality (adjusted odds ratio for RCTS > 3 compared with RCTS ≤ 3 : 2.792, 95% CI 1.235-6.311) and other unfavorable outcomes (adjusted odds ratio for RCTS > 3 compared with RCTS ≤ 3 : 2.063, 95% CI 1.056-4.031).

CONCLUSION: RCTS is an independent predictor of unfavorable outcomes and mortality among patients undergoing emergency DC.

OP-149[Neurotrauma and Intensive Care] INTRATHECAL BACLOFEN THERAPY IN SEVERE HEAD INJURY: A RAW TECHNIQUE IN DEVELOPING COUNTRY

Prabin Shrestha

Department of Neurosurgery, Norvic International Hospital, Kathmandu, Nepal

INTRODUCTION - OBJECTIVE: Intrathecal baclofen therapy (ITB) has been found to be helpful for the unconsciousness state after head injury. However, this technology is not possible in developing countries where baclofen pump is not available.

METHOD: This is a case series study of ITB in the patients with severe head injury. The study was carried out in 6 cases in Nepal from 2009 to Jun 2012.

Baclofen pumping system is not available in Nepal. Instead, an spinal epidural catheter was used. The catheter was inserted into the thecal sac in lumbar spine. Baclofen was injected into the thecal sac with aseptic precaution. Dose of baclofen ranged from 50 to 200 microgram per day in multiple divided doses for 4-8 weeks. The inclusion criteria for ITB were vegetative state after head injury, more than 1 month post head injury and generalized spasticity.

RESULTS: Improvement in the spasticity was noticed within few days. Consciousness improved significantly to modified Rankin Scale (mRS) 3 within 1 month. In 3 of 6, therapy was discontinued after about 1 month due to infection. There was significant improvement within 6 months. Complications were CSF leak and infection. ITB was found to be more beneficial when used for longer period.

CONCLUSIONS: ITB is very helpful in severe head injury and vegetative state. Even a raw technique as explained, for shorter period can be of great help. This technique can be a life saving technique in developing countries.

OP-150[Neurotrauma and Intensive Care]

TEMPORALIS-BASED HINGE CRANIOTOMY: TECHNICAL MODIFICATION OF DECOMPRESSIVE CRANIECTOMY IN HEAD INJURY

Mohamed Ibrahim Refaat, Ahmed Mohamed Zaater, Ahmed Abdallah Elfiki
Department of Neurosurgery, Cairo University, Cairo, Egypt

INTRODUCTION - OBJECTIVE: Decompressive craniectomy (DC) was proven to be an effective therapy for intractable elevations of intracranial pressure. Hinge craniotomy is a modification for DC, decreasing the potential associated morbidities and the need for a delayed Cranioplasty.

OBJECTIVE: The aim of the current study is to investigate a modification for this procedure, using the patient's own temporalis muscle as a hinge for the bone flap.

METHOD: This is a prospective study on 20 cases indicated for decompressive craniectomy. In situ temporalis hinged decompressive craniotomy was done for all cases. Cases were followed up regarding their GCS, midline shift in CT scans, as well as ICP monitor values.

RESULTS: 85% of cases showed midline shift improvement in postoperative CT-scans, 75% of cases had postoperative GCS 15. ICP monitoring was used in only 5 cases, all of which showed normalization of ICP within 48 hours. We had 3 mortalities (15%) in our study.

CONCLUSIONS: Temporalis based hinging is a simple, less costly, and effective alternative for metallic plate application for in situ hinged craniotomy in cases of refractory elevations of ICP related to head injury.

OP-151[Neurotrauma and Intensive Care]

TOWARD ZERO MORTALITY IN ACUTE EPIDURAL HEMATOMA: A REVIEW OF 268 SURGICAL CASES IN SURABAYA, INDONESIA

Asra Al Fauzi, Rohadi Rohadi, Teddy Apriawan, Abdul Hafid Bajamal
Department of Neurosurgery, Airlangga University, Surabaya, Indonesia

INTRODUCTION - OBJECTIVE: Epidural Hematoma (EDH) is one of the most life threatening lesion in neurotrauma patients. While zero mortality is still a 'reasonable' goal in treating traumatic EDH, there are many facts and factors correlated in the fields. The purpose of this review was to evaluate the overall management and outcome of EDH in Surabaya, Indonesia.

METHOD: This study includes 268 consecutive patients operated on for EDH in our hospital from January 2009 to May 2012. Each patient was evaluated in terms of age, sex, hematoma localization, GCS score, neurological findings, and the time intervals with regard to referral and treatment course to determine the risk factors and problems that influenced the outcome.

RESULTS: We performed a chart review of 268 EDH patients in emergency department diagnosed by CT scan and surgically treated between January 2009 and May 2012. 77% patients were male, with a mean age of 27.1 years old. On admission, 30% patients were GCS 14-15, 43% GCS 9-13 and 27% GCS 3-8. Trauma operation interval after injury mostly after six hours 232 cases (87%) including 64 cases after 24 hours. 29% patients had anisocoric pupils. The most extracranial associated injury including musculoskeletal and head and neck. Thirty-one patients (11.56%) died after neurosurgical treatment.

CONCLUSIONS: Outcome of EDH depends on the several factors, including trauma operation interval, patient's age, clinical status preoperative and associated extracranial injury. Zero mortality in EDH seems 'still' unattainable specially in developing country scenario. The hospital facilities, transportation and communication system, and referral system may impact the outcome.

OP-152[Neurotrauma and Intensive Care]

1ST PROJECT OF KOREAN TRAUMA DATA BANK SYSTEM (KTDBS) 2009-2014: 2698 CASES OF TRAUMATIC BRAIN INJURY

Sang Koo Lee
Department of Neurosurgery, Dankook University, Cheonan, Korea

INTRODUCTION - OBJECTIVE: We will review the recent epidemiologic data of traumatic brain injuries as well as to research the factors that affect outcomes in Korea.

METHOD: About 5 year study(2009-2014) of 2798 cases in KTDBS (Korean Trauma Data Bank) participating 23 trauma centers were reviewed. All admitted head trauma patients were included. Original data have 8 categories(patient information/pre-hospital care/neuroimaging/medical treatment/surgical treatment/additional treatment/neurological outcome) including 121 items.

RESULTS: The population contained more males in total, 1915 men (71%) as compared to women 783(29%), with age ranging from 0 to 93 years(mean 52 year, median 55 year). Injuries from motor vehicle accident for 32.7% (882 cases). A large percentage (46.8 %) of non-motor vehicle accidents involving falls, assaults and leisure activities. Acute subdural hematoma (SDH) for 36.6%(988 cases) in main leading diagnosis. The outcome was assessed at the time of discharge by Glasgow outcome scale(GOS). Death(D) occurred in 7.7%(209 cases) and vegetable status(VS) in 4.0%(109 cases). Good outcome including GR(good recovery) for 72.5%(1958 cases) and MD(moderate disability) for 10.5% were considerably higher because of broad inclusion criteria including higher percentage of mild head injury. The outcome of traumatic brain injuries underwent worse progression after 50 years in men and 70 years in women. The cause of trauma and GOS had different patterns by age group.

CONCLUSIONS: We have reviewed 2698 cases enrolled data from 1st project of KTDBS in recent 5 years. The data showed the prevalence, management patterns, and outcomes affecting the epidemiologic factors such as mechanism of injury and age.

OP-153[Neurotrauma and Intensive Care]

A NOVEL HEMORHEOLOGIC TREATMENT FOR BRAIN ISCHEMIA AFTER TRAUMATIC BRAIN INJURY

Denis E Bragin¹, Gloria L Statom¹, Olga A Bragina¹, Marina V Kameneva², Edwin M Nemoto¹

¹Department of Neurosurgery, University of New Mexico School of Medicine, Albuquerque, NM, USA

²McGowan Institute for Regenerative Medicine, University of Pittsburgh Medical Center, Pittsburgh, PA, USA

INTRODUCTION - OBJECTIVE: Currently there is a lack of an approved neuroprotective strategy for post-traumatic ischemia after brain injury. We propose a previously unexplored approach based upon the direct modulation of hemorheologic properties of blood flow by drag-reducing polymers (DRP) which have been shown to improve circulation and survival in animal models of the ischemic myocardium and limbs but not yet in the brain.

METHOD: DRP or saline was intravenously injected after traumatic brain injury (TBI) in rats. The acute changes in cerebral microvascular flow, hypoxia and blood brain barrier (BBB) permeability were measured using in-vivo 2-photon laser scanning microscopy (2PLSM). Cortical Doppler flux, temperature, arterial and intracranial pressures, blood gases and electrolytes were monitored. Neurodegeneration was evaluated by Fluoro-Jade B at 24 hours and neurological motor deficit by Rotarod at 2 days, 1 and 2 weeks after TBI.

RESULTS: TBI compromised microvascular flow, induced hypoxia and BBB damage leading to neurodegeneration and neurological motor deficit. DRP restored flow in collapsed capillaries ($24 \pm 6.7\%$, Mean \pm SEM, $p < 0.05$, $n = 10$) and reduced the progression of ischemia and BBB damage by 16 ± 4.6 and $17 \pm 6.5\%$, respectively ($p < 0.05$) compared to saline group. The number of degenerated neurons was reduced by $44.2 \pm 12.6\%$ compared to saline treated animals ($p < 0.05$). The Rotarod tests showed better neurological recovery in DRP than in saline treated rats ($84.4 \pm 17.5\%$ and $54.2 \pm 15.0\%$ latency, respectively, as percent of pre-TBI).

CONCLUSIONS: DRP administered early after TBI improved and restored cerebral microvascular perfusion and tissue oxygenation in peri-injury area thereby protecting neurons from degeneration, and, as a result, improved neurologic recovery.

OP-154[Neurotrauma and Intensive Care]

BIFRONTAL DECOMPRESSIVE CRANIECTOMY FOR TBI PATIENT WITH PREGNANCY: A CASE REPORT

Thomas Tommy, S. Indharty, I. Japardi

Dept. of Neurosurgery – Universitas Sumatera Utara – Rumah Sakit Pusat Haji Adam Malik Medan

INTRODUCTION - OBJECTIVE: Background

The management of TBI with pregnancy is rare and challenging to obstetricians, anesthesiologists, and neurosurgeons because of conflicting anesthetic considerations and systemic condition that would complicate operative management. Advances in fetal and maternal monitoring, neuroanesthesia, and microsurgical techniques allow safe neurosurgical management of these patients. A multidisciplinary approach is essential in perioperative period and there seems to be no ideal best management.

METHOD: Case Report

A 34-year-old female arrived in our emergency unit seven hours after having a traffic accident. When she was walking on the side of road, a motorcycle accidentally hit her on her back and she fell on the ground. On admission she was GCS 10 (E3M5V2), symmetric pupil 3mm, good light reflex. She had tachycardia (HR 102 x/m) but other vital signs were normal. We did not find any fetal distress signs. She was in her third trimester of pregnancy with gestational age and viable fetus measured by ultrasound of 28 weeks. CT scan showed she had a bilateral frontal contusion with open basal cisterns and Lab results came with anemia (Hb 6). Because there was no given consent for an operation, we sent her to ward and gave blood transfusions and mannitol with tight neurosurgical observation. Phenytoin was not administered. 8 hours after ER admission, her consciousness decreased, GCS 8 (E2M5V1) and pupil asymmetry. After a family consent, she got intubated, CT scan, and emergency bifrontal decompressive craniectomy with falx cut and duroplasty were done. Fetal monitoring during and after surgery was done (Fetal Heart Rate ranges 135 – 153 x/m) and dexamethasone was given for fetal lung maturation.

RESULTS: Three days after surgery there was signs of fetal distress, our Obstetrics team decided to do normal delivery with induction of labor. The baby was doing well with Apgar 8/10 weighed 1900 grams. The patient had 2 weeks of ICU stay and another 2 weeks ward stay. GOS on discharge was SD (Severe disability). **CONCLUSIONS:** Cases of TBI with pregnancy must be managed with multi-disciplinary approaches fully tailored primarily for the health of mother and fetus (baby) considering fetomaternal physiology and risks of any procedures.



OP-155 THE IMPORTANCE OF A HEALTHY FOOD, WATER AND ENVIRONMENT FOR THE DEVELOPMENT & PERFORMANCE OF THE HUMAN BRAIN.

Prof. A.V. Ciurea MD., PhD., MSc. Dr. h.c. Mult.

H. Moisa MD. Carol Davila University School of Medicine, Bucharest, Romania. Sanador Medical Center, Department of Neurosurgery, Bucharest, Romania.

BACKGROUND: The authors debate the major actual problem of healthy alimentation and its impact on the development of the nervous system referring mostly to young persons and the intrauterine period. The modifications of the human genome through alimentation, water and environment can be in such circumstances unpredictable and irreversible.

MATERIAL: The development of the human body depends mostly on genetic factors. These in turn depend on a series of nutritional factors, environmental factors and possible nociceptive external aggressions. The maximal teratogenous period stretches from the 2nd week of pregnancy until the 30th week, with the brain being the most sensitive organ prone to lesions. The nervous cell is highly sensitive to teratogenous agents. Nutriments need to be chosen carefully to allow the best course of development of the organism and especially the nervous system. Young organisms until the age of 20 need to be protected from poisonous factors from food and the external environment. Studies from all over the world have demonstrated that food and water influence the genotype and the phenotype in a decisive way being the source or vector of a various array of diseases. The consequences of "industrial alimentation" enriched with growth hormones and other alimentary additives are shown in this study together with the poisonous effects of alcohol consumption, tobacco, drugs, radiation etc. Furthermore the authors bring in discussion quantum mechanics and physics studies that aim to show that all human beings are interconnected and that each one of us has the potential to influence his partners by what he thinks. At the end the authors insist upon alimentation issues promoting natural food and presenting in parallel the risks and possible consequences of genetically modified food.

The authors advocate against mall culture and industrial alimentation while presenting the advantages gained by natural alimentation and the use of several well known herbal remedies.

CONCLUSIONS: Natural alimentation is a crucial element in the development of the nervous system especially in the intrauterine period and early childhood together with the poisonous external factors.

KEY WORDS: Brain, Food, Water, Environment, behavior, fast food, mall culture.

OP-156 GAMMA KNIFE RADIOSURGERY FOR PARASAGITTAL MENINGIOMAS

Prof. Selcuk Peker

Acibadem University School of Medicine, Department of Neurosurgery, Istanbul, Turkey

Meningiomas involving the superior sagittal sinus (SSS) are among the most challenging tumors to treat. Authors of some recent series have advocated total removal with SSS reconstruction. However gamma-knife surgery is a reasonable choice for these tumors.

When a small meningioma involves the SSS and the sinus is patent, the first-line treatment should be radiosurgery. If the tumor is large and the sinus is patent, we recommend gross total resection with no removal of SSS. If postoperative or follow-up MR imaging demonstrates residual tumor or recurrence, gamma knife surgery should be performed. If a large meningioma has completely obliterated the SSS, our policy is to remove the tumor and all sinus tissue without reconstructing the SSS.

OP-157 CLINICAL USEFULNESS OF 3D-AND 4D-CT ANGIOGRAPHY FOR EVALUATION OF SPINAL DURAL AV FISTULAS

Kaoru Kurisu, Satoshi Yamaguchi, Masaaki Takeda, Yosuke Kajihara, Kazutoshi Mukada, and Shiro Kajihara

Department of Neurosurgery, Hiroshima University Hospital
1-2-3 Kasumi, Minami-ku, Hiroshima, 734-8551 Japan

OBJECT: The purpose of this study was to evaluate the usefulness of multidetector-row CT angiography (MDCTA) in demonstrating spinal dural arteriovenous fistulas (SDAVFs).

METHODS: The authors studied 10 patients with SDAVFs, including who underwent preoperative MR imaging, MDCTA, and DSA. In the evaluation of coronal sections of multiplanar reformation MDCTA images, inspection was focused on the presence of the following findings: 1) dilated perimedullary veins in the spinal canal; 2) focal enhancement of the nerve root, suggesting the location of the AVF, around the dural sleeve; and 3) a radicular vein that drains the AVF into perimedullary veins. The utility of 3D- and 4D-CTA was assessed by comparing its findings with those of DSA in each case.

RESULTS: DSA confirmed that the AVFs were located in the thoracic spine in 4 patients and in the lumbar spine in 6 patients, and MDCTA detected dilated perimedullary veins in all 10 patients. In 8 patients, there was focal enhancement of the nerve root. The radicular vein that drains the AVF into the perimedullary veins was found in 8 cases. In 8 cases, the MDCTA-derived level and side of the AVF and its feeder corresponded with those shown by DSA. Four D-CTA showed the draining point and direction of feeders and drainers.

CONCLUSIONS: The use of 3D- and 4D-CTA preceding DSA can be helpful to focus the selective catheter angiography on certain spinal levels. However, one should keep in mind that epidural AVFs with perimedullary drainage may resemble SDAVFs.

OP-158 MULTIMODAL MANAGEMENT OF ARTERIOVENOUS MALFORMATIONS. AN EXPERIENCE OF 244 CASES.

A PAPER DEDICATED TO PROF. ALEXANDER KONOVALOV.

1,2Prof. A.V. Ciurea MD., PhD., MSc., Dr. H.c. Mult

3Assoc. Prof. D. Mohan MD., PhD.

1H. Moisa MD.

4F. Stoica MD., PhD.

4A. Chefneux MD., PhD

1Carol Davila University School of Medicine, Bucharest, Romania. Department of Neurosurgery

²Sanador Medical Center Hospital, Bucharest, Romania. Department of Neurosurgery

³Bihor County Emergency Hospital, Oradea, Romania. University of Oradea, Faculty of Medicine, department of Neurosurgery. Oradea, Romania.

⁴Bagdasar-Arseni University Hospital, Bucharest, Romania.

BACKGROUND: Arteriovenous malformations are pathologic entities known since ancient times. The first excision of an AVM is credited to Pean in 1889 who operated on a 15 year old child. As soon as Egas Moniz's angiography was routinely introduced in practice the number of diagnosed AVMs increased and their management became routine for vascular neurosurgeons. Current techniques such as DSA or CBCT-a allow for correct diagnosis and surgical planning for the treatment of AVMs and maximize the chances of a good outcome for patients.

MATERIAL AND METHOD : The authors present 244 consecutive cases of AVMs : 113 operated using microsurgical techniques (46.3%), 105 treated with Gamma-Knife Surgery (43%) and 26 treated by embolization (10.6%) at the Bagdasar-Arseni University Hospital in Bucharest and at the Sanador Medical Center Hospital in Bucharest, between 2000 and 2014 (14 years). The including criteria were : patients diagnosed with AVMs admitted, investigated, treated and followed-up in our clinic. Excluded cases were AVMs diagnosed or treated in other services, malformations of the Vein of Galen and grade VI AVMs. The 244 cases represent 3.1% of all cases with mass lesions admitted in the period of time described above (7871 cases). There were 111 females (45.6%) and 133 males (54.4%) aged between 9 and 54 years of age with a median age of 21.9 years. The most affected age group was that of patients aged between 11 and 20 : 87 patients (35.6%). All the cases followed the same protocol for clinical and neuroimaging assessment (CT scan, MR, Angio-MR, DSA). Three therapeutical methods were used for these 244 cases – microsurgery, Gamma Knife Surgery and Embolization.

A number of 32 cases received combined procedures (13%). The positioning of the AVMs was : superficial in 178 cases (73%), deep supratentorial in 35 cases (14.2%), brainstem – 1 case (0.4%) and cerebellum 30 cases (12.3%). Clinical onset by hemorrhage was present in 202 cases (83%), seizures in 37 cases (15.1%), headache / progressive non-hemorrhagic neurological deficit in 24 cases (9.8%). The clinical features were dominated by headache in 209 cases (85.7%), followed by motor deficits in 78 cases (32.1%), seizures in 81 cases (33%), neck stiffness in 57 cases (23.2%) and vomiting in 35 cases (14.4%). The distribution according to the Spetzler-Martin Grading Scale for AVMs (1986) illustrated 60 cases of grade I AVMs (24.5%), 74 cases of grade II AVMs (30.4%), 62 grade III AVMs (25.4%), 37 grade IV AVMs (15.2%) and 11 grade V AVMs (4.4%). Multimodal treatment methods were adapted according to the AVMs sizes, locations, patient ages and associated conditions.

RESULTS : The postoperative complications were : recurrent hemorrhage 4/113 cases (3.3%) and obstructive hydrocephalus in 15/113 cases (13.1%) in which V-P shunts were inserted. Important complications after Gamma-Knife Surgery encompassed 2 cerebral ischaemic strokes, 1 intranidal AVM hemorrhage, 1 malignant brain swelling, 1 focal neurologic deficit. Other unusual complications were diffuse headache, seizures, dizziness. Complications for embolization were 1 case of intraparenchymal hematoma, 3 cases showing new neurological deficits and 6 cases of cranial nerve palsies.

A neurological evaluation at 6 months postop for the entire series (244 cases) showed : focal neurological deficits in 22 cases (9.2%), seizures in 60 cases (24.7%), cognitive deficits in 56 cases (22.8%), mental disturbances in 35 cases (14.4%), visual disturbances in 38 cases (15.4%) and obstructive hydrocephalus in 27 cases (11.2%).

The global outcome assessment using the Glasgow Outcome Scale at 6 months for all the 244 AVMs showed a good recovery in 41.8% (103 cases), moderate disability in 47.4% (116 patients), severe disability in 8.2% (20 patients), persistent vegetative state in 2 cases (1%) and death in 3 cases (1.5).

CONCLUSIONS: Epileptic seizures and intracranial hemorrhage are generally the initial symptoms in AVMs. For many years microsurgery has represented the best treatment for grade II-III AVMs. Gamma-Knife Surgery opens a new minimally invasive perspective for grade I-III AVMs. Large AVMs (grade IV-V) and AVMs in functional areas require a multimodal treatment : gradual embolization, microsurgical excision and GKS if necessary. Give that the patients are generally teenagers and young adults great emphasis must be placed on the patient's quality of life.

KEY WORDS : Arteriovenous malformation; Intracerebral hemorrhage; seizures; CT scan; MRI; MRA; DSA; Spetzler-Martin Grading System; Microsurgery; GKS; Embolization.

OP-159 IMPACT OF INTRAOPERATIVE VISUALIZATION ON OUTCOME AFTER BRAIN TUMOR SURGERY

H. Maximilian Mehdorn, Felix Schwartz

Dept. of Neurosurgery, University Hospital Kiel, Germany

Surgery of intrinsic brain tumors should bring to the patient the longest possible survival time yet with the best quality of life. In order to achieve these goals, intraoperative visualization and definition of the tumor and its surrounding structures has been aided since many years by using surgical microscope, next intraoperative neuronavigation („image-guided surgery“), tumor fluorescence e.g. aminolevulinic acid (ALA) and with growing frequency intraoperative magnetic resonance imaging (ioMRI).

There is a varying degree of proven efficacy for those methods: While no study has been performed to evaluate the use of surgical microscope, ALA has been shown to be beneficial with regards to progression free survival in high grade glioma patients. Intraoperative MRI has been shown in several studies to improve resection control both in low- and high-grade gliomas and other entities such as pituitary adenomas. Additionally applying awake craniotomy while resecting tumor in eloquent brain areas, has further improved functional outcome in these patients which in itself improves longterm survival.

Clinical data of our patients will be presented in whom awake craniotomy has been performed since 1994, ALA being a routine adjunct in glioma surgery since the early studies, and intraoperative MRI being used since 2005 also in the combination with awake surgery. Discussion will center on the requirements of systems to make brain tumor surgery safe and als more accessible in a variety of economic conditions.

OP-160 FUNGAL GRANULOMA IN BRAIN

Prof. Tariq Salahuddin

Intracranial fungal infection of central nervous system is a relatively uncommon infection, mainly among immunocompromise patients. It manifests as meningitis, infarction, or space occupying lesion of brain. Intracranial fungal granuloma are rare, mostly they are due to contiguous spread of infection from paranasal sinuses and rarely due to hematogenous spread from lung. Isolated cerebral granuloma are extremely rare without obvious extracranial focus of infection. Predisposing illnesses are diabetes mellitus, HIV infection, Organ transplantation, cancer chemotherapy, prolong steroid use and autoimmune disorders. We are presenting a review of 55 cases of cranial fungal lesion during past 11 years. This study specifically analyzed the outcome of cranial fungal granuloma by using different treatment modalities (medical/surgical). Different surgical options were used to determine the efficacy and achievement of better results depending upon the anatomical sites involved. Aspergillums spp was the most common causative agent in this series. Most of the intracranial fungal granuloma were as a result of spread of infection from paranasal sinuses 42 cases (76%). Purely intraparenchymal Fungal Granuloma with no evidence of nasal sinuses involvement 10 cases (18%) fungal osteomyelitis was seen because of direct invasion of infection following surgery for removal of extradural hematoma 2 cases (4%).

Our study showed excellent results in extradural fungal infection. Intradural extension required minimal invasive procedure like bur hole / stereotactic biopsies for tissues diagnosis, adjuvant medical therapy remains to be the treatment of choice. Intracranial excision of the lesion can flare up the disease process, hence should not be attempted. Antifungal therapy should be started as soon as the diagnosis is made.

OP-161 CRANIOPHARYNGIOMAS IN CHILDREN VERSUS ADULTS AN EXPERIENCE OF 167 CASES - QUALITY OF LIFE AND GLOBAL OUTCOME

(GKS INCLUDED)

1,2 Prof. A.V. CIUREA MD., PhD., Msc. Dr. h.c. Mult.

3 Prof. D. Mohan MD., PhD.

4D. Nica MD., PhD.

5F. Stoica MD., PhD

1H. Moisa MD.

6Virginia Rotarascu Medical Psychologist

¹Department of Neurosurgery, Carol Davila University School of Medicine. Bucharest, Romania.

²Sanador Medical Center Hospital, Department of Neurosurgery. Bucharest, Romania.

³Bihor County University Hospital. Oradea, Romania.

⁴St. Pantelimon University Hospital, Department of Neurosurgery, Bucharest, Romania.

⁵Department of Gamma Knife Surgery, Bagdasar-Arseni University Hospital, Bucharest, Romania.

⁶Department of Medical Psychology, Bagdasar-Arseni University Hospital, Bucharest, Romania. [Contact](#)

OBJECTIVES: Craniopharyngiomas (CPH) are benign, slow-growing, intra-cranial, calcified tumors, preponderant in children. The goal of this study is to analyze the outcome of a series of 167 cases of CPH out of which 132 were pediatric and 35 were adult. All cases were treated surgically and confirmed by pathologic examination.

MATERIALS & METHODS:

Authors performed a retrospective analysis for 132 consecutive children and 35 adults with CPH diagnosed and operated at the "Bagdasar-Arseni" University Hospital, Bucharest, Romania, and the Sanador Medical Center Hospital in Bucharest, Romania, over a period of 22 years (1993 – 2014).

In the cohort of children, males were slightly preponderant (69 boys and 63 girls), the disease affecting predominantly the age group 7 – 10 y.o. (54 cases – 40.9 %).

The clinical features consisted of visual impairment (89 cases – 67.4%), endocrine dysfunction (104 cases – 78.7%) and increased ICP syndrome (88 cases – 67%). Visual and endocrine symptoms prevailed. Headache, was frequently encountered – 114 cases (86.6%). Hydrocephalus was present preoperatively in 33 cases (25.4%) and was dealt with VP shunt insertion before definitive tumor therapy in 16 cases (12.3%). The essential neuroimaging exploration technique is currently MRI. No DSA investigations were carried out routinely. In adults (preponderantly 31-40 y.o., 21 cases) the main clinical picture was characterized by headache 31 cases (88.5%), visual impairment 28 cases (80%), and endocrine dysfunction 15 cases (42.8%). None of them received radiotherapy and/or stereotactic radiosurgery, before the surgical approach. All the cases underwent thorough endocrinological and neurosurgical investigations, pre- and postoperatively. Pathology: the adamantinoma type was preponderant in children (120 cases – 91.1%) while in adults it was minority (9 cases – 25.7%). The papillary type in children represented 8.9 % with 12 cases but in adults it was majority with 26 cases (74.2 %). In our opinion the pathology aspects are definitory in what regards tumor proliferation, calcification processes, adhesions, complications etc. The prevalence of adamantinomas generates a less optimistic prognosis in children. In our series, in children, the most frequent location of CPH was the suprasellar retrochiasmatic region (96 cases – 73.2%). Pathologically, combined forms (cystic type with calcifications) are prevalent: 71 cases (53.6%). A personal craniopharyngiomas grading scale was presented. In children, the surgical approach was adapted to the tumor location: bilateral subfrontal (42 cases–31.8%), unilateral frontal (26 cases–19.6%), and pterional (34 cases–25.7%), followed by midline interhemispheric (21 cases–15.9%), transcallosal (3 cases–2.2%) and combined (6 cases–4.5%).

In adults, the surgical approach varied as follows: subfrontal (20 cases–57.1%, subfrontal bilateral 12 cases, 34.3%, unilateral frontal 8 cases, 22.8%), interhemispheric (2 cases–6.3%), pterional (11 cases–31.2%), transcallosal 0 cases, transsphenoidal 2 cases (6.3%), combined approaches 0 cases.

RESULTS: All the cases (167 CPH) were followed up for a period ranging from 6 months to 18 years. In children: the total removal of the CPH tumor mass was the goal of the surgery, but this was achieved in only 72 cases (54.4%), due to the risk of functional impairment or possible operative mortality. In 12 cases (8.9%) a near-total resection was performed, in 45 cases (33.9%) a partial resection, and in 3 cases (2.2%) only biopsies were performed. Biopsies with cyst evacuation were performed only on giant, extremely compressive forms, in which tumor collapse was accompanied by bradycardia. Hydrocephalus was present in 35 cases (26.2%). No intraoperative death occurred. In the first month 6 deaths occurred (4.9 %), due to hypothalamic injury, in each case total removal had been attempted.

The real recurrences occurred in 22 cases from 72 cases of total removal (30.5%); tumor regrowth was noticed in 44 cases (70.9 %) from a total of 62 cases with remnant tumor mass (near-total, partial

and biopsies). The actual treatment targets cystic craniopharyngiomas which are prevalent in children. Despite all operative difficulties, all reinterventions must pursue the removal of the cystic part of the craniopharyngioma which determine compression on hypothalamic neural structures. Gamma Knife Surgery (GKS) was used in 9 (6.8%) cases in children, all with recurrences, but the results remain disputable as the tumoral cyst pressure required surgical decompression. In the adults series the total removal was achieved in 24 cases (68.5%), near total removal in 4 cases (11.4%), partial in 7 cases (20 %), and no biopsy. No perioperative death in 35 cases CPH, operated in adults. Recurrences and regrowth occurred in 4 cases (11.4%). Neuropsychological assessments revealed no altered IQ at individual level. The Intracranial Hypertension (ICP) and the tumor localization determined attention deficits. The extended tumor localization determines the mental deficiency and apathy. The recurrent tumors determine psychological dysfunction: attention, memory and the orientation. The depression factor varies with age and the QOL depends on the tumor localization. Psychosocial reinsertion is affected by memory dysfunction, medium moodiness and the forceless Ego. A good rehabilitation was recorded in 50% patients who underwent counseling before neurosurgical interventions.

CONCLUSIONS: The microsurgical treatment remains the main option, but the important number of complications, regrowths and recurrences demonstrate the necessity of a multidisciplinary approach: microsurgery, radiosurgery and endocrinological treatment. Total or partial removal depends on the tumoral volume and hypothalamic adhesions. Actually the authors advocate for partial removal with adjuvant therapies. The adamantinoma type was very important in recurrences and regrowths of CPH. Also, the authors present a CPH scale which facilitates the perfect location, surgical approach and outcome in this kind of tumor. MRI represents the gold standard for diagnosis, operative strategy and follow up in time.

KEY WORDS: craniopharyngioma (CPH), MRI, children, adamantinoma, CPH Scale, recurrences, regrowth, Gamma Knife Surgery

OP-162 MICROVASCULAR DECOMPRESSION FOR TRIGEMINAL NEURALGIA STUDY OF 275 PATIENTS IN TWENTY YEARS

Prof. Tariq Salahuddin

Terminal neuralgia (TGN) is a common pain syndrome and is characterized by recurrent episodes of intense lancinating pain in one or more divisions of the trigeminal nerve. Neurovascular compression (NVC) has been considered as the main cause of TGN in the root entry zone (REZ) of the trigeminal nerve in the cerebellopontine angle cistern. Micro vascular decompression (MVD) is the surgical procedure of choice for the treatment of medically refractory TGN. We retrospectively reviewed 275 cases of TGN operated in last 20 years. Latency period for surgery was 3-5 years; age range was 40-70 yrs. There was male predominance of 2.5:1. Majority of the patients had unilateral Symptomatology, 34% had left and 69% had right sided TGN, bilateral TGN in only 1% patient. Majority of the patients (92%) showed good relief of symptoms after MVD, 8% patients had relapse. Transient facial dysesthesia noted in 10% of patients which recovered in 6 to 8 weeks, 6 patients developed mild facial weakness that recovered, two of our patient suffered from wound site CSF leakage which managed conservatively by putting lumbar drain for five days. Other serious complications (VII & VIII Cranial Nerve palsy, ICH, Brainstem contusion) were not encountered.

CONCLUSION: MVD has shown to provide excellent results in patients with failure of medical treatment. Additionally, despite more invasive nature it has been accepted that MVD can provide the highest rate of pain relief and patient's satisfaction with lowest rate of pain recurrence.

OP-163 DEEP BRAIN STIMULATION FOR MOVEMENT DISORDERS AND BEYOND - PRACTICAL AND ETHICAL ISSUES

H. Maximilian Mehdorn, Daniela Falk

Dept of Neurosurgery, Kiel University Hospital, Germany

Deep Brain Stimulation (DBS) has gained increasing acceptance for movement disorders e.g. M. Parkinson (PD), Essential Tremor (ET) and other types of tremor and Dystonia. Many studies, in the best scientific standard randomized and controlled, have demonstrated its benefit when well indicated. In our dept. we have performed since 1999, more than 750 DBS operations in patients with standard indications, but also some rare indications have been operated upon, such as epilepsy, cluster headaches and SUNCT. Based on the traditional lesioning experiences and newer results sometimes discovered inadvertently, some groups have suggested further indications such as depression, obsessive compulsive disorders, addiction, and vegetative status. These indications need to be extremely well discussed with the patients resp. caregivers, if possible also in the framework of multicenter randomized trials, and the results should be published also when negative. Open discussion about risks, benefits and unclear situations including ethical implications should be warranted in order to promote ethically guided surgical improvement of movement disorders, mental diseases and psychiatric disorders.

OP-164 PURE ENDOSCOPY TRANSPHENOID SURGERY FOR TUMOR AT THE SELLA REGION

Julius July

Department of Neurosurgery, Medical Faculty of Pelita Harapan University
NeuroScience Centre, Siloam Hospital Lippo Village, -Tangerang, Indonesia

OBJECTIVE: In our institution, pure endoscopic transphenoid surgery has become a routine surgical approach for tumor at the sella region. The purpose of this study is to review the result and complication of this approach.

METHODS: All the data were collected retrospectively from March 2008 till July 2014. All the patients characteristic data were collected from the medical record, including the presenting symptoms, hormonal profile, ophthalmologic review, post operative complications, length of stay, Olfactory dysfunction, visual improvement, and symptoms improvement. All surgery were done by one primary surgeon (JJ) and might be assisted by one neurosurgeon, fellow, resident or nurse. Most surgery were done through one nostril (right). Univariate analysis were done and presented as percentage.

RESULTS: There were 349 cases (183 F, 166 M), average age 43,6 yo (range 14-80 y.o.). Majority of the cases are non functional adenoma (272 cases), the rest presenting with hormonal syndrome (31 cases) and pituitary apoplexy (26 cases). Others, turn out to be other lesion such as craniopharyngioma, infected mucocele, etc. Visual improvement after surgery 91.09%, 8.5% remain stable, 0.8% get worst on one eye. The surgical complication; CSF leak 7.7%, Mild DI 7.7%, Infection (meningitis, cacosmia) 6%, post operative delayed epistaxis 1%, post operative hematoma at tumor bed 0.5%, and other complication such as empty sella syndrome 0.2%, carotid injury 0.2%, second nerve injury 0.4%. One patient may have more than one complications.

CONCLUSION: Overall, a pure endoscopic transphenoid surgery for tumor at the sella region is a safe approach.

KEY WORDS.

Pure Endoscopic transphenoid. Pituitary adenoma. Sella tumor. Complications.

OP-165 MICROVASCULAR DECOMPRESSION FOR HEMIFACIAL SPASM

Julius July

Department of Neurosurgery, Medical Faculty of Pelita Harapan University
NeuroScience Centre, Siloam Hospital Lippo Village,
Tangerang, Indonesia

OBJECTIVE: One of the best indication for doing microvascular decompression (MVD) is hemifacial spasm. The purpose of this study is to review the result and complication of MVD for hemifacial spasm at our institution.

METHODS: All the data were collected retrospectively from August 2007 till July 2014. All the patients characteristic data were collected from the medical record, including the onset of symptoms, right/left side, the length of the disorder before they decide to have the MVD, prior botox injection, post operative course, post operative complications, and length of stay. Univariate analysis were done and presented as percentage.

RESULTS: There were 61 cases (36 F, 25 M), average age 49.2 yo (range 26-71 y.o.). Thirty seven on left side, and 24 cases on right side, none with bilateral. Average time before the patient decide to do MVD 4.4 years (range 1.6- 11.5 years). One third of the patients (22 cases) got botox injection (range 1-5 times). Fifty nine cases shows immediate relief of the spasm for the first two days, but 12 cases (19.6%) the spasm come back on day 3 and stay for almost 1-2 weeks before the spasm disappear at all. Two cases the spasm remain since day one after surgery, both cases underwent re-do surgery and the spasm disappear. The complications are; two cases (3.2 %) with permanent hearing loss on the same side, four cases (6.6%) with temporary weakness of the same side face at second week, and two cases (3.2%) with remote bleeding require clot evacuation, no CSF leak, no infection, and no mortality. Average length of stay 5 days (range 3-9).

CONCLUSION: Microvascular decompression is a safe approach and offering a cure to hemifacial spasm.

KEY WORDS: Hemifacial spasm. MVD. Post operative course. Complication.

OP-166 THE CHOICE OF THE OPTIMAL TREATMENT OF PATIENTS WITH METASTATIC BRAIN TUMORS

A.V.Golanov

The Burdenko Neurosurgical Institute, Moscow, Russia

Thanks to advances in surgery, radiotherapy, chemotherapy of the cancer patients and the development of neuroimaging, the number of patients with metastatic brain tumors (MBT) continues to increase. Currently, the number is more than 10 times higher than the corresponding figures for all primary CNS tumors . According to conservative estimates , at least 10% of patients with malignant tumors will develop MBT , which often cause life-threatening symptoms. Standard treatment for these patients is to remove the tumor, followed by irradiation of the whole brain (WBRT) . With the development of chemotherapy prognosis of patients with malignant tumors has improved significantly , but in respect of MBT success of chemotherapy is much more modest . In the case of inoperable cancer with MBT median survival is only about 50 days . For patients receiving WBRT is 2.8 - 5.4 months. Therefore, effective chemotherapy and local tumor control are of paramount importance for the prediction of quality of life. WBRT should be considered as under-treatment of patients with a better prognosis, as prospective randomized studies have shown that OVGM provides limited local control metastases with complete or partial response (24-55 %). Large MGM with clinically significant mass effect should be surgically removed, several prospective randomized studies have shown improved survival after resection compared WBRT in independent form. Radiosurgery large MGM usually not recommended due to an increased risk of later edema may associate with necrosis . At the same time, the development of equipment and procedures of modern radiotherapy, appearance apparatus type "CyberKnife" and techniques such as "IMRT" and "IGRT" , - have significantly expand the indications for stereotactic radiation , including at big metastatic brain tumors. In the nine years of its existence, department of stereotactic radiotherapy and radiosurgery (Burdenko Neurosurgical Institute) by modern standards using a variety of techniques have been treated about 12,000 patients , more than three thousand patients with MBT . The obtained results are consistent with international studies. It was shown that: - adding WBRT after surgical resection of brain metastases does not improve overall survival or duration of preservation of cognitive function , but improves the control of previously treated metastatic and new distant metastases; - in the same time in patients with a good prognosis and a single MBT (<3 cm) , to be applied either surgery or radiosurgery some patients with MGM can be treated with radiosurgery as an independent treatment option. With this control MGM may be important to preserve cognitive function of the brain, prevent worsening of neurological symptoms , but may not always have a direct impact on the survival of the patient , as determined by the patient's outcome status with systemic disease , lack WBRT after radiosurgery is associated with preservation of neurocognitive and better quality of life . In this situation, the chemotherapy is a major role since it usually is not interrupted during radiosurgery. It is shown that radiosurgery is developing as a new standard of care. Hypofractionated radiosurgery's role must be defined in the near future . Further data requires collection and analysis of results of the radiosurgical treatment, the correlation with survival and quality of life of patients with various MBT, depending on the condition of the patients , immunohistochemical and genetic features of cancer themselves ; with views of the treatment in various combinations , the volume and the number of metastasis ; radioresistance of tumors, including towards WBRT .

Fig 2a and 2b. CT of brain showing deep nuclear hematoma and postoperative scan of complete evacuation

Fig.3. Intra-operative view after dural opening and subfrontal retraction

Fig.4. Intraoperative view of opening the interoptic cistern

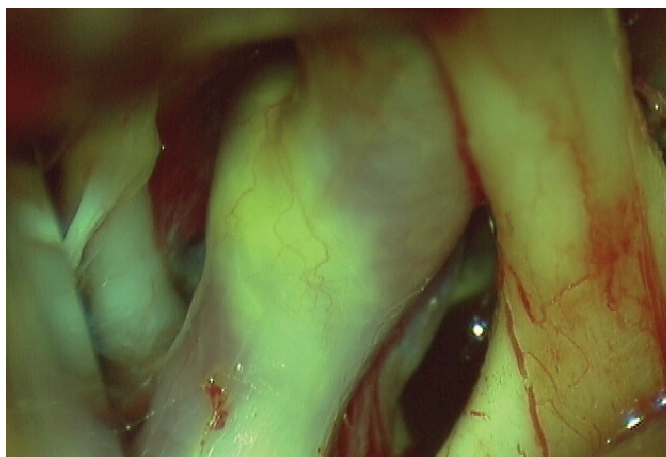


Fig. 5. Intraoperative view of optico-carotid and lateral carotid space

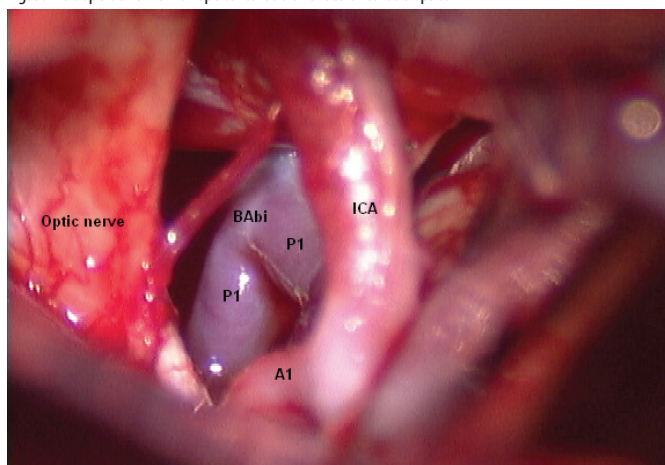


Fig. 6. Intraoperative view of Interpeduncular and pre-pontine cistern with basilar artery

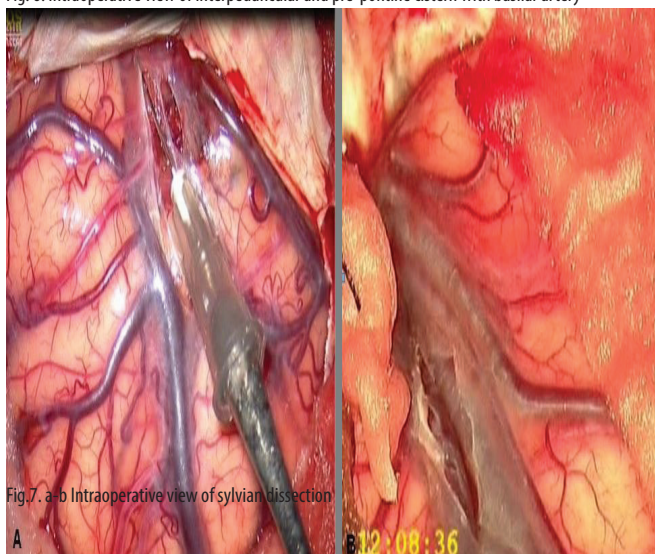


Fig.7. a-b Intraoperative view of sylvian dissection

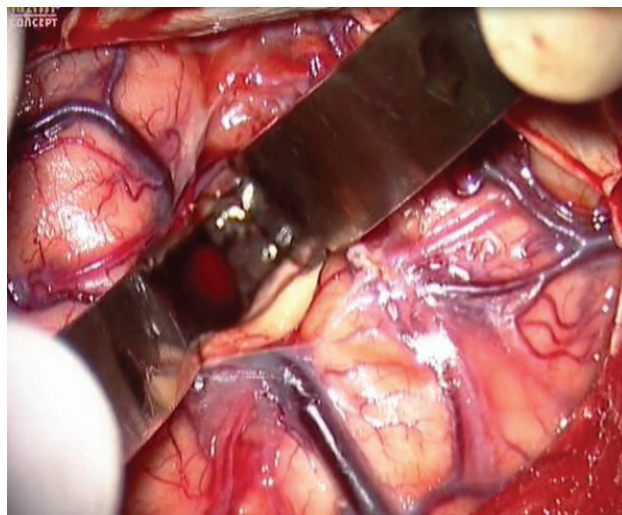
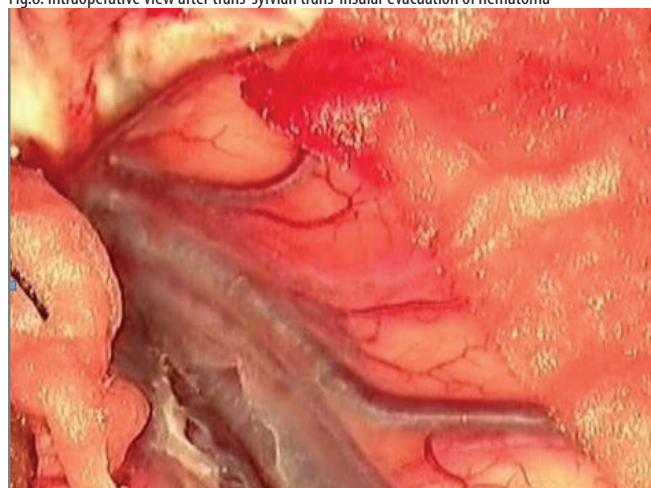


Fig.8. Intraoperative view after trans-sylvian trans-insular evacuation of hematoma



EP-001[Neurooncologic Surgery] OPPORTUNITIES AND IMPLICATIONS OF MODERN NEUROIMAGING IN BRAIN TUMOR SURGER

Dilorom Murodova, Makhmud Ahmediev, Rano Ismailova
Neurooncology department, Republican Research Center for Neurosurgery, Tashkent, Uzbekistan

INTRODUCTION - OBJECTIVE: DTI tractography is a method to visualize the orientation and integrity of the pathways of the brain in vivo. State of pathways in the depths of the brain may be estimated at present, while only using DTI tractography. The purpose of the study was evaluation of the results of surgical treatment of brain tumors using DTI-tractography, accompanied by intraoperative monitoring.

METHOD: We analyzed the results of treatment of 112 patients who were hospitalized at the Republican Scientific Center of Neurosurgery, Ministry of Health and operated under identical conditions. Surgery was performed under the control of intraoperative monitoring in the form of mechanogram using needle electrodes in m.bicepsbrachii, m.quadricepsbrachii and m. quadricepsfemoris, installed with geterolateral side.

RESULTS: Of the patients operated on our core group of marked regression of neurological deficit to 46.9%, which contributed to the leakage of the postoperative period without complications and improved quality of life and its duration. For the noninvasive and more complete removal of the tumor with maximum preservation of pathways, we used data mechanogram to visualize increase of the amplitude of muscle potentials and the appearance of sharp peaks in the motor tract irritation, allowing surgeons to more accurately determine the angle of attack, the amount of tumor resection.

CONCLUSIONS: Removal of intracranial tumors under the control of intraoperative monitoring mechanogram using data from MRI tractography, intraoperative ensure accuracy and safety of surgery to minimize surgical trauma, helps reduce the risk of neurological deficit, which determines the efficiency of operations and good quality of life of patients.

Before and after surgery On images with tractography revealed deformation and ousting tracts. Infiltration: a slight decrease in the anisotropy of dislocation without fiber pathways are readily identified by color charts.

The results of our study showed that the improvement in outcomes of surgical treatment of patients with tumors of supratentorial localization depends on an assessment of changes in the white matter of the brain in terms of imaging pathways DT tractography one below examples of different localization

EP-002[Neurooncologic Surgery] MINIMALLY INVASIVE MANAGEMENT OF INTERHEMISPHERIC SUBDURAL EMPYEMA

Rakhmon Egamberdiev¹, Gulnara Alihodjaeva², Ulugbek Asadullaev¹, Uygun Altibaev¹, Jahingir Yakubov¹

¹Republican research centre of neurosurgery, Tashkent, Uzbekistan

²Tashkent Medical Academy, Neurosurgery Department, Tashkent, Uzbekistan

INTRODUCTION - OBJECTIVE: Interhemispheric subdural empyema makes 13-20 % of all purulent diseases of central nervous system. With the development of microneurosurgery, introduction in practice CT and MRI, the tendency to minimal invasive methods of treatment of interhemispheric subdural empyema is marked. The purpose is to study the possibilities of minimally invasive methods of drainage of interhemispheric subdural empyema by assistance of neuroendoscope.

METHOD: We observed 5 patients with interhemispheric subdural empyema, among them 3 patients were men. Middle age is 26 year. Etiologically patients are distributed as a complication of adjacent infections in paranasal sinuses – at 3 patients, posttraumatic – at 1, unknown – at 1 patient. Along with traditional methods of research, CT and MRI of a brain are investigated. To all patients performed removal and drainage of the cavity of the interhemispheric subdural empyema by assistance of neuroendoscope.

RESULTS: Minimally invasive drainage has allowed to receive in all cases positive results. In the postoperative period at 3 patients neurologic deficiency it is not revealed. Epilepsy and hemiparesis were observed at 2 patients. At postoperative CT revealed that intrahemispheric cleft was free of purulent mass.

CONCLUSIONS: Presence of modern methods of diagnostics, such as CT and MRI and neuroendoscope allows to diagnose and to operate patients with interhemispheric subdural empyema on time. Meanwhile accurate implantation of drainage tube can be achieved by endoscopic assistance. Minimally invasive removal and drainage of the cavity of interhemispheric subdural empyema allows to receive positive results.

EP-003[Neurooncologic Surgery] THREE-DIMENSIONAL RECONSTRUCTION OF CRANIAL NERVES AND CLINICAL APPLICATION EXPLORATION BASED ON DIFFUSION IMAGING TRACTOGRAPHY

Shuyuan Yue
Department of Nerosurgery, Tianjin Medical University General Hospital, Tianjin, China

INTRODUCTION - OBJECTIVE: Objective to investigate the feasibility of 3-dimensional reconstruction of cranial nerves (cranial nerves CNs) via diffusion imaging tractography, and attempt to apply in the preoperative planing of skull base tumor.

METHOD: METHODS 3-Tesla magnetic resonance imaging scans, including 3D-FSPGR, FIESTA and DTI, were used to collect information of 10 healthy subjects and 10 skull base tumor patients. DTI data were integrated into the 3D slicer for fiber tracking, overlapped anatomic images to determine course of nerves. 3D reconstructions of tumors were achieved to perform neighbour, encasing, invading relationship between lesion and nerves whose location was then recorded during surgery by surgical Observation and neurophysiological monitoring.

RESULTS: RESULTS Detailed fibers of the cranial nerves were depicted. Optic pathway showed perfect 3D streamline body, especially the posterior of optic chiasm. Oculomotor nerve coursed from the brainstem to the cavernous sinus distally, which also had high fidelity. Trigeminal nerve allowed visualization of gasserian ganglion as cisternal segment. Cisternal parts of abducent nerve, facial/ vestibulocochlear nerve, vagus nerve, hypoglossal nerve were also imaged well. Moreover, the 3D-spatial relationship between CN and skull base tumor estimated preoperatively by tumor modeling and tractography corresponded to the results determined during surgery.

CONCLUSIONS: CONCLUSIONS Supported by DTI and 3D slicer, 3D reconstruction of cranial nerve is feasible in normal and pathological circumstances. It will have a satisfactory clinical application perspective and greatly expand the scope of minimally invasive neurosurgery.

EP-004[Neurooncologic Surgery] CLEAR CELL EPENDYMOMA; A RARE VARIANT OF A CNS TUMOR: EXPERIENCES FIRST TIME TO BE REPORTED BY A TERTIARY CARE HOSPITAL IN PAKISTAN

Saad Akhtar Khan, Fauzan Hashmi, Ehsan Bari
Department of Neurosurgery, The Aga Khan University, Karachi, Pakistan

INTRODUCTION - OBJECTIVE: We aim to see the features, behavior, treatment offered, Recurrence, Progression free and overall survival of this rare entity in Pakistan.

METHOD: A retrospective cohort study conducted from 2003 – 2012. MRIs from the hospital data base and Histopathological slides were reviewed. Patients lost to follow-up were telephoned. Analysis was done on SPSS 20.

RESULTS: Nine cases of CCE. Median age 47 years. MRI showed hypo intense signals on T1-weighted images in 75% patients. T2 weighted images showed hyper-intense signals in all patients. Contrast enhancement was found in 7 patients (77.8%). Histopathology: Peri-vascular pseudorosettes seen frequently. Clear cells found focally in 4 and frequently in 5 cases. Anaplasia found in 77.8% cases. GFAP and EMA positivity in all cases. Ki-67 showed high proliferative index in 5 patients. Gross total resection in 5 patients (55.5%), Subtotal Resection in 4 patients (44.4%). 5 patients underwent surgery + radiotherapy, 3 patients underwent surgery+ Radiotherapy + chemotherapy. Recurrence in 7 patients. Repeat surgery in 3 patients, 1 patient developed disseminated CNS metastasis. Six patients died of the disease. Median Progression free survival 8 ± 8.7 months, mean overall survival 15 ± 17.62 months. Age, volume, Extent of surgical resection, WHO grade, Ki-67, Post surgical radiotherapy, post surgical concurrent chemotherapy & radiotherapy were statistically significant factors (P < 0.05) for progression free survival whereas age, WHO grade, Post surgical Radiotherapy and recurrence had statistical significance (P < 0.05) on overall survival and outcome.

CONCLUSIONS: CCE is a significantly aggressive tumor in Pakistan with prognosis worse than other parts of the world.

EP-005[Neurooncologic Surgery] OUTCOME OF SURGICAL TREATMENT AT PATIENTS WITH OBSTRUCTIVE HYDROCEPHALUS SECONDARY TO BRAIN TUMORS*

Rakhmon Egamberdiev¹, Gulnara Alihodjaeva², Ulugbek Asadullaev¹, Javlon Tuhtamurodov²

¹Republican Research centre of neurosurgery, Tashkent, Uzbekistan.

²Neurosurgery department, Tashkent Medical Academy, Tashkent, Uzbekistan.

INTRODUCTION - OBJECTIVE: The purpose is carry out comparative analysis of efficiency of various methods of liquor shunting operations depending on a level of occlusion at patients with hydrocephalus secondary to brain tumours.

METHOD: We observe and carry out analysis of medical in-patient cards of 37 patients with Obstructive tumor associated hydrocephalus, which are treated in the Republican Research Centre of Neurosurgery within 2008 – 2013 years. Age of patients ranged from 1 till 75 years. 37,8 % of them were male, 62,2 % female. Among our patients children aged 1-17 years were (43,3 %), and young and middle aged people aged 18-44 years were (37,8 %). 36 (97,3 %) patients from 37 were operated.

RESULTS:The group of patients in which has been performed tumor removal with the subsequent placement of ventriculocisternostomy by Torkildsen the lethal outcome were occurred in (29 %) patients. The group of patients which was performed ETV with the subsequent tumor removal recovery was marked in (84,2 %) patients. ETV and tumor removal was performed in (42 %) patients. Complications such as recurrence of hypertensive hydrocephalic syndrome were occurred in (15,7 %) patients, on whom subsequently performed ventriculoperitoneal shunting.

CONCLUSIONS: ETV in patients with tumors of posterior cranial fossa, complicated with Obstructive hydrocephaly, is an effective method and can be accepted as the first step for liquidation of hypertensive hydrocephalic syndrome. At a choice of tactics of surgical treatment in patients with Obstructive tumor associated hydrocephalus, it is important to consider patient's condition and stage of clinical compensation.

EP-009[Neurooncologic Surgery]

DYNAMICS OF MOTION DISORDERS AFTER SURGICAL TREATMENT OF PARASAGITTAL MENINGIOMAS

Alexei Buzunov, Vjacheslav Stupak, Ainur Karchalova, Liubov Krivoschapkina

Department of Neurosurgery, Novosibirsk Research Institute of Traumatology and Orthopaedics n.a. Ya.L. Tsivyan, Novosibirsk, Russia

INTRODUCTION - OBJECTIVE: Study of dynamics of motion disorders in patients after removal of parasagittal meningiomas of the medium and rear thirds of the upper sagittal sinus.

METHOD: Retrospective analysis of the results of surgical treatment of 84 patients operated for parasagittal meningiomas during the period from 2006 to 2009 has been carried out. The patients were 37-80 years old. They were supervised during 5-8 years. In 34 patients tumors were removed by standard methods (control group), in 50 of them Nd-YAG-laser was used (researched group).

RESULTS: Before the operation more than a half of the patients had focal neurologic impairment. In the control group 18 (52.94%) of patients had it, and in the researched group it was found in 29 (58%) patients. After the operation there were more patients with motion disorders: in the control group 24 (70.59%) and 37 (74%) in the researched group. In the postponed post-operative period with restorative treatment patients in all groups had regression of focal symptoms, but patients in the researched group had better results. Here only 17 (34%) patients had motion disorders of mostly slight degree, while in the control group they were present in 16 (47.06%) patients as moderate to severe hemiparesis.

CONCLUSIONS: Clinical results of treatment in patients with parasagittal meningiomas in a long term period confirm the effectiveness of the developed laser technologies while their surgical removal.

EP-010[Neurooncologic Surgery]

BACTERIAL NANO-CELLULOSE HYDROFILM AS A TRANSPLANT OF MENINGEAL FIBROBLASTS (EXPERIMENTAL TRIAL)

Andrei Lekhner¹, Peter Larionov¹, Maxim Filipenko², Vjacheslav Stupak¹

¹Department of Neurosurgery, Novosibirsk Research Institute of Traumatology and Orthopaedics n.a. Ya.L. Tsivyan, Novosibirsk, Russia

²Institute of Chemical Biology and Fundamental Medicine of the SB RAS, Novosibirsk, Russia

INTRODUCTION - OBJECTIVE: To evaluate properties of bacterial nano-cellulose hydrofilm (BNCHF) and effectiveness of its use as a transplant of meningeal fibroblasts (MF).

METHOD: In the experiment 0.5-2 mm thick BNCHF was used as MF transplant. BNCHF is polysaccharide produced by *Acetobacter xylinum*. It looks like hydrogel consisting of high frequency microfibrils with some important properties: hydrophilism, atraumatic ability, antibacterial activity, inertness (sterilization and autoclaving resistance), absolute biocompatibility, no gas exchange prevention, ability to reduce probability of scarring. The researched group of animals consisted of 20 chinchillas having craniotomy under anaesthetic, whose meningeal fibroblasts were excised in the area of 0.5 x 0.5 cm with subsequent implantation of BNCHF without extra fixation. On the 7th, 14th, 21st and 42nd day animals the histological material was evaluated.

RESULTS: No wound complications have been found in the researched group. Histologically, on the 7th day the material looked as follows: corrugated cell-free structure of BNCHF with cellular structure, no inflammatory reaction. On the 14th day: corrugated fibrous tissue with cellular structure, with areas of transformation of the cellular structure into hard fibrous tissue with neovascularisation. On the 21st day: cellular structures of beam build with neovascularisation; these structures are included into thick connective tissue, with areas of myxoid type of the connective tissue. On the 42nd day: fibrous connective tissue, connective tissue cellular structures with moderate vascularisation.

CONCLUSIONS: With account of the preliminary experimental results it can be concluded that BNCHF is a promising material for replacement of MF defects.

EP-011[Neurooncologic Surgery]

MICRO-RNA-DIAGNOSTIC AND TYPING OF BRAIN TUMOURS

Nikolai Kolesnikov¹, Sergei Titov¹, Mikhail Ivanov², Yulia Veryaskina¹, Larisa Akhmerova¹, Igor Zhimulev¹, Vjacheslav Stupak³, Andrei Lekhner³, Evgeniy Stupak³

¹Institute of Molecular and Cell Biology of SB RAS, Novosibirsk, Russia

²Vector-Best, Closed Company, Novosibirsk, Russia

³Novosibirsk Research Institute of Traumatology and Orthopaedics n.a. Ya.L. Tsivyan, Novosibirsk, Russia

INTRODUCTION - OBJECTIVE: Currently new methods and ways of early diagnostics of oncologic diseases are being researched and searched everywhere in the world; they are based on advanced technologies of molecular biology, ways of diagnostics of tumours based on Objective and reliable quantitative methods of evaluation of normal and pathological cells. Discovery of the new class of small noncoding RNA molecules with huge regulatory potential, micro-RNA (miRNA) resulted in considerable progress in this field. The goal of our research is comparative analysis of the expression profile of some microRNA in human brain tumours and detection of specific quantitative characteristics of their expression in tumours of different tissue types

METHOD: Intraoperative material is represented by tissues of tumours and normal tissues; they were obtained from 70 patients with different histopathological tumours types. To determine the expression level of miRNA real-time PCR was executed with amplifier CFX96 (Bio-Rad Laboratories, USA).

RESULTS: Four micro-RNAs were analysed, which, according to references, refer to oncogenic miRNAs, i.e. overexpression of which in cancer cells disturbs functions of suppressor genes, as well as two oncosuppressive microRNAs were analysed, the reduction of level of which results in activation of oncogenes, and miRNA-126 with an important role in angiogenesis.

CONCLUSIONS: The conducted research allowed us to detect specific expression profiles of microRNA typical for tumours of different tissue types and depending on the degree of their malignity.

EP-012[Neurooncologic Surgery]

UTILIZATION OF RADIATION THERAPY FOR NEUROSURGICAL CASES: COMPARISON BETWEEN NEUROSURGICAL CENTRES WITH AND WITHOUT DEDICATED NEURO-RADIATION FACILITIES

Liew Boon Seng¹, Rosman Azmin Kass¹, Adnan Johari Siregar², Mohammad Jaweed³

¹Department of Neurosurgery, Hospital Sungai Buloh, Selangor, Malaysia

²Department of Neurosurgery, Hospital Sultanah Aminah, Johor Bahru, Johor, Malaysia

³School of Medicine Taylors University, Lakeside Campus Subang, Kuala Lumpur, Malaysia

INTRODUCTION - OBJECTIVE: A timely and comprehensive treatment plan is essential for all neurosurgical cases. This study is to determine the utilization of radiation therapy as both primary and adjuvant therapies between neurosurgical centres with and without dedicated neuro-radiation facilities.

METHOD: Neuro-radiation census in the year 2012 of five neurosurgical centres without dedicated neuro-radiation facility (Group A) and one neurosurgical centre with such facility (Group B) were studied at the end of 2013.

RESULTS: A total of 665 tumours and arteriovenous malformations of the brain and spine cases were presented to these six neurosurgical centres. The mean percentage of cases requiring radiation therapy was 42.0% (Table 1). At the end of 2013, the percentages of cases that have completed their conventional radiotherapies and stereotactic radiosurgeries in Group A were 67.7% and 11.3% respectively. Meanwhile in Group B, the percentages were 100.0% and 66.7% respectively. The differences in completion of both conventional radiotherapy and stereotactic radiosurgery between the two groups were statistically significant ($p < 0.001$) (Table 2). Delays in initiation of neuro-radiation therapies have resulted in avoidable repeating surgeries. There were a total of 20 out of 208 patients (9.6%) subjected for repeating surgeries due to delayed neuro-radiation therapies in Group A, but none of the 71 patients in Group B was subjected for any repeat surgery. The difference was statistically significant ($p = 0.007$) (Table 3).

CONCLUSIONS: Every major neurosurgical centres should have their own dedicated neuro-radiation facilities if possible. Proper utilization may avoid unnecessary repeat surgeries, better tumour control and eventually ensuring better quality of life for the patients.

Table 1: Newly diagnosed tumours and arteriovenous malformations of the brain and spine cases in 2012 and referrals for neuro-radiation therapy in each neurosurgical centre

Neurosurgical centre	*a	*b	*c	*d	*e	#f	Total	Percentage
Dedicated neuro-radiation facility	No	No	No	No	No	Yes		
New cases	60	40	65	150	170	180	665	
Referrals for conventional radiotherapy	12	18	20	70	35	50	205	30.8%
Referrals for stereotactic radiosurgery	10	6	5	10	22	21	74	11.1%
Total neuro-radiation referrals	22	24	25	80	57	71	279	42.0%

* Group A: Neurosurgical centre without dedicated neuro-radiation facility # Group B: Neurosurgical centre with d

Table 2: Cases with completion of neuro-radiation therapy at the end of 2013 in each neurosurgical centre

Neurosurgical centre	*a	*b	*c	*d	*e	#f	Total in Group A (Percentage)	Total in Group B (Percentage)	p Value
Dedicated neuro-radiation facility	No	No	No	No	No	Yes	No	Yes	
Total neuro-radiation referrals	22	24	25	80	57	71	208 (42.9%)	71 (39.4%)	
Completed conventional radiotherapy (Percentage)	6 (50.0%)	14 (77.8%)	15 (75.0%)	50 (71.4%)	20 (57.1%)	50 (100.0%)	105 (67.7%)	50 (100.0%)	<0.001
Completed stereotactic radio-surgery (Percentage)	2 (20.0%)	0 (0%)	2 (40.0%)	1 (10.0%)	1 (4.5%)	14 (66.7%)	6 (11.3%)	14 (66.7%)	<0.001

* Group A: Neurosurgical centre without dedicated neuro-radiation facility # Group B: Neurosurgical centre with dedicated neuro-radiation facility ! Pearson Chi-Square

Table 3: Cases subjected for repeating surgery following delay in neuro-radiation therapy in each neurosurgical centre

Neurosurgical centre	*a	*b	*c	*d	*e	#f	Total in Group A (%)	Total in Group B (%)	p Value
Dedicated neuro-radiation facility	No	No	No	No	No	Yes	No	Yes	
Total neuro-radiation referrals	22	24	25	80	57	71	208 (42.9%)	71 (39.4%)	
Number of cases subjected for repeating surgery (Percentage)	0 (0%)	8 (33.3%)	5 (20.0%)	0 (0%)	7 (12.3%)	0 (0%)	20 (9.6%)	0 (0%)	0.007

* Group A: Neurosurgical centre without dedicated neuro-radiation facility # Group B: Neurosurgical centre with dedicated neuro-radiation facility ! Pearson Chi-Square

EP-013[Neurooncologic Surgery]

QUALITY OF LIFE OF PATIENTS AFTER REMOVAL OF BASAL MENINGIOMAS

Alexei Buzunov, Vjacheslav Stupak, Ainur Karchalova, Liubov Krivoshapkina
Novosibirsk Research Institute of Traumatology and Orthopaedics n.a. Ya.L. Tsivyan, Novosibirsk, Russia

INTRODUCTION - OBJECTIVE: To study quality of life of patients in the post-operative period after removal of basal meningiomas

METHOD: Retrospective analysis of treatment of 81 patients operated within the period from 2007 to 2009 for basal meningiomas was carried out. The first group (control) consists of 29 patients operated by standard methods, while the second group (researched) consisted of 52 patients operated with Nd-YAG-laser. The average supervision period comprised 5.9 years. Dynamics of life quality of patients according to Karnovsky scale before the operation and in the postponed post-operative period was analyzed.

RESULTS: The average life quality index at the pre-operative level was equal in both groups of patients. In the control group it comprised 73.18 ± 0.74 scores and 72.02 ± 0.62 scores in the researched group. After the operation the figures decreased in both groups and were notably different, comprising 65.32 ± 1.14 scores in the control group and 69.28 ± 0.82 in the researched group. In the postponed post-operative period considerable increase of these figures is observed, besides, they prevail in the group of those operated with laser (80.34 ± 1.04) as compared to the control group (71.6 ± 1.68).

CONCLUSIONS: The obtained results of surgical treatment of basal meningiomas in a long-term period demonstrated high effectiveness while using the original laser technologies.

EP-014[Neurooncologic Surgery]

SURGICAL TREATMENT OF INTRAVENTRICULAR MENINGIOMAS

Irakli Otarashvili¹, Giorgi Ingorokva²

¹G. Ingorokva

²I. Otarashvili

INTRODUCTION - OBJECTIVE: Intraventricular tumoral location is rare and accounts for 0.5% to 5% of all intracranial meningiomas. As compared to other intraventricular tumors

METHOD: 11 patients underwent craniotomy for intraventricular meningioma resection in high technology medical center university clinic in the period from 2009 till 2013. The mean age was 51 years. Among which women rate was 8(79%) patients, men 3(21%). Headaches and seizures were most frequent initial presentations. In all cases tumors were located in the ventricular trigone. Right sided tumor location was in 8 patients, left sided – 3. Pre-operative embolization we used in one case. There were posterior parieto – occipital transcortical

RESULTS: In all cases we used parieto – occipital transcortical craniotomies. Resection grade was Simpson I in 10 patients. Simpson II in one. Surgical mortality was zero

CONCLUSIONS: Correct understanding of microsurgical anatomy cooperates for further success in operation in Intraventricular meningiomas. operation of Pre-operative embolization is helpful reduce bleeding.

EP-015[Neurooncologic Surgery]

SURGICAL TREATMENT OF ACOUSTIC NEUROMA

Giorgi Ingorokva¹, Irakli Otarashvili²

¹Giorgi Ingorokva

²Irakli Otarashvili

INTRODUCTION - OBJECTIVE: A vestibular schwannoma, often called an acoustic neuroma (AN) are benign arising from the vestibular nerves, usually within the internal auditory canal, where hearing loss is the most common symptom. The goal of our study was identify the actual benefits and persisting problems in surgical treatment of AN using lateral suboccipital retrosigmoid approach

METHOD: 51 patients with ANS have been surgically removed in the High technology medical center university clinic. Age ranging between 19 and 75 years. All patients underwent lateral suboccipital retrosigmoid approach for ANs in the sitting position

RESULTS: Thirty-nine cases of tumors were totally removed(77%), and the rest 12 (33%) cases had subtotal resections. Facial nerves were anatomically preserved in 44(87%). Four cases had a facial nerve function of House – Brakman (H-B) grade 2 and 3 cases were Grade IV

CONCLUSIONS: The suboccipital retrosigmoid approach is a reliable approach for the total excision rate of tumor mass and the reservation rate of facial-acoustic nerve

EP-016[Neurooncologic Surgery]

GETTING AWAY FROM CONTRAST: IS APPARENT DIFFUSION COEFFICIENT (ADC) VALUE A BETTER PREDICTOR OF HIGH GRADE TUMORS THAN CONTRAST ENHANCEMENT?

Muhammad Waqas, Syed Faaiz Enam, Aneela Darbar

Section of Neurosurgery, The Aga Khan University Hospital Stadium Road PO Box 3500 Karachi.

INTRODUCTION - OBJECTIVE: Contrast enhancement on MRI is generally regarded a feature of high grade tumors. Different regions of the brain have diverse diffusion characteristics because of different tissue density. This makes ADC a potential tool in predicting tumor grade. The aim was to evaluate ADC value as a predictor of tumor grade and compare it with predictive value of contrast enhancement.

METHOD: Cases of primary brain tumors operated over 2 years were included. Preoperative ADC mapping and contrast enhanced sequences of patients undergoing tumor excision/biopsy were reviewed on a workstation (1.5 Tesla). Lowest mean ADC of the tumor was recorded. Tumor pathology reports were then reviewed and dichotomized into low (I,II) and high (III,IV) grade. ROC (receiver operator curve) analysis was performed for mean ADC value which was then subdivided into low or high. Sensitivity, specificity, negative and positive predictive values of contrast enhancement and mean ADC value were calculated using SPSS v 19.

RESULTS: The study included 91 patients. The mean age of the patients was 35.9 years. Females comprised 67% of the sample. 61.5% tumors had high grade pathology. Contrast enhancement was 91.1% sensitive, 2.9% specific with negative and positive predictive values of 16.7% and 60% respectively. Area under the curve for ADC value as predictor of tumor grade was 0.808 (95% CI 0.71-0.90, p-value less than 0.0001). ADC value less than 800 was 75% sensitive and 74.3% specific for tumor grade.

CONCLUSIONS: Low ADC values are more likely to have high grade tumor pathology. Contrast enhancement is sensitive but lacks specificity.

EP-017[Neurooncologic Surgery]

CLINICAL ANATOMY AND DIAGNOSTIC VISUALIZATION OF EMISSARY VEINS

Florian Roser¹, Kristofer Ramina², Florian H Ebner²¹Department of Neurosurgery, Neurological Institute, Cleveland Clinic Abu Dhabi²Department of Neurosurgery, University Hospital Tuebingen, Germany

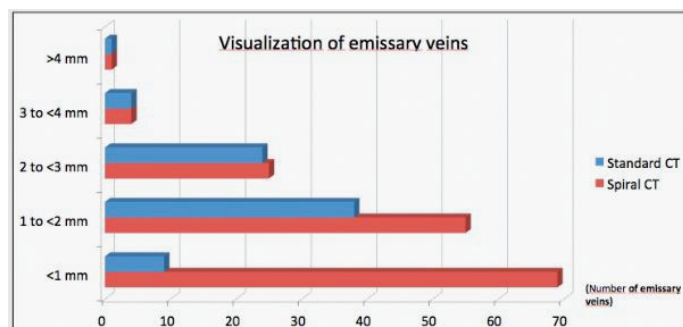
INTRODUCTION - OBJECTIVE: Emissary veins are often neglected in their clinical relevance. However at the retrosigmoid approach especially during semi-sitting positions these transosseous venous connections become potentially life threatening. Therefore knowledge of presence and the configuration of emissary veins is essentially in the preoperative planning.

METHOD: Two-hundred consecutive patients planned for the retrosigmoid approach due to a cerebello-pontine-angle pathology were evaluated by computed-tomography in standard technique (5mm slices) and spiral technique for the posterior fossa (1mm slices). The presence and size of emissary veins, entry point in the sigmoid sinus, the predilection side and the visibility in either CT technique were evaluated.

RESULTS: Emissary veins were present in 80% of the patients, varying from 0.3 to 4 mm in diameter, whereas 1% (right side) resp. 2% (left side) of the patients have more than one emissary vein. The mean length of the intraosseous course of the vein to the entry point in the sigmoid sinus was 7.6 mm (right side) and 5.1 mm (left side). The study shows that with standard CT-technique only emissary veins larger 1.0mm can be identified and that either entry point in the skullbase or sigmoid sinus cannot be securely visualized. On the other hand spiral technique CT-scans visualized emissary veins of 0.3mm with their exact course from the skull to the entry point in the sigmoid sinus.

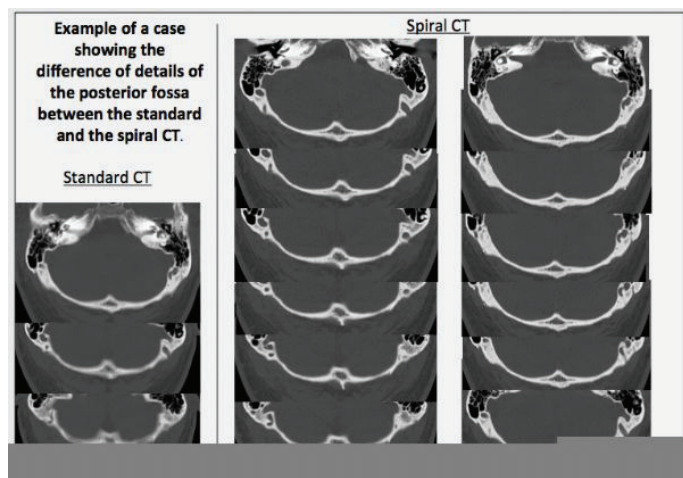
CONCLUSIONS: Thin sliced CT-scans are inevitable in the preoperative planning of the retrosigmoid approach in order to identify the presence and the course of emissary veins, reducing unnecessary morbidity during surgery.

data



Comparison of visualisation in standard and thin-slice technique

Case example



Example of a case showing the difference of details of the posterior fossa between the standard and the spiral CT.

EP-018[Neurooncologic Surgery]

ENDOSCOPIC ASSISTED SURGERY OF GIANT SKULLBASED EPIDERMoids

Florian Roser¹, Artemisia Dimostheni², Marcos S Tatagiba², Florian H Ebner²¹Department of Neurosurgery, Neurological Institute, Cleveland Clinic Abu Dhabi²Department of Neurosurgery, University Hospital Tuebingen, Germany

INTRODUCTION - OBJECTIVE: To report about endoscope-assisted surgery of large skull based epidermoid cysts focusing on the application of neuro-endoscopy and the clinical outcome in cases of epidermoid cysts.

METHOD: Twenty-seven consecutively operated patients (2005-2011) with an epidermoid cyst of the skull base were retrospectively analysed. Among them thirteen were giant, defined by compromising the brainstem and expanding over at least two skull fossa. Surgeries were performed both with an operating microscope (OPMI Pentero, Zeiss Company, Oberkochen, Germany) and endoscopic equipment (4 mm rigid endoscopes with 30° and 70° optics; Karl Storz Company, Tuttlingen, Germany) under continuous intraoperative monitoring (SSEP, MEP, AEP, MEP/EMG of anatomical and clinical affected cranial nerves). Surgical reports and DVD-recordings were evaluated for identification of adhesion areas and surgical details.

RESULTS: All cases were operated through the retrosigmoid approach despite the supratentorial extension of the epidermoid. In six cases cranial nerves I-XII could be visualized and documented through the standard approach. In all cases the endoscope was used as an adjunctive tool for inspection/endoscope-assisted removal of microsurgical remnants. The effective time of use of the endoscope was limited to the end stage of the procedure, but very effective. Neurological deficits were all temporary; no permanent postoperative morbidity/mortality was noted. Within the follow-up time (mean 32 month, 6-84) no recurrences have been detected.

CONCLUSIONS: In a modern operative setting giant epidermoid cysts may be removed through a standardized skull based approach with excellent clinical results. The combined use of microscope and endoscope offers relevant advantages in demanding anatomical situations.

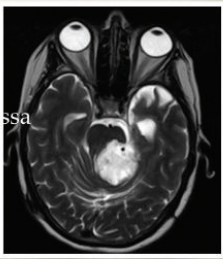
Epidemiology

Epidemiology

2005-2011
27 patients with Epidermoids

13 „Giants“ - posterior & middle fossa
> 200cm³


9 females / 4 males
mean age 44,7 years (25-65)




Epidemiology of presented cases

Technique

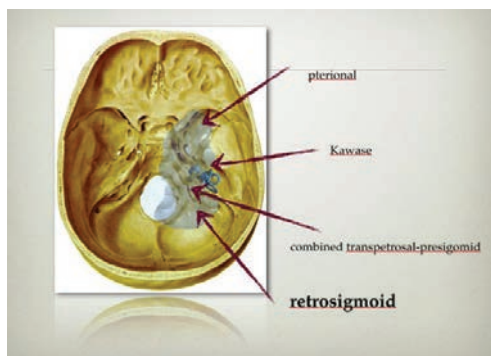
microsurgical en gross resection
endoscopic inspection
remnant identification
mobilisation with microsurgical instruments





The endoscopic-assisted microsurgical technique for removal of epidermoid tumours

Approaches



various approaches discussed for giant skull based epidermoids

Results

Literature

complete resection rates 97%
posterior fossa 75%

Santti M et al. Surgical treatment of epidermoid cysts of the cerebellopontine angle. J Neurosurg 1996; 84: 14-19
Talacchi A et al. Assessment and surgical management of posterior fossa epidermoid tumors. Neurosurgery 1998; 42: 242-251

present study

radical (incl. capsule)	none
complete	15%
remnants	85%

Time frames

Time frames

mean intra-op set-up (e'phys)	55 min
mean surgical time (skin-skin)	4h 13 min (2:36 - 6:55)
mean start endoscope	at 1h 55 min
mean ICU-days	1.2 (range 1-3d)
mean hospital stay	8.3 (range 4-21d)

Morbidity

Morbidity

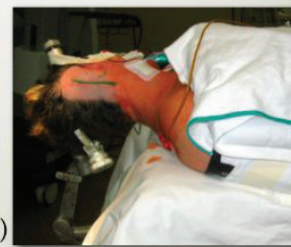permanent:	none
transient:	IV-palsy - 4 patients
	VI - palsy - 6 patients
	caudal CN - 2 patients
	Hemiparesis - 1 patient

CSF -fistula 1 patient (treated with LD)

Set-up

setup

supine position
retrosigmoid approach
Microscope (Zeiss Pentero)
Endoscope (30° and 70° Storz)
IOM (SSEP, MEP, AEP, VII-MEP, EMG CN III-XII)



the intra-operative set-up in this entity consists of supine position with the head flexed under continuous electrophysiological neuromonitoring.

Follow-up

follow-up

mean 34 month (range 6-84)
no recurrence / regrowth

Literature:

mean time to recurrence after gross total resection: 12 years

Guidetti B, Gagliardi FM. Epidermoid cysts. Clinical evaluation and late surgical results. J Neurosurg 1977; 47: 12-18
Lumardi P et al. Long-term results of surgical treatment of CPA epidermoids. Acta Neurochir (Wien) 1990; 103: 105-108

EP-019[Neurooncologic Surgery]

APPLICATION OF VISUAL EVOKED POTENTIALS AT REMOVAL OF SELLAR REGION TUMORS

Uygun Altibaev, Gayrat Kariev, Rakhmon Egamberdiev, Jahogir Yakubov, Ulugbek Asadullaev
Republican Research centre of neurosurgery, Tashkent, Uzbekistan

INTRODUCTION - OBJECTIVE: Tumors of sellar region make 15-18 % from all tumors of brain at adults. Reduction or loss of visual functions after tumor removal is connected with a lot of possible mechanisms. Application of monitoring during operation strengthens accuracy and attention of the neurosurgeon that, in turn, gives the early prevention of possible complications with the purpose of revealing of visual infringements before its irreversible damage. The purpose of our research is to estimate the role of intraoperative monitoring of the visual evoked potentials at patients with sellar region tumors.

METHOD: The work is based on results of treatment of 20 patients with tumors of sellar region, treated in the Republican centre of neurosurgery since 2011. All patients were operated via cranial approaches under monitoring of visual evoked potentials.

RESULTS: In our research the estimation of visual acuity at all patients before operation and in the early postoperative period was made. The application of intraoperative monitoring allowed prevention of long time irritation of optic structures, which causes ischemia, and decrease the visual functions. In our supervision the deterioration of visual acuity in postoperative period was not marked.

CONCLUSIONS: 1. Intraoperative monitoring of the visual evoked potentials is considered an OBJECTIVE, adequate and most informative method for an estimation of functional condition of structures of the visual analyzer at removal tumors of sellar region. 2. Application of intraoperative monitoring of the visual evoked potentials allows preventing and lowering the quantity of visual infringements at tumors of sellar region.

EP-020[Neurooncologic Surgery]

THE PREVALENCE OF THE BRAIN TUMORS IN THE SOUTH REGION OF THE REPUBLIC OF UZBEKISTAN

Abdurakhmon Mamatkulovich Mamadaliev
Neurosurgery Department of Samarkand State Medical Institute, Samarkand, Uzbekistan

INTRODUCTION - OBJECTIVE: The study of the prevalence of the different diseases among population presents a big scientific and practical interest. We in the accessible to literature could not find randomized trials regarding epidemiology of the tumors of the central nervous system in the South region of the Republic of Uzbekistan.

METHOD: For the last 13 years in our clinic it was surgical operated 465 patients with primary (328 patients) brain tumors and recurrent tumors 125 patients. Among recurrent tumors in 102 patients we determined neuroectodermal tumors and in 23 patients we determined meningo-vascular tumors.

RESULTS: Distribution of the patients with brain tumors among regions showed that in clinic there were 135 patients from Samarkand region, 102 patients from Kashkadarya region, 113 patients from Surkhandarya region, 28 patients from Navoiy region and 87 patients from Jizzakh region. Among received and operated patients in our clinic from the regions which were pointed above there were not any differences. But on the other hand from Samarkand region in 2013 it was received in 2 times more patients with brain tumors in the comparison from 2000. From Surkhandarya and Kashkadarya regions it was received in 1,5 times more patients with brain tumors in the comparison from 2000. From Jizzakh region it was noted some decreasing amount of patients with brain tumors in 2013 in comparison from 2000.

CONCLUSIONS: These data were telling us not only about the increasing number of the brain tumors, but also about the high operational activity of our neurosurgeons in our clinic.

EP-021[Neurooncologic Surgery]

ULTRASONIC ECHOLLOCATION DURING OPEN BRAIN SURGERY

Gennadii Ivanovich Okladnikov, Leonid Haritonovich Nesterenko, Oleg Mihailovich Kurov, Alexandr Gennadevich BObylev, Alexandr Evgenievich Mityukov, Ivan Victorovich Pendyurin
Novosibirsk Research Institute of Traumatology and Orthopaedics

INTRODUCTION - OBJECTIVE: Ultrasonic echolocation used in neurosurgical diagnosis allows detecting expansive processes in the brain based on midline echo displacement and other parameters.

METHOD: Echoencephalographic investigation during open brain surgery was performed in 60 patients with different pathologies: hemorrhagic stroke with intracerebral hematoma, traumatic intracranial hematoma, and glial brain tumors. Measurements were conducted with echoencephalograph "Echo 11" with 14 mm piezoelectric transducers and 1.76 MHz frequency.

RESULTS: In hemorrhagic stroke with hematomas echoencephalography detected sets of multiple unstable signals with bifurcated vertices and expanded base. At the background of high-amplitude signals reflected from the cavity filled with hematoma's liquid fraction, low-amplitude signals from blood clots were also identified. Similar pattern was obtained in traumatic intracerebral hematomas. EEG pattern in brain tumors had two variants depending on the tumor structure. In clearly delineated tumors signals with relatively high amplitude and narrow base and smooth edges suddenly appeared at the brain-tumor border. When ultrasound beam passed from the tumor to the brain tissue, moderate echo signal sets disappeared also suddenly. EEG pattern in infiltrating tumors had not sharply delineated set of polymorphic signals. Difference between brain echolocation findings in patients with dense and infiltrating tumors is apparently due to uneven acoustic barrier at the brain-tumor border.

CONCLUSIONS: Main indications for echoencephalography during urgent open brain surgery include: extremely severe condition, and inability to perform tomographic investigation (CT, MRI).

EP-022[Neurooncologic Surgery]

INDICATIONS FOR ENDOSCOPIC ENDONASAL TRANSSPHENOIDAL SURGERY

Dmitry Fomichev, Pavel Kalinin, Maxim Kutin, Boris Kadashev, Alexey Shkarubo, Sergey Alekseev, Ludmila Astafieva, Oleg Sharipov
Scul Base Department, Burdenko Neurosurgical Institute, Moscow, Russia

INTRODUCTION - OBJECTIVE: Indications for endoscopic endonasal transsphenoidal surgery.

METHOD: Endoscopic endonasal transsphenoidal approach.

RESULTS: For the last 10 years we gained a great experience in treating over 4000 patients by endoscopic endonasal transsphenoidal approach. The majority of patients had pituitary adenomas (P.A.) (85%). The other tumors were represented by craniopharyngiomas, chordomas, meningiomas, angiophyromas, cancers, arachnoid cysts etc.

CONCLUSIONS: Use of endoscopic technique permitted us to considerably broaden indications for transsphenoidal surgery. In particular, this approach allowed removal of P.A. with a small-size Turkish saddle, P.A. with secondary nodes as well as P.A. with a narrow neck between their superior and basal parts, and giant tumors (over 60 mm in size). Introduction of endoscopic technologies into daily practice permitted to evacuate tumors via anterior extended transsphenoidal approach which earlier could be hardly accessed by a transcranial approach: suprasellar craniopharyngiomas, meningiomas of planum sphenoidale and olfactory fossa, chiasmal gliomas, gliomas of III ventricular. Lateral extended transsphenoidal approach allows safety removal tumors invading cavernous sinus (especially when medial displacement ICA). Via posterior extended transsphenoidal approach is available the removal of clivus chordomas invading in posterior fossae. A modified method was used for a multilayer hermetic closure of major postoperative skull base defects and prevention of postoperative CSF leakage.

EP-023[Neurooncologic Surgery]

OUTCOMES FOLLOWING ENDOSCOPIC EXTENDED TRANSSPHENOIDAL RESECTION OF SUPRASellar CRANIOPHARYNGIOMAS

Dmitry Fomichev, Pavel Kalinin, Maxim Kutin, Oleg Sharipov
Scul Base Department, Burdenko Neurosurgical Institute, Moscow, Russia

INTRODUCTION - OBJECTIVE: In this study we discuss our experience in extended transsphenoidal

endoscopic approach to the suprasellar craniopharyngiomas.

METHOD: From last 6 years 143 patients with different purely supradiaphragmatic tumors (suprasellar craniopharyngiomas, meningiomas of planum sphenoidale and olfactory fossa, chiasmal gliomas, gliomas of III ventricular, cholesteatomas, some pituitary adenomas) underwent removal use extended endoscopic transsphenoidal transtuberculum transplanum approach. Most of the patients were with craniopharyngiomas - 100 pts. Four patients with craniopharyngiomas had been treated transcranial approach previously.

RESULTS: Total tumor removal was achieved in 70%. Vision symptoms improved significantly in 50% patients, 10% patients worsening vision. Endocrine functions did not improve after surgery, and endocrine dysfunctions (hypopituitarism and diabetes insipidus) increase after operations in 35% cases. Other main complications: bacterial meningitis - 9%, CSF-leaks - 10%, mental disorder - 2%. Recurrence rate 8%. Lethality 3%. Mean follow-up period is 36 months.

CONCLUSIONS: The endoscopic extended transsphenoidal approach for suprasellar craniopharyngiomas may be a viable alternative to the transcranial approach (pterional and transcallosal) in many cases and could significantly improve treatment outcomes craniopharyngiomas.

EP-024[Neurooncologic Surgery]

ENDOSCOPIC ENDONASAL TRANSSPHENOIDAL REMOVAL OF PITUITARY ADENOMAS: EXPERIENCE WITH 3000 PATIENTS

Pavel Kalinin, Dmitry Fomichev, Maxim Kutin, Boris Kadashev, Alexey Shkarubo, Sergey Alekseev, Oleg Sharipov
Scul Base Department, Burdenko Neurosurgical Institute, Moscow, Russia

INTRODUCTION - OBJECTIVE: Now endoscopic endonasal approach is main surgical approach in treatment of pituitary adenomas (p.a.). Used the endoscopic endonasal approach to the sella, without a transsphenoidal retractor or postoperative nasal packing, with a different rigid endoscope.

METHOD: We analyzed 3000 patients with p.a. who underwent endoscopic endonasal transsphenoidal adenomectomy (EETA) for the last 10 years. Only 19% p.a. in our series was endosellar, other had parasellar extension. A total of 77% of the patients had large (more 3cm) and giant (more 6cm) tumors. The distribution of p.a. by their hormonal activity: 32% - GH-secreting, 5% - PRL-secreting, 3% - ACTH-secreting, 60% - nonfunctioning p.a. The visual disturbances are revealed at 68% patients.

RESULTS: Tumor removal was total in 78% patients. Hormonal status was normalized in 73% cases. The improvement of visual functions or without dynamics in the early p/o period was observed at 96% patients. Postoperative complications (including CSF-leak, meningitis, nasal bleeding, new neurological deficits) occurred in 4%.

CONCLUSIONS: Advantages of EETA: the panoramic view of an operative wound, good light exposure of operative field. That allows precisely view the basic anatomic structures, to lower risk of their damage, radically remove a tumor, to reveal CSF-leakage and to close defect in tumor capsule. The EETA is less traumatic in comparison with microscopic transsphenoidal and transcranial operations, is more easy transferred by the patients, that reduces period of rehabilitation and term of hospitalization of the patients. Postoperative results show, that the designated advantages of a EETA allow to improve quality of surgical treatment of p.a.

EP-025[Neurooncologic Surgery]

OUR EXPERIENCE OF SURGICAL TREATMENT OF MIDLINE BRAIN TUMORS

Gayrat Maratovich Kariev
Republican Scientific Center of Neurosurgery Ministry of Health of the Republic of Uzbekistan, Tashkent

INTRODUCTION - OBJECTIVE: Group of brain tumors located in the midline, combines mass lesions of sellar and pineal regions, corpus callosum, III and IV ventricles, as well as the brainstem and features a large variety. Among all brain diseases tumors account for 4-4.5%, and 13-29% of this intracranial neoplasms are located along the midline.

METHOD: In this case, among all midline tumors, 80-90% are located in the posterior fossa. During the period from 2007 to 2014, 910 patients with midline brain lesions were treated in the Republican Center of neurosurgery.

RESULTS: Of them sellar region tumors were at 147 patients, tumors of third ventricle - 154 patients, tumors of pineal region - 89 patients and 269 patients presented with the lesions of vermis and 4th ventricle. In addition, the Observation included 213 patients with uni or bilateral falx meningiomas, and 38 patients with corpus callosum lesions. Of all 910 patients 876 patients were operated, in the remaining 34 patients the surgery was either contraindicated due to heavy somatic and neurologic status or not permitted by the patient relatives. Both transcranial and transnasal approaches were applied. In 65 patients with the localization of tumor in pineal region causing the Obstructive hydrocephalus only restoration of CSF circulation were achieved by ETV or shunt implantation. The postoperative lethality was observed in 62 patients, and the mortality rate reached 7.07% of all operated patients.

CONCLUSIONS: It should be noted that the highest mortality occurred in patients with lesions of posterior fossa structures.

EP-026[Neurooncologic Surgery]

FACIAL NERVE FUNCTION AFTER SURGERY OF BENIGN TUMORS OF THE CEREBELLOPONTINE ANGLE

Sergey Chernov, Jamil Rzaev, Anton Kalinovskii, Alexander Dmitriev, Alexander Zotov, Ekaterina Gormolysova, Nina Chischina, Elena Uzhakova
Department of Neurooncology, Federal Neurosurgical Center, Novosibirsk, Russia

INTRODUCTION - OBJECTIVE: To evaluate the facial nerve function after microsurgical removal of vestibular schwannomas and cerebellopontine angle meningiomas

METHOD: Since the 2013 to the present 33 patients were operated on. 20 patients were with vestibular schwannomas and 13 - petrous meningiomas. All patients were operated through a standard retrosigmoid approach using the operating microscope, microsurgical instruments and neurophysiological monitoring. The tumors by their size were divided as follows: over 6 cm - 5 patients (3 neuromas and 2 meningiomas), from 4 to 6 cm - 10 patients (8 neuromas and 2 meningiomas) from 3 to 4 cm - 10 (6 neuromas and 4 meningiomas), and less than 3 cm - 8 (3 neuromas and 5 meningiomas)

RESULTS: We evaluated the results as excellent if facial nerve function was the House – Brackmann grade 1 and 2 - 12 patients (36 % - 8 meningiomas and 4 neuromas), good (House – Brackmann grade 3 and 4) - 14 patients (43% - 9 neuromas, 5 meningiomas) and poor (5 and 6 grade) - 7 patients (21% - with neuromas only).

CONCLUSIONS: The best results were obtained in cases of meningiomas - in 8 patients (62 %) the facial nerve function was preserved; in 5 patients (38 %) developed House – Brackmann grade 3 dysfunction. In the group of patients with acoustic neuromas excellent result was achieved in only 20% of cases, good - in 45 % (9 of 20 patients), and poor - in 35 % (7 patients).

EP-027[Neurooncologic Surgery]

MULTIPLE PRIMARY MALIGNANCIES IN NEUROSURGICAL PATIENTS - THE EXPERIENCE OF THE FEDERAL CENTER OF NEUROSURGERY, NOVOSIBIRSK

Alexander Dmitriev, Sergey Chernov, Jamil Rzaev, Anton Kalinovskii, Alexander Zotov, Ekaterina Gormolysova, Elena Uzhakova
Department of Neurooncology, Federal Neurosurgical Center, Novosibirsk, Russia

INTRODUCTION - OBJECTIVE: To identify the role of neurosurgery in the diagnosis and its influence on the treatment in patients with multiple primary malignancies.

METHOD: From December 2012 to the present 17 patients have been operated on with brain tumors, which combined with malignancies in other organs. Patient age ranged from 47 to 76 years (mean 59.8). 12 were women - 70.5% and 5 - men (29.5%). Patients were directed mainly by oncologists with a history of one or two malignant tumors.

RESULTS: Among all patients, malignant brain tumors were noted in 70.5 % (12 patients), benign - in 29.5 % (5 cases). All benign brain tumors were meningiomas. Malignant tumors had different histological structure: glioblastoma - 7 (58.5%); B- cell lymphoma - 8.3 % (1); 8.3% (1 case) - low grade glioma; 1 - melanoma metastasis (8.3%); glandular cancer metastasis in 2 cases (16.6%). After morphological verification of brain tumors and their comparison with the proposed course of treatment without neurosurgical procedure in all cases were noted a discrepancy in the program of specific therapy. Moreover, in cases of meningiomas (5 patients), postoperative treatment was not required. Conversely, in 2 patients the localization of primary tumor and presence of the brain lesion assumed the refusal of adjuvant therapy. But after neurosurgical treatment and verification of the histology, these patients underwent a full course of chemotherapy and radiotherapy.

CONCLUSIONS: The verification of the morphological structure of any brain lesion is necessary, despite the oncological history, as it allows to determine the correct further treatment.

EP-028[Neurooncologic Surgery]

THE EXISTENCE OF HUMAN CYTOMEGALOVIRUS (CMV) IN PATIENTS WITH GLIOBLASTOMA MULTIFORME

Mahmoud Taha
King Fahad Specialist Hospital - Dammam, Saudi Arabia

INTRODUCTION - OBJECTIVE: The expression of CMV in GBM was shown in several studies which concluded that CMV sequences and expression exist in most, if not all, malignant gliomas (GBM), and this virus can modulate the malignant phenotype in GBM by interacting with key signaling pathways; and that CMV could serve as a novel target for a variety of therapeutic strategies. The objectives: 1-To investigate the presence of human cytomegalovirus (CMV) in primary Glioblastoma Multiforme (GBM) specimens of patients treated at KFSH - Dammam. 2-To assess if there is any correlation between the level of CMV expression and overall prognosis

METHOD: Retrospective study of all cases of GBM treated in our hospital for the last 6 years. The first part of the study is to investigate the presence of CMV by routine immunohistochemistry stains and molecular analysis on formalin-fixed and paraffin-embedded tissue blocks of all patients included in the study as per the inclusion criteria. The molecular analysis will be used to confirm the previous immunohistochemistry testing. The second part of the study will look into the correlation between degree of CMV expression (according to the grading used) and overall survival of the patient.

RESULTS: We have 46 patients with GBM for analysis. The study is ongoing and the results will be ready by August 2014

CONCLUSIONS: we have 46 patients with GBM for analysis. The study is ongoing and the results will be ready by August 2014

EP-029[Neurooncologic Surgery]

RESULTS OF SPINAL ONCOLOGY SURGICAL TREATMENT

Roman Khalepa, Klimov Vladimir, Loparev Eugeniy, Evsukov Alexey, Vasilenko Ivan
Spinal neurosurgical department, Federal Neurosurgical Center, Novosibirsk, Russia

INTRODUCTION - OBJECTIVE: The surgery of spinal tumors is one of the difficult directions in neurosurgery demanding individual and differentiated estimates of each patient

METHOD: During 2013 in spinal neurosurgical department 103 patients with tumors of vertebra bodies, extra and intradural tumors were operated. The age of patients varied from 22 to 74 years; middle age of 53 years. Women was 65% and men 35%. Tumor level: chest (51%) and lumbar levels (44%), cervical (18%), sacrum (0.98%). In 28 cases (27%) the tumor affected 2 vertebrae, in 2 cases 3 vertebra bodies (2%). With neurologic deficit were (54%) patients and without 46%. Before operation MRI, CT, X-examination analysis were provided to all patients to determine relationships with organs and tissues. Structure of tumors: vertebra bodies 54%; extradural 13%; intradural extramedullary 33%. For all patients with vertebra body tumors provided biopsy for definition of the nature of a tumor (primary or metastatic). In cases of primary tumors provided radical surgery. Metastatic tumors surgery was palliative and depended from Tokuhashi score.

RESULTS: We used posterior, posterolateral and anterolateral approaches in our surgery. Choice of approach was defined by localization and direction of growth of a tumor. Surgical stabilization of vertebra columns required in 53%. Histology of tumors: aggressive hemangioma 39% (vertebroplasty provided); metastatic tumors 17%; meningioma 13%; neuroma 9%; other tumors 22% (sarcoma, cavernous angioma, ependymoma). Rate of complications was 19%: deterioration of neurological deficit, hydro/pneumothorax, purulent complications.

CONCLUSIONS: Surgery of spinal tumors is difficult and demands the complex analysis of each case and preoperative planning.

EP-031[Neurooncologic Surgery]

SURGICAL TREATMENT OPTIONS FOR PITUITARY MACROADENOMAS: ENDONASAL TRANSPHENOIDAL AND SUPRAORBITAL EYEBROW APPROACHES

Radu Safta, Dina Sibgatullina, Eugen Condrea, Valerii Timirgaz
Institute of Neurology and Neurosurgery

INTRODUCTION - OBJECTIVE: Pituitary adenomas are the most common tumors of the sellar region. Current surgical route used to approach this lesion is the transphenoidal one, but in some cases, the tumor is difficult to remove by this method. We present our experience with surgical treatment of pituitary macroadenomas by transnasal, combined with supraorbital or by supraorbital approach alone.

METHOD: In the period covered by the present study, 97 operations for pituitary macroadenoma were performed. 58 patients were operated on by transnasal transphenoidal approach, 28 patients were operated on by supraorbital approach and 11 patients by combined transnasal - transcranial (supraorbital) approach in two stages.

RESULTS: For transnasal transphenoidal approach there was no operative mortality and no severe complications, as the lesion of the main intracranial arteries or neural structures. Our complications with this approach included postoperative advancement of the visual disturbances (2.8% of cases) and CSF leak (2.96%). Subtotal removal was achieved in 34.3% and partial removal in 14% respectively. In the group with transcranial route total removal was achieved in almost 60.4%, and subtotal removal in 39.6%. There were 3 intra and postoperative complications in this group, not related with the approach. No CSF leak was detected in the transcranial group.

CONCLUSIONS: Supraorbital approach is not the "Golden Standard" in the surgery of pituitary adenomas. It has certain indications in suprasellar and centrally located pituitary tumors. Our experience would suggest that the transcranial supraorbital approach may allow adequate removal of the pituitary adenomas with very good long-term results and acceptable complication rate.

EP-033[Neurooncologic Surgery]

RADIOLOGIC CLASSIFICATION OF CONVEXITY MENINGIOMA TO PREDICT THE SURVIVAL AND AGGRESSIVE MENINGIOMA BEHAVIOR

Silky Chotai, Yi Liu, Jun Pan, Songtao Qi
Nanfang Hospital, Southern Medical University, Guangzhou, China

INTRODUCTION - OBJECTIVE: The clinical, histopathological and radiological parameters for accurate prediction of meningioma behavior are lacking. The aim of present study is to propose a radiologic classification to predict aggressive meningioma behavior

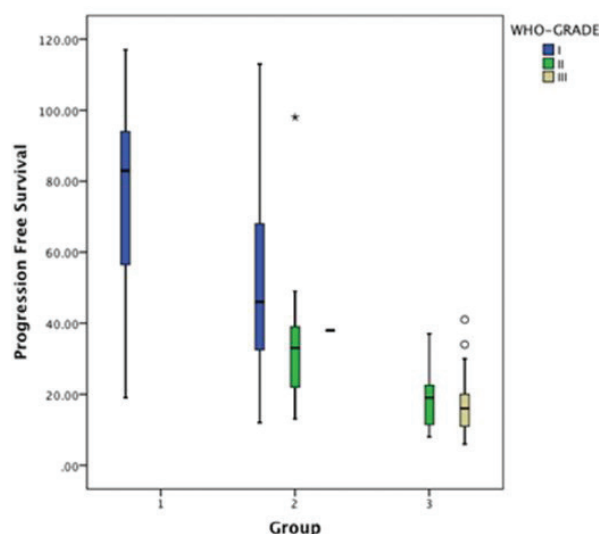
METHOD: A retrospective review of medical records was conducted for all convexity meningioma patients who underwent surgery as primary treatment. WHO 2007 classification was used for histopathological diagnosis. The radiologic parameters including signal intensity on diffusion weighted MRI (DWI), heterogeneity on T1-weighted gadolinium enhanced MRI, arachnoid layer and peritumoral edema (PTE) on T2-weighted MRI and tumor shape were reviewed. The presence of each parameter was scored 1 and

all patients were then classified into three groups. The survival, recurrence and recurrence free survival time (RFS) was analyzed

RESULTS: The hyperintensity on DWI, disruption of arachnoid layer and PTE on T2-weighted MRI, heterogeneity on T1-weighted gadolinium enhanced MRI and irregular shape of the tumor were all independent predictors of non-grade I meningioma and recurrence. The mean follow-up period was 94.6 months (range 12-117 months). The mean overall survival and PFS in groups-I, II and III was 114.1 ± 1.2 and 115.7 ± 0.8 , 88 ± 3.3 and 58.5 ± 3.9 , 43.2 ± 5.1 and 18.2 ± 1.7 months respectively. The MRI grading system significantly predicted unfavorable survival ($P=0.02$, OR= 3.1, CI=1.16-8.4) and recurrence ($P=0.001$, OR=6.5, CI=2.1-19.5). Group-II ($P<0.001$, OR=15.7, CI=4.9-50.1) and group-III ($P<0.001$, OR=151.2, CI= 37.8-604.2) predicted unfavorable outcomes.

CONCLUSIONS: The proposed scoring system predicted survival and recurrence outcomes for convexity meningioma. Group-I meningioma demonstrated benign radiologic, histopathologic and clinical behavior; group-III meningioma demonstrated aggressive behavior. Group-II meningioma might be considered intermediate and need for more aggressive management should be further investigated.

Figure



Progression free survival among groups I, II and III

EP-034[Neurooncologic Surgery]

INTRAVENTRICULAR BRAIN TUMORS: SURGICAL RESULTS

Taras Havryliv¹, Volodymyr Smolanka²

¹Regional Clinical Center of Neurosurgery and Neurology, Uzhhorod, Ukraine

²Uzhhorod National University, Ukraine

INTRODUCTION - OBJECTIVE: Intraventricular brain tumors account for approximately 10% of all tumors of the central nervous system. Despite the fact that some of these tumors are aggressive high grade lesions, most of them are histologically benign and potentially curable after surgical resection. The aim of the study was to identify patterns of surgical results in treatment of patients with intraventricular tumors, depending on the lesion location and its degree of differentiation.

METHOD: A retrospective analysis of 54 consecutive surgical interventions on intraventricular brain tumors that were treated at the Uzhhorod Regional Clinical Center of Neurosurgery in the period from January 2004 to February 2014. Localization of tumors was as follows: the fourth ventricle - 32 (59%), third ventricle - 13 (24%), lateral ventricles - 9 (17%).

RESULTS: Among intraventricular tumors prevail the tumors of the fourth ventricle (59%), the most frequent histological type - ependymoma (24%). The total tumor removal was achieved in 38 patients (70%), of whom in 33 (87%) the degree of tumor differentiation was grade I-II. Postoperative mortality was 9% (5 patients), of which 4 (80%) - with the localization of the tumor in the third and fourth ventricles. The results of treatment were assessed according to Karnofsky scale: more than 60 points - 46 (85%) patients.

CONCLUSIONS: Acceptable results of surgical treatment of intraventricular brain tumours are in direct dependence from the tumor localisation and its histological structure. The most unfavorable factor is the localization of tumors in close proximity to the brainstem and the low degree of tumor differentiation.

EP-037[Neurooncologic Surgery]

SURGERY OF PINEAL REGION TUMORS USING SUBOCCIPITAL SUPRACEREBELLAR APPROACH

Irakli Toidze, Vladimir Tsikarishvili, Irma Elizbarashvili
Khechinashvili Medical University Hospital

INTRODUCTION - OBJECTIVE: The surgical removal of pineal region tumors ranks among the most difficult neurosurgical intervention and neurosurgeons must have high skills for this type of surgery. The aim of present study was the assessment of advantages of suboccipital supracerebellar approach to pineal region tumors.

METHOD: We present data of 5 patients with pineal region tumors, which underwent open surgery by suboccipital supracerebellar approach.

RESULTS: All patients (Mean age 10,2 years old, 3 male/2 female) underwent neurosurgical intervention used suboccipital supracerebellar approach and gross total removal was achieved. MRI with contrast enhancement had been done in all patients before and after surgery, which demonstrated tumor radical removal. Pathological investigation were revealed - 2 pineocytoma, 2 pineoblastoma, 1 meningioma. Before and after surgery neurological assessment revealed the following: visual and ocular movement were impaired in 3 patients, imbalance and ataxia were found in 2, but all of them were temporary. All symptoms resolved in 3 months, long-term outcome was good in all patients 3 of them completely recovered, in 2 patients revealed only neurological signs, which were not interfere in everyday life. 2 patients with pineoblastoma underwent radiation therapy. In all cases marked hydrocephalus presented before operation. In two cases third ventricle was connected with cisterna magna by shunt. In 3 patients shunt weren't needed, because of restored of cerebrospinal fluid flow.

CONCLUSIONS: Our results suggested that suboccipital supracerebellar approach in cases of pineal region tumors is useful, valuable and sufficient to shape the surgical access to achieve total tumor removal.

EP-038[Neurooncologic Surgery]

SURGERY OF FORAMEN MAGNUM MENINGIOMAS USING CONVENTIONAL POSTERIOR SUBOCCIPITAL APPROACH

Irakli Toidze, Vladimir Tsikarishvili, Irma Elizbarashvili
Khechinashvili Medical University Hospital

INTRODUCTION - OBJECTIVE: We have analysed perioperative and short-term outcome in 7 patients with foramen magnum meningioma operated via posterior suboccipital approach.

METHOD: From 2007-2013, 7 patients with foramen magnum meningiomas were operated by use of conventional suboccipital approach with a midline incision, C1 laminectomy and suboccipital craniectomy with lateral extension toward the side of the tumor up to occipital condyle.

RESULTS: The age of patients varied from 35 to 69 years old. The tumor size was ranged from 2,4 to 4,2 sm. A partial condyle resection was performed in two cases to improve the exposure. Total tumor resection was performed in 6 patients and subtotal resection in 2 case, because of the enhancement to brainstem and VA-PICA junction. After surgery two patients developed low cranial nerves weakness. In one patient transient hemiparesis was developed. There was not any significant postoperative complication in other patients. The average length of follow up was 18 months. During follow-up there has been no recurrence of the tumor or growth of the residual tumor.

CONCLUSIONS: According to our experience we thought that a large majority foramen magnum meningiomas can be excised with lateral suboccipital approach and meticulous microsurgical techniques

EP-039[Neurooncologic Surgery]

RELEVANCE OF ICP MONITORING DURING TRANSPHENOIDAL PITUITARY SURGERY

Alex Kurnosov, Pavel Kalinin, Alexandr Shmigesky, Maxim Kutin, Dmitriy Fomichev, Oleg Sharipov, Alex Shkarubo, Sergey Alekseev
department of pituitary surgery, Burdenko NSI, Moscow, Russia

INTRODUCTION - OBJECTIVE: We introduced minimally invasive and effective techniques for identify hidden intraoperative liquorrhea.

METHOD: Forty two patients were included in the study (average age $48,7 \pm 2,93$). Patient's ICP has been examined by a lumbar drainage (LD). It was examined at the beginning and the end of operation.

RESULTS: Patients were divided into 3 groups: 1) Patients with LD which wasn't opened during the operation or was opened to remove CSF less then 30 ml CSF (15 patients); 2) The second group has had LD which was opened to remove CSF all the time more than 30 ml (17 patients); there were not dura mater injury and intraoperative CSF leak in the first and second groups; 3) patients with LD who has had intraoperative CSF leak and/or dura mater injury (8 patients). ICP was constant in the first group or was noted decrease of ICP (from $11,53 \pm 0,83$ mmHg to $8,33 \pm 1,11$ mmHg). It decreased to negative value (from $13,7 \pm 0,99$ mmHg to $-8,76 \pm 1,45$ mmHg) in the second group. ICP decreased to zero so long as there was CSF leak (from $13,62 \pm 1,36$ mmHg to $0,38 \pm 0,26$ mmHg) and became positive or negative after dura mater repair (average value $-4,62 \pm 2,29$ mmHg).

CONCLUSIONS: intraoperative CSF leak could be hidden or plastic defect could not be effective after TMO injury during endoscopic transphenoidal surgery. Intraoperative ICP monitoring via lumbar drainage is effective for detecting hidden intraoperative liquorrhea.

EP-040[Neurooncologic Surgery] USING HYPERHAES FOR ENDOSCOPIC ENDONASAL TRANSSPHEOIDAL SURGERY VERSUS LUMBAR DRAINAGE

Alex Kurnosov, Pavel Kalinin, Alexandr Smigelsky, Maxim Kutin, Oleg Sharipov, Dmitriy Fomichev
department of pituitary surgery, Burdenko NSI, Moscow, Russia

INTRODUCTION - OBJECTIVE: We introduced new effective non-invasive technique to reduce ICP.

METHOD: Lumbar drainage (LD) is used for decrease of ICP, but this method has several complications. Twenty patients were included in the study (average age $47,9 \pm 2,93$). They've got intravenous introduction of Hyper HAES (HH) 250 ml at the beginning of the endoscopic transsphenoidal approach. LD has been used to control ICP during surgery.

RESULTS: All patients had stable hemodynamic during operation. The lesser arterial blood pressure was $94,47 \pm 1,58$ mmHg at the beginning of operation. It was $98,4 \pm 2,47$ mmHg and $94,01 \pm 2,56$ mmHg at the access to the tumor and at the end of the operation respectively. The lesser heart beat was $75,55 \pm 1,33$ bpm. It was $80,9 \pm 1,44$ bpm and $77,9 \pm 1,3$ bpm at the access to the tumor and at the end of the operation respectively. ICP was been reduced after injection of HH (from $10,96 \pm 0,7$ mmHg to $2,5 \pm 1,04$ mmHg). Na⁺ increased from $142,95 \pm 0,55$ mmol/l to $150 \pm 0,71$ mmol/l after injection of HH in blood and Cl increased $-1,05,45 \pm 0,54$ mmol/l to $118,3 \pm 1,06$ mmol/l. Amount of electrolytes returned to normal rates during 24 h after injection of HH (Na⁺ - $144,15 \pm 0,61$ mmol/l, Cl - $102,55 \pm 4,5$ mmol/l). K⁺ was normal all time.

CONCLUSIONS: We've noted a positive effect after HH infusion – adequate raise of the tumor capsule.

EP-041[Neurooncologic Surgery] CT PERFUSION OF BRAIN IN ESTIMATION OF RESULTS OF GLIOBLASTOMA SURGERY

Mikhail E. Amelin, Boris G. Ivanov, Anna I. Nikolaeva, Elena P. Bartosh, Andrey M. Perfilov
X-ray department of Federal Center of Neurosurgery

INTRODUCTION - OBJECTIVE: To estimate results of surgical treatment of glioblastomas in near post-operation period using CT perfusion of brain.

METHOD: 54 patients with brain glioblastomas underwent surgical treatment. Before surgery and one day after we performed CT perfusion of brain with CT scanner Siemens Somatom Definition AS, 80 kV, 170 mAs, rotation time 1 sec, jog-scan, Z-axis range 80 mm, scan duration 50 sec. On perfusion maps we analyzed CBV, CBP, MTT, TTP and permeability in tumor and peritumoral brain tissue. After surgery we searched for residual tumor fragments with same CBP parameters, also we compared our findings with surgeon's opinion of operation results.

RESULTS: In 49 cases there were no residual tumor fragments, that could be estimated with perfusion CT maps, these findings corresponded to surgeon's opinion. We regarded total tumor excision when we found no tissue with corresponding parameters to tumor on perfusion maps. In 5 cases due to high risk of total excision on perfusion maps we could estimate residual volume of tumor tissue, in all cases its volume did not exceed 5-7% of initial volume of tumor. These findings also corresponded to surgeon's opinion. Residual tumor fragments had same CBV, CBP, MTT, TTP and permeability parameters as before surgery.

CONCLUSIONS: Brain perfusion CT in near post-operation period is high sensitive and high informative method in estimation of results of surgical treatment of glioblastomas.

EP-042[Neurooncologic Surgery] VASCULAR TYPE OF PRIMARY MANIFESTATION IN PATIENTS WITH PRIMARY BRAIN TUMORS

Alexey Ulitin¹, Istam Agzamov¹, Mansur Agzamov²

¹Department of Neurosurgery, Northwestern State University Medical Academy named by I.I. Mechnikov, Saint-Petersburg, Russia

²Department of Neurosurgery, Samarkand Branch of the Republic Research Center of Emergency Medicine, Samarkand, Uzbekistan

INTRODUCTION - OBJECTIVE: The clinical manifestation of primary brain tumors very often associated as vascular diseases, and therefore diagnosis of tumor of cerebral is very difficult.

METHOD: The results of examination and surgical treatment of 392 patients with brain tumors. There were 186 males and 206 females. The patients' age varied from 1 to 75 years. Children under 15 years was 38 cases, representing 9.7% of patients, in the age of 15-20 years - 30 (7.7%), 21-30 years - 46 (11.7%), 31-40 years - 67 (17.1%), 41-50 years - 82 (30%), 51-60 - 91 (23.2%), more than 60 years - 38 (9.7%) patients.

RESULTS: There were 269 patients with supratentorial location of tumors, 205 of them were operated; 95 patients – with subtentorial location, and 68 of them were operated. The vascular type of clinical manifestation were observed in 50 (12.7%) of cases, of primary tumor - in 238 (60.7%), epileptiform - in 92 (23.4%), psychopathological - in 12 (3%) cases. It was found, that in vascular type of clinical manifestation there were 62% of cases in which age of the patients was over 40 years. With moderate clinical manifestations were 35 (70%) patients, with severe manifestations and decompensated - 15 (30%).

CONCLUSIONS: Among patients admitted with primary brain tumors, the vascular type of clinical manifestation was identified almost a quarter of patients. Basically, this type of manifestation is marked in patients, over 40 years.

EP-043[Neurooncologic Surgery] ENDOSCOPIC ENDONASAL TRANSSPHEOIDAL SURGERY OF PITUITARY ADENOMAS INVADING THE CAVERNOUS SINUSES. SURGICAL OUTCOMES

Oleg Sharipov, Pavel Kalinin, Maksim Kutin, Dmitriy Fomichev, Boris Kadashev, Konstantin Popugaev, Aleksey Kurnosov

N.N. Burdenko Neurosurgical Institute, Moscow, Russian

INTRODUCTION - OBJECTIVE: We've investigated efficacy of a lateral extended transsphenoidal endoscopic approach (LETEA) to remove pituitary adenomas (PA) invading the cavernous sinus (CS)

METHOD: Parasellar extension of the PA was measured according to the Knosp Scale. All patients were divided into two groups: the first – the tumors were removed via a purely endoscopic transsphenoidal approach (60 patients); the second – the tumors were removed via LETEA (32 patients).

RESULTS: Parasellar extension according to the Knosp Scale was: Grade1 – 11 (11,96 %) cases, Grade2 – 21 (22,8 %) cases, Grade3 – 22 (23,9 %) cases, Grade4 – 38 (41,3 %) cases. There were nonsecretory adenomas in 48 (52,2 %) cases and hormone-secreting adenomas in 44 (47,8 %). Total resection was achieved in the first group in 51,7 % of cases, in the second group in 62,5 % of cases. The greatest amount of total resection were among the tumors with Grade1 and Grade2 extension (64,5 %) in the first group and with Grade4 extension (60 %) in the second group. Normalization hormone's levels were achieved in 14 cases (32,56%) with hormone-secreting adenomas. Overall neurological complications occurred in 13 cases (14,13%): 23,07 % of cases in the first group, 76,92 % of cases in the second group. CSF leak wasn't occurred in both groups (0%). There wasn't any vascular injury (0 %). There wasn't any mortality as well (0%)

CONCLUSIONS: LETEA is an efficient surgical technique in pituitary adenomas invading the cavernous sinus

EP-044[Neurooncologic Surgery] PLEOMORPHIC ADENOMA OF THE LACRIMAL GLAND

Volkan Murat Ünal¹, Nail Özdemir¹, Onur Yaman²

¹Tepecik Training and Research Hospital, Izmir, Turkey

²TÖBB Economy and Technology University, Ankara, Turkey

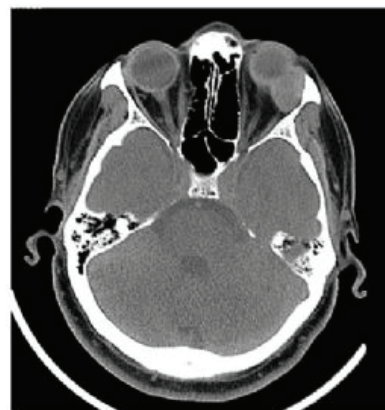INTRODUCTION - OBJECTIVE: Lacrimal gland tumors occur relatively rarely, accounting for 5-6 % of all lacrimal gland lesions. We are presenting case of pleomorphic adenoma of the lacrimal gland in a 34 year old male.

METHOD: A patient presented with 6 months duration of slowly progressing painless swelling in the lateral aspect of the left orbit. The examination of the left eye revealed a firm, nodular, non tender, non pulsatile and irreducible swelling in the lateral aspect of the left orbit. There was an exophthalmos of the left orbit. Although the vision examination of the right eye was within normal limits, the left eye was 0,3. Computerized tomography scan of the orbit showed a homogenous soft tissue mass (2x1,5 cm) in the lateral aspect of the left orbit without bone involvement. T1- and T2- magnetic resonance imaging revealed a hypointense and hyperintense mass of the left orbit, which was homogeneously enhanced by gadolinium-diethylene-triaminepenta-acetic acid (Gd-DTPA) administration.

RESULTS: Tumour resection was performed under general anesthesia, by doing a modified lateral orbitotomy. The tumour was removed a blunt dissection with the intact capsule. The histologic examination was diagnosed as pleomorphic adenoma. The postoperative period was uneventful. He was discharged without neurological deficits a ter postoperative seventh day.

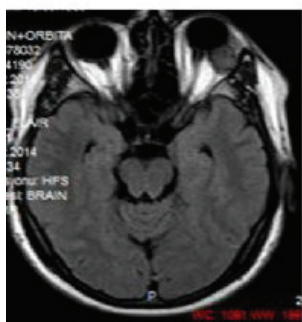
CONCLUSIONS: The most important point for diagnosis is that pleomorphic adenomas first manifest as painless exophthalmos. This tumour presents an excellent prognosis following a total excision, with the pseudocapsule.

Figure 1



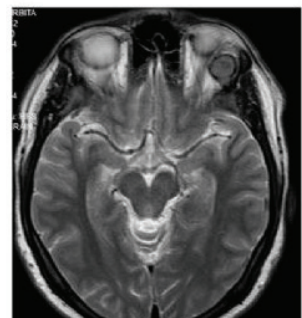
Computerized tomography scan of the orbit showed a homogenous soft tissue mass (2x1,5 cm) in the lateral aspect of the left orbit without bone involvement

Figure 2



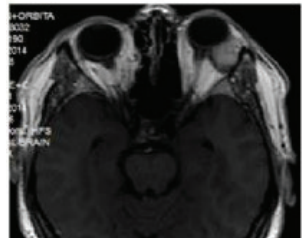
T1W magnetic resonance imaging revealed a hypointense mass of the left orbit

Figure 3



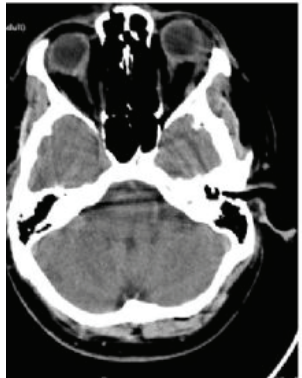T2W magnetic resonance imaging revealed a hyperintense mass of the left orbit

Figure 4



Magnetic resonance imaging after Gd-DTPA administration showed a homogeneously enhanced mass for left orbital mass

Figure 5



Tumour resection was performed under general anesthesia, by doing a modified lateral orbitotomy. The tumour was removed a blunt dissection with the intact capsule.

EP-046[Neurooncologic Surgery]

PRIMARY MELANOCYTIC MENINGIOMA IN THE LEFT TEMPORAL LOBE: A CASE REPORT

Seyed Ali Mousavinejad, Mohammad Samadian, Guive Sharifi, R za Jabbari, Omidvar Rezaie
department of neurosurgery of loghman hospital, shahid beheshti university, tehran, iran

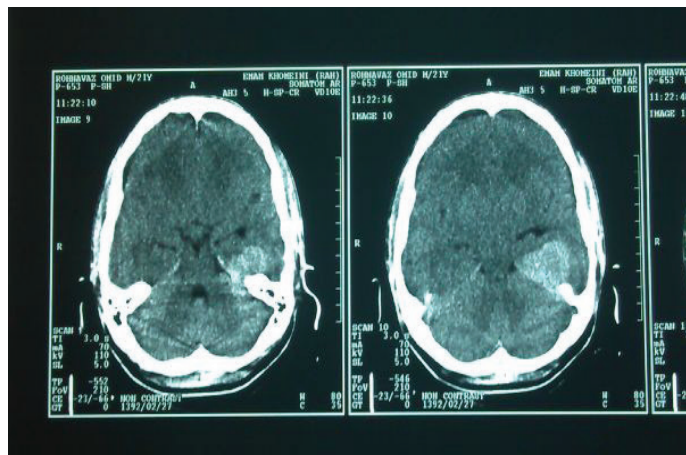
INTRODUCTION - OBJECTIVE: Primary melanocytic neoplasms of the central nervous system (CNS) are rare lesions arising from melanocytes of the leptomeninges. These leptomeningeal melanocytes are found at highest density underneath the brain stem and along the upper cervical spinal cord. Thus, most reported cases of meningeal melanocytomas are located in the posterior fossa and the spinal cord, and presentation of the tumor in supratentorial is very rare..

METHOD: : A 19-year-old man presented with headache and seizure at our department. Neurological exams were otherwise normal. A left temporal space-occupying lesion was seen on magnetic resonance imaging. The mass was hyperintense on T1-weighted images and hypointense on T2-weighted images. on contrast-enhanced MR enhancement was shown. Prior to surgery, meningioma was diagnosed and gross tumor removal was performed. After surgery pathological diagnosis was made as meningeal melanocytoma WHO grade 1, the patient received radiation therapy

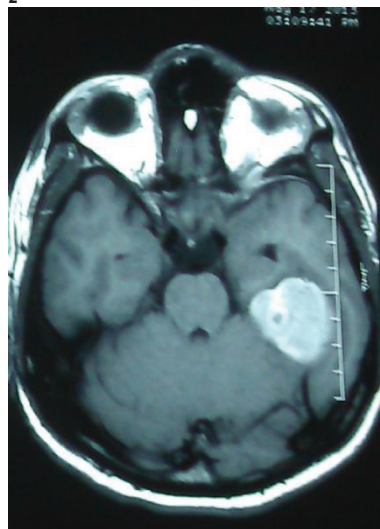
RESULTS: No tumor was seen on follow-up MR images one year after surgery.

CONCLUSIONS: : presentation of melanocytic meningioma in supratentorial is very rare.. Although this lesion is benign, but may behave aggressively. for most cases Complete surgical resection of the lesion is curative. to prevent relapse of the tumothe. Radiation therapy is important, especially in cases of incomplete surgical resection

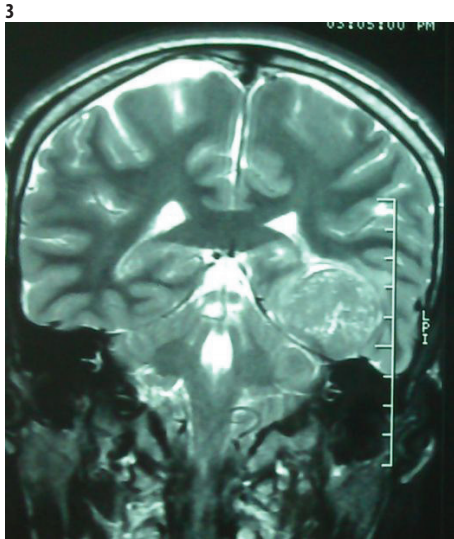
1



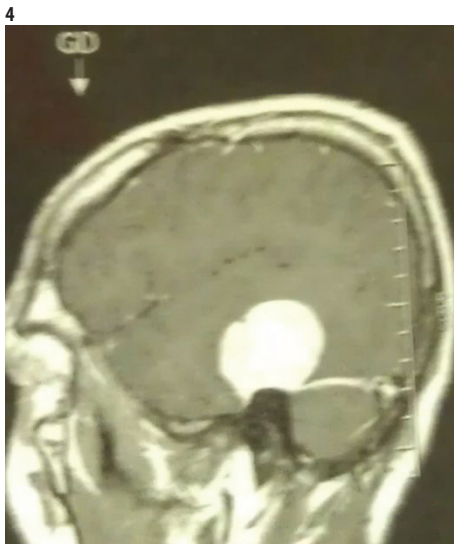2



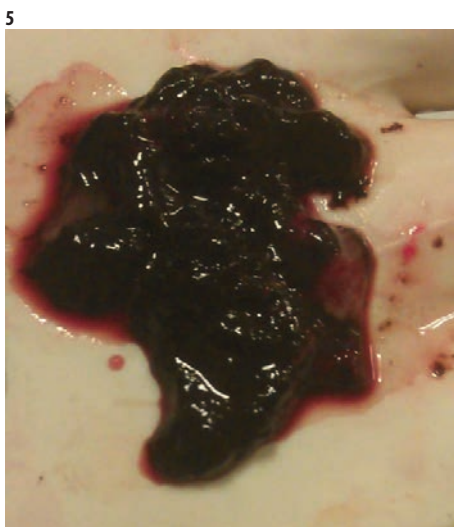brain mri show a hyperintense lesion in T1 MRI



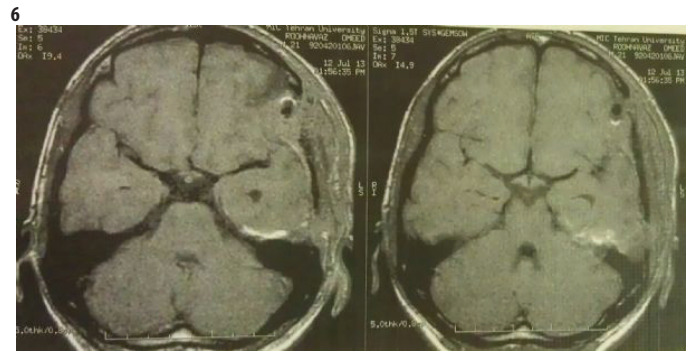
brain mri show a isointense lesion in T1 MRI



brain sagital mri with contrast show a a lesion in left temporal lobe that enhanced homogenous



macroscopic view of lesion



post op AXIAL MRI

EP-047[Neurooncologic Surgery]

BRAIN TUMORS AND RESULTS OF SURGICAL TREATMENT DURING PREGNANCY

Gabit Olenbay, Serik Akshulakov, Nurzhan Ryskeldiev, Aidos Doskaliev, Dmitry Surdin
National Centre for Neurosurgery

INTRODUCTION - OBJECTIVE: In 75% cases tumors are progressing in reproductive age. Placenta is a powerful hormonal body stimulating the tumors growth. Maternal fatality is 24.3%. Objectivity is to formulate treatment tactics.

METHOD: 22 women (2009-2014) were surgically treated with clinical symptoms mistakenly interpreted as an early preeclampsia - headache 100% and vomiting 42%. The treatment choice agreed with neurosurgeons, anesthesiologists and Obstetricians. 14 of 22 patients surgically treated in postnatal period. Delivery performed by cesarean section, 6 patients produced fetus wastage, 2 (19-20 and 25-26 weeks) with surgical treatment under fetal ultrasound and Obstetricians monitoring, performed with StealthStation and Medtronic navigation systems providing us with optimal access and visualization of low-grade gliomas with no clear boundaries and difficult location.

RESULTS: Glial tumors are prevail 9 of 22 (40.9%), 4 (44.4%) have fibrillar protoplasmic astrocytoma, 3 (33.3%) anaplastic astrocytoma, 2 (22.2%) glioblastoma multiforme, 4 (18.1%) meningiomas, 1 (25%) atypical meningioma, 2 (9.0%) hemangioblastoma anaplastic, 2 (9.0%) ependymoma. After 3 months CT and MRI showed total removal 12 (54.5%) and 9 (40.9%) subtotal removal. 1 (4.54%) - verifies the histological autopsy. One fatality case among 22, rated as (4.54%).

CONCLUSIONS: Surgical treatment depends on neurological condition, location of tumor and gestation and is not an absolute indication for fetus wastage.

EP-048[Neurooncologic Surgery]

RESULTS OF BRAIN TUMOUR SURGERY IN KYRGYZSTAN

Keneshbek Yrysov, Mitalip Mamytov
Kyrgyz State Medical Academy, Dpt. Neurosurgery

INTRODUCTION - OBJECTIVE: Authors present a series of brain tumour cases who we had operated and analysed retrospectively with respect to survival and surgical complications.

METHOD: Between September, 2003 to February, 2009 two hundred sixty craniotomies for intracranial tumours have been performed. Main management principles included surgery for progressive or symptomatic tumours, unless surgery was contraindicated or refused by the patient; to make surgery as aggressive as possible but with the aim of preserving of brain function; Observation for asymptomatic tumours.

RESULTS: The neurological status and the quality of life were analysed preoperatively and during the follow-up examinations. Median follow-up was 4 years. There was no operative mortality. The transient morbidity was 11%. The operative intervention significantly improved the quality of the life in all patients during the follow-up period. The average survival time of all patients was 24 months. Twenty patients died following the operation after a mean time of 28 months. There were seventeen surgical complications for a rate of 7%. Complications included hemiparesis (2.9%), new cranial nerve palsy (1.9%) and indolent osteomyelitis (1.9%). Thirty five patients had Observation only; none of which progressed.

CONCLUSIONS: Tumour removal in the brain using individually modified surgical strategies based on an approach recognizing tumour location and size of tumour significantly increases the time of survival and quality of life..

EP-049[Neurooncologic Surgery] RETROSGMOID APPROACH IN ACOUSTIC NEUROMA SURGERY

Mitalip Mamytov, Keneshbek Yrysov
Kyrgyz State Medical Academy, Dpt. Neurosurgery

INTRODUCTION - OBJECTIVE: Acoustic Neuromas (AN) are benign tumours arising from the vestibular nerves, usually within the internal auditory canal, where hearing loss is the most common symptom. The goal of our study was to identify the actual benefits and persisting problems in surgical treatment of AN using lateral suboccipital retrosigmoid approach.

METHOD: Since 2010, 85 ANs have been surgically removed in the neurosurgical clinic of Kyrgyz State Medical Academy, Bishkek, Kyrgyz Republic. Age ranging between 21 and 74 years; all patients underwent lateral suboccipital retrosigmoid approach for ANs.

RESULTS: Complete tumour removal was performed in 54 patients. In other 31 deliberate subtotal tumour removal was performed, with the aim of life-saving surgery in 18 cases and of hearing-saving surgery in 13. To achieve hearing preservation, brain stem auditory evoked potentials were controlled during the whole operative procedure. Preservation of hearing was achieved in 58% of attempts. Anatomic preservation of the facial nerve was achieved in 81%. Surgical complications included CSF fistulas in 10.3%; caudal cranial nerve palsies in 7.4%; postoperative hematomas in 4.6%; bacterial meningitis in 2.2%, and wound revisions in 1.7%. There were 2 deaths occurring at 3 to 11 days after surgery (2.4%).

CONCLUSIONS: The lateral suboccipital retrosigmoid approach is the only one that enables hearing preservation regardless of tumour size. By careful patient selection, the complications and mortality rates should be further reduced.

EP-050[Neurooncologic Surgery] BRAIN TUMOUR INCIDENCE IN KYRGYZSTAN

Keneshbek Yrysov, Mirgul Yrysova
Kyrgyz State Medical Academy, Dpt. Neurosurgery, Dpt. Epidemiology

INTRODUCTION - OBJECTIVE: Brain tumours cause considerable concern due to a high mortality and there are increasing efforts to provide adequate care. The goal of this study was to determine the incidence of brain tumours in Kyrgyz Republic.

METHOD: A population based study was performed. Patients from Kyrgyz Republic with incident intracranial tumours diagnosed in 2010 and 2013 (by CT, MRI or histology) were identified retrospectively using multiple sources. Differences in incidence by tumour type, age and sex were examined.

RESULTS: Eight hundred and eighty four patients with incident brain tumours were identified (456 primary tumours and 428 secondary tumours). The commonest primary tumours were neuroepithelial tumours (53.5%), meningeal tumours (19.5%), and sellar tumours (16.5%). The crude yearly incidences of primary and secondary tumours were 30.3 and 28.3 per 100 000 respectively. About 50% of patients with secondary tumours had an underlying lung cancer. The incidence of primary and secondary tumours increased markedly with age. Meningeal tumours were more common in women.

CONCLUSIONS: This study shows that the incidence of intracranial tumours in Kyrgyz Republic is considerably higher than previously thought. Brain tumours are a significant cause of morbidity and mortality in Kyrgyz Republic, and further research into their aetiology and treatment is urgently required.

EP-051[Neurooncologic Surgery] SUPRATENTORIAL PRIMARY MALIGNANT MELANOMA: A CASE REPORT

Emre Hasan Aydin¹, Zuhtu Ozbek², Deniz Arık³, Arslantas Ali²

¹Department of Neurosurgery, Eskisehir State Hospital, Eskisehir, Turkey

²Department of Neurosurgery, Osmangazi University, Eskisehir, Turkey

³Department of Pathology, Osmangazi University, Eskisehir, Turkey

INTRODUCTION - OBJECTIVE: Primary malignant melanomas can be seen rarely in central nervous system. Primer melanocytic tumors originating from melanocytes localized in central nervous system. Melanomas classified three pathological processes; leptomeningeal melanosis, neurocutaneous melanosis and localized pigmented tumors (melanocytoma and primer malignant melanoma).

METHOD: Localized pigmented tumors and primer malignant melanomas are most aggressive tumors which showed intense immunoreactivity for S100 and HMB45.

RESULTS: Primary malignant melanomas are usually found in regions filled with melanocytes anterior and posterior side of spinal cord and skull base.

CONCLUSIONS: Supratentorial localization of this tumors are uncommon. We present a case of primary malignant melanoma which localized supratentorial on the basis of the literature.

EP-052[Neurooncologic Surgery] ELEVATED PREOPERATIVE RED CELL DISTRIBUTION WIDTH AS A BIOMARKER OF HIGHER MALIGNANCY RISK IN PATIENTS WITH CEREBRAL GLIOMAS

Raushan Auezova¹, Nurzhan Riskeldiev¹, Daniyar Teltaev¹, Aidos Doskaliev¹, Erbol Kuanishev¹, Nurgul Aldiyarova¹, Natalia Ivanova², Serik Akshulakov¹

¹Department of pat. CNS., National Centre for Neurosurgery, Astana, Kazakhstan

²AL Polenov Russian Scientific Research Institute of Neurosurgery

INTRODUCTION - OBJECTIVE: Red cell distribution width (RDW) is routinely performed as part of a full blood count. RDW elevation has been proven to be firmly associated with many chronic inflammation-associated diseases. Despite the findings that chronic inflammation is one of the underlying mechanisms of oncogenesis, very few studies investigated RDW as a potential biomarker of tumor malignancy and survival. The present study aimed to evaluate the association of RDW with malignancy grade and survival in patients with cerebral gliomas.

METHOD: We performed a retrospective study, where we included of 104 patients with primary gliomas (WHO grade I-IV). Blood samples were obtained for full blood cell count including RDW (Hematology Analyzer CD-1800). Statistical analysis was performed using SPSS software (version 17.0); chi-square and t-tests were used at p < 0.05 level of significance.

RESULTS: Patients were divided into two groups: A (RDW $\geq 14.5\%$) and B (RDW < 14.5%). In group A, 36% patients had low-grade gliomas (LGG) versus 64% patients who had high-grade gliomas (HGG). While group B consisted of 60% patients with LGG versus 40% patients with HGG. In group A 33% patients were alive and 67% died at the moment of the study. In group B 47% patients were alive and 53% died. Univariate analysis revealed a significant association between elevated RDW ($\geq 14.5\%$) and higher-grade tumor histology (HGG) (p < 0.019). No association was found between RDW and survival.

CONCLUSIONS: Our study demonstrated for the first time the association of RDW with higher malignancy risk in glioma patients, providing a simple and cost-effective biomarker of cancer surveillance.

Table 1. Distribution of the patients according to histological type of neuroepithelial tumour

Histology	Malignancy grade	N
Pilocytic astrocytoma	I	3
Dysembryoplastic neuroepithelial tumour	I	2
Gangliocytoma	I	2
Ganglioglioma	I	1
Subependymal giant cell astrocytoma	I	1
Diffuse astrocytoma	II	35
Oligodendroglioma	II	6
Pleomorphic xanthoastrocytoma	II	2
Ependymoma	II	2
Anaplastic astrocytoma	III	17
Anaplastic oligodendroglioma	III	8
Anaplastic ependymoma	III	5
Anaplastic ganglioglioma	III	4
Choroid plexus carcinoma	III	1
Glioblastoma	IV	9
Medulloblastoma	IV	6
Total		104

aLGG: I&II HGG: III&IV

Table 2. Association of RDW with malignancy grade and survival in patients with gliomas

Grade	RDW ≥ 14.5	RDW < 14.5	P value
LGG	13 (36%)	41 (60%)	<0.019
HGG	23 (64%)	27 (40%)	<0.019
Alive	12 (33%)	32 (47%)	>0.05
Died	24 (67%)	36 (53%)	>0.05

aThe RDW values of the patients at admission ranged from 12.0% to 40.2%.

EP-053[Neurooncologic Surgery]

THE PREOPERATIVE PLANNING FOR SELLAR & PARASELLAR LESIONS, PART (A); A NEW STRATEGIC MULTIPLANNER CLASSIFICATION

Mohamed Ahmed Fahmy Mohamed Mostafa Zeid,¹ Ahmed Mostafa Yehya², Abd Al Aziz A. El Nekady.³

¹Department of Neurosurgery, Faculty of Medicine, Alexandria University, Alexandria, EGYPT.

²Same As above.

³Department of Diagnostic Radiology, Faculty of Medicine, Alexandria University, Alexandria, EGYPT.

INTRODUCTION - OBJECTIVE: Surgical indication, More-over approaches and specific strategic planning to that pre-plexing anatomical as well as pathological origin of the sellar and jaxta-sellar lesions cause a changeable task for even an experienced neuro-surgeons.

METHOD: We used a classification system which include the pre-operative detailed Imaging "three dimensional studies by CT, MRI" and dynamic contrast scanning. The combination of tumor invasion (grading) with anatomical tumor extension "staging" that delineated precisely the anatomical spread and the possible pathology.

RESULTS: Seven different grades of spread in the coronal imaging studies with five different types of midline lesion expansion in addition to three different sub-types on the same imaging studies which could correlate with anatomical-operative finding. In these classification we have eight alphabetical grades from (A) up to (H). a) Entirely the lesions in the intrasellar, b) Invade the sphenoid sinus. c) Invade the cavernous sinus. f) Invade the roof of the sphenoid sinus., g) Invade the floor of the sphenoid sinus. Then, we used the Roman numerals to describe the anatomical spread to the different jaxta-sellar area; from I. Inside the sellar cavity "micro-adenoma" up to VII. reach above the third ventricle

CONCLUSIONS: The use of bony anatomical landmarks of the skull base in addition to the configuration of the third ventricle with cavernous sinus shapes & Also, The sizes and morphology of the carotid arteries could help us for pre-operative planning. Also, to compare the operative results between different approaches, techniques and tumors sizes with different Neuro-surgical centers having different post-operative outcome including varies follow up duration in different protocols of management.

EP-054[Neurooncologic Surgery]

RELEVANCE OF INTRAOPERATIVE NEUROPHYSIOLOGICAL MONITORING IN SPINAL TUMOURS

Corrado Iaccarino¹, Reza Ghadirpour², Davide Nasi², Rossella Sabadini³, Luisa Motti³, Gabriella Torre³, Elisa Mazzini⁴, Giorgio Mazzi⁵, Franco Servadei¹

¹Neurosurgery Unit, Emergency Department, University Hospital of Parma, Parma, Italy

²Emergency Neurosurgery, Neuromotor Department, IRCCS "ASMN" of Reggio Emilia, Reggio Emilia, Italy

³Neurophysiology Unit, Neuromotor Department, IRCCS "ASMN" of Reggio Emilia, Reggio Emilia, Italy

⁴Medical Direction, IRCCS "ASMN" of Reggio Emilia, Reggio Emilia, Italy

⁵General Health Direction, IRCCS "ASMN" of Reggio Emilia, Reggio Emilia, Italy

INTRODUCTION - OBJECTIVE: Intraoperative neurophysiological monitoring (IOM) for intramedullary tumors has become standard in neurosurgical practice. The same monitoring for intradural extramedullary lesions is still under debate. We report our experience on the utility of IOM both for intramedullary that intradural extramedullary lesions.

METHOD: From March 2008 to September 2013 we have operated with complete IOM 110 cases. 35 patients harboured intradural extramedullary lesions (12 ependymomas, 5 astrocytomas, 7 syringomyelia, 6 tethered cord and 5 other lesions). Others 62 patients had intradural extramedullary lesions (25 schwannomas, 20 meningiomas, 6 arachnoid cysts and 11 other lesions). The IOM included MEP, SEP and D-waves. All patients were evaluated pre and post-operatively (minimum 6 months) with the Modified McCormick Scale (mMCS).

RESULTS: In patients with intramedullary tumors we have 3 cases (8,57 %) of transitory alterations of IOM with complete tumor removal (STOP & GO SURGERY) and 4 cases of stable alterations of IOM (11,42 %) with abandon of surgery (STOP SURGERY). In 2 cases of intradural extramedullary tumors we have STOP & GO SURGERY. In others 2 patients (3,22 %) we abandon surgery for stable IOM alterations. At follow up no patients presented a worsening of the pre-operative clinical conditions

CONCLUSIONS: The use of the IOM during surgery was useful in respectively in 20 % and 6,45 % of patients. On the basis of our results, we believe that the IOM should be considered mandatory during surgery for intramedullary tumors and should also be recommended during intradural extramedullary lesions microsurgery.

EP-055[Neurooncologic Surgery]

PROGNOSTIC VALUE OF MGMT PROMOTER STATUS IN NON-RESECTABLE GLIOBLASTOMA AFTER ADJUVANT THERAPY

Reza Ghadirpour¹, Corrado Iaccarino², Vania Ramponi², Anna Pisanello³, Rosario Pascarella⁴, Massimo Maggi⁴, Elisabetta Froio⁵, Silvia Serra⁵, Davide Nicolini⁶, Edoardo Vioroli², Franco Servadei²

¹Emergency Neurosurgery, Neuromotor Department, IRCCS "ASMN" of Reggio Emilia, Reggio Emilia, Italy

²Neurosurgery Unit, Emergency Department, University Hospital of Parma, Parma, Italy

³Neurology Unit, Neuromotor Department, IRCCS "ASMN" of Reggio Emilia, Reggio Emilia, Italy

⁴Neuroradiology Unit, IRCCS "ASMN" of Reggio Emilia, Reggio Emilia, Italy

⁵Histopathologic Unit, IRCCS "ASMN" of Reggio Emilia, Reggio Emilia, Italy

⁶Laboratory of Molecular Biology, IRCCS "ASMN" of Reggio Emilia, Reggio Emilia, Italy

INTRODUCTION - OBJECTIVE: Few data in literature about prognostic factor for not-resectable GBL are available.

METHOD: This is an Observational retrospective study on 174 GBL cases. After biopsy or surgery patients were assigned for Radiotherapy (XRT) and/or Temozolomide (TMZ) treatment.

RESULTS: 55 patients fulfilled inclusion criteria: age >18 years, supratentorial GBL, determined MGMT status, first surgery, XRT and/or TMZ, follow-up above 6 months. 23 patients underwent neuronavigated biopsy (B Group) and 32 patients underwent craniotomy (R Group). The preoperative mean tumor volume and age were similar in both groups (46.2 cm³ vs 44.1 cm³) (61.7y vs 60.3y). The B groups showed lower KPS (82.1 vs 90.3). The MGMT promoter was methylated 51.2% of B Group and in 53.1% of R Group. XRT/TMZ/TMZ was accomplished 47.8% of B Group and in 75% of R Group; in 82.8% methylated and in 42.3% unmethylated patients. In B Group the mean overall survival (OS) of methylated patients was 11.4 months vs 4.8 months of unmethylated patients. In R Group the mean OS was 21.7 months for methylated patients and 14.0 months for unmethylated patients. At the multivariate Cox regression XRT and TMZ resulted statistically significant in OS for all 55 patients, while only for the R Group KPS, XRT and TMZ were statistically significant and just for the B Group XRT and MGMT promoter methylation were statistically significant in OS.

CONCLUSIONS: MGMT promoter unmethylation has a predominant unfavourable influence for the subpopulation with non-resectable GBL. The biopsy could help in a future to modify the treatment relating prognostic factors

EP-056[Neurooncologic Surgery]

SURGICAL NUANCES IN TENTORIAL MENINGIOMAS: A NEW CLASSIFICATION BASED ON THE SIMPLE AND COMPLEX VARIETIES

Sanjay Behari, Dinesh K Shukla, Awadhesh K Jaiswal, Rabi N Sahu, Anant Mehrotra, Arun K Srivastava, Isha Tyagi

Department of Neurosurgery, Sanjay Gandhi Postgraduate Institute of Medical Sciences, Lucknow, India

INTRODUCTION - OBJECTIVE: Tentorial meningiomas (TM): comprising 3% - 6% of all intracranial meningiomas, are complex entities with intricate relationship to surrounding neurovascular structures and require multiple surgical approaches.

METHOD: 40 patients with TM were evaluated for their clinical presentation, radiology, surgical management and outcome. The extent of excision was categorized according to Simpson's grade. 30 primary (supratentorial[2], infratentorial[22], both[6]); and, 10 complex (CP angle[6] and petroclivotal[4]) TM were included. Excision was done using the occipital transtentorial, supracerebellar infratentorial, subtemporal, midline suboccipital, retrosigmoid, extradural transpetrous, translabrynthine and presigmoid approaches.

RESULTS: Simpson's excision grade was: I:12; II:8; III:7; IV:13. At follow up (3 mths-9 yrs) in 31 patients (81.57%): 26: resumed normal life with no or minimal symptoms; 4: returned to previous activity with major cranial nerve palsy; and, 1: required permanent assistance. 2 patients had recurrence; 4 others underwent re-surgery for residual tumor; 2 with petroclival lesions died due to aspiration pneumonia and meningitis, respectively. Morbidity was due to pseudomeningocele, CSF leak and cranial nerve palsy.

CONCLUSIONS: Classifying tentorial meningiomas into medial and lateral, supra and infratentorial groups helps in deciding appropriate and safe approach. Meticulously preserving venous sinuses is important since risk of venous infarction cannot be predicted even with radiological good venous collateralization and apparent venous sinus blockade by tumour. Laterally situated tumors carry a better prognosis as compared to medially located ones. Leaving small residual tumor in an effort to preserve important neurovascular structures is associated with a good long-term prognosis, minimal morbidity and low recurrence rates.

EP-057[Neurooncologic Surgery]

BRAINSTEM CAVERNOUS MALFORMATIONS PRESENTATION OF 20 CASES AND REVIEW OF LITERATURE RECOMMENDATIONS

Lorenza Pereira, Daniel Carvalho Kirchhoff, Luiz Paulo Alves, Fabio Furukawa Okuda, Abel Mitsuo Takey, Rodrigo Gusmao Coimbra, Dierk Fritz Bodo Kirchhoff

Assistencia Neurologica São Bernardo

INTRODUCTION - OBJECTIVE: Bleeding from brainstem cavernomas may cause severe deficits due to the absence of non-eloquent nervous tissue and the presence of several ascending and descending white matter tracts and nerve nuclei. Surgical removal of these lesions presents a challenge to the most surgeons. We present our experience with the surgical and clinical treatment of 20 patients with brainstem cavernomas. Important aspects of microsurgical anatomy are reviewed. The surgical management, with special focus on new intraoperative technologies as well as controversies on indications and timing of surgery are presented

METHOD: Were retrospectively reviewed to evaluate the outcome of 43 patients harboring brainstem cavernous malformations treated surgically between 1999 and 2009. It was observed if they have previous hemorrhages (one, two or more episodes), the possibility of the total surgical removal at the first operation, the presence of previous or new transient postoperative deficits and the patient's choice of clinical support as unique threatment and it was considered the surgical techniques used and recommended at literature

RESULTS: The patients have at middle 54 years, have cavernomas most at pons our at midbrain-pons our pons-medullary transition. The most part have partial clinical improvement and cranial nerves function recovery

CONCLUSIONS: According to our experience, surgical resection remains the treatment of choice of brainstem cavernomas if there was previous hemorrhage and the lesion reaches the pial surface of brainstem. An excellent outcome with very low morbidity and no mortality may be achieved if the surgery is performed by experienced neurosurgeons in selected referral centers employing all the currently available technology.

EP-058[Neurooncologic Surgery]

GLIOMA STEM CELLS PROMOTE MALIGNANT TRANSFORMATION OF GLIAL CELLS DURING TUMOR TISSUE REMODELING VIA PDGF SIGNALING

Jun Dong

Department of Neurosurgery, 2nd Affiliated Hospital of Suzhou University, Suzhou, China

INTRODUCTION - OBJECTIVE: Glioma stem cells (GSCs) play important roles in tumor initiation and progression. However, interactions between GSCs and other local tumor microenvironmental cells kept unknown. Besides GSCs and their progeny cells, whether adjacent normal glial cells contribute to tumorigenesis during glioma tissue remodeling deserves further investigation.

METHOD: Red fluorescent protein (RFP) gene was transfected into human primary GSCs cell lines, then SU3-RFP cells were transplanted intracerebrally into Balb/c nude mice with whole-body green fluorescent protein (GFP) expression. The interactions between GSCs and host cells were observed during tissue remodeling processes initiated by hGSCs. The biological characteristics of host glial cells with high proliferation capability cloned from the xenograft were further assayed.

RESULTS: In the hGSCs initiated dual-fluorescence xenograft glioma model, some host glial cells cloned from the intracerebral tumors were found acquiring the capability of unlimited proliferation. PCR and FISH results indicated that malignant transformed glial cells were derived from host cells, further research found that these host malignant transformed cells expressed oligodendrocyte specific marker CNP, and parts of these cells expressed oligodendrocyte progenitor cells (OPCs) specific markers PDGFR- α and NG2. Chromosomal analysis showed that most of these cells were super tetraploid. In vivo studies showed they behaved high invasiveness activity and nearly 100% tumorigenic ratio. These malignant transformed host glial cells highly expressed PDGFR- α , and hGSCs expressed higher PDGF-B level than that of low invasive U87 derived GSCs.

CONCLUSIONS: Primary hGSCs could promote of adjacent normal host glial cells in local tumor microenvironment possibly via PDGF/PDGFR signaling activation, which deserved further investigation.

EP-060[Neurooncologic Surgery]

EFFECT OF TRANSFERRIN MODIFIED NANOSCALED GRAPHENE OXIDE LOADING DOXORUBICIN FOR TREATING GLIOMA: IN VITRO AND IN VIVO EVALUATIONS

Liu Guo Dong¹, Lan Qing¹, Shen He², Zhang Zhijun², Sun Tao³, Dong Xiaofeng³

¹Neurosurgery Department, The Second Affiliated Hospital of Soochow University

²Suzhou Key Laboratory of Nanobiomedicine, Division of Nanobiomedicine, Suzhou Institute of Nanotech and Nano-bionics, Chinese Academy of Sciences

³Department of Biological Sciences, Xi'an Jiaotong-Liverpool University

INTRODUCTION - OBJECTIVE: Transferrin (Tf), an iron-transporting serum glycoprotein that binds to receptors overexpressed at the surface of glioma cells, was chosen as the ligand to develop Tf-conjugated PEGylated nanoscaled graphene oxide (GO) for glioma targeting delivery of anticancer drug doxorubicin (Dox) (Tf-GO-Dox).

METHOD: GO was prepared by modified Hummers method and converted to carboxylated GO, followed by PEGylation. Tf-PEG-nGO was developed via a two-step coupling of Tf to PEG-GO by EDC chemistry. Loading of Dox onto the GO sheets was carried out by adding Dox (dissolved in DMSO) to the Tf-PEG-GO or PEG-GO. The antitumor efficiency was evaluated both in vivo and in vitro.

RESULTS: Tf-GO with lateral dimensions of 100–400 nm exhibited Dox loading ratio up to 115.4%. Compared with Dox-loaded PEGylated GO (GO-Dox) and free Dox, Tf-GO-Dox displayed the greater intracellular delivery efficiency evaluated by HPLC assay, and the stronger cytotoxicity against C6 glioma cells via MTT assay. Competition test showed Tf played a key role in the glioma targeting in vitro. HPLC assay for Dox of tumour tissue and contrapart tissue of the brain gave the intuitive proof that Tf-GO-Dox could deliver more Dox into tumour in vivo. The life span of tumour bearing rats after administering Tf-GO-Dox was significantly longer than that after giving saline, free Dox or GO-Dox.

CONCLUSIONS: In conclusion, the glioma targeting Tf-GO-Dox is able to improve the therapeutic efficacy of brain glioma in vitro and in vivo.

EP-061[Neurooncologic Surgery]

CYSTIC MENINGIOMAS: REPORT OF THREE CASES

Selçuk Göçmen¹, Ali Kıvanç Topuz¹, Cem Atabey¹, Göksel Güven¹, Mehmet Nusret Demircan¹, Ufuk Berber²

¹Department of Neurosurgery, GATA Haydarpasa Training Hospital, Istanbul, Turkey

²Department of Pathology, GATA Haydarpasa Training Hospital, Istanbul, Turkey

INTRODUCTION - OBJECTIVE: Cystic meningioma is rare and said to account for 1.6 to 10% of all types of meningioma. Recognition of the diagnostic features of cystic meningiomas is important, because they may be difficult to differentiate from glial or metastatic tumors with cystic or necrotic changes, neurinoma, or hemangioblastoma. We now reported three cases of cystic meningiomas and

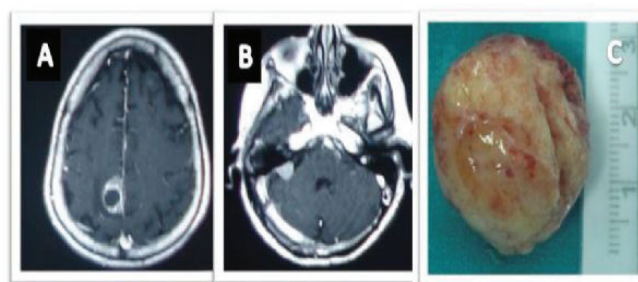
discussed the characteristics of these lesions.

METHOD: Various authors describe different types of cystic meningiomas. We detected type 1 cysts in our first and third cases and a type 2 cyst in the second case, according to Nauta classification. All the patients underwent surgery. The tumors were totally resected. In our cases, mean age was 62 years and all patients were female. Histopathologically, there were two meningothelial and one angiomatous. One case was in the posterior fossa, one was in the falx region and one was on parasagittal region in our series. The third case is very rare localization of cystic meningioma. Second lesions are an extremely rare condition with cystic meningiomas.

RESULTS: Meningiomas are generally solid tumors and the presence of such cystic areas is relatively rare.

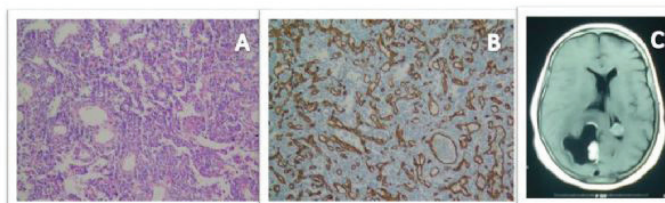
CONCLUSIONS: An unusual site may be also characteristic of cystic meningiomas, including lateral ventricle, intraparenchymal or in the posterior fossa. Careful analysis of the imaging studies, primarily MRI, frequently offers additional information, detecting the imaging findings that are suggestive of other disease processes. Cystic meningiomas have a very low incidence and the cyst wall should be completely removed to prevent tumor recurrences.

Case 1



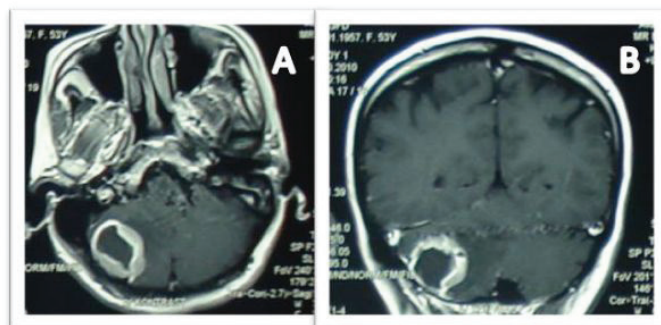
Gadolinium-enhanced T1-weighted magnetic resonance imaging (MRI) of the first case demonstrated a cystic tumor in the parasagittal area (A) and right pontocerebellar meningioma (B). The tumor was seen after completely removed (C).

Case 2



Angiomatous meningioma with abundant stromal hyalinized vessels, HE, x20. (B) CD34 immunoreactivity highlights vascular network in angiomatous meningioma, x20. (C) Gadolinium-enhanced T1-weighted MRI showed a cystic tumor in the right falx region and left lateral ventricular lesion in the second case

Case 3



Gadolinium-enhanced T1-weighted MRI showed a homogeneously enhancing solid mass attached to the undersurface of the tentorium with a large cyst

EP-062[Neurooncologic Surgery]

THE EXPERIMENTAL STUDY ON TEMOZOLOMIDE DERIVATIVES AGAINST HUMAN GLIOMA

Qiang Huang

2nd Affiliated Hospital of Suzhou University, Suzhou, 215004, China

INTRODUCTION - OBJECTIVE: To Observe the anti-tumor effect of temozolomide water-soluble derivatives (2T-P400, 2T-P600) against human glioma.

METHOD: Anti-tumor effect of temozolomide derivatives (2T-P400, 2T-P600) in vitro on human glioma cell line SHG44 was evaluated by MTT assay, then SHG44 glioma-bearing nude mouse model was prepared, tumor-bearing mice were divided randomly into TMZ group, 2T-P400 group, 2T-P600 group, PEG group and NS group. TMZ was administered orally, and the other drugs were administered via tail vein injection. Tumor volume of the mice was measured once every four days.

RESULTS: The anti-glioma effect of 2T-P400 and 2T-P600 in vitro has almost the same level with that of TMZ, all of them have much better effect than PEG and NS group ($P < 0.01$). Tumor inhibition ratios of TMZ, 2T-P400 and 2T-P600 in vivo were higher than PEG and NS ($P < 0.05$). No obvious adverse drug reactions was observed.

CONCLUSIONS: 2T-P400 and 2T-P600 retained anti-tumor activity of TMZ, and will provide a new treatment option for glioma patients.

EP-063[Neurooncologic Surgery]

SIMULTANEOUS USE OF AN INTRAOPERATIVE NEUROMONITORING AND ENDOSCOPIC-ASSISTANCE IN SURGERY OF VESTIBULAR SCHWANNOMAS

Serik Akshulakov, Khalit Mustafin, Nu zhan Ryskeldiyev, Daniyar Teltayev,

Aidos Doskaliyev, Aigerim Zhumadildina

Department of CNS pathology, National Centre for Neurosurgery, Astana, Kazakhstan

INTRODUCTION - OBJECTIVE: Vestibular schwannomas account for approximately one third of all tumors of the posterior cranial fossa and from 4.9% to 10% of all brain tumors. Due to the introduction to our clinic the intraoperative neuromonitoring and the endoscopic assistance improved operations quality of vestibular schwannomas remove.

METHOD: In The National Centre of Neurosurgery during 2013 were done surgery for 15 patients with vestibular schwannomas. Average age was from 30 to 60 years, 12 females (80%). Average tumor diameter was 3.7 cm (2.5-5.0 cm). 11 patients were operated by the standard method and in 4 cases we used intraoperative neuromonitoring «NIM Eclips» of «MEDTRONIC» and endoscopic-assistance with angles 0 and 30 degrees endoscope of the Karl-Storz.

RESULTS: In the first group 6 patients of 11 with initial hearing loss was recorded even greater hearing loss (54%) after surgery. 4 patients developed facial nerve paresis (36%), one case of bulbar syndrome (9%) that was regressed within 10 days. In the second group hearing impairment was observed in two patients (50%) and 1 patient had a facial nerve paresis (25%) after surgery.

CONCLUSIONS: The neuromonitoring allowed us to preserve the function of the cranial nerves, as well as prevent damage to the brain stem structures almost all patients, while the endoscope increased operative view and allowed radical removal of the tumor. Hence we came to the conclusion that the use of intraoperative neuromonitoring and endoscopic assistance is recommended in all operations of vestibular schwannomas remove.

EP-064[Neurooncologic Surgery]

APPLICATION OF ULTRASOUND NAVIGATION SONOWAND INVITE SURGERY INTRACEREBRAL BRAIN TUMORS

Kanat Akhmetov, Serik Karibay

Department of General Neurosurgery, National Centre for Neurosurgery, Astana, Kazakhstan

INTRODUCTION - OBJECTIVE: Analysis of neurosurgical intervention in removing intracerebral brain tumors using ultrasound navigation SonoWand Invite.

METHOD: The National Center of Neurosurgery Department of General Neurosurgery in 2013 introduced and actively used intraoperative ultrasonography during surgery of brain tumors. The experience of treatment in 10 patients aged 45-60 years with intracerebral tumor were treated for the 2013-2014 year in the department of general neurosurgery. In all cases we used SonoWand - 3D ultrasound intraoperative neuronavigation.

RESULTS: The study was conducted before incision of the dura mater. Radical surgical interventions were: total removal - 6 patients (60%), subtotal removal - in 3 patients (30%), partial - 1 patient (10%). Thus, intraoperative ultrasound can quickly and reliably localize volume formation and conduct its navigation: specify anatomically important structures adjacent to the tumor and to determine the optimal access path and radical surgery, and also allows to describe in detail the internal structure of space-occupying lesions of the central nervous system. Ultrasound navigation can greatly facilitate the access path planning at the beginning of the operation, as well as the orientation within the operative field and the surrounding areas during the operation itself.

CONCLUSIONS: Installing ultrasonic navigation is convenient, reliable, fast and compact system neuroimaging mass lesions of the brain, capable of also conduct a full investigation of intraoperative ultrasound. Using SonoWand Invite significantly improves the quality of neurosurgical operations.

EP-065[Neurooncologic Surgery]

FAHR'S DISEASE AND ACCOMPANYING CYST OF THE CEREBELLUM: REVIEW OF THE LITERATURE

Mustafa Korucu¹, Mecvi Ozdemir¹, Feridun Acar¹, Bayram Cirak¹, Cihan Kaya², Murat Kocaoglu¹¹Pamukkale University Faculty of Medicine, Department of Neurosurgery, Denizli, Turkey²Pamukkale University Faculty of Medicine, Department of Radiology, Denizli, Turkey

INTRODUCTION - OBJECTIVE: Fahr disease, also named symmetric striopallidodentate calcinosis; is a disease that goes with very disseminated calcifications in the brain parenchyma without any abnormalities in the serum Ca and PTH levels. This disease was described in 1930 by Fahr. Although sporadic and autosomal recessive forms are reported, it usually shows autosomal dominant inheritance. Intracranial calcifications are bilaterally located and they are usually symmetrical. CT is the best diagnostic tool for showing calcifications. In this report, we aimed to discuss Fahr disease that rarely seen as the cause of intracranial calcifications and our case which have cerebellar cyst in the radiologic imaging in the light of literature.

METHOD: 24 years old, male patient applied to our neurosurgery clinic with complaints of headache, intermittent vertigo, nausea and vomiting. In the axial series of cranial CT, amorphous calcifications are seen in the bilateral corpus striatum, thalamus and pons (Image 1a-1b).

RESULTS: Bilateral cortical linear dystrophic calcifications are seen at centrum semiovale level. Also, a 43*41 mm lobulated, contoured cyst on the left side and a 10 mm cyst are seen on the right side of cerebellum.

CONCLUSIONS: As a result, when we find bilateral symmetric calcifications on the cranial CT and can not find any other etiological factor, we have to remember Fahr disease for differential diagnosis and its clinical appearance with very different neurological symptoms. We need MRI together with CT for diagnosis of cerebellar cysts.

Figure 1a

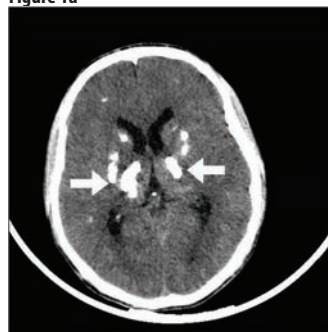
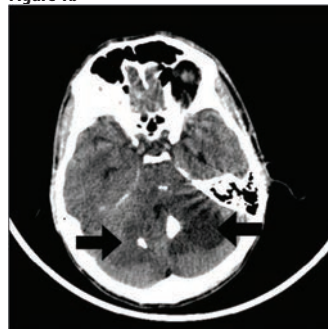

Figure 1b



EP-066[Neurooncologic Surgery]

THIRD VENTRICLE HERNIATION INTO THE SPHENOID SINUS FOLLOWING ENDOSCOPIC TRANSNASAL TRANSPHENOIDAL FENESTRATION OF RATHKE'S CLEFT CYST

Guive Sharifi¹, Seyed Ali Mousavinejad¹, Maryam Jalesi², Khosro Parsa³, Mohammad Samadian¹, Reza Jabbari¹, Mehrdad Hosein Zadeh¹, Omidvar Rezaie¹¹department of neurosurgery, loghman hospital, shaheed beheshti university, tehran, iran²department of ENT, RASOOL hospital, iran university, tehran, iran³department of neurosurgery, iranmehr hospital, tehran, iran

INTRODUCTION - OBJECTIVE: Rathke cleft cyst (RCC) is an uncommon albeit benign sellar lesion with an incidence rate of between 2 to 33%. RCCs are usually asymptomatic except in the large cases with suprasellar extension.

METHOD: We herein describe a unique case of RCC.

RESULTS: the patient presented with severe visual loss owing to massive herniation of the optic chiasm and third ventricle down into the sphenoid sinus just through a small 8x8 mm foramen after transnasal

endoscopic surgical fenestration and marsupialization of the cyst

CONCLUSIONS: We describe a reconstruction method via endonasal transsphenoidal approach in this case and suggest prophylactic reconstruction of the sellar floor in sellar lesions with equal or more voluminous suprasellar extensions which are susceptible to such massive herniation and secondary empty sella syndrome.

EP-067[Neurooncologic Surgery]

INCIDENTAL FINDING OF THROMBOSED ANEURYSM INSIDE HUGE PITUITARY MACROADENOMA CASE REPORT AND REVIEW OF LITERATURE

Guive Sharifi¹, Seyed Ali Mousavinejad¹, Maryam Jalesi², Mohammad Samadian¹, Reza Jabbari¹, Masod Asghari¹, Omidvar Rezaie¹

¹department of neurosurgery, loghman hospital, shaheed beheshti university, tehran, iran

²department of ENT, RASOOL hospital, iran university, tehran, iran

INTRODUCTION - OBJECTIVE: although apoplexy and cystic formation are common inside the pituitary adenoma and hemorrhage with different times as revealed by MRI sequences can be seen inside a pituitary macroadenoma aneurysm with classical wall and its association with carotid artery hasn't been yet reported

METHOD: 52 years old woman referred for visual loss and headache with a pituitary adenoma. she has no specific past medical history. we plan to resect her huge pituitary macroadenoma by endoscopic endonasal transsphenoid surgery.

RESULTS: During surgery we encountered a tough saccular mass and checking imaging brought the conjecture of a thrombosed aneurysm. By careful dissection and use of intranasal Doppler sonography its association with left internal carotid was revealed. After coagulation of its main branch that was probably a tumor feeder aneurysm resected totally and we proceed for further tumor removal

CONCLUSIONS: Up to our knowledge and review of literature it is the first time that intra adenoma thrombosed aneurysms reported.

EP-068[Neurooncologic Surgery]

FIRST CALCIFIED INTRASellar SHOWANOMA

Guive Sharifi¹, Seyed Ali Mousavinejad¹, Nader Akbari¹, Reza Jabbari¹, Mohammad Samadian¹, Armin Jahangiri¹, Armin Jafari¹

department of neurosurgery, loghman hospital, shaheed beheshti university, tehran, iran

INTRODUCTION - OBJECTIVE: Intracranial schwannomas usually arise from the eighth cranial nerve in the cerebellopontine angle. Its arising in the sella and extending into the suprasellar region is very rare and is easily mistaken for pituitary adenoma. We present a 46 woman with primary intrasellar schwannoma that radiologically resembled a pituitary adenoma.

METHOD: The patient is a 46 years old woman that presented with history of acute visual disturbance. Neurological examination showed poor visual acuity of both eyes with bitemporal hemianopsia. other neurological exam was normal. Investigations revealed a well demarcated sellar mass with supra sellar extension. ct scan show a calcified intrasellar mass. The lesion was isointense in both T1- and T2-weighted imaging. In T1 MRI there was a hypointense spot in the lesion. for more investigation brain ct-angiography was performed that didn't show aneurysm. Pituitary adenoma was considered as a preoperative diagnosis. The patient candidate for trans-sphenoidal resection

RESULTS: Intra operative the lesion was very firm and non suctionable and non curatable mass. Gross total excision of the lesion was done via a transsphenoidal approach. Microscopic examination of the tumor revealed schwannoma. Because the rarity of showanoma in this region IHC study was performed that showed showanoma.

CONCLUSIONS: atypically Schwannomas may occur in the sellar region, that demonstrate the typical light microscopic, immunohistochemical, and ultrastructural features of showanoma in the peripheral nervous system [Till date, 20 intrasellar showanoma have been documented in the literature that all of them were soft lesion. Our patient was the first calcified and firm schwannoma in the sellar region

EP-069[Neurooncologic Surgery]

INDICATIONS AND SURGICAL STRATEGY FOR RETROSIGMOID APPROACH FOR PETROCLIVAL MENINGIOMAS: REPORT OF AN EXPERIENCE WITH 76 CASES

Atul Goel

Seth G.S. Medical College And K.E.M Hospital

INTRODUCTION - OBJECTIVE: AIMS: The authors report the indications and surgical subtleties of retrosigmoid approach for petroclival meningiomas.

METHOD: MATERIAL- METHODS: Seventy-six patients of petroclival meningiomas treated during the period 1991 to 2011 by conventional posterior cranial fossa route are analyzed. All patients were operated in 'sitting' surgical position. The average length of follow-up is 55 months

RESULTS: RESULTS: The maximum diameter of the tumors ranged from 1.8 to 6.8 cm (mean of 4.2 cm). Thirteen tumors extended up to or beyond the contralateral petroclival junction. Basilar artery was at-least partially encased in 31 cases. Gross total resection of the tumor was achieved in 55 cases and a partial tumor resection was achieved in the remaining 21 cases. Re-exploration was done for tumor recurrence or re-growth in two cases. Five patients had major neurological deficits following surgery and died in the postoperative phase. There were no sitting position related complications.

CONCLUSIONS: CONCLUSIONS: Conventional posterior cranial fossa surgery can be suitable and ideal for a majority of petroclival meningioma. Tumors having a significant supratentorial or middle fossa extension may not be suitable for posterior cranial fossa approach. Apart from other advantages, a posterior cranial fossa approach provides easy and quick exposure of the tumor, without any petrous bone drilling. It also provides a direct and early exposure of the tumor-cranial nerve-brainstem interface facilitating the dissection. The lateral and inferior tumor extensions in relationship to the clivus can be more easily accessed.

EP-070[Neurooncologic Surgery]

ENDOSCOPIC EXTENDED TRANSSPHEROIDAL APPROACH (TRANSPALANUM) FOR RESECTION OF HUGE AND EXTENDED PITUITARY MACROADENOMA: ELABORATE BUT SAFE AND EFFECTIVE SURGICAL APPROACH TO DEAL WITH THIS SURGICAL DILEMMA

Guive Sharifi¹, Maryam Jalesi², Seyed Ali Mousavinejad¹, Mohammad Samadian¹, Reza Jabbari¹, Navid Farzin¹, Omidvar Rezaie¹

¹department of neurosurgery, loghman hospital, shaheed beheshti university, tehran, iran

²department of ENT, RASOOL hospital, iran university, tehran, iran

INTRODUCTION - OBJECTIVE: Previously huge and pituitary adenoma with superior and anterior extensions assumed contraindication to transsphenoidal approach. Passing indispensable learning curve we tried extended transplanum transtuberulum approach to resect huge extended macroadenoma.

METHOD: In 44 cases extended approach was used in last three years (2010- 2013). Inclusion criteria was huge suprasellar, subfrontal or intraventricular extensions which usually preclude only TSS approach to succeed. 8 of our cases were previously failed operations (transcranial or TSS). After classic exposure of sell tuberculum sella and planum sphenoidale were removed by powered drill.

RESULTS: in all cases we were able to perform total resection and remove the subfrontal intraventricular and interpeduncular fossa extensions set aside cavernous sinus involvement. No patient experience worsening of vision or new neurological deficit. In 60% of cases the pituitary gland was saved and at three month postop we observed acceptable adeno hypophysis physiology. thirty five cases had transient diabetes insipidus. In one patient has late post op CSF leak and we were suspicious of meningitis that she controlled with empirical antibiotic and bed rest and her problem resolved. One patient came around badly after surgery and after diagnosis of intrasellar, suprasellar hematoma with compression of midbrain, treated with endonasal exploration and hematoma evacuation with good results

CONCLUSIONS: Using this technique and applying angled lenses surgeon can manage huge adenoma like a usual macroadenoma and successfully resects extension which usually needs separate surgical approach. Rate of CSF leak in our series is the same as our other cases indebted to pediculated nasoseptal flap when it felt necessary (23 cases).

EP-071[Neurooncologic Surgery]

OPTIMIZATION OF SURGICAL TREATMENT OF MULTIPLE BRAIN TUMORS

Serik Karibai, Baglan Mustafayev

JSC "National Center of Neurosurgery" Astana, Kazakhstan.

INTRODUCTION - OBJECTIVE: The increase in detection of multiple tumors, including metastases, has become possible due to the development and implementation of neurovisualization diagnostic methods, as well as the increase in the length of remissions and the higher survival rate of the more effective modern treatment programs. The purpose of the study is the optimization of surgical treatment of patients with multiple brain tumors.

METHOD: This work presents an analysis of surgical treatment of 9 patients with multiple brain tumors, operated in general neurosurgery departments of the «National Center of Neurosurgery» JSC, during 2013-2014. At the moment of admission the patients' Karnofsky index varied between 40 and 60, with the average of 50.2±8.6. All patients underwent surgical treatment for the purpose of histological identification of the tumor to determine further tactics of adjuvant therapy and maximum possible cytoreduction of the pathological tissue. The main operative treatment was the removal of the tumor node which caused mass-effect and was the primary cause of the dominating neurological disorders.

RESULTS: In the early postoperative period, the intensity of neurologic deficit decreased in 7 patients and remained the same in 2 patients. At discharge, patients' Karnofsky index varied between 50 and 90, with the average of 60.6±12.4. All the patients were referred to further adjuvant chemo- and radiotherapy.

CONCLUSIONS: Surgical treatment is the main method; the tactics of surgical treatment of multiple brain tumors is affected by the number of tumor lesions, their location and size, the intensity of mass-effect, and the degree of functional compensation in the patient.

EP-072[Neurooncologic Surgery]

INCIDENCE OF PRIMARY BRAIN TUMORS AMONG RESIDENTS OF CHUI REGION AND BISHKEK CITY

Eleonora Tuuganbaevna Nazaralieva, Buranbek Djamyrgychievich Diusheev

Department of neurosurgery №1, National Hospital, Bishkek, Kyrgyzstan

INTRODUCTION - OBJECTIVE: An epidemiological study of the incidence of primary brain tumors (PBT) among residents of Chui region and Bishkek city for the period 2001-2010.

METHOD: The Object of the study were residents of Chui region and Bishkek city, who were treated for PBT in hospitals providing specialized of neurooncologic care.

RESULTS: From 2001 to 2010, just in Chui region and Bishkek city were registered 474 cases PBT. 224 cases PBT residents Chui region. The average incidence among residents PBT Chui region is $2,9 \pm 0,2$ per 100 thousand population. Most disadvantaged in terms of neurooncologic are Issyk -Ata (3.8 per 100 thousand population) Alamedinskii (3.7 per 100 thousand) and Sokuluk (3.2 per 100 thousand) areas. The average incidence PBT for 10 years among the inhabitants of Bishkek city was $3,2 \pm 0,3$ per 100 000 population. PBT incidence among men was 2.6 per 100 000 population and was comparable in Bishkek city and Chui region ($2,6 \pm 0,6$ and $2,4 \pm 0,1$ per 100 thousand population, respectively). In women, the incidence in general was considerably higher ($3,5 \pm 0,3$). PBT peak incidence occurs between the ages 55-64 years, which in this age range was 8.9 cases per 100 thousand population.

CONCLUSIONS: PBT incidence among residents of the Chui region during the period 2001-2010 was 2.9 per 100.000 population, residents of Bishkek city - 3.2. PBT peak incidence occurs between the ages 55-64 years and in this age group was 8.9 cases.

EP-074[Neurooncologic Surgery]

A RARE SELLAR LESION: ACTINOMYCES INFECTION

Serkan Civan¹, Murat Kocaoglu¹, Eyüp Baykara¹, Mevci Özdemir¹, Nejdet Ardic², Özkan Çeliker¹

¹Department of Neurosurgery, Pamukkale University, Denizli, Turkey

²Department of Otolaryngology, Pamukkale University, Denizli, Turkey

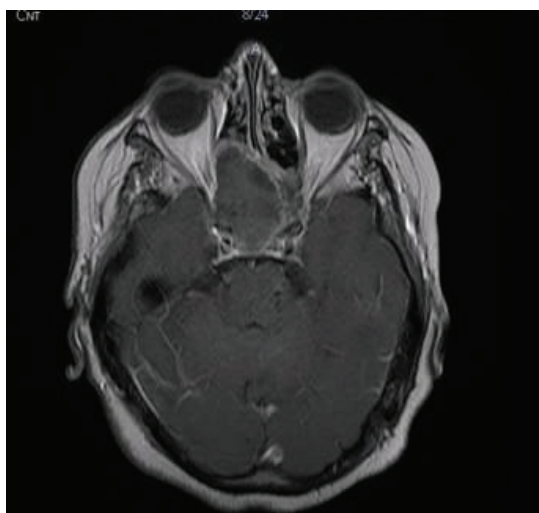
INTRODUCTION - OBJECTIVE: Sellar lesion is a significant part of intracranial tumors. Differential diagnosis of sellar lesions include pituitary tumors, non-pituitary tumors, metastatic tumors, cysts, malformations, inflammatory events and vascular lesions. In this article, actinomyces infection was presented as a rare sellar lesion

METHOD: 64 years old female patient admitted another center due to severe headache and impaired vision in the right eye. The magnetic resonance imaging (MRI) was performed and the patient was referred to our clinic with diagnosis of pituitary macroadenoma. Physical examination was not significant features, but the patient had visual field loss on right eye on neurological examination. The laboratory tests and hormones profiles levels were no abnormality.

RESULTS: The patient underwent surgery. The endonasal-transsphenoidal approach was performed by using neuronavigation on the supine position. Once entering the sphenoid sinus, we have reached the lesion. The lesion was dirty yellow color, soft consistency, avascular structure and it was totally removed. There wasn't any complication in postoperative period. The histopathological result was Actinomyces abscess. The antibiotic treatment was given immediately after the operation. The patient was full recovery in the follow-up period. Her visions improved.

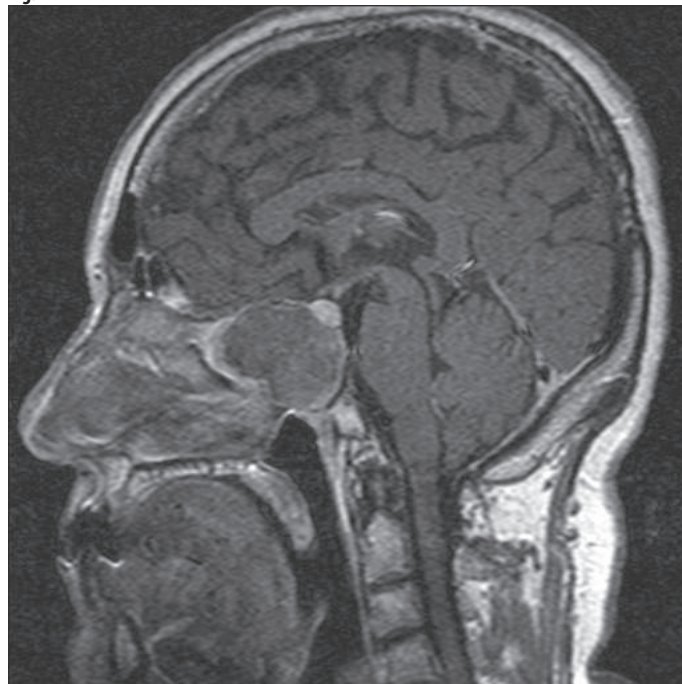
CONCLUSIONS: Actinomyces israelii is an anaerobic gram-positive bacterium. Actinomyces infections cause purulent abscesses and sulfur granules are characteristic under microscopic examination. Surgical drainage and antibiotic therapy are performed in the treatment. The neurosurgeons should be keep in mind that actinomyces infection can be confused easily with pituitary adenoma under defines of the radiological finding

Fig. 1



Preoperative axial view of pituitary MRI

Fig. 2



Preoperative sagittal view of pituitary MRI

EP-075[Neurooncologic Surgery]

MINIMALLY INVASIVE APPROACH FOR ANTERIOR SKULL BASE LESIONS

Ali Ayyad, Firas Hammadi, Alf Giese

Department of neurosurgery, Johannes Gutenberg university

INTRODUCTION - OBJECTIVE: The priority in contemporary Surgery is to achieve the greatest therapeutic effect while causing the least iatrogenic injury. The evolution of microsurgical techniques with refined instrumentation and illumination and the enormous development of diagnostic tools enable neurosurgeons to treat different lesions through limited and specific keyhole approaches. The introduction of the endoscope in neurosurgical procedures has brought a further new dimension into the field of intraoperative visualization.

METHOD: During a 9 years period between Oct.2000 till Dec.2012 we have performed 903 endoscopic assisted microsurgical procedures for ant. Skull base lesions including: Aneurysms (ICA, A.C.A, A.com.A, P.Com.A) 483 Meningiomas 164 Craniopharyngiomas 87 Pituitary adenomas 36 Arachnoid cyst 43 Epidermoid/Dermoid cysts 33 Astrocytomas 29 Germinoma 9 Teratoma 14 Hamartoma 5

RESULTS: The postoperative complications associated with the approach were: partial supraorbital hypesthesia 17, Palsy of the frontal branch of the facial nerve appeared 14, permanent hyposmia appeared 17 patients, wound healing disturbances occurred 4, CSF collection and leak 8, Pituitary insufficiency 4 patients

CONCLUSIONS: the supraorbital craniotomy allows a wide, intracranial exposure for deep-seated intracranial areas. The supraorbital craniotomy offers equal surgical possibilities with less approach-related morbidity owing to limited exposure of the cerebral surface and minimal brain retraction. The optical advantages of the endoscopic visualisation in anatomical orientation and surgical dissection improves the surgical outcome. All these factors contribute to improve the postoperative results due to reduction of the complications. In addition the minimally invasiveness of the procedure results in pleasing cosmetic outcome.

EP-076[Neurooncologic Surgery]

ENDOSCOPIC TRANSSPHEOIDAL APPROACH FOR PITUITARY ADENOMA; 10 YEARS EXPERIENCE

Ali Ayyad, Jens Conrad, Alf Giese

Department of neurosurgery, Johannes Gutenberg university

INTRODUCTION - OBJECTIVE: The transsphenoidal route is a direct and rapid extracerebral approach to the sellar region, and therefore, it is the most widely used technique for the processes involving this area. Since its introduction in 1907 it has been subjected to tremendous developments. The endoscope is the latest innovation in the field of optical instrumentation; it allows the 'surgeon's eye' to penetrate the depth and width of the access route.

METHOD: During 4 years between Dec.2003 till Dec.2013 we have operated 427 patients with pituitary macroadenoma, including 19 giant adenoma. 219 males, 208 females. 115 had hormone active tumors (64 GH, 25 ACTH, 14 Prolactinoma, 7 GH+Prol., 3 LH+FSH), 194 with non functioning adenoma. Most patients presented with visual disturbances.

RESULTS: Total excision was achieved in 90% of patients. From 76 patients with active adenoma 75% were in remission postop. 85% of patients with visual disturbances showed improvement. No visual deterioration. Complications were: 2 patients developed postoperative bleeding, 3 patients had postoperative CSF rhinorrhea. 46 hyposmia or anosmia. 2 Mortalities.

CONCLUSIONS: The minimum traumatization of the nasal cavity without nasal retractor, the optical advantages of the endoscopic visualization in anatomical orientation and tumor removal and the early postoperative improvement of the patients without nasal packing are obvious advantages of the endoscopic binostril technique.

EP-077[Neurooncologic Surgery]

SKULL BASE AND CRANIO-CERVICAL JUNCTION LYMPHOMA – STRATEGY OF SURGICAL TREATMENT – CASE REPORT

Zygmunt Siedlecki, Maciej Sniegocki, Sebastian Grzyb, Mateusz Szostak, Karol Nowak, Wojciech Smuczynski

Department of Neurosurgery and Neurotraumatology, Nicolaus Copernicus University, Bydgoszcz, Poland

INTRODUCTION - OBJECTIVE: Primary lymphoma of skull base is uncommon. It is considered to be the rarest location in the group of bone lymphomas. In literature no information about such lymphomas is found. This case demonstrates extremely rare finding of skull base and craniocervical joint lymphoma causing instability and pain of neck and occiput. 62-year-old man was admitted to hospital because of this pain and the compulsory fixation of head to left side. A physical examination identified paresis of right-side cranial nerves V-XII. MRI revealed a homogeneously enhancing tumor of clivus, right cavernous sinus, right petrous bone, and occipital condyle with destruction of right the atlantooccipital joint and foramen magnum.

METHOD: The concept of surgical treatment was established. In sitting position of patient the posterior approach to occiput and cervical spine was achieved. Posterior arch of C1 and margin of foramen magnum was removed. On the right side of foramen magnum grey pathologic tissue of tumor was found. About 2 cm³ of tumor was taken as a biopsy. In the next step of procedure laminar hooks were attached to C2-C4 and occipital plate was screw on. Then the rod was fixed and laminar hooks were linked to occipital plates for craniocervical stabilization.

RESULTS: There were 3 purposes of surgical procedure: 1. biopsy to obtain tumor tissue, 2. stabilization of craniocervical joint to relieve pain causing by instability, 3. foramen magnum decompression to prevent potential fatal tonsillar herniation.

CONCLUSIONS: These purposes seem to be optional directive in neurosurgical treatment of lymphomas of skull base and craniocervical joint.

EP-078[Neurooncologic Surgery]

FACTORS AFFECTING THE BIOLOGICAL BEHAVIOR AND PROGNOSIS OF MENINGIOMAS

Numan Karaarslan¹, Özkan Ateş¹, Veli Çitilisi³, Tezcan Çalışkan⁴, Sabri Gürbüz²

¹Namık Kemal University medical faculty Neurosurgery department, Tekirdağ, Turkey

²SB Haydarpasa Numune Training and Research Hospital, Department of neurosurgery, Istanbul, Turkey

³Pamukkale university medical faculty, Department of neurosurgery, Denizli, Turkey

⁴GaziOsmanPaşa University medical faculty, Neurosurgery Department, Tokat, Turkey

INTRODUCTION - OBJECTIVE: Meningiomas are mostly extra-axial benign tumors whose biological behavior pattern isn't always possible to be predicted in advance. Although there are many studies on the biological behavior and prognosis of tumor tissue, it has been concluded that especially the localization, invasion to surrounding tissue, age, gender and the degree of surgical resection are the effective factors. In this study, the factors affecting the behavioral pattern and prognosis of meningiomas are discussed.

METHOD: The records of 79 patients operated on for meningioma between 2005-2010 at the Neurosurgery Clinic, S. B. Haydarpasa Numune Education and Research Hospital were analyzed retrospectively. The patients' age, gender, blood type, history of alcohol intake and smoking, meningioma localization, peritumoral edema, Simpson and Kobayashi surgical grade, meningioma histological subtype, meningioma grade and recurrence information were obtained from clinical records.

RESULTS: In this study, it was determined that histopathological subtype and the degree of surgical resection had a significant role in prognosis of meningioma. Moreover, it was considered that the presence of tumor localization and peritumoral edema might affect prognosis and biological behavior of meningioma, however it was concluded that studies with larger series are needed.

CONCLUSIONS: The factors that may play a role in the biological behavior and prognosis of meningiomas were discussed in this study. In particular, it was identified that histopathological subtype and the degree of surgical resection had an important role in prognosis. Moreover, it was considered that the localization of tumor and the presence of peritumoral edema might affect the biological behavior and prognosis of meningioma.

Figure 1

Table 1: Histopathological Type Distribution

Histopatolojik Tip	Grade I; n (%)	Grade 2; n (%)	Total; n (%)
Anjiomastik	1 (%1,7)	0 (%0)	1 (%1,3)
Anjiok	0 (%0)	16 (%80)	16 (%20,3)
Berrak Hücreli	0 (%0)	2 (%10)	2 (%2,5)
Fibroblastik	3 (%15,1)	0 (%0)	3 (%3,8)
Kordoid	0 (%0)	2 (%10)	2 (%2,5)
Meningeotelyal	13 (%62,2)	0 (%0)	13 (%16,5)
Mikrokistik	1 (%1,7)	0 (%0)	1 (%1,3)
Pammonastik	2 (%10,4)	0 (%0)	2 (%2,5)
Transizyonel	39 (%66,1)	0 (%0)	39 (%49,4)
Toplam	59 (%100)	20 (%100)	79 (%100)

Lokalizasyon	Histopatolojik Grade		p
	Grade I n (%)	Grade II n (%)	
Falks	4 (%6,8)	2 (%10)	0,648
Intraventrüküller	0 (%0)	1 (%5)	0,253
Klinoid	1 (%1,7)	1 (%5)	0,445
Konveksite	16 (%27,1)	7 (%35)	0,573
Olfaktor Oluk	8 (%13,6)	2 (%10)	0,679
Parasagittal	10 (%16,9)	4 (%20)	0,744
Petroklival	1 (%1,7)	1 (%5)	0,445
Planum Sfenoidal	1 (%1,7)	0 (%0)	1,000
Sfenoid Kanat	12 (%20,3)	4 (%20)	0,974
Sp. Köşe	2 (%3,4)	0 (%0)	1,000
Tentorial	1 (%1,7)	0 (%0)	1,000
Tuberkulum Sella	4 (%6,8)	0 (%0)	0,567

Table 3: Blood Distribution According to Histopathological Grade

Kan Grubu	Histopatolojik Grade		p
	Grade I n (%)	Grade II n (%)	
A (-)	3 (%5,1)	0 (%0)	
A (+)	24 (%40,7)	12 (%60)	
AB (+)	1 (%1,7)	2 (%10)	
B (-)	1 (%1,7)	0 (%0)	0,224
B (+)	9 (%15,3)	2 (%10)	
0 (-)	2 (%3,4)	0 (%0)	

Table 4: Smoking According to Histopathological Grade

Sigara	Histopatolojik Grade		p
	Grade I n (%)	Grade II n (%)	
Var	18 (%30,5)	5 (%25)	0,639
Yok	41 (%69,5)	15 (%75)	

Table 5: The Correlation between Peritumoral Edema and Localization

Lokalizasyon	Peritumoral Ödem		p
	Var n (%)	Yok n (%)	
Falks	2 (%4,5)	4 (%11,4)	0,398
Intraventrüküller	1 (%2,3)	0 (%0)	1,000
Klinoid	1 (%2,3)	1 (%2,9)	1,000
Konveksite	15 (%34,1)	8 (%22,9)	0,275
Olfaktor Oluk	4 (%9,1)	6 (%17,1)	0,285
Parasagittal	7 (%15,9)	7 (%20)	0,686
Petroklival	0 (%0)	2 (%5,7)	0,193
Planum Sfenoidal	0 (%0)	1 (%2,9)	0,480
Sfenoid Kanat	15 (%34,1)	1 (%2,9)	0,001**
Sp. Köşe	0 (%0)	2 (%5,7)	0,193
Tentorial	1 (%2,3)	0 (%0)	1,000
Tuberkulum Sella	1 (%2,3)	3 (%8,6)	0,317

Table 6: The correlation between surgical grade and tumor recurrence

	Nüks		p
	Var n (%)	Yok n (%)	
Simpson Grade	Grade I 4 (%44,4)	46 (%65,7)	0,442
	Grade II 2 (%22,2)	24 (%34,3)	
	Grade IV 3 (%33,3)	0 (%0)	
Kobayashi Grade	Grade I 4 (%44,4)	46 (%65,7)	0,649
	Grade II 2 (%22,2)	11 (%15,8)	
	Grade IV A 2 (%22,2)	0 (%0)	
	Grade IV B 1 (%11,1)	0 (%0)	

EP-079[Neurooncologic Surgery]

GIANT PRIMARY DURAL LYMPHOMA WITH VAULT INVOLVEMENT: CASE REPORT AND SYSTEMATIC LITERATURE REVIEW

Brahim Eljebbouri, Jawad Laaguili, Adil Belhachmi, Miloudi Gazzaz, Brahim El Mostarchid
Department of Neurosurgery Mohamed V Military Teaching Hospital Rabat, University of Mohamed V Souissi. Rabat Morocco

INTRODUCTION - OBJECTIVE: To report a case of giant primary dural lymphoma with vault involvement mimicking frontal meningioma and illustrate the efficacy of surgical removal completed by chemo and radiotherapy.

METHOD: A 52-year-old man was referred because of frontal painless bossing ho gradually increased in size. Clinical and radiologic evaluation showed a giant frontal tumor suspecting most likely a meningioma

RESULTS:bitragal approach was used to expose the tumor and we conducted a total removal of the tumor facilitated by a cleavage plane all around the latter. Pathological studies are in favor of a dural lymphoma.

CONCLUSIONS: Primary dural lymphoma (PDL) is extremely rare. Surgical excision followed by radiotherapy and chemotherapy are recommended.

EP-080[Neurooncologic Surgery]

INTRACRANIAL METASTASIS OF GLIOBLASTOMA MULTIFORME: CASE PRESENTATION

Anas Abdallah, Mustafa Levent Uysal, Erhan Emel, Müslüm Güneş, Betül Güler, İlhan Aydın, Rashid Avyasov, Sarper Polat, Emre Abdullah Taçyıldız
Bakırköy Research and Training Hospital for Neurology Neurosurgery, and Psychiatry, Department of Neurosurgery, İstanbul, Turkey

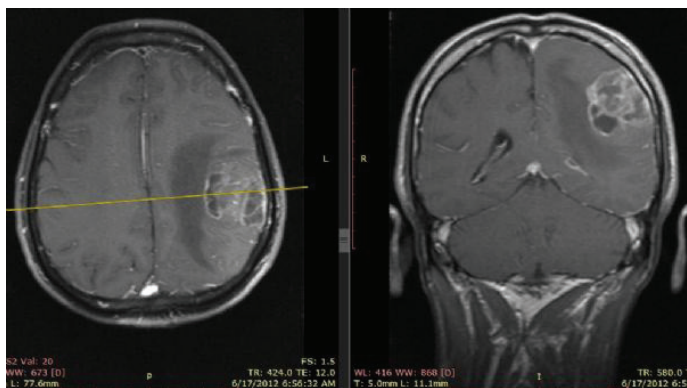
INTRODUCTION - OBJECTIVE: Glioblastoma Multiforme (GBM) is the most common primary malignant brain tumor in adults. It is characterized by a rapid and frequent tendency to local recurrence as same as rare distant intracranial metastasis related to the primary tumor localisation as well. This report describes a rare case of intracranial metastasis of GBM.

METHOD: A 51 year-old man had referred to our hospital with right side hemiparesis, nausea and vomiting. Excluding +4/5 grade of weakness in the right side, dysarthria and ataxic gait there was no significant neurological deficit. MRI revealed on signal tumor heterogeneity in the left parietal lobe. The patient had been managed surgically using stereotactic surgical procedure to achieved total excision of the mass which diagnosed histopathologically as GBM grade IV WHO. The patient was well till experienced dysarthria, gait disturbance, generalized seizure, and imbalance 21 months later. MRI revealed on heterogeneity lesion in left superior frontal lobe.

RESULTS:The patient had been reoperated and total excision was performed. Histopathological diagnosis was revealed on GBM grade IV. Postoperative neurological examination revealed on eyes open was spontaneously, best verbal response was inappropriate words, he did not Obey commands but localized pain, pupils were equal, round and reactive to light normally. Motor strength of the right side was evaluated as 2/5 grade of weakness.

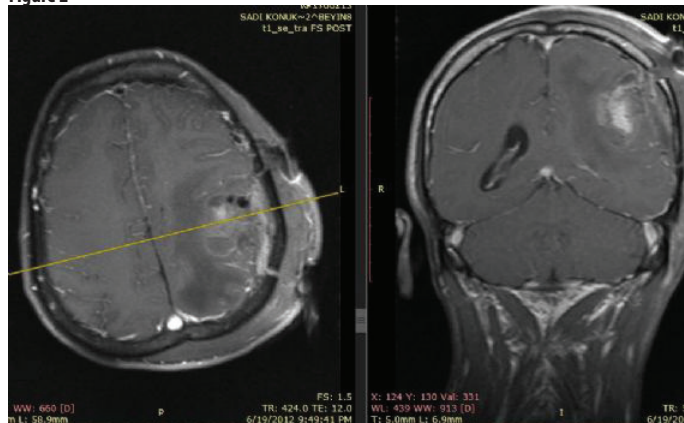
CONCLUSIONS: The spread of cancer cells of GBM within the nervous system takes place mainly via cerebrospinal fluid. Although our neurosurgeon avoid opening the cerebrospinal spaces using stereotactic procedure, our patient was involved with early intracranial metastasis.

Figure 1



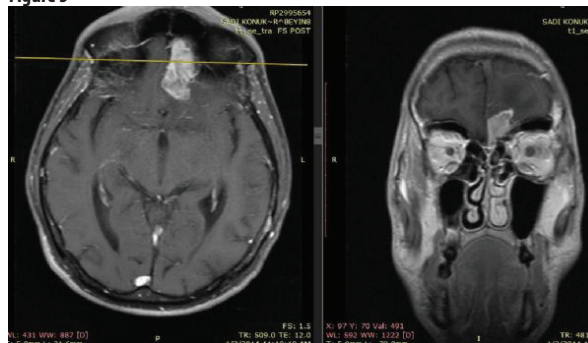
T1-weighted MRI that revealed on signal tumor heterogeneity that surrounded by edema in the left parietal lobe.

Figure 2



Postoperative T1-weighted MRI (after first surgery) showed that the signal tumor in the left parietal lobe had been removed surgically.

Figure 3



T1-weighted MRI revealed on signal tumor heterogeneity that surrounded by edema in the left frontal lobe. Note there is no focus in left parietal lobe.

EP-081[Neurooncologic Surgery]

PRIMARY HEMANGIOMA OF THE SKULL: CASE REPORT

Anas Abdallah, Müslüm Güneş, Erhan Emel, Betül Güler, İlhan Aydın, Sarper Polat, Emre Abdullah Taçyıldız
Bakırköy Research and Training Hospital for Neurology Neurosurgery, and Psychiatry, Department of Neurosurgery, İstanbul, Turkey

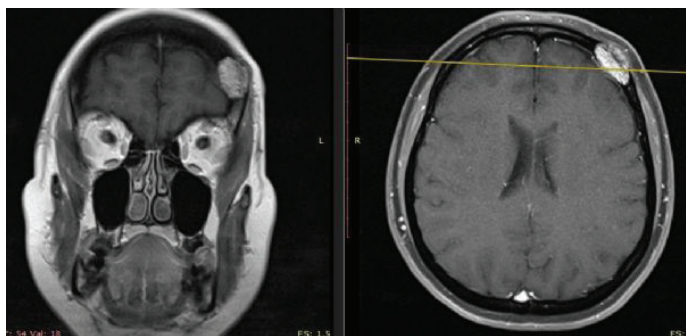
INTRODUCTION - OBJECTIVE: Primary osseous hemangiomas (POHs) are common benign vascular tumors that may involve any part of the body. POHs occur in the spine frequently, but those of the skull are infrequent. POHs account for 0.2% of all bone tumors. This report describes a rare case of skull cavernous hemangioma.

METHOD: A 32 year-old female patient presented to our outpatient polyclinics of neurosurgery with headache and swelling on left frontal bone. She was on drug treatment for depression, and had undergone tonsillectomy while she was 15 years old. There was no known significant past medical history. On examination, there was no any neurological deficit. Rest of the systemic examination was unremarkable. Cranial CT and MRI were revealed on intraosseous expansive lytic lesion on the left frontal region, without signs of brain tissue involvement. There was no symptom attributable to the bone lesion. She underwent left frontal craniectomy with en bloc resection of the osseous lesion with total excision of soft tissue, followed by cranioplasty with acrylic cement.

RESULTS:The histopathological examination revealed on primary osseous cavernous-type hemangioma and lipoma, respectively. Postoperative cranial CT was performed and there no pathological lesions were detected. On follow-up after 3 months neurological examination was normal and there was no recurrence detected.

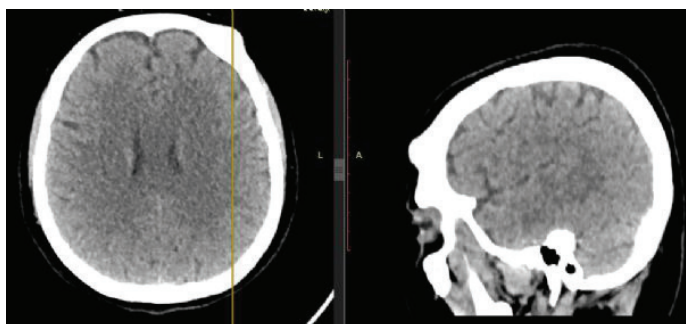
CONCLUSIONS: Although cavernous hemangiomas more often involve the brain parenchyma, skull bones may also be affected. En bloc resection of the lesion reduces the risk of bleeding, always potentially high in these tumors. Relapse is rare when adequate safety margins are Observed.

Figure 1



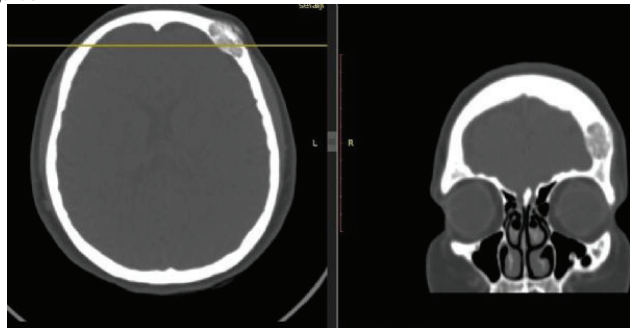
The cranial MRI revealed an intraosseous expansive lytic lesion on the left frontal region, without signs of brain tissue involvement.

Figure 2



The cranial CT revealed an intraosseous expansive lytic lesion on the left frontal region, restricted in bone of skull. Note that normal brain tissue did not involve with lesion.

Figure 3



The cranial CT revealed an intraosseous expansive lytic lesion on the left frontal region, restricted in bone of skull.

EP-082[Neurooncologic Surgery]

PRIMARY CENTRAL NERVOUS SYSTEM LYMPHOMA (PCNSL) PRESENTING AS BEHÇET'S DISEASE: CASE REPORT

Anas Abdallah, Hasan Burak Gündüz, Betül Güler, Erhan Emel
Bakırköy Research and Training Hospital for Neurology Neurosurgery, and Psychiatry, Department of Neurosurgery, İstanbul, Turkey

INTRODUCTION - OBJECTIVE: PCNSL may be indistinguishable clinically and radiologically from some white matter diseases, including Behçet's syndrome, multiple sclerosis, demyelinating or inflammatory disorders. This report describes a rare case of PCNSL mimicking a neuro-Behçet disease.

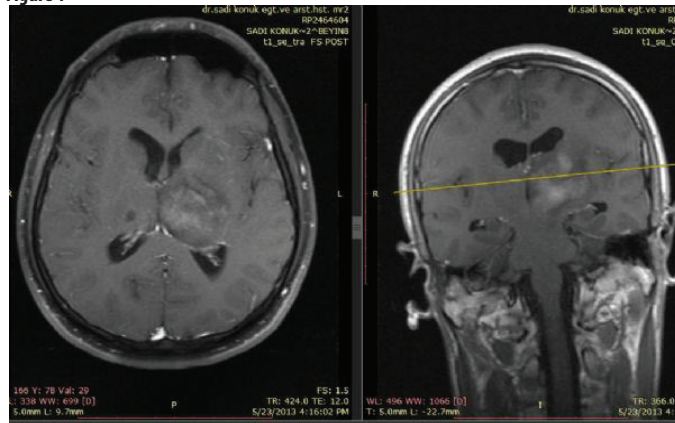
METHOD: A 26-year-old right-handed man had referred to neurology department of our hospital with right hemiparesis and loss of the sensation of the right side developed acutely, after tooth extraction. Examination showed motor deficit in the right side weakness, hypoesthetic right upper facial spasm, diplopia associated with bilateral restriction of upward gaze, and right central facial palsy. Radiological investigation suggested multiple lesions in both of the left, right thalamus and in other localizations in the brain were hyperintense on T2-Flair weighted images. His father had a history of Behçet disease and major depression. His past medical history was unremarkable. HLA-B51 was positive.

RESULTS: The patient had been diagnosed as Behçet's disease and received steroid therapy, but there was no response detected and repeated MRI demonstrated progression of the initial lesions. The patient has been referred to our neurosurgery department to confirm diagnosis by taking biopsy. Histopathologically;

Obtained pieces were proved that a lesion was diffuse large B-cell lymphoma. The patient was referred to oncology department to receive radiotherapy. On follow-up after 12 months a remarkable improvement of the neurologic symptoms was achieved with persistent complaints of vision.

CONCLUSIONS: Unfortunately, delayed diagnosis and treatment of PCNSL can negatively affect the prognosis. If the patients with white matter diseases do not response well to medical treatment, the stereotactic biopsy is favorable.

Figure 1



T2- and Flair weighted MRI after mild enhancement a contrast substance shows multiple lesions in both of the left and right thalamus were hyperintense, as well as lesions in all of the corona radiata, centrum semiovale, frontoparietal lobe, periventricular and subcortical white matter areas were mildly hyperintense too.

EP-083[Neurooncologic Surgery]

FACIAL NERVE PRESERVATION WITH PREOPERATIVE IDENTIFICATION AND INTRAOPERATIVE MONITORING IN LARGE VESTIBULAR SCHWANNOMA SURGERY

Hongyi Liu¹, Yuhai Zhang¹, Yuanjie Zou¹, Wenbin Zhang¹, Rui Zhang¹, Xiang Liu¹, Zhuhai Lv¹, Kun Yang¹,
Xinhua Hu¹, Chaoyong Xiao², Wen Liu²

¹Department of Neurosurgery, Nanjing Brain Hospital, Nanjing Medical University, Nanjing, China

²Department of Medical Imaging, Nanjing Brain Hospital, Nanjing Medical University, Nanjing, China

INTRODUCTION - OBJECTIVE: Anatomical and functional preservation of facial nerve (FN) is still a challenge in large vestibular schwannoma (VS, ≥ 30 mm in maximal extrameatal diameter) surgeries. Preoperative identification of FN with magnetic resonance (MR) diffusion tensor tracking (DTT) and intraoperative identification with facial electromyography (EMG) may be desirable for improving functional results of FN.

METHOD: Twenty-three consecutive cases with large VS were retrospectively studied. FN DTT was performed in each case preoperatively. All the cases underwent microsurgery with intraoperative FN EMG monitoring. Correctness of prediction for FN location by DTT was verified by the surgeon's inspection. Postoperative FN function was followed up.

RESULTS: Maximal extrameatal diameter of the tumors was 3.0-6.0cm (mean 3.8cm). Preoperative identification of FN was possible in 18 of 23 (78.3%) cases. The course of each FN was consistent with the surgical findings in all the 18 cases. Facial EMG responses were usually elicited by stretching or compressing the FN. If the facial EMG was fixed by manipulation around the FN, the surgeon was alarmed to pause his manipulation. Stimulated facial EMG was useful in locating the FN or confirming the integrity of the nerve. Total resection was achieved in 20 of 23 (87.0%) and subtotal resection in 3 cases. All FNs were anatomically preserved. All cases had excellent facial nerve function (HB Grade I-II) at last follow-up 1-25 months postoperatively.

CONCLUSIONS: FN DTT is a powerful technique in preoperative identification of FN in large VS cases. Continuous intraoperative FN EMG monitoring is contributive to locating and protecting FNs.

EP-084[Neurooncologic Surgery]

SQUAMOUS CELL CARCINOMA ARISING FROM INVERTED PAPILLOMA OF NOSE PRESENTING AS CEREBRAL TUMOR

Haroon Pillay

RIPAS hospital, Brunei

INTRODUCTION - OBJECTIVE: Presenting a rare case of squamous cell carcinoma arising from inverted papilloma of the nose manifesting as intracerebral tumor

METHOD: 52 year old lady presented with head ache and mood changes of 1 month duration. She also noticed a progressive swelling of the forehead since 2 weeks.

RESULTS: Nasal endoscopy revealed a submucosal tumor. MRI brain showed an left frontal intracerebral tumor in continuity with the medial orbit and nasal cavity. The tumor was also eroding the frontal bone and presenting subcutaneously. The tumor was excised using a bifrontal craniotomy and glabellar osteotomy. Total excision of the tumor was done. The medial wall of the orbit was reconstructed using titanium mesh and the floor of anterior cranial fossa was reconstructed using a double layer of fascia lata reinforced with Tissue glue. The patient made an uneventful recovery.

CONCLUSIONS: Inverted papillomas rarely undergo squamous cell metaplasia. It is even more rare to see such a tumor invading the brain and presenting as a subcutaneous mass in the forehead. Prompt recognition and radical excision followed by radiotherapy is the treatment of choice.

EP-085[Neurooncologic Surgery]

MULTIPLE ROSAI–DORFMAN DISEASE PRIMARILY INVOLVED IN CENTRAL NERVOUS SYSTEM: A SINGLE CASE REPORT AND LITERATURE REVIEW

Zhengxiang Luo¹, Penglai Zhao¹, Wei Miao², Jinbing Zhao¹¹Department of Neurosurgery, NanJing Brain Hospital affiliated with NanJing Medical University, China²Department of Neurosurgery, ZhongDa hospital Southeast University, China

INTRODUCTION - OBJECTIVE: To summarize the clinical characteristics of multiple Rosai–Dorfman disease primarily involved in central nervous system and to explore the diagnosis and treatment.

METHOD: By combining literature review, we analysed the clinical, imaging and pathological characteristics as well as treatment and prognosis for a case of multiple Rosai–Dorfman disease primarily involved in central nervous system.

RESULTS: The largest intracranial lesion was totally resected and steroid administration and radiotherapy were performed phaselessly for the rest lesions. During the 1-year follow-up, the excised lesion didn't recur and no obvious variations were observed in the rest lesions.

CONCLUSIONS: Multiple Rosai–Dorfman disease primarily involved in central nervous system is rare, with similar imaging characteristics to those of meningiomas, and the pathological features indicated as lymphocytes and plasma cells reaching tissue cells with large volume and abundant cytoplasm. Operation is the preferred treatment as the effects by steroid administration and radiotherapy are not obvious.

EP-086[Neurooncologic Surgery]

RADIATION-INDUCED CEREBELLOPONTINE ANGLE (CPA) MENINGIOMA: CASE REPORT

Hasan Burak Gündüz, Anas Abdallah, Fatih Cesur, Erhan Emel, Betül Güler, Akin Öztürk, Melih Üçer
Bakırköy Research and Training Hospital for Neurology Neurosurgery, and Psychiatry, Department of Neurosurgery, İstanbul, Turkey

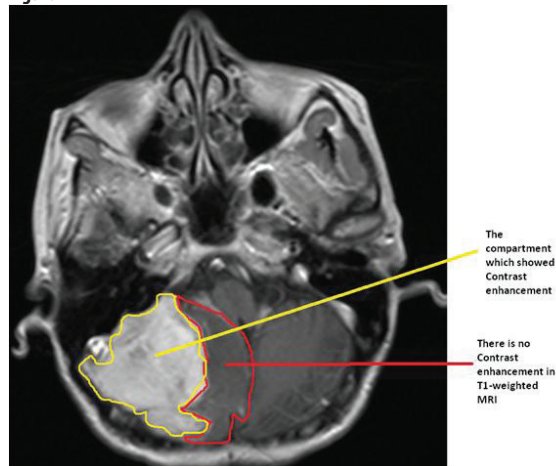
INTRODUCTION - OBJECTIVE: Radiation-induced meningioma (RIM) is the most common brain neoplasm known to be caused by ionizing radiation. This report describes a rare case of RIM that occurred after radiotherapy treatment of midline vermian medulloblastoma.

METHOD: A 38 year-old woman was underwent an operation because of the brain mass, 25 years ago. After Obtained a cranial CT that demonstrated a midline vermian mass, performed operation was right suboccipital craniectomy to remove the mass which diagnosed as desmoplastic medulloblastoma, histopathologically. The postoperative adjuvant RTP was performed with high-dose as 50 Gy at whole CNS, and the posterior fossa as a focal boost 15 Gy. The patient had been suffered year-controls for 25 years. Before this year control patient had referred to our hospital with headache, gait impairment, nausea and vomiting. Excluding right cerebellar tests were impaired, there was no significant neurological deficit. MRI revealed on signal tumor isointense in the right CPA that consist of two compartments; the medial compartment did not show contrast enhancement and the lateral compartment that belong to dura showed moderate contrast enhancement homogenously.

RESULTS: The patient had been managed surgically using right suboccipital craniectomy followed by total resection of the lateral compartment and biopsy of the medial compartment that thought to be radiation-induced fibrotic tissue. Total excised mass was diagnosed histopathologically as meningioma WHO Grade I, patient was well and discharged in the third.

CONCLUSIONS: Exposure to ionizing radiation has been shown to increase the risk of meningioma significantly. Total resection is recommended as a treatment choice.

Figure 1



Preoperative magnetic resonance imaging (MRI) performed in this year control, on April 2014. Preoperative coronal T1-weighted MRI showing a tumor of right CPA that measures 5.5x7x3 cm. Note that there are two compartments showed different contrast enhancing; the lateral compartment measures 4.2x6.2x3 cm that indicated by yellow color and showing contrast enhancement homogenously. The medial compartment measures 1.5x6.6x2.7 cm that indicated by red color and showing no contrast enhancement.

EP-087[Neurooncologic Surgery]

WORKING MEMORY AND EXECUTIVE FUNCTION IMPAIRED IN PATIENTS WITH FRONTAL GLIOMA

Hu Xinhua, Liu Yong, Yang Kun, Liu Hongyi

Department of Neurosurgery, Nanjing Brain Hospital affiliated to Nanjing Medical University, Nanjing, China

INTRODUCTION - OBJECTIVE: Most patients with frontal glioma have neurocognitive dysfunctions such as executive function, working memory and attention, that affect outcome. To date, there has been a lack of comprehensive assessment. This study was to evaluate the defects in working memory and executive function in patients with frontal glioma.

METHOD: This study recruited 28 patients with frontal glioma and 20 healthy control subjects from January 2011 to December 2013. The neurocognitive tests contained tests that estimate (1) information processing, (2) psychomotor function, (3) attention, (4) verbal memory, (5) working memory, and (6) executive functioning.

RESULTS: Compared to healthy control, patients performed poor on working memory and executive function. There were no differences in attention and verbal memory between the left and right hemisphere (15 left, 13 right) ($P=0.07$). Patients with left side glioma were significantly worse in working memory than in right side patients ($P=0.021$) but showed no correlation in executive function between the two groups ($P=0.12$).

CONCLUSIONS: This study showed a marked decline in working memory and executive function in patients with frontal glioma. Patients with left frontal glioma had significant deficits in working memory. The executive function of patients with glioma in frontal lobe had obvious impairment, but but has not specifically between left and right side.

EP-088[Neurooncologic Surgery]

PETROCLIVAL MENINGIOMAS: CHOOSING THE RIGHT APPROACH

Suresh Nair Narayanan Nair

Sree Chitra Tirunal Institute for Medical Sciences & Technology, Trivandrum, India

INTRODUCTION - OBJECTIVE: A retrospective analysis of 123 cases of petroclival-premeatal meningiomas surgically managed in their institute from 1st Jan 1990 till 1st Nov 2012 was carried out to see the outcome with various approaches.

METHOD: While the tumor resection was carried through an anterolateral/lateral route in 32 (27%), it was through a combined posterior subtemporal /pre or trans-sigmoid (posterior petrosal) in 24 (20%) & retrosigmoid supra-paracerebellar route in 58 cases (46%). In three cases with extra cranial extension to infratemporal area, a modified Fisch approach was used. Six patients who were in poor clinical condition had only a CSF diversionary procedure. The tumor could be radically removed in 80 patients (66%), subtotally in 27 (22%) and decompression only in 9. Seven patients had tumor excision in two stages. There was an operative mortality of 8.2% (10 cases).

RESULTS: Forty of the 53 patients who underwent surgical decompression since Jan 2004 were operated by the retrosigmoid route and operative mortality for this group of 53 patients have been less than 4% (2 cases). There was only one operative mortality among the last 40 cases operated by the retrosigmoid route. Out of the 85 patients on long term follow up 58 are independent. Seven out of the nine patients who had symptomatic recurrence were re-operated.

CONCLUSIONS: The percentage of these tumors operated by conventional retrosigmoid route has increased in the later part of the series thus proving that in many of these tumors without significant middle fossa extension, it is not necessary to use complex and time consuming skull base approaches.

EP-089[Neurooncologic Surgery]

EXPERIENCE OF SURGICAL TREATMENT OF SYRINGOMYELIA

Buranbek Djamgyrchievich Diusheev, Denis Sergeevich Pipchenko
department neurosurgery #1, National Hospital, Bishkek, Kyrgyzstan

INTRODUCTION - OBJECTIVE: Evaluate the results of different methods of surgical treatment of syringomyelia.

METHOD: The analysis of the results of treatment in 46 patients with syringomyelia (24 male and 22 female, aged 19 to 61 years) treated at the National Hospital from 2005 to 2013 year. The main research method was MRI using various application programs morphometric (Makhaon Lite).

RESULTS: Determining factors for the indication for neurosurgical intervention were: progressive form of the disease, the growth of disturbances liquorodynamics, cavities in the spinal cord in combination c craniovertebral anomalies. We have carried out 17 surgical cases. When the isolated form of syringomyelia (4 cases) conducted Syrinx - subarachnoid shunt silicone catheter for Albert L. Rhoton. In the case of a combination with syringomyelia craniovertebral anomaly development (in particular Chiari malformation type I) as the main method performed reconstructive surgery on craniovertebral level as economical resection of the occipital bone trepanation audit neural structures post cranial fossa -terminated plastic dura mater, fascia lata (12 cases). 1 case of application of two -stage operation. Results of surgical treatment using different methods of surgery were as follows: immediate improvement was seen in 13; stabilization process - in 3; progression of the process - in 1.

CONCLUSIONS: Effective method of treatment of syringomyelia is surgical intervention. But the search for new conceptual surgical solutions to ensure high efficiency of treatment continues.

EP-090[Neurooncologic Surgery]

DOWN-REGULATION OF PHOSPHOGLYCERATE KINASE 1 BY SHRNA SENSITIZES U251 XENOGRAFT TO RADIOTHERAPY

Hua Yan¹, Yi Jun Cheng¹, Hao Ding¹, Hua Qing Du², Hong Yi Liu¹, Hong Xiao²

¹Department of Neurosurgery, Nanjing Medical University, Affiliated Nanjing Brain Hospital, Nanjing, China

²Neuro-Psychiatric Institute, Nanjing Medical University, Affiliated Nanjing Brain Hospital, Nanjing, China

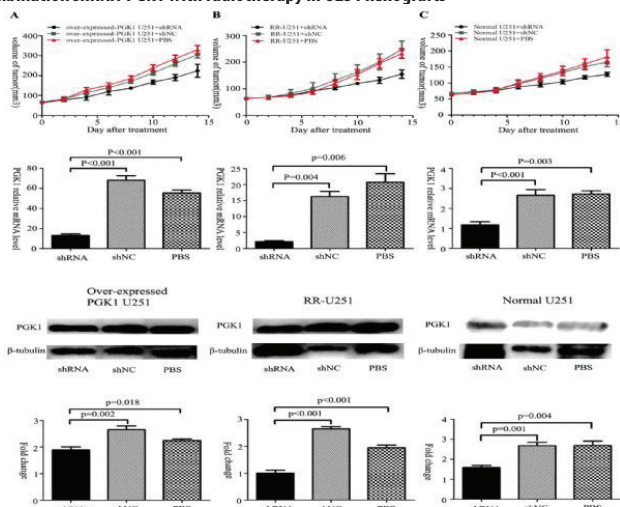
INTRODUCTION - OBJECTIVE: Phosphoglycerate kinase 1 (PGK1) has been shown to involve and impact glioma radioresistance. This study was designed to investigate the effect of PGK1 on radioresistance in vivo.

METHOD: The short hairpin RNA (shRNA)-PGK1 and pcDNA3.1-PGK1 were transfected into U251 cells by lipofectamineTM2000. After radiotherapy, the radiosensitivity of U251 xenografts was observed by tumor growth curve. The PGK1 expression of xenografts in different tumor models were evaluated by quantitative PCR, western blot and immunohistochemistry.

RESULTS: The expression of PGK-1 was maximally inhibited in response to shRNA4 at 24h after the transfection in vitro. Tumor growth of U251 xenografts was inhibited significantly by treating with shRNA-PGK1 and radiotherapy. In vivo, comparing with the treatment of shNC and PBS after the radiotherapy, the expression of PGK1 at mRNA levels and protein levels were down-regulated by the treatment of shRNA1.

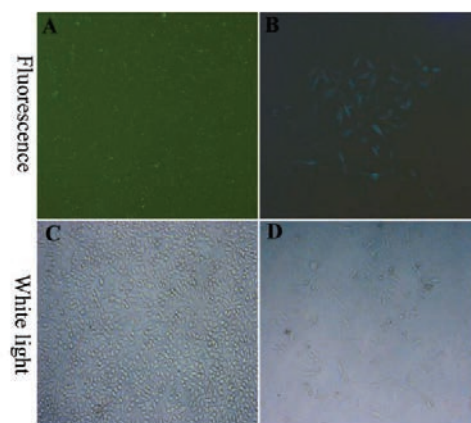
CONCLUSIONS: Depression of PGK1 could enhance the radiosensitivity of U251 xenografts and which suggested PGK1 may serve as a useful target in radioresistant glioma treatment. Hua Yan and Yi-Jun Cheng contributed equally in this study and should be regarded as co-first author.

Combination shRNA-PGK1 with radiotherapy in U251 xenografts



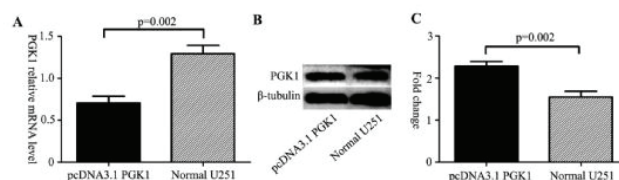
The growth of xenografts was inhibited by treating with PGK1-shRNA in Normal U251 group, RR-U251 group and over-expressed-PGK1 U251 group. About 2 days after first treatment, over-expressed PGK1 U251 xenografts acquired a faster growth rate compared with the Normal U251 and RR-U251 group tumors (Fig4).

Over-expression of PGK1 in Human Glioma Cells (1)



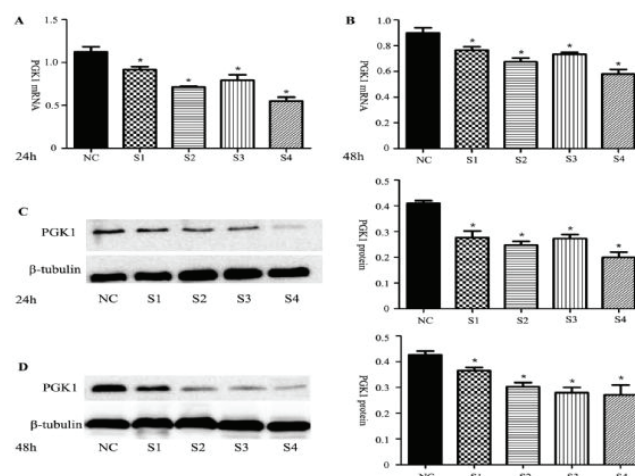
U251 cells were stable transfected with the pcDNA3.1-PGK1 plasmid, and visible green fluorescence were observed in the fluorescence microscope after transfection (Fig. 1A and C) and the efficiency is about 85-90%. Two weeks after the screening, most cells were killed by G418(400 g/ml), only a small number of cells survived and the formed of clones (Fig. 1B and D)

Over-expression of PGK1 in Human Glioma Cells (2)

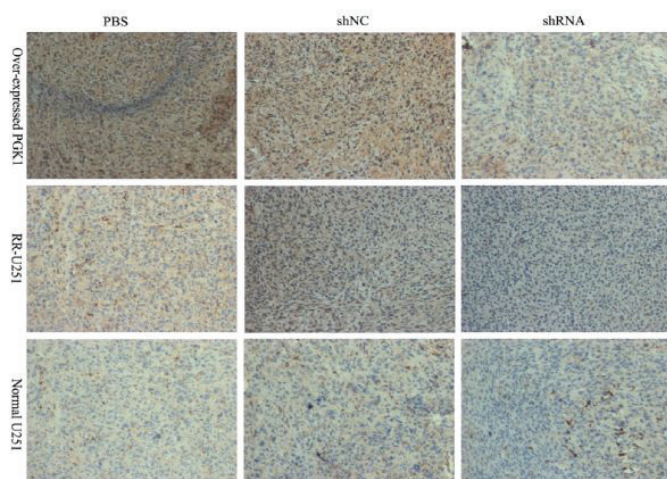


Stable clones were selected after 3 weeks, both mRNA and protein levels of PGK1 were up-regulated in U251 cells which treated with pcDNA3.1-PGK1 (Fig.2).

Selection of the most efficient shRNA specific to PGK1



Transfection of shRNA-PGK1 duplexes led to a stable exogenous gene expression with about 85-90% efficiency in U251 cells, all four duplexes showed an inhibitory effect on PGK1 expression both in mRNA and protein level ($p < 0.05$) (Fig.3)

Xenografts tumor sections showed extensive PGK1 staining by immunohistochemistry

shRNA down-regulated PGK1 expressing xenografts in all groups (Fig.5)

EP-091[Neurooncologic Surgery]
COGNITIVE DYSFUNCTION IN PATIENTS WITH GLIOMA: RESTING-STATE FMRI STUDY

Hu Xinhua, Liu Yong, Yang Kun, Yang Hua, Zou Yuanjie, Liu Hongyi
 Department of Neurosurgery, Brain Hospital Affiliated to Nanjing Medical University, Nanjing, China

INTRODUCTION - OBJECTIVE: To investigate the brain networks' 'small world' characteristics and evaluate the relationship between neurocognitive dysfunction and functional brain connected network.

METHOD: 13 patients with gliomas (7 males and 6 females) and 20 healthy controls were selected between June 2012 and June 2013. The mean age of patients was 43.7 years (range, 24-76 years). Resting-state functional magnetic resonance imaging (fMRI) was performed. The clustering coefficient, average path length, global efficiency (Eglob) and "small world" index were calculated. All of them underwent 6 neurocognitive function tests (including attention, verbal fluency, memory, sports ability, visual space ability and intelligence).

RESULTS: Compared to healthy controls, patients performed poorer Z scores in attention, verbal fluency, calculation, digit symbol and mapping tests. High Gamma frequency band "small world" index and verbal fluency test results were positively correlated, Alpha frequency band "small world" index and computation and mapping test results were positively correlated in patients with glioma. Interestingly, Eglob was positively correlated with intelligence test scores in both subjects.

CONCLUSIONS: Low Gamma frequency band and high Gamma frequency band small world index and cognitive functions exist widely related. Disappeared High Gamma and low Gamma frequency band resting state function connection network "small world" characteristics is significantly affected the neurocognitive function of patients with glioma. This study also demonstrated that reduced global efficiency for poorer intellectual performance in patients with glioma.

EP-092[Neurooncologic Surgery]
A CASE OF ORBITAL MALT LYMPHOMA

Megumi Takahashi, Hiroaki Namatame, Yutaka Ohtsubo, Satirou Azuma
 Department of Neurosurgery, Tokyo Metropolitan Ohtsuka Hospital

INTRODUCTION - OBJECTIVE: MALT (Mucosa-Associated Lymphoid Tissue) lymphoma is the B cell-lymphoma originated from a type of tissue called mucosa-associated lymphoid tissue (MALT) and occupied only 7-8% of malignant lymphoma.

METHOD: We report a case of orbital MALT lymphoma which diagnosis was confirmed by surgical resection using transcranial-transorbital approach.

RESULTS: A 65-year-old female complained of right exophthalmos and eye movement disorder for 2 months. A MRI scan demonstrated 4cm enhanced mass in the upper-lateral side of right orbit. Immunoglobulin (IgG)4 was not elevated in blood sample. Surgical resection was performed using fronto-temporal craniotomy with orbital roof removal. After tumor resection, orbital roof was built by own bone using titanium mesh. The pathological findings of surgical specimen showed "Lymphoepithelial lesion (LEL)" which demonstrates lymphoma cells infiltration into mucous epithelia, the specific finding of MALT lymphoma. After surgery, oral prednisolone was received for a month and neither radiotherapy nor chemotherapy was done. MRI scan revealed tumor disappearance and her symptoms were improved.

CONCLUSIONS: In this case, tumor resection using transcranial-transorbital approach was very useful to confirm the pathological diagnosis of MALT lymphoma.

EP-093[Neurooncologic Surgery]
ACTIVE SURGICAL TACTICS IN METASTATIC BRAIN TUMORS

Buranbek Djamyrgychievich Diusheev, Nurlan Tolobekovich Kachiev
 Kyrgyzstan, National Hospital, Department of Neurosurgery №1

INTRODUCTION - OBJECTIVE: To improve the results of treatment of patients with metastatic tumors by optimizing diagnostic and treatment tactics.

METHOD: Were examined 73 patients with metastatic tumors. The most common source of metastatic tumor was lung cancer - in 26 cases (35.6%). In 11 cases - breast tumors, 3 Observations thyroid tumor, gastric and melanoma, in 2 cases, the tumor of the kidneys and colon. In 23 (31.5%) patients, the primary source was not identified. Men were 40 (54.7%) aged 50 to 60 years (71%). Women was 33 (45.2%). Patients admitted to hospital with the existing focal neurologic signs, and more (50%) in a state of moderate severity caused by somatic symptoms. 34 (46.6%) patients showed single metastasis in 39 (53.4%) - multiple. 73 patients were operated. In 84% of patients the tumor was removed radically, 12% - subtotal, 4% - partially.

RESULTS: 71.7% patients experienced a significant regression of neurological deficit 19.5% were discharged in satisfactory condition, with the increase of focal neurological symptoms Observed in 8.8% patients. The average life expectancy after surgery to increase life 7.1 ± 1.2 months. In three cases, there was death, that was (4.1%) in these patients has been a multiple nodus brain.

CONCLUSIONS: Active surgical tactics in patients with metastatic brain tumors is the method of choice, allowing to overcome the "therapeutic nihilism" that existed earlier in these patients.

EP-094[Neurooncologic Surgery]
FORAMEN MAGNUM MENINGIOMA

Suresh Nair Narayanan Nair
 Sree Chitra Tirunal Institute for Medical Sciences & Technology, Trivandrum, India

INTRODUCTION - OBJECTIVE: A retrospective analysis of 32 cases of foramen magnum meningioma surgically managed in this institute for nearly 23 consecutive years from Jan 1990 to November 2012 was carried out to study the surgical outcome

METHOD: Twenty four females and eight males ranging in age between 18 to 70 years were diagnosed following mean symptom duration of 30 months. The choice of surgical technique was guided by the tumour location in the horizontal plane (anterior-7, ant lateral-19, dorsal-4, and posterolateral 2), the location of vertebral artery (above, below or traversing through the tumour) and relationship of the tumour to dura (intradural or intra / extradural). While 12 of the lateral meningiomas were approached through the posterior approach, 7 were tackled by postero-lateral route. Six anterior meningiomas were also operated by postero-lateral approach. One patient of anterior meningioma was operated through the posterior route from either side.

RESULTS: While a radical resection could be carried out in 29, two patients with extradural extension had only subtotal removal. There were two operative mortality. Four other patients required prolonged postoperative ventilatory support. One patient underwent revision surgery for symptomatic recurrence. At short term follow-up twenty patients did not have any deficit, six moderately disabled and three severely disabled (all improving from preoperative dense quadriplegia). One patient was not available for follow-up.

CONCLUSIONS: Foramen magnum meningiomas can be radically removed in most cases using an appropriate technique which should be chosen after precise location of the tumour.

EP-096[Neurooncologic Surgery]
CAVERNOUS SINUS SURGERY- SERVING THE 'BOSS (BASE OF SKULL SURGERY)'

Atul Goel
 Seth G.S. Medical College and K.E.M Hospital, Parel, Mumbai, India

INTRODUCTION - OBJECTIVE: The progressive refinements of imaging techniques have helped neurosurgeons delineate pathologies close to the skull base, an arena wherein, so far, even angels feared to tread. The past two decades have been marked by a global, concerted effort to confront these pressing problems by the healing knife. Base of Skull Surgery- BOSS- has come of age as a super-specialty that must turn safer and easier as the years roll by.

METHOD: The crowding of structures on either side of sella turcica and sphenoid sinus has forced anatomists into describing cavernous sinus as an area through which cranial nerves and carotid artery course. A little embryological retrospection will clarify the issue for us. The cranial nerves have a well defined dural and arachnoid covering in their course along the cavernous sinus which keeps them isolated from direct contact with the venous blood.

RESULTS: The site of the origin of the lesion, and its nature, determine the extensions and displacements in the cavernous sinus. The direction of approach holds the key to successful resection of the lesions involving the cavernous sinus.

CONCLUSIONS: The BOSSist, working or in the making, has to be most Hippocratic- Primum, non nocere. Towards this end, it is important that a BOSSist appreciates the epigenetic sequence that fashions all the blood vessels, nerves, and meninges first and then the skull base, as an afterthought later. Hands-on experience would reveal these concepts to be verifiable realities that can be put to the advantage of the patient and the ease of the surgeon.

EP-097[Neurooncologic Surgery]

CEREBELLAR HEMORRHAGE AFTER RESECTION OF
FRONTAL MENINGIOMA. CASE REPORT

Melih Üçer, İlhan Aydın, Sarper Polat, Abdullah Emre Taçyıldız
Bakirköy Research & Training Hospital for Psychiatry, Neurology and Neurosurgery

INTRODUCTION - OBJECTIVE: Remote cerebellar hemorrhage is an infrequent complication, potentially harmful with an unclear etiologic mechanism. There may be incriminated multiple risk factors: arterial hypertension, use of antiplatelet medication, CSF aspiration or drainage associated with intracranial hypotension.

METHOD: We present a 69 year old woman with remote intracerebral hemorrhage that occurred after frontal parasagittal meningioma resection.

RESULTS: An inadequate oral hydration was responsible for decreased level of consciousness, cerebellar and parietaloccipital cortical-sub-cortical contra-lateral hemorrhages. Close monitoring of water balance and adequate hydration is related to clinical improvement and resolution of brain imaging.

CONCLUSIONS: Retraction of the brain due to intracranial hypotension led to some small vessels rupture and development of remote cerebellar hemorrhage.

EP-098[Neurooncologic Surgery]

MID-TERM SURGICAL TREATMENT OUTCOMES OF INTRACRANIAL
EPIDERMOID: EXPERIENCE OF 15 PATIENTS

Anas Abdallah, Erhan Emel, Betül Güler, Akın Öztürk, Mustafa Levent Uysal, Melih Üçer, Murad Asiltürk, Hasan Burak Gündüz, Müslüm Güneş, Özden Erhan Sofuoğlu
Bakirköy Research and Training Hospital for Neurology Neurosurgery, and Psychiatry, Department of Neurosurgery, Istanbul, Turkey

INTRODUCTION - OBJECTIVE: Epidermoids are uncommon lesions of the central nervous system. The cerebellopontine angle (CPA) is the most common site of occurrence of intracranial epidermoids that account for 9% of tumours in the CPA second only to acoustic neuromas. In this study mid-term surgical treatment outcomes of our 15 patients of intracranial epidermoid cysts have been evaluated.

METHOD: Medical records were retrospectively reviewed in 15 (7 women, 8 men) patients of cerebral tumors who operated between the years 2009 and 2013, and the cases which confirmed as epidermoid cysts pathologically were obtained in this study. The mean age was 39.2 years (5-59yr). The mean follow-up period was 32 months. The mid-term clinical outcomes were evaluated retrospectively.

RESULTS: The most common complaints were headache (86.6%). Seven (R:3, L:5) "53%" cases were sited in CPA, three cases in midline posterior fossa "20%", 3 (R:2, L:1) "20%" cases in the temporal lobe, and one case was sited in right frontal lobe (in olfactory groove) "7%". Two patients (13.3%) showed recurrence; but totally 6 patients had been undergone surgery previously. The mean of the time between the first complaint and surgery was 25.95 months (20 days- 60 months). 10 patients had been managed successfully and Gross-total resection was achieved, while subtotal resection in 5 patients (almostly because of the premature termination of resection to protect main functional sites in the brain).

CONCLUSIONS: To reduce the recurrence of cranial epidermoid cysts, total excision of tumor mass should be done. Our mortality rate was 13.3% and was seen in two patients with recurrence.

EP-099[Neurotrauma and Intensive Care]

TRAUMATIC INTRA VENTRICULAR HEMORRHAGE IN SEVERE
BLUNT HEAD TRAUMA ONE YEAR ANALYSIS

Gholamreza Bahadorkhan
Department of Neurosurgery, Mashhad University of Medical Sciences Mashhad Iran

INTRODUCTION - OBJECTIVE: Out of 904 patients with severe closed head injury that were admitted in NSICU 31 patients with intraventricular hemorrhage (GCS less than 8) are reported herein and the mechanism involved are discussed. Nine cases had intracerebral hemorrhages (contusional group) four cases in the frontal lobe, 3 cases in the temporal lobe and two cases in parietal lobe. 9 cases (basal ganglia hemorrhage group) had hemorrhages in basal ganglia, 6 in caudate nucleus and 3 in thalamus, all spreading into the ventricles. In 13 cases the original site of hemorrhage could not be determined.

METHOD: Although different speculations have been proposed (2), incidence of IVH in non penetrating head injury is 1.5 to 3% and 10 to 25% of patients with severe head injury (GCS less than 8) have IVH (3-6). The presence of IVH indicates a severe force has been applied to the head and generally is a sign of severe head injury (2, 3).

RESULTS: In this one year prospective study (March 2001-2002) 1117 cases of severe head injuries (with a GCS less than 8) were admitted to Neuro Surgical Intensive Care Unit (NSICU) of Kamyab Hospital, the main trauma center in Mashhad, Iran. 31 cases of a total 904 patients (3.4%) had IVH with or without concomitant CT abnormalities and without extra cranial lesions.

CONCLUSIONS: Posttraumatic IVH is relatively rare but a recognized clinical entity. Severity and direction of application of force and other associated abnormalities are major determining factors in extent of hemorrhage.

EP-100[Neurotrauma and Intensive Care]

DISTANT CONSEQUENCES OF LIGHT CRANIAL-CEREBRAL INJURIES DEPENDENCE
FROM CLINICAL SIGNS AND METHODS OF TREATMENT IN ACUTE PERIOD

Najmiddin Norkulov Uralovich¹, Amirqul Shodiev Shodiech¹, Sirojiddin Norkulov Najmiddinovich¹, Kamola Ikramova Shuhratovna²

¹Department of Neurosurgery, Medical Institute, Samarkand, Uzbekistan

²Department of Foreign Philology, academic lyceum #1, Samarkand, Uzbekistan

INTRODUCTION - OBJECTIVE: The purpose of investigation is to study dependence of distant consequences of light cranial-cerebral injuries (CCI) from clinical symptoms and treatment methods with nootropes in acute period. 60 patients (aged from 5 months to 66 years) from them composed clinical group: 30 patients got traditional treatment, which included nootropes (1 group), the rest 30 patients got traditional treatment (Control group).

METHOD: We have performed examination with the use of special informative and catamnestic charts, datas of ophthalmological, otoneurological, rentgenological, echo-encephalological, electroencephalographical, computer tomographic investigations datas, also we have used Shultes table and the remembering of 10 words.

RESULTS: On the base of that information we have evaluated patients condition and CCI consequences evaluation of patients efficacy. Efficacy evaluation of a patient with mild form of CCI in dependence from, clinical symptoms and treatment with nootropes has showed that although on Jennets and Bonds (1975). 1) Recovery on 30% in first group and 26,6% in a second group; 2) Functions restoration fill compensative condition - 66,6 % in first and 60 % in a second group; 3) Moderate neurologic breaches - in 3,3 % in first group and 13,3 % in second group 3 years after CCI.

CONCLUSIONS: In conclusion, we have established direct dependence between mild CCI consequences and nootropes treatment in acute period, and by this way reduce moderate neurologic breaches 3 times.

EP-101[Neurotrauma and Intensive Care]

THE FEATURES OF THE NEUROPHYSIOLOGICAL PARAMETERS AT
APALIC SYNDROME OF THE TRAUMATIC ETHIOLOGY

Jaloliddin BOboev, Usmonov Laziz
Neurosurgical research center, Tashkent, Uzbekistan

INTRODUCTION - OBJECTIVE: Comparison of the clinical data and parameters EEG at patients with apallic syndrome (AS) of the traumatic etiology is lead.

METHOD: 46 patients with the AS, taking place in RSCNS with 2005 on 2013 years are surveyed. The age of patients has made from 6 till 46 years. Duration coma at all patients proceeded or till 26 day, in the subsequent passed in the AS.

RESULTS: The main attribute of transition from coma to the AS was alternation of an awakesness and a dream at absence of consciousness, disintegration cognitive functions at safety of function of a trunk. Duration the AS in our supervision was about one year; 12 patients have died; at 4 patients the acinetical mutism is developed and in 11 cases the output from the AS with the psychoneurological deficiency, characteristic for dementia was marked. Monitoring of the basic of the EEG parameters at the AS has shown heterogeneity of these parameters and distinction of dynamics at different forms the AS: a) the complete AS; 6) the incomplete AS, with development of the massive psychoneurological deficiency; b) the incomplete AS, with an output in a stage of defect with an opportunity of social adaptation.

CONCLUSIONS: Thus, the estimation of an outcome the AS can be lead at the analysis of the EEG methods spent for dynamics.

EP-102[Neurotrauma and Intensive Care] CIRCULATING CD34+CD45+ CELLS WITH PREDICTIVE VALUE FOR TRAUMATIC BRAIN INJURY OUTCOME AND POTENTIAL TO IMPROVE PROGNOSTIC POWER OF CRASH MODEL

Vadim Chernykh¹, Natalia Pronkina², Ekaterina Shevela², Vjacheslav Stupak¹, Vjacheslav Phonin¹, Elena Chernykh², Oleg Parluk¹, Samuil Rabinovich¹, Alexandr Ostanin²

¹Novosibirsk Research Institute of Traumatology and Orthopaedics n.a. Ya.L. Tsivyan, Novosibirsk, Russia

²Novosibirsk Research Institute of Clinical Immunology, Novosibirsk, Russia

INTRODUCTION - OBJECTIVE: to determine whether circulating CD34+CD45+ cells have predictive value in traumatic brain injury (TBI) outcome and may improve the prognostic power of the CRASH model.

METHOD: 88 TBI patients (73 males and 15 females) with contusions or brain compression (Glasgow Coma Scale <15) from two neurosurgical centers participated in the current study. All patients underwent neurological and CT evaluation. TBI severity and outcomes were assessed using Glasgow Coma Scale and Glasgow Outcome Scale. The level of HP was assessed within 1-3 days by flow cytometry. Risks of 14-day mortality and unfavorable outcome at 6 mo were determined with the use of CRASH calculator (www.crash2.lshtm.ac.uk).

RESULTS: Utilization of ROC analysis demonstrated high prognostic value of CRASH model. The area under the ROC curve (AUC) for the risk of 14-day mortality was 0.76 (sensitivity 70, specificity 70.6%) and for the risk of unfavorable outcome at 6 mo - 0.85 (sensitivity 73, specificity 79.5%). The number of HP <3100 cells/ml allowed to predict an unfavorable outcome at hospital discharge with specificity of 96% and sensitivity of 71% (AUC 0.8), and the number of HP <1900 cells/ml predicted unfavorable outcome at 6 mo with specificity of 80% and sensitivity of 67% (AUC 0.75). The combination of two models resulted in decrease of type II errors from 25 to 5%.

CONCLUSIONS: Circulating HPs can be used as a monopredictor of TBI outcome and improve predictive value of CRASH for the risk of unfavorable outcome at 6 months.

EP-103[Neurotrauma and Intensive Care] RESULTS OF SURGICAL TREATMENT OF TRAUMATIC INTRACRANIAL HAEMORRHAGES IN ELDERLY PATIENTS

Ibrohim Eshmuhamadovich Soyibov, Marat Jumabekovich Mirzabaev
Department of urgent neurosurgery, Republic Neurosurgical Research Center

INTRODUCTION - OBJECTIVE: At elderly persons by the anatomico-physiological features of an organism the brain injury proceeds originally, due to age changes from a brain and its vessels.

METHOD: There were analyzed the results of investigations and treatments of 85 elderly patients with the heavy craniocerebral trauma.

RESULTS: In the neurologic status there were prevailed common cerebral symptoms on 82 (99.7 %) patients and mental infringements on 61 (71.8 %) patients. Dislocation syndrome was identified only at 8 (9.4 %) patients. Consciousness disturbances to 12-14 by Glasgow Coma Scale at 47 (55.3 %) patients and to 10-11 at 16 (18.8 %) cases was marked. At 48 (56.5 %) patients on computed tomography scans revealed subdural hematoma; in 24 (28.2 %) cases was revealed the epidural hematoma; in the others 13 (15.3 %) the intracerebral hematoma is detected. Due to methods of treatment and time data of the lead operative intervention, the patients were divided into 3 groups. 1-group: 12 (14.1 %) the patients were made wide decompressive craniectomy with removal of a hematoma in the acute period of a trauma. Mortality in 10 cases. 2-group: 54 (63.5 %) were established drainage systems with carrying out a local fibrinolysis at sub acute stage. Mortality in 4 cases. 3 - group: 19 (22.4 %) patients were led only conservative treatment. Mortality in 2 cases.

CONCLUSIONS: Surgical treatment of traumatic intracranial hemorrhages in elderly patients is more preferential, to perform operative interventions at the sub acute period of a trauma and minimal invasive methods.

EP-104[Neurotrauma and Intensive Care] ADDITION TO TREATMENT TACTICS OF POSTERIOR CRANIAL FOSSA INJURY

Jaloliddin BOboev, Laziz Usmonov
department of Urgent Neurosurgery, Republic Neurosurgical Research Center

INTRODUCTION - OBJECTIVE: Posterior cranial fossa (PCF) injury is rough and rare type of brain injuries. Statistically, PCF injuries share 0,01-0,3% of brain injuries.

METHOD: We have analyzed the correlation of injury extension and treatment options of 42 patients with PCF injuries.

RESULTS: The injury extension determined secondary intracranial complications (brain's dislocation, hydrocephaly). Among 24 operated patients average injury extension was 53,4-26,5 cm³, in the group of 18 nonoperative patients extension was 7,1-6,2 cm³. In group of patients with epidural haematomas of PCF less than 15 cm³ all of them were treated conservatively; all the patients with haematomas greater than 31 cm³ were operated. In the group of patients with injury extension less than 30 cm³ and greater than 16 cm³ has been used both operative and nonoperative options. Minimally volume of epidural haematomas underwent operation made 25 cm³, maximum volume of haematomas in the conservative group made 16 cm³. The average volume of cerebellar haematomas of patients that have taken nonoperative treatment made 9,0-5,2 cm³.

CONCLUSIONS: 1. Patients with epidural haematomas less than 15 cm³ and cerebellar contusion less than 9 cm³ don't need surgery. 2. For the patients with epidural haematomas greater than 25 cm³ and intracerebellar contusion greater than 20 cm³ surgery is obligatory. 3. For the patients with epidural haematomas greater than 11 and less than 25 cm³ and cerebellar contusion greater than 9 and less than 20 cm³ alternative factors to be concerned.

EP-105[Neurotrauma and Intensive Care] EARLY DECOMPRESSIVE CRANIECTOMY FOR THE TREATMENT OF SECONDARY BRAIN DAMAGE IN PATIENTS WITH TRAUMATIC INTRACRANIAL HEMATOMAS

Jamshid Kuzibaev, Kozim Makhkamov

Neurosurgery department of Republican Research Center of emergency medicine, Tashkent, Uzbekistan

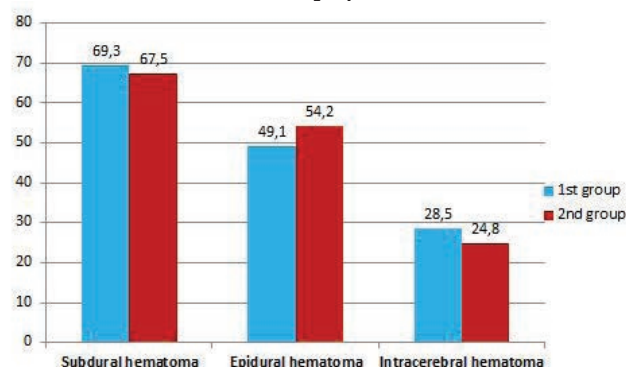
INTRODUCTION - OBJECTIVE: Traumatic intracranial hematomas represent a challenge for neurosurgeons due to their high mortality and morbidity. Secondary brain damage is an important factor that influences the outcome of traumatic intracranial hematomas. We compared the effect of early decompressive craniectomy with that of non-decompressive craniectomy on the outcome of patients with secondary brain damage following severe traumatic brain injury.

METHOD: A retrospective review was conducted of 127 consecutive patients who presented with secondary brain damage following isolated severe head injury with intracranial hematomas. Early decompressive craniectomy after hematoma removal (mean time from injury: 5.8±2.5 h) was carried out in 82 patients (mean age: 45.7±5.6 years), whereas 45 patients (mean age: 43.4±4.1 years) were underwent only hematoma removal without decompressive craniectomy (mean time from injury: 6.1±3.1 h). All patients in two groups were comparable due to the level of consciousness of patients, volume and localization of hematoma, severity of secondary brain injury and axial dislocation of middle brain structures.

RESULTS: Due to postoperative CT results volume of secondary brain injury zone was reduced 2.4 times more in patients who underwent early decompressive craniectomy compared with the patients without decompressive craniectomy. Axial dislocation of middle brain structures was decreased from 11.4±3.7 mm to 1.8±0.8 mm in the early decompressive craniectomy group, and from 8.9±4.5 mm to 4.4±2.5 mm in non-decompressive craniectomy group.

CONCLUSIONS: Early decompressive craniectomy, employed prior to the onset of irreversible ischemic changes, may be an effective method of treating the secondary deterioration from secondary brain damage following severe head injury with intracranial hematomas.

Localization of hematomas in the 1st and 2nd groups



The patients in two groups were comparable due to the localization of hematomas.

Comparison of variables in the 1st and 2nd groups

Variables	1st group	2nd group
Male/Female ratio	44/38	26/19
Average age	45.7±5.6	43.4±4.1
Admission GCS score	8.2±2.1	8.8±1.8
Volume of hematoma	62.8±10.4	58.4±12.1
Volume of secondary brain injury	35.2±5.7	38.3±4.9
Dislocation of middle brain structures	11.4±3.7	8.9±4.5

All patients in two groups were comparable due to the gender of patients, the mean age, the level of consciousness of patients, volume and localization of hematoma, severity of secondary brain injury and axial dislocation of middle brain structures

Repeat CT images after early decompressive craniectomy and removal of left acute subdural hematoma, showing regression of midline shift

EP-106[Neurotrauma and Intensive Care] PREDICTING OF PROGRESSIVE SECONDARY BRAIN DAMAGE FOLLOWING TRAUMATIC INTRACRANIAL HEMORRHAGE

Jamshid Kuzibaev, Kozim Makhkamov

Neurosurgery department of Republican Research Center of emergency medicine, Tashkent, Uzbekistan

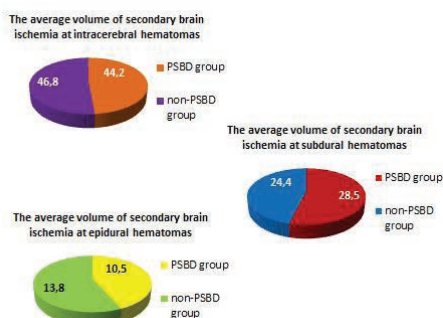
INTRODUCTION - OBJECTIVE: Traumatic intracranial hemorrhage (TIH) represents a challenge for neurosurgeons due to its high mortality and morbidity rates. The most severe lesion associated with TIH is secondary brain damage. Thus, the purpose was to investigate the CT parameters for predicting of PSBD associated with TIH.

METHOD: We reviewed the records of 252 patients suffering from TIH whose first CT scan was Obtained within 24 h of the injury. The repeat CT examinations were routinely Obtained within 24 h of admission as well as when suggested by clinical worsening. The patients were divided into two groups: PSBD group (124 patients) and non- PSBD group (128 patients). All patients in two groups were comparable due to the level of consciousness and ages of patients and severity of secondary brain injury.

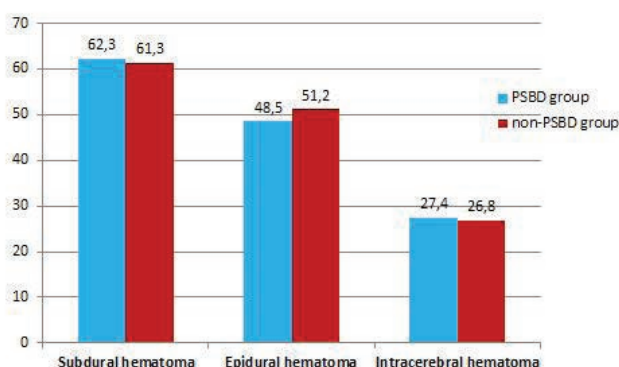
RESULTS: The differences between PSBD and non- PSBD were significant in the initial CT scans showing type, volume and location of TIH, brain swelling and midline shift as well as the associated brain contusion ($P < 0.01$). Logistic regression analysis showed that early predictors of PSBD were: intracerebral type of hemorrhage, temporal localization of hematoma, volume of hematoma more than 40 cm³, midline shift more than 5mm, brain swelling and contusion volume more than 20 cm³ ($P < 0.01$).

CONCLUSIONS: Thus, if the initial CT scan of patients with TIH shows intracerebral hemorrhage, temporal localization of hematoma, volume of hematoma more than 40 cm³, midline shift more than 5mm, brain swelling and contusion volume more than 20 cm³, an earlier CT scan should be performed for detection of PSBD.

Initial CT images, demonstrating left acute subdural hematoma with midline shift to the right. The average volume of secondary brain ischemia at different traumatic intracranial hematomas in PSBD and non-PSBD groups



The average volume of traumatic intracranial hematomas in PSBD and non-PSBD groups



All patients in two groups were comparable due to the average volume of subdural, epidural and intracerebral hematomas.

Clinical variables related to the progression of secondary brain damage

Clinical variable	PSBD group	non-PSBD group
Intracerebral hemorrhage	48 (38.7)	25 (19.5)
Temporal hematoma	79 (63.7)	24 (18.7)
Volume of hematoma more than 40 cm ³	88 (70.9)	46 (35.9)
Midline shift more than 5mm	45 (36.3)	21 (16.4)
Brain swelling and contusion volume more than 20 cm ³	56 (45.1)	23 (17.9)

The difference of the results were significant at $P < 0.01$. Values within parentheses are percentages.

EP-107[Neurotrauma and Intensive Care] CORRECTION OF HOMEOSTASIS DISORDERS AFTER HIASM-SELLAR REGION TUMORS REMOVAL

Ilya Denisov, Vsevolod Luchansky

Faculty of General Medicine, Novosibirsk State Medical University, Novosibirsk, Russia

INTRODUCTION - OBJECTIVE: -Analysis of homeostasis dysfunction in patients after hiasm-sellar region (HSR) tumors removal; -Assessment of current diencephalic syndrome dysfunction; -Optimization of intensive therapy in this group of patients.

METHOD: 79 case histories of intensive therapy unit patients after HSR tumors removal were analyzed. Neurological status, vital functions, water-electrolyte balance compensation and necessity of substitution therapy evaluation was performed.

RESULTS: The main syndromes were water-electrolyte disorders, diabetes insipidus, consciousness disorders, respiratory dysfunction, cardiovascular dysfunction and adrenal insufficiency. Three cases of generalized edema syndrome, one of intestinal dysfunction were occurred. Correction of the manifestations of panhypopituitarism consists of the hormonal replacement therapy, infusion program, inotropic support. All of the 5 patients were discharged from hospital with significant clinical improvement.

CONCLUSIONS: The most serious complication of the postoperative period is polyhormonal deficiency. It develops immediately after the operation and reaches its peak on the third day. Stabilization of homeostasis comes on the 5th day in the ICU. Principles of optimal therapy are: control of water-electrolyte homeostasis, hormonal background; use of hydrocortisone during the operation in doses of 1 to 3 mg/kg; control of diuresis, electrolytes in plasma and urine, evaluation and correction of the volumic status; substitution therapy with the optimal doses of hydrocortisone, L-thyroxine, vasopressin; immediate correction of arterial hypotension - normovolemia, sympathomimetics; early start of enteral nutrition. Adequate selection of therapy and complications prophylaxis in most cases allows achieving compensation of water-electrolyte and neuroendocrine disorders.

EP-108[Neurotrauma and Intensive Care] THE SPECIFICITY OF CEREBRAL BLOOD CIRCULATION IN THE CRITIC PERIOD AT SENIOR AGED PEOPLE WITH THE COMBINED CRANIAL-BRAIN TRAUMA

Batirbay Umirserigov¹, Marat Mirzabayev²

¹Department of polyclinic, Republican scientific centre of neurosurgery, Tashkent, Uzbekistan

²Department of neurooncology, Republican scientific centre of neurosurgery, Tashkent, Uzbekistan

INTRODUCTION - OBJECTIVE: Nowadays the problems of amount and sequence of surgical intervention to senior people suffering from traumatic shock have not been decided. There has been hold the investigation of cerebral blood circulation of 54 senior citizens at our hospital, study of bioelectrical dynamics and functional activity of brain, central and peripheral haemodynamics, their age and attendant status were taken into consideration. The initial cerebral bleeding was stipulated by mechanical brain injury, vascular and liquor problems. Secondary cerebral bleeding appeared at haemodynamic and haemic dysfunctions of big and small circles of blood circulation at local and diffusional oxygen starvation, infarction, shock and others.

METHOD: Brain injury has become the most widely spread form at combined traumas (66,1 %). People suffering from this type of trauma were characterized by typical change of central haemodynamics with different pathological variants of circulation. Brain bruises were diagnosed at 28% of patients. Clinical situation at serious brain traumas and late diagnostics led to the appearance of syndrome of "mutual aggravation" at combined traumas.

RESULTS: The squeezing of brain was registered at 4,8 % of patients. The reasons of them were subdural and epidural haematomas. By the end of the critical period they grew. The correction of cerebral bleeding in the critical period of traumatic disease was connected with the traditional surgical tactics of compression liquidation, brain dislocation at squeezing and holding early osteosynthesis.

CONCLUSIONS: Early diagnostics and shock therapy of trauma at combined cranial-brain traumas of old-aged patients were one of the basic principles of rational treatment of cerebral bleeding.

EP-109[Neurotrauma and Intensive Care] MONITORING OF THE BRAIN BLOOD STREAM IN PATIENTS WITH THE CRANIOCEREBRAL TRAUMA

Andrey Afanasevich Kim, Nurjan Turabekov
Urgent Neurosurgery department, Republic Neurosurgery Research Center

INTRODUCTION - OBJECTIVE: The purpose of research - investigation of the brain blood stream in patients with the craniocerebral trauma.

METHOD: 37 patients with craniocerebral trauma (28 men and 9 women) in the age of 23-55 years, in the Republican scientific centre of neurosurgery are surveyed.

RESULTS: Depending on a degree of a brain bruise all patients are divided into 3 groups: in patients of 1 group the increase of linear speed of blood-groove (LSB) in all basal arteries was moderately - diffuse and has made 100-110 sm/sec, attributes of angiospasm have been less expressed; in patients of 2-nd group was marked diffuse increase of LSB which in the first day made 180 sm/sec; in patients with severe degree of brain bruise change of cerebral blood-groove specified as expressed and critical, LSB has made 180-210 sm/sec. It is necessary to take into account, that in a basis of LSB increase rise may be uncontrollable intracranial pressure which is the vasospasm reason and compensator hyperperfusion. Also falling peripheral resistance in microcirculate bed. In 8 patients asymmetry of LSB with its prevalence on the party of defeat (an intracranial hematoma) owing to a unilateral ischemia of brain hemisphere that proved to be true neurologic semiology was marked.

CONCLUSIONS: Thus, change of LSB can to predict the further angiospasm expressiveness and to predict secondary ischemic processes and outcome of intracranial trauma.

EP-111[Neurotrauma and Intensive Care] DECOMPRESSIVE CRANIOTOMY FOR TRAUMATIC NON MISSILE ACUTE SUBDURAL HAEMATOMA

Waleed Abbass Ahmed
Departement of neurosurgery,cairo university,cairo,Egypt

INTRODUCTION - OBJECTIVE: Acute subdural haematoma is the most lethal of all head injuries, it occurs in 10-20% of traumatic brain injury and counts for 30% of fatal injuries.

METHOD: Study included 21 cases, 15 males and 6 females with age ranging from 7 to 59 years. Inclusion criteria: Glasgow coma scale 11 and below. 7 cases with Glasgow coma scale 11, 2 cases with scale 10, 1 case with scale 9, 1 case with scale 8, 3 cases with scale 7, 4 cases with scale 6, 2 cases with scale 5 and 1 case with scale 4. Exclusion criteria: patients with Glasgow coma scale above 11 and patients with scale 3. Computed tomography showed acute subdural haematoma with mid line shift. All cases were operated upon by large decompressive craniotomy, opening the dura in snips, evacuation of the haematoma by irrigation and then wide closure of the dura by pericranium or fascia lata. Bone flap is removed and was put in bone bank until the patient recovered and then it is returned back.

RESULTS: Within 6 months from the injury 2 patients developed hydrocephalus and needed ventriculoperitoneal shunt. 4 patients developed deep venous thrombosis. 2 patients developed diabetes insipidus. 3 patients died due to associated injuries. 3 patients died due to severe deterioration of the conscious level at the time of presentation. 2 patients became vegetative. 8 patients recovered fully conscious with no neurological deficit. 3 cases recovered with various types of neurological deficits in the form of aphasia and hemiparesis.

CONCLUSIONS: Early diagnosis, rapid transfer, age of the patient and rapid surgical treatment of acute subdural haematoma with decompressive craniotomy decreases the morbidity and mortality.

EP-112[Neurotrauma and Intensive Care] PITFALLS AND RISK MANAGEMENT OF HEAD INJURY CARE IN EMERGENCY ROOM IN KOREA

Dong Ho Kim, Young Seok Park, Kyung Soo Min, Mou Seop Lee, Young Gyu Kim
Department of Neurosurgery, Chungbuk National University, Cheongju, Korea

INTRODUCTION - OBJECTIVE: When managing head injury at emergency room we can face a large pitfall. So we need to protect ourselves against medico-legal problems. We would like to discuss about some problems both clinical and medico-legal that may arise when managing head injury especially at emergency room in Korea. It is important to appreciate that patients who have sustained head injuries are often the subject of medico-legal action or malpractice litigation.

METHOD: In Korea, with formed social consensus on promoted demand of emergency medical care, emergency medicine was approved as a special major. Before 1995, Primary care for head injury was performed by NS residents. After 1995, it was replaced by residents of EM or Emergency physician. For risk identification and risk analysis, We would like to present some cases of medical errors that occurred during head injury care at ER in Korea including our hospital. And then will discuss on risk control for that.

RESULTS: Concerning head injury care, one of the most common error is medico-legal problem due to delayed or expanding ICH. Oral anticoagulant therapy is important risk factor for unfavorable outcome in head injury. All head injuries are considered to have a CSI until proven otherwise and have potentially huge medico-legal liability. Scalp has richest subcutaneous vascular supply and bleeding from scalp can result in shock.

CONCLUSIONS: In Korea, we have an increasing tendency of medico-legal problems on head injury care at ER. Neurosurgeon and Emergency physician should enhance team experience on teamwork and performance in emergency care of head injury.

EP-113[Neurotrauma and Intensive Care] INTRADURAL MELANOCYTIC SCHWANNOMA AT SACRAL SPINE

Mou Seop Lee

Department of Neurosurgery, Chungbuk National University Hospital, Cheongju, Chungbuk, South Korea
INTRODUCTION - OBJECTIVE: Melanocytic schwannomas are part of a spectrum of central nervous system melanocytic tumors that commonly are associated with the leptomeninges. Spinal melanocytic schwannomas are variants that can be extradural or intradural, and are typically considered benign. The spinal melanocytic schwannomas are rare lesion, and they are usually intradural and extramedullary, but can be either extradural or intramedullary. The dark pigmentation of the tumor cells arising from the cytoplasmic melanin is a hall mark of this lesion.

METHOD: The author report a case of a 68-year-old woman presented with low back pain and radiating pain into the left thigh and calf. The lumbar-MR image revealed the presence of intradural lesion in a sacral 2-3 level with combined ruptured intervertebral disc in lumbar 4-5 level.

RESULTS: The lesion in a sacral level was gross totally removed. The resection was done with some difficulty due to tumor infiltration into sacral bone and poor surgical plane for dissection. Histopathological examination of the resected lesion was compatible with melanocytic schwannoma.

CONCLUSIONS: We report an unusual case of a melanocytic schwannoma at sacral spine. In reviewed literatures, reported case that melanocytic schwannomas at sacral spine are very rare.

EP-114[Neurotrauma and Intensive Care] PHARMACOGENOMIC EFFECTS OF APOLIPROTEIN E ON COG1410 IMPROVES OUTCOMES AT EARLY STAGE AFTER CONTROLLED CORTICAL IMPACT IN MICE

Yong Jiang¹, Jieshi Liu¹, Ligang Chen¹, Xiaochuan Sun²

¹Department of Neurosurgery, the Affiliated Hospital of Luzhou Medical College, Luzhou, P.R. China

²Department of Neurosurgery, the First Affiliated Hospital of Chongqing Medical University, Chongqing 400016, P.R. China

INTRODUCTION - OBJECTIVE: Traumatic brain injury (TBI) is a common severe neurosurgery disease. The relationship between APOE genotype and COG1410's neuroprotective effect is still controversial. The current study was to investigate the effect of different APOE isoforms and the feasibility of administering COG1410 to improve outcomes at early stage on TBI.

METHOD: TBI model was established by PSI head injury impactor precision strike in APOE targeted-replacement mice (APOE33TR, APOE44TR) and APOE knockout mice. Mice were randomly to receive either vehicle or COG1410. Outcomes included functional neurological tests (Rotarod latency) over the initial 7 days after injury, cerebral edema and quantitative amyloid precursor protein (APP)-immunoreactive axonal varicosities in the pericontusional corpus callosum and external capsule at 1, 3 and 7 days.

RESULTS: APOE33TR mice demonstrated superior rotarod latencies over the first 3 days after controlled cortical impact, decreased cerebral edema and APP levels at 24 hours when compared to APOE44TR mice counterparts. After intravenous administration of 1 mg/kg COG1410, compared to mice that receive vehicle, APOE33TR mice exhibited improved rotarod latencies at 4-7 days after injury ($P < 0.05$), decreased cerebral edema at 3d and 7d ($P < 0.05$). While APOE44TR mice exhibited improved rotarod latencies over 7d after injury ($P < 0.05$), decreased cerebral edema at 1d, 3d and 7d ($P < 0.05$). Moreover, APOE33TR mice suppressed APP levels at 1d, 3d and 7d after injury ($P < 0.05$), instead of APOE44TR mice.

CONCLUSIONS: Our data demonstrate that apoE mimetic (COG1410) peptide improves outcome, reduced some of cardinal pathological changes at early stage after controlled cortical impact in both APOE33TR and APOE44TR mice.

EP-115[Neurotrauma and Intensive Care] IN-HOSPITAL AND ONE YEAR OUTCOME OF 1281 SEVERE TBI PATIENTS FROM INDIA: A SINGLE CENTER STUDY

Deepak Agrawal, V.K. Kamal, Rm Pandey
All India Institute of Medical Sciences

INTRODUCTION - OBJECTIVE: To assess the In-hospital mortality and 6 month Outcome of patients with severe TBI managed at a single institution in India

METHOD: This prospective study was carried out at a level I trauma center in New Delhi over a 26 month period. Clinical and radiological records of consecutive patients of severe TBI (GCS ≤ 8) were analyzed. Outcome assessment was done by assessing In-hospital mortality. 12 month outcome was assessed using GOS. A GOS 1-3 was considered as 'Unfavorable' outcome and GOS 4-5 was considered as 'favorable' outcome.

RESULTS: A total of 1281 patients were enrolled in the study. There were 1114 (87%) males. The overall mortality was 38.56% (n=494). Of the 523 patients with motor score of 5, 81 (14.65%) expired. The mortality was 29.38% (n=57) in patients with motor score of 4; 39.05% (n=41) in patients with motor score of 3; 63.53% (n=169) in patients with motor score of 2 and 91.19% (145) in patients with motor score of 1. Overall, 71.54% (n=646) had unfavorable outcome at 6 months. Unfavorable outcome was 39.94% (n=125) in patients with motor score of 5, 71.43% (n=95) in patients with motor score of 4, 85.71% (n=60) in patients with motor score of 3, 93.45% (n=214) in patients with motor score of 2 and 96.79% (n=151) in patients with motor score of 1.

CONCLUSIONS: This is the largest single center study of its kind from the Indian subcontinent and shows that large number of severe TBI (28.45% in our study) had favorable outcome at 12 months.

EP-116[Neurotrauma and Intensive Care] ELECTRONIC MONITORING OF HAND HYGIENE COMPLIANCE IN AN INPATIENT HOSPITAL SETTING USING KINECT CAMERA

Deepak Agrawal
All India Institute of Medical Sciences

INTRODUCTION - OBJECTIVE: This study will focus on the electronic measurement of hand hygiene activities of all individuals that either work or visit the neurosurgical ward. **Aim & OBJECTIVES:** Create a 3-dimensional virtual screen where the doctor's "hand washing activity" is depicted as captured by the "Kinect" sensor.

METHOD: The study was done at neurosurgery intensive care unit (NICU) at JPNATC, AIIMS. Nurses/doctors from NICU recruited to participate in the study after taking appropriate informed consent. The Kinect camera has a resolution of 640 X 480 pixels and can track the user's arm, leg and finger movements. The camera was placed strategically so as to cover whole areas such as ICU's (Intensive care units) and all events such as the number of times a particular healthcare professional hand washed were recorded. Data collected throughout the day in the NICU. From the collected data methodological modeling was done in the 3 phases such as skeleton tracking, feature extraction and action recognition. We took a window of 30 frames for individual to create feature vector and Concatenated the 3-D coordinates in each frame.

RESULTS: Successful recognition of hand washing was seen at the individual level. This model gave possible number of times a particular healthcare professional hand washed in a specific time period with automatic logging of this activity.

CONCLUSIONS: This preliminary study shows that it is possible to successfully recognize hand washing at the individual level. Further research is in progress to make it easily applicable in a real world setting.

EP-117[Neurotrauma and Intensive Care] EPIDEMIOLOGIC ANALYSIS OF PATIENTS WITH SEVERE TRAUMATIC BRAIN INJURY IN SHIRAZ, IRAN FROM 2011 TO 2013

Nima Derakhshan, Hosseinali Khalili, Fariborz Ghaffarpasani
Shiraz neuroscience research center, Shiraz University of medical sciences, Shiraz, Iran

INTRODUCTION - OBJECTIVE: Traumatic brain injury remains the leading cause of mortality and morbidity worldwide. With changes in demographic status, improvements in technology and introducing novel medical and surgical guidelines for management of TBI patients, regular evaluation of epidemiological profile, injury severity classification, and outcomes are required.

METHOD: A form was designed to record demographic data, trauma event history and TBI-related variables such as GCS, pupils, brain CT finding, vital signs, arterial blood gas results, and final GOS after 6 months follow up. From March 2010 till June 2012 all Patients with severe TBI admitted in Shahid Rajaei hospital affiliated to Shiraz University of Medical Sciences, Shiraz, Iran was reviewed. Available data were filled within the mentioned forms and then transferred to SPSS 16 software for analysis.

RESULTS: Of 681 patients with TBI who had GCS ≤ 10 , 98 (14.4%) were female and 583 (85.6%) were male. The most frequent mechanism of trauma was motor-vehicle accident (MVA) (65%) followed by pedestrian (17.3%), fall (12.3%), and assault injuries (5%). Mean age (\pm SD) of our patients was 36.1 (\pm 18) years with 68% were young (≤ 40), 17.6% Middle-aged (40-59), and 14.1% Old (≥ 60). Six-months GOS score of these patients, which shows 80% of our patients, had favorable outcome (GOS ≥ 4) with 41% full recovery (GOS = 7 & 8).

CONCLUSIONS: Shahid Rajaei trauma center which was one of the largest referral trauma centers in southern Iran has achieved similar favorable outcomes as other trauma centers worldwide which had presented their epidemiologic data.

EP-118[Neurotrauma and Intensive Care] NON-CONVULSIVE SEIZURES IN CHINESE SEVERE TRAUMATIC BRAIN INJURY PATIENTS AND PERSONALIZED ANTI-SEIZURE TREATMENT CONSIDERING CYP2C19 AND CYP2C9 GENETIC POLYMORPHISMS

Yirui Sun, Yu Jian, Xing Wu, Xuehai Wu, Yi Jin, Jin Hu, Ying Mao, Liangfu Zhou
Department of Neurosurgery, Huashan Hospital, Fudan University

INTRODUCTION - OBJECTIVE: Non-convulsive seizures have been recognized as a significant challenge in NICU, particularly for patients with severe traumatic brain injury (TBI). Although prophylactic anti-seizure treatment is often applied according to the latest guidelines, little is known regarding genotypes and vedproate response. The aims of this study are: 1) to determine the prevalence of Non-convulsive seizures in Chinese TBI patients; 2) to investigate whether the CYP2C19 and CYP2C9 genetic polymorphisms involved in the metabolic process of vedproate and prognosis.

METHOD: 256 patients with acute severe TBI were enrolled; all received intensive care and bedside electroencephalograph (EEG) monitoring. Prophylactic anti-seizure treatment was applied for all patients. Blood vedproate levels were monitored one week after injury and relationships were determined with patients' CYP2C19 and CYP2C9 genetic polymorphisms. Neurological outcomes were determined one year after injury by GOS and Weschler Memory Scale scores.

RESULTS: Over 21 percent patients were detected non-convulsive seizures at least once, of which the percentage of patients carrying 1 or 2 CYP2C19 loss-of-function alleles (*2, *3) was higher than that in patients without seizure. In addition, patients carrying 1 or 2 CYP2C19 loss-of-function alleles show lower blood vedproate levels, but such difference was not found in patients carrying CYP2C9 genetic

polymorphisms. By adjusting blood vedproate levels, patients with different genetic polymorphisms showed similar incidence of seizures and outcomes as determined by GOS and Weschler Memory Scale scores one year post-injury.

CONCLUSIONS: Incidence of non-convulsive seizures high in severe TBI patients. Common CYP2C19 but not CYP2C9 genotypes had significant impact on vedproate response.

EP-119[Neurotrauma and Intensive Care] DEFEROXAMINE ATTENUATED ACUTE VENTRICULAR DILATION AFTER TRAUMATIC BRAIN INJURY IN RAT

Jinbing Zhao¹, Zhi Chen², Yangdong He², Guohua Xi², Richard F Keep², Ya Hua²

¹Department of Neurosurgery, Nanjing Brain Hospital Affiliated to Nanjing Medical University, Nanjing, China

²Department of Neurosurgery, University of Michigan, Ann Arbor, Michigan, USA

INTRODUCTION - OBJECTIVE: Acute posttraumatic ventricular dilation and hydrocephalus are relative frequent consequences after traumatic brain injury (TBI). Besides, several recent studies indicated that high iron level in brain may relate to hydrocephalus and brain atrophy after intracranial hemorrhage. However, there is still no report about the role of iron in the development of posttraumatic ventricular dilation.

METHOD: Lateral fluid-percussion (FPI) was used to introduce TBI in male Sprague-Dawley rats. Magnetic Resonance (MR) T2-weighted and T2* gradient-echo sequence imaging was applied to measure the lateral ventricular volume. HO-1 and complements (C3a, C5b-9) were measured by immunohistochemistry. Enlargement of lateral ventricular was also evaluated by MR after intraventricular injection of 200 μ l FeCl₃ (0.5 mmol/L) or saline.

RESULTS: We found the dilation of ventricles appeared at 24 hours after TBI by MR imaging. Intraventricular injection of FeCl₃ resulted significantly lateral ventricular enlargement compared with the saline at 24 hours after injection. DFX treatment attenuated the ventricular enlargement and the TBI-induced HO-1 over expression in periventricular area and upregulation in CSF, but not the complement components (C3a, C5b-9).

CONCLUSIONS: The iron released from the hemoglobin breakdown during hematoma resolution mediated by TBI played an important role in acute posttraumatic ventricular dilation, which could be alleviated by DFX, an iron chelator.

EP-121[Neurotrauma and Intensive Care] CHRONIC SUBDURAL HEMATOMA WITH SPONTANEOUS REGRESSION

Emre Hasan Aydin¹, Zuhtu Ozbek², Ramazan Durmaz²

¹Department of Neurosurgery, Eskisehir State Hospital, Eskisehir, Turkey

²Department of Neurosurgery, Osmangazi University, Eskisehir, Turkey

INTRODUCTION - OBJECTIVE: Chronic subdural hematoma related with trauma generally seen in elderly patients. Related to the cerebral atrophy; a potential space occurs under dura and this space predisposes occurrence of subdural hematoma resulted from parasagittal vein bridge rupture in acceleration injuries.

METHOD: Clinical is insidious, patient generally has only headache. Underlying hematological illness can be counted as possible causes.

RESULTS: Surgical treatment is necessary if neurological deficit occurs and increased intracranial pressure effect of hematoma is determined in radiologic finding. In our patient; because of the refractory thrombocytopenia surgery can not be applied; under close clinical follow-up in eight month duration hematoma is resorbed.

CONCLUSIONS: As a result; we suggest that with successful clinical follow-up and medical treatment, chronic subdural hematoma can be resorbed.

EP-122[Neurotrauma and Intensive Care] CLINICORADIOLOGICAL PREDICTORS OF OUTCOME OF POSTERIOR FOSSA EXTRADURAL HAEMATOMA

Shivender Sobti, Sondev Bansal, Ajay Choudhary, Laxmi Narayan Gupta, Suryanarayanan Bhaskar
Department of Neurosurgery, Postgraduate Institute of Medical Education & Research, Dr. Ram Manohar Lohia Hospital, New Delhi

INTRODUCTION - OBJECTIVE: INTRODUCTION- Posterior fossa extradural hematomas (EDH) comprise 4% to 7% of all intracranial extradural hematomas. **OBJECTIVES-** 1) To study demographic features of patients with Posterior fossa Extradural haematoma. 2) To assess predictors of the outcome of Posterior fossa Extradural haematoma.

METHOD: A prospective study of 25 patients who presented with Posterior fossa EDH was conducted in PGIMER DR.RML Hospital, New Delhi in department of neurosurgery from January 2011 to July 2012. Patients' data included age, sex, GCS, mode of trauma, volume of haematoma, associated fracture and intracranial injury.

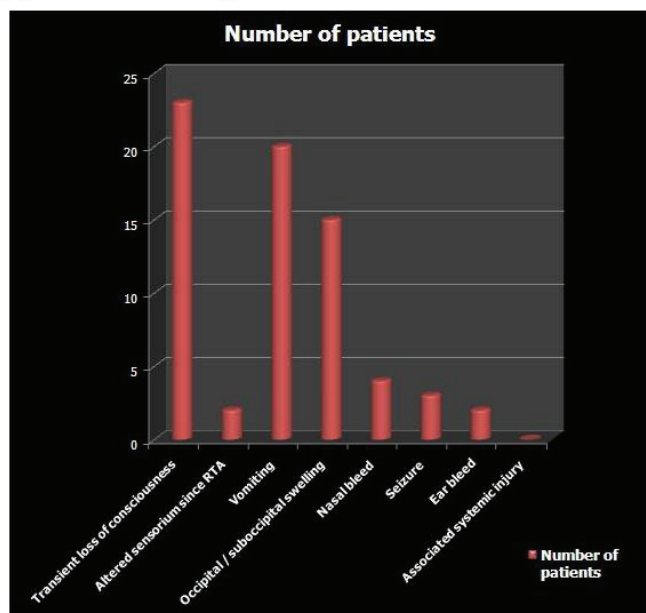
RESULTS: In our study male to female ratio was 22:3 Age range was 6 month to 62yrs and Mean age was

23.70 years Mode of trauma was fall from height in 12 patients, RTA in 12 patients, assault in 1. Majority of the patients had acute course (80%) followed by subacute course (20%). GCS was between 8 to 15. Volume of haematoma ranged from 2 to 100 ml and mean was 14.54 ml. 4th ventricle was compressed in 6 patients out of 25. Fracture was associated in 21 patients out of 25. Associated intracranial injury was present in 22 patients.

CONCLUSIONS: In our series posterior fossa EDH is a result of direct impact injury as 88% of patients had overlying fracture. The neurological status and outcome was associated with GCS, volume of hematoma and associated intracranial injury. Posterior Fossa EDH rarely occur as an isolated injury.

Figure 1: Clinical Presentation of patients

Figure 1: Clinical Presentation of patients



Loss of consciousness was the most common presentation seen in all the cases, followed by vomiting (80%), Occipital / suboccipital swelling (60%), ENT bleed (24%), seizure (12%), neurological deficit (04). Transient loss of consciousness was seen in 92% of cases and altered sensorium since RTA was seen in 08% of cases. The most consistent feature was an external injury to the occiput. 15 out of 25 cases had evidence of local trauma to the back of the head in the form of occipital swelling. Out of 24% ENT bleed cases, in 16% case nasal bleed and in 8% cases ear bleed seen. Neurological deficit was seen in the form of hemiparesis. Seizure, an uncommon association with the posterior fossa lesion was recorded in 3 patients.

Figure 2: Glasgow coma scale at presentation

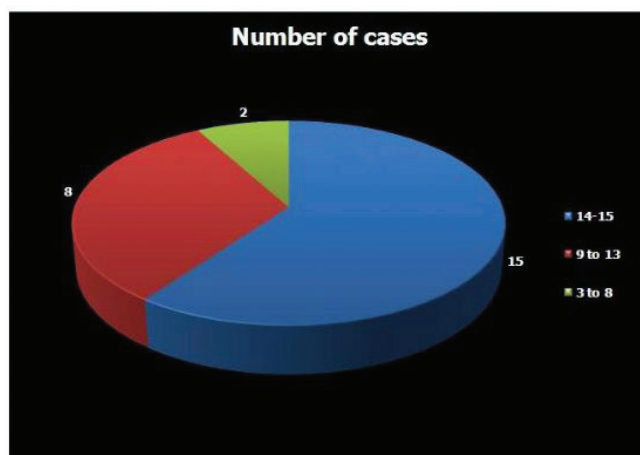
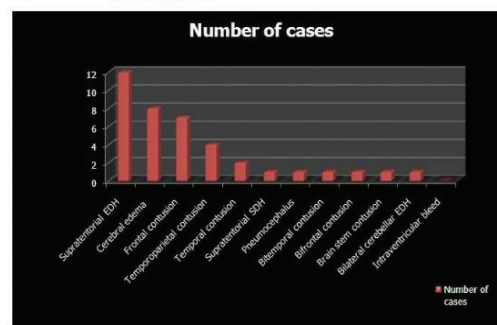


Figure 2: Glasgow coma scale at presentation

Range of GCS was 8 to 15. Most of the patients in our study had good GCS. 60% had GCS of 14-15, 32% had between 9 to 13, 8% had GCS of 8.

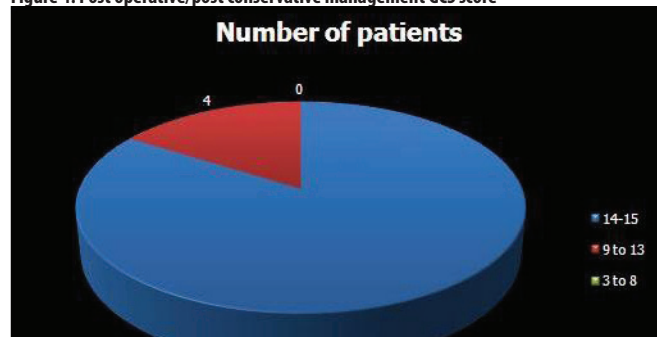
Figure 3: Associated Parenchymal Injury

Figure 3: Associated Parenchymal Injury



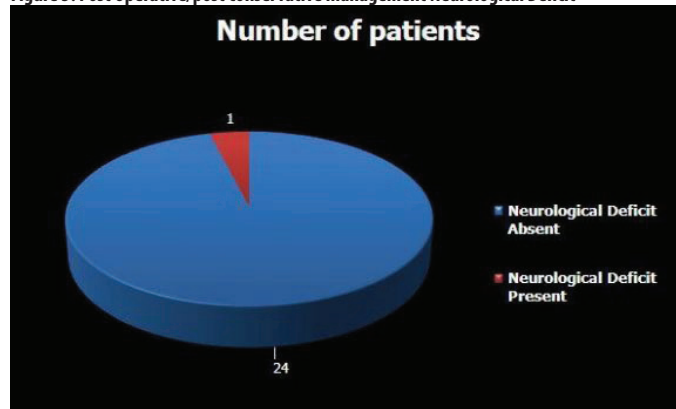
Most common associated parenchymal injury was supratentorial EDH that was present in 12 cases (48%). It was followed by cerebral edema (32%), frontal contusion (28%), Temporoparietal contusion (16%), Temporal contusion (8%) respectively. Supratentorial SDH, pneumocephalus, Bitemporal contusion, Bifrontal contusion, Brain stem contusion, Bilateral cerebellar EDH were seen in 1 case (4%). None of the patients had Intraventricular bleed.

Figure 4: Post operative/post conservative management GCS score



21 (84 %) patients had post operative/post conservative management GCS score between 15- 16 whereas 4 (16%) had post operative/post conservative management GCS score between 9-13.

Figure 5: Post Operative/post conservative management Neurological Deficit



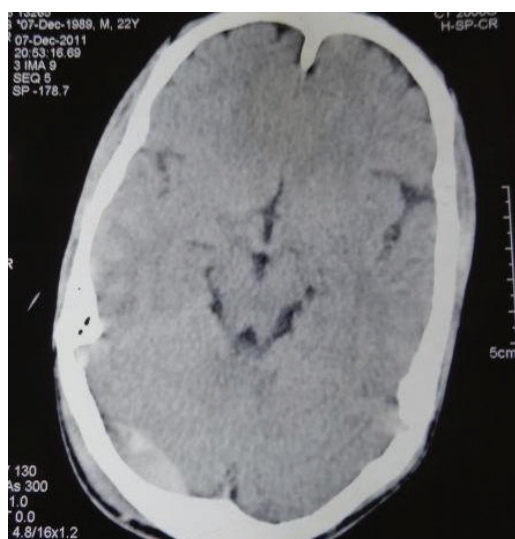
Post operative neurological deficit was seen very rarely, in one patient in the form of hemiparesis. Most of the patients had good recovery.

Table 1: Patient Characteristics

Patient Characteristics	Number of cases	Percentage
Sex		
Male	22	88
Female	3	12
Age (Years)		
0-18	7	28
19-30	12	48
31-45	4	16
46 - 60	1	4
Above 60	1	4
Mode of Injury		
RTA	12	48
Fall from height	12	48
Assault	01	4

Patients were divided into two groups, paediatric (below 18 years) and adult (above 18 years). Mean age of presentation was 23.70 years. Out of 25 patients 22 (88%) were male and 3 (12%) were female. So predominate sex in our study was male as compared to females. Fall from height (48%) and RTA (48%) were the commonest modes of injury followed by assault (4%). The most common mode of fall was from stairs. Least common mode of injury was assault in our study.

CT Scan showing EDH



CT Scan showing EDH

Table 2: Clinical Characteristics of patients

Clinical Characteristics	Number of cases	Percentage
Clinical course		
Acute	20	80
Sub-acute	5	20
Chronic	0	0
Occipital pain		
Present	13	52
Absent	01	04
Not applicable	11	44
Lucid interval		
Present	10	40
Absent	15	60

In our study most of the patients had acute course (80%) followed by subacute course (20%). None of the patients had chronic course. Mean time interval between injury and presentation was 18hrs. Occipital pain was seen in 13 (52%) cases and the 3rd commonest mode of presentation. It was not applicable to 44% of cases because of low GCS and low age at the time of presentation. Lucid interval was present in 10 cases and absent in 15 cases so it was not as common presentation as seen in supratentorial EDH.

Table 3: Radiological Findings

Radiological Findings	No. of cases	Percentage
Haematoma volume		
<=10 cc	16	64
>10 cc	9	36
Clot thickness		
<=15mm	17	68
>15mm	08	32
4th ventricle status		
Compressed	06	24
Normal	19	76
Hydrocephalus		
Present	06	24
Absent	19	76
Skull fractures		
Present	21	84
Absent	04	16
Associated parenchymal injury		
Present	22	88
Absent	03	12

Volume of haematoma was found to be between 3ml to 100 ml in our study, with mean of 14.54 ml. It was observed that clot thickness was <= 15mm in majority of patients (68%), while rest(32%) had >15mm thickness. Mean clot thickness was 12.88 mm in our study group. 4th ventricle was seen compressed in six patients (24%). Hydrocephalus was absent in majority of patients (76%) and present in 06 patients (24%). Posterior fossa EDH is commonly associated with occipital bone fracture (84%). Rt sided (52%) occipital fracture was more common than Lt sided (32%). Associated parenchymal injury is commonly seen in Posterior Fossa EDH. It was seen in 88% of cases.

Table 4: Management of Patients

Management	No of patients	Percentage
Surgical for Posterior Fossa EDH	8	32
Surgical for associated injury	2	8
Conservative	15	60

In our study 8 patients were managed by surgical evacuation of heamatoma, 2 were operated for associated injury and remaining 15 were managed conservatively.

Table 5: Outcome according to Glasgow Outcome Scale

Glasgow Outcome Scale Outcome	Number of patients	Percentage
V Good recovery	24	96
IV Moderately disabled	1	4
III Severely disabled	0	0
II Vegetative life	0	0
I Dead	0	0

Good recovery was seen in 96% of the patients whereas 1 patient (4%) was moderately disabled according to Glasgow Outcome Scale.

EP-123[Neurotrauma and Intensive Care] ANALYSIS OF LETHAL OUTCOME AT VICTIMS WITH SEVERE COMBINED CRANIO-CEREBRAL INJURIES

Ulugbek Kurbanov¹, Kurbon Mamanazarov²

¹Surkhandarya Multidisciplinary medical center, Termez, Uzbekistan.

²Republican research centre of neurosurgery, Tashkent, Uzbekistan

INTRODUCTION - OBJECTIVE: The role of combined traumatic brain injuries is increasing in the structure of mortality in developed countries, especially in the middle aged group of population. Usually it becomes difficult to reveal the leading pathologic process that causes to lethal outcome, especially in the pre-hospital phase. The purpose is to enhance the quality of emergency medical care by analyzing the lethal outcomes in combined cranio-cerebral injuries.

METHOD: We analyzed 129 lethal cases with combined traumatic brain injuries, which are sectioned at our center. Among them 23 were women (17.8%), 106 men (82.2 %). Injuries were mostly caused by traffi accidents -76.9 % of cases, household injuries -12, 6%, 6 - occupational injuries, 3%, other factors - 4.2%.

RESULTS: Concomitant injuries occurred with brain injuries were as follows: Damage of the facial skeleton - 21 (16.3%), chest injuries and fractures of ribs - 23 (17.8%), abdominal and retroperitoneal injuries - 17 (13.1%), with fractures of the extremities - 27 (20.9%), with multiple injuries - 41 cases (31.8%). Prevalent age was 20-40 at 72% cases. The main causes which were revealed by retrospective analysis of 129 sectioned cases are showed in the table.

CONCLUSIONS: To improve the quality of patient care, reduce disability and mortality at victims with combined traumatic brain injuries require in time first aid at the scene as well as emergency transportation of victims in well equipped vehicles, which allows to perform preventive measures to reduce severe shock and restoration of external breathing disorders.

Immediate causes and timing of lethality in patients with combined traumatic brain injuries

	Causes of lethality		Timing of lethality					
		Before 6:00	Up to 24 hr	Up to 1 week	Up to 1 month	More than 1 month	Total	%%
1	Massive blood loss	6	3	-	-	-	9	7,0
2	Brain edema	7	6	2	-	-	15	11,6
3	Severe shock	28	13	-	-	-	41	31,8
4	Incompatible with life damage	52	-	-	-	-	52	40,3
5	Fat embolism	-	-	-	5	3	8	6,2
6	Complications of injuries	-	-	-	4	-	4	3,1
	Total:	93	22	2	9	3	129	100

EP-126[Neurotrauma and Intensive Care]

EARLY SURGICAL TREATMENT OF A LIFE-THREATENING LARGE RETROPHARYNGEAL HEMATOMA AFTER MINOR TRAUMA

Sang Youl Lee, Jin Hoon Park
Gangneung Asan Hospital

INTRODUCTION - OBJECTIVE: Only a few cases of anterior longitudinal ligament (ALL) injury related with retropharyngeal hematoma without fracture have previously been reported. The treatment of choice for retropharyngeal hematoma is generally considered to be conservative care, but we believe that early surgery of this pathology would be better in certain situations. Here, we describe two cases with life-threatening large retropharyngeal hematomas related with ALL injuries and operated on at an early stage.

METHOD: Two previously healthy patients visited the emergency room with neck pain and dyspnea after falling. Serious neck swelling was observed and lateral neck X-ray showed severe widening of the prevertebral space.

RESULTS: Due to dyspnea progression, emergency endotracheal intubation was performed. Although there was no primary cause of the retropharyngeal hematoma on preoperative examination, ALL tearing was intraoperatively confirmed during early surgery. The in-hospital evolutions of the patients were favorable after surgery.

CONCLUSIONS: We should bear in mind the possibility of ALL injury and perform early surgery where possible given the earlier convalescence and good prognosis

EP-127[Neurotrauma and Intensive Care]

ACUTE EXTRADURAL HAEMATOMA: A RETROSPECTIVE STUDY OF 460 PATIENTS WITH ANALYSIS OF FACTORS AFFECTING OUTCOME

Ramandeep Singh Dang¹, Balkrishan Ojha², Pranshu Bhargava¹, Anil Chandra²

¹Department of Neurosurgery, G.G.S. Medical College & Hospital, BFUHS, Faridkot, India

²Department of Neurosurgery, K.G.M.U., Lucknow, India

INTRODUCTION - OBJECTIVE: Extradural hematoma (EDH) is considered as neurosurgical emergency and is well accepted that timely surgical intervention leads to good outcome among these patients. There are not many studies on the outcome prediction among EDH patients exclusively. We undertook this retrospective study to analyze the outcome of patients with EDH who required surgical intervention for EDH evacuation with the aim to find out the overall outcome and the factors influencing the outcome.

METHOD: Records of all patients operated for EDH evacuation alone over a period of two and half years were included in the study. The collected data was tabulated for analyses and results were subjected to statistical evaluation. In present study Pearson's Chi Square Test for proportions was used to check the significance of differences in different categories/groups.

RESULTS: Of 460 patients, good outcome at discharge (GOS 5) was achieved in all patients with mild head-injury, 85% with moderate head injury and 49% with severe head injury. Statistically significant

good outcome was seen with mild head injury and lower age & poor outcomes were seen with severe head-injury at presentation, volume of EDH > 120cc & site (temporal & temporo-parietal)

CONCLUSIONS: EDH, should be treated as soon as detected because of possibility of achieving zero mortality rate in mild head injury and near zero mortality rate in moderate form of head injury cases. Though mortality rates rise and percentage of patients having good functional outcome becomes low but still these patients with severe head injury fare better than other subsets of head injury.

EP-128[Neurotrauma and Intensive Care]

INFECTION RATES AND FACTORS THAT AFFECTED POSTOPERATIVE INFECTIONS OF PATIENTS WHO DIAGNOSIS AS ANEURYSM IN NEUROSURGERY INTENSIVE CARE UNIT: RETROSPECTIVE EVALUATION OF 398 PATIENTS

Anas Abdallah, Betül Güler, Murad Asiltürk, Hasan Burak Gündüz, Erhan Emel, Mustafa Levent Uysal, Müslüm Güneş, Özden Erhan Sofuoğlu, İlhan Aydın, Fatih Cesur
Bakırköy Research and Training Hospital for Neurology Neurosurgery, and Psychiatry, Department of Neurosurgery, Istanbul, Turkey

INTRODUCTION - OBJECTIVE: Nosocomial infections can be defined as those occurring within 48 hours of hospital admission, 3 days of discharge or 30 days of an operation. Intensive care units (ICU) have the highest prevalence of hospital-acquired infections in the hospital setting. In this study postoperative infection rates and factors that affected 398 patients who underwent microsurgical clipping treatment and stay in ICU have been evaluated.

METHOD: Medical records were retrospectively reviewed in 398 (216 women and 182 men) patients of aneurysm who underwent 409 microsurgical clipping operations by our neurosurgeons between the years 2011 and 2013 have been evaluated. Blood, sputum, urine and CSF cultures had been obtained from patients who had high fever > 38.0 degree, needed frequent aspiration, or got impairment of neurological status. 274 patients were prestened after SAH, while 124 patients were diagnosed as aneurysm incidentally. Single aneurysm was detected in 308 patients, and 90 patients diagnosed as multiple aneurysm. The mean age was 50.4 (11-82).

RESULTS: Postoperative infections were detected in 58 (34 women, 24 men) (14.57%) of evaluated 398 patients. The majority of patients were presented as SAH (50 patients). The most common BSI (36) (21 women, 15 men) (9%) (SAH: 28; Incidental: 8) (Multiple: 14; ACoA: 7...). 2. infection was pneumonia (12) (6 women, 6 men) (3%) (SAH: 11; Incidental: 1) (Multiple: 6; ACoA: 3...). Meningitis (9) (4 women, 5 men) (2.2%) (SAH: 8; Incidental: 1) (Multiple: 1; ACoA: 4...). SSI (7) (4 women, 3 men) (1.75%) (SAH: 5; Incidental: 2) (Multiple: 3; ACoA: 2...). UTI seen in 5 (2 women, 3 men) (SAH: 5) (multiple: 4; MCA: 1), and osteomyelitis (2).

CONCLUSIONS: SAH, multiple aneurysms and especially patients with ruptured aneurysms located in anterior communicating artery have increased infection rates.

EP-129[Neurotrauma and Intensive Care]

ROLE OF MICROVASCULAR SHUNTING IN CEREBROVASCULAR DYSAUTOREGULATION AND MEASUREMENT OF THE CRITICAL CEREBRAL PERFUSION PRESSURE AT HIGH INTRACRANIAL PRESSURE

Denis E Bragin, Gloria L Statom, Edwin M Nemoto
Department of Neurosurgery, University of New Mexico School of Medicine, Albuquerque, NM, USA

INTRODUCTION - OBJECTIVE: To show that microvascular shunting is responsible for erroneously low critical cerebral perfusion pressure (CPP) obtained by static cerebral blood flow (CBF) autoregulation curve at high intracranial pressure (ICP) and whether dopamine induced intracranial (iPRx) and cerebrovascular (iCVRx) reactivity accurately identifies the critical CPP.

METHOD: Using in-vivo 2-photon laser scanning microscopy over the rat cortex we measured microvascular flow velocity, NADH and blood brain barrier (BBB) during stepwise decrease of CPP by increasing ICP with artificial cerebrospinal fluid reservoir connected to the cisterna magna. Doppler flux, temperature, intracranial and arterial pressure were monitored. A transient 10 mmHg rise in mean arterial pressure (MAP) was induced by i.v. dopamine for iPRx and iCVRx determination; $iPRx = \Delta ICP / \Delta MAP$ and $iCVRx = \Delta CBF / \Delta MAP$.

RESULTS: Reduction of CPP to 50 mmHg by increasing ICP caused stagnation of capillaries and transition of flow to microvascular shunts, leading to hypoxia, edema and BBB damage. At a normal CPP = 70 mmHg, the MAP challenge caused no change in iPRx or iCVRx reflecting intact reactivity. When CPP was decreased to 50 mmHg, iPRx and iCVRx increased to 0.24 ± 0.016 and 0.31 ± 0.013 , respectively ($n=10$, $p<0.05$), reflecting impaired autoregulation.

CONCLUSIONS: The correct critical CPP at high ICP measured by dynamic iPRx and iCVRx is 50 mmHg where pathophysiological processes begin to occur. The static autoregulation curve gives erroneous critical CPP = 30 mmHg because Doppler probe, averaging blood flow in a large volume of tissue, could not differentiate the oppositely directed changes in collapsing capillary and developing high-velocity MVS flow which resulted in a pathologically elevated CBF at a lower CPP.

EP-130[Neurotrauma and Intensive Care]

OUTCOME FOLLOWING DECOMPRESSIVE CRANIECTOMY IN SEVERE HEAD INJURY

Syed Ul Abrar Bukhari, Abdulla Muhammad Qassim
rashid hospital dubai uae

INTRODUCTION - OBJECTIVE: OBJECTIVES: In the growing population the incidence of head trauma had increased. The aim of the study was to assess the outcome of decompressive craniectomy in severe head injury.

METHOD: METHODS: During period of June 2008 till June 2012 consecutive patients with severe head injury having GCS 8 and below having sub dural hematoma, contusions with midline shift and brain edema underwent decompressive craniectomy along with intracranial pressure (ICP) monitoring with removal of clot. This measure controlled the ICP and reverse the dangerous brain shift. Total 80 patients were included in the study. Diffuse injury was demonstrated in 12 cases. decompressive craniectomy was performed immediately in 65 patients and in 15 patients initially ICP was inserted and the procedure was performed after ICP had become unresponsive to conventional medical management. Survivors were followed up for one year to determine the Glasgow outcome scale (GOS).

RESULTS:RESULTS: Decompressive craniectomy lowered the ICP to less than 20mm of Hg in 85% of cases. Out of 80 patients twelve died and 18 remained in vegetative state. Thirty patients were severely disabled and 20 patients had good recovery. Outcome was unaffected by abnormal pupillary response to light, timing of decompressive craniectomy, brain shift (as seen on ct scan) and patient age possibly because of the small number of patients in each subsets.

CONCLUSIONS: CONCLUSION: Decompressive craniectomy was associated with better ICP control and more than expected functional outcome in patients with severe head injury having subdural haematoma.

EP-132[Neurotrauma and Intensive Care]

“GLASGOW OUTCOME SCORE” ASSOCIATION WITH INTERLEUKIN 8
CHANGES IN THE CEREBROSPINAL FLUID OF THE SEVERE TRAUMATIC
BRAIN INJURY PATIENT WITH PROGESTERONE TREATMENT

I Gde Anom Ananta Yudha

Department of Neurosurgery, Medical Faculty, Airlangga University

INTRODUCTION - OBJECTIVE: To analyze the effects of interleukin 8 changes in cerebrospinal fluid in patients with severe traumatic brain injury with progesterone treatment added, and its correlation with Glasgow outcome score.

METHOD: This study uses Observative longitudinal analytic design. Cerebrospinal fluid sample was taken during intracranial pressure monitoring surgery. Progesterone was injected at first day, sample was taken twice: at 24 hours after brain injury and 4th day afterwards. interleukin 8 level on cerebrospinal fluid measured with Enzyme Linked Immuno-Assay (ELISA) method with spectrophotometer. Glasgow Outcome Score was used to examine the outcome score after six month.

RESULTS: The statistical analysis on correlation between the levels of interleukin 8 on the first day and the fourth day using Paired T-test resulted in $p = 0.065$ which means that, there is no association between interleukin 8 level at the first day with interleukin 8 level on the fourth day. The statistical analysis using Pearson correlation resulted in $p = 0.002$ ($p > 0.05$), which means that there is association between the interleukin 8 level changes with Glasgow outcome score.

CONCLUSIONS: Interleukin 8 changes on cerebrospinal fluid has a remarked effects on Glasgow outcome score. There is no significant correlation between level of interleukin 8 at first day with fourth day. There is significant correlation between interleukin 8 level changes with Glasgow outcome score.

CONCLUSIONS: We conclude that an initial or peak ICP of 60mmHg or more in diffuse head injury carries a mortality of 100% within a week and may represent the threshold of treatment futility.

EP-134[Neurovascular Surgery]

ENDOVASCULAR TREATMENT OF ANEURYSM OF FETAL POSTERIOR
CEREBRAL ARTERY: ONE CASE REPORT AND LITERATURE REVIEW

Qing Zhu, Ailin Chen, Yanming Chen, Chao Sun, Qing Lan

Department of Neurosurgery, Second Affiliated Hospital of Soochow University, Suzhou, China

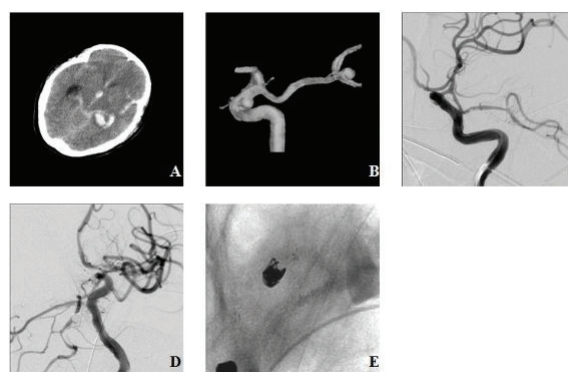
INTRODUCTION - OBJECTIVE: To discuss the clinical characteristics and endovascular treatment of aneurysm located at fetal posterior cerebral artery.

METHOD: One case, who presented as spontaneous subarachnoid hemorrhage, was diagnosed angiographically as a ruptured aneurysm of fetal posterior cerebral artery and an unruptured one of ophthalmic segment of internal carotid artery. The lesions were coiled assisted by stents under general anesthesia. The relevant literatures were retrieved and filtered with the key words as “fetal posterior cerebral artery” and “intracranial aneurysm” from the Pubmed database via internet.

RESULTS: The dense occlusion of two aneurysms and successful preservation of parent arteries were achieved by stenting-after-coiling technique. The satisfactory outcome of the case was confirmed during the follow up of a period of 28 months. Four relevant literatures were gained from the Pubmed database.

CONCLUSIONS: The key point of endovascular treatment for the aneurysm of fetal posterior cerebral artery is the preservation of parent artery of aneurysm. The technique of endovascular coiling assisted by stent is a safe and effective method for the treatment of such lesions.

Picture 1



Endovascular Procedure. A. Head CT showed subarachnoid hemorrhage. B. Three dimension angiography of lesions. C.D. Two aneurysms were coiled densely assisted by stents. E. The outline of parent artery was well described by the edge of coils.

Table 1. Results of literature retrieval

Year	Journal	Authors	Case Number	Procedures
2012	J Neurosurg	Lv X et al.[2]	3	Occlusion of lesion and parent artery
2011	No Shinke Geka	Yamaguchi S et al.[3]	1	Coiling
1996	No Shinke Geka	Kawamura A et al.[4]	1	Clipping
1986	J Neurosurg	Simpson RK Jr et al.[5]	1	Clipping

EP-135[Neurovascular Surgery]

ENDOVASCULAR COILING OF ANEURYSMAL REMNANTS
AFTER CLIPPING OF INTRACRANIAL ANEURYSMS

Qing Zhu, Ailin Chen, Yanming Chen, Chao Sun, Qing Lan

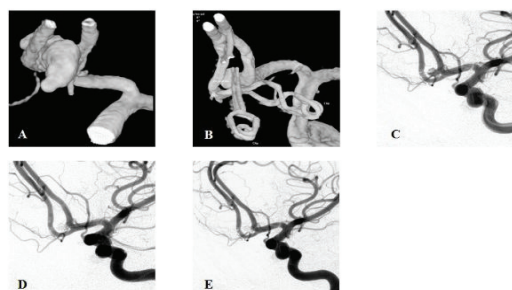
Department of Neurosurgery, Second Affiliated Hospital of Soochow University, Suzhou, China

INTRODUCTION - OBJECTIVE: To discuss the characteristics and endovascular coiling of aneurysmal remnants after clipping of intracranial aneurysms.

METHOD: Five cases, who experienced clipping surgeries previously, were diagnosed angiographically as aneurysmal remnants. The lesions were coiled under general anesthesia, and two of them were assisted by stents. The relevant literatures were retrieved and filtered with the key words as “residual aneurysm”, “incomplete clipping” and “endovascular coiling” from the Pubmed database via internet.

RESULTS: The total occlusion of lesions was achieved in four cases, with stenting in one case. The partial remnant of aneurysmal neck after stent assisted coiling occurred in one case and disappeared angiographically in six months' follow-up. Ten relevant literatures were gained from the Pubmed database.

CONCLUSIONS: It is more difficult and dangerous to re-clip the aneurysmal remnant after previous clipping. Endovascular coiling is an effective and safe therapy for the treatment of such lesions.



Picture 1. Case 1.

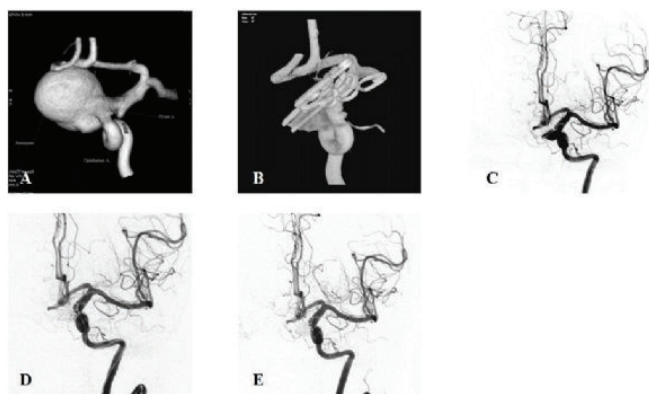
A: Three dimension angiography before surgical clipping. B: Three dimension angiography after incomplete clipping of anterior communicating artery aneurysm. C: Angiography before coiling for remnant. D: Angiography after coiling (Microvention) immediately demonstrated dense packing. E: Angiographical follow up in six months revealed satisfactory result.

Table 1. Patients list

No.	Sex	Age (Years)	Remnant Location	Max. Diameter (mm)	Technique	Results
1	Female	44	A.Com.A.	3.61	Coil	Coiled densely
2	Male	53	A.Com.A.	3.72	Coil	Coiled densely
3	Female	55	Oph.ICA	11.64	Coil + Stent	Coiled densely
4	Male	36	A.Com.A.	5.63	Coil	Coiled densely
5	Female	52	Oph.ICA	2.02	Coil + Stent	Residual of neck

A.Com.A.: Anterior communicating artery. Oph.ICA: Ophthalmic segment of internal carotid artery.

Picture 2. Case 3.



A: Three dimension angiography before surgical clipping. B: Three dimension angiography after incomplete clipping of ophthalmic segment of internal carotid artery aneurysm. C: Angiography before coiling for remnant. D: Angiography after stent (Codman) assisted coiling (Microvention) immediately demonstrated a little residual of aneurysmal neck. E: Angiographical follow up in six months revealed completely disappearing of aneurysmal cavity from angiography.

Table 2. Results of literature retrieval

Year	Journal	Authors	Case Number	Results
1994	Surg Neurol	Fraser KW et al.[1]	2	Coiled densely
1996	J Neurosurg	Forsting M et al.[2]	2	Coiled densely
1997	J Neurosurg	Thielen KR et al.[3]	8	Coiled densely in 6 Residual in 2
1999	Neuroradiology	Pierot L et al.[4]	3	Coiled densely
2000	Acta Radiol	Cekirge HS et al.[5]	4	Coiled densely
2002	Neurosurgery	Bendok BR et al.[6]	5	Coiled densely in 4 Residual in 1
2002	Stroke	Rabinstein AA et al.[7]	21	Coiled densely in 17 Residual in 4
2002	J Endovasc Ther	Lylyk P et al.[8]	1	Coiled densely
2004	Neuroradiology	Lubicz B et al.[9]	8	Coiled densely
2010	Neurosurgery	Kim BM et al.[10]	24	Coiled densely in 19 Residual in 5

EP-136[Neurovascular Surgery]

NUMERICAL SIMULATION OF HEMODYNAMICS OF A VERTEBRAL ARTERY ANEURYSM ASSOCIATED WITH BLOOD-SUPPLY OF BRAIN BY OPPOSITE VERTEBRAL ARTERY

Qing Zhu, Ailin Chen, Yanming Chen, Chao Sun, Qing Lan

Department of Neurosurgery, Second Affiliated Hospital of Soochow University, Suzhou, China

INTRODUCTION - OBJECTIVE: To discuss the hemodynamic characteristics of a vertebral artery aneurysm associated with blood-supply of brain by opposite vertebral artery, and analyze the origination of the aneurysm.

METHOD: The numerical simulation analysis in one patient with the left ruptured vertebral artery aneurysm associated with the blood-supply of whole brain by right vertebral artery was performed by the finite element method of computational fluid dynamics according to the images of three dimension rotation angiography.

RESULTS: The hemodynamic characteristics of the left vertebral aneurysm, which was originated from the abnormal hemodynamics of the blood-supply of brain by right vertebral artery only, was coincide with that of aneurysm located in the arterial bifurcations.

CONCLUSIONS: The numerical simulation of computational fluid dynamics can reflect the hemodynamic characteristics of intracranial aneurysms directly. The formation of the intracranial aneurysms was mainly associated with the various abnormal hemodynamics.

EP-138[Neurovascular Surgery]

INDIVIDUALIZED ENDOVASCULAR TREATMENT FOR INTRACRANIAL ANEURYSMS

Qing Zhu, Ailin Chen, Yanming Chen, Chao Sun, Qing Lan

Department of Neurosurgery, Second Affiliated Hospital of Soochow University, Suzhou, China

INTRODUCTION - OBJECTIVE: To evaluate the experience of individualized endovascular treatment for intracranial aneurysms.

METHOD: The clinical data of 30 patients with 32 intracranial aneurysms were analyzed retrospectively. Endovascular treatment was performed in all the patients including simple detachable coil embolization in 15 aneurysms, stent-assisted coil embolization in 12, balloon-assisted coil embolization in 2 and occlusion of the parent arteries in 3.

RESULTS: Complete embolization was achieved in 22 aneurysms, subtotal embolization in 7 and non-development of aneurysm after parent artery occlusion in 3. Intraoperative rupture of aneurysm occurred in 2 patients and severe vasospasm in 1. During the follow-up period from 1 to 72 months, 25 patients recovered well, 1 was mildly disabled, 1 severely disabled and 3 died.

CONCLUSIONS: Individualized endovascular treatment is a safe and effective method for intracranial aneurysms. Rational selection of interventional techniques and correct management of complications are key factors for successful treatment.

EP-139[Neurovascular Surgery]

EVOKED POTENTIAL MONITORING DURING ENDOVASCULAR TREATMENT OF CEREBROVASCULAR DISEASE TO PREVENT ISCHEMIC STROKE INDUCED BY TEMPORARY OCCLUSION OF THE FEEDING ARTERY

Qing Zhu, Ailin Chen, Yanming Chen, Chao Sun, Qing Lan

Department of Neurosurgery, Second Affiliated Hospital of Soochow University, Suzhou, China

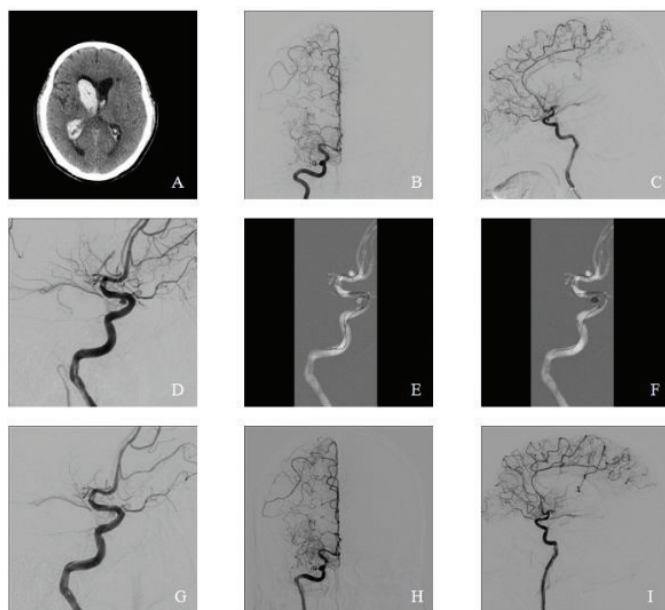
INTRODUCTION - OBJECTIVE: To explore the value of evoked potential monitoring to preventing ischemic stroke induced by the temporary occlusion of the feeding artery during the endovascular treatment of cerebrovascular diseases.

METHOD: In 13 patients with cerebrovascular diseases, the evoked potential monitoring was performed during the endovascular treatment in order to detect the ischemic changes induced by the temporary occlusion of the feeding arteries and to adjust the operative strategy in time.

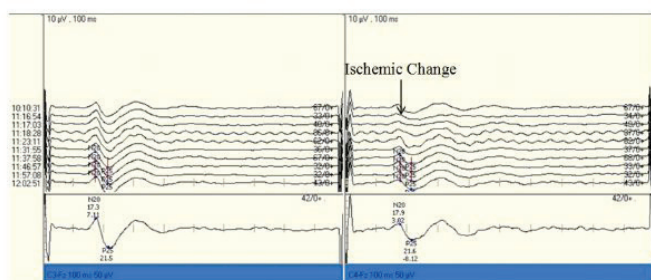
RESULTS: Seven patients with intracranial aneurysms and one patient with internal carotid cavernous fistula were successfully treated by the permanent occlusion of parent arteries after the temporary occlusion of the parent arteries with the balloons under the evoked potential monitoring. Balloon-assisted coils embolization was successfully performed in 5 patients with intracranial aneurysms, in whom, 1 with internal carotid artery aneurysm accompanied with Moyamoya disease underwent the adjustment of the duration of full balloon until the return of the somatosensory evoked potential (SEP) to normal because the abnormal change in SEP appeared after the temporary occlusion of the parent artery. The following-up 6 months after the operation showed that the postoperative ischemic stroke did not occur in all the patients.

CONCLUSIONS: The complications may be decreased and the curative effect of the endovascular embolization on the cerebrovascular disease may be enhanced by the evoked potential monitoring which is sensitive to ischemic changes in brain tissues, and may be routinely used during the endovascular treatment of the cerebrovascular diseases.

Picture 1.



Patient suffering from hemorrhagic moyamoya disease accompanied with unruptured aneurysm of cavernous segment of internal carotid artery. A. Head CT on admission. B.C. Angiography of right internal carotid artery before endovascular treatment. D. Working projection angiography before endovascular treatment. E. Dilated HyperGlide (4x15) balloon. F. Densely coiled aneurysm. G. Working projection angiography after endovascular coiling. H.I. Angiography of right internal carotid artery after endovascular coiling. **Picture 2.**



Intraoperative SEP monitoring of the same patient. Decreasing over 50% of amplitude of N20 and P25 in C4-Fz occurred after occlusion of right internal carotid artery by dilated balloon in 95 seconds. Amplitude of N20 and P25 recovered in five minutes after shrink of balloon rapidly.

EP-140[Neurovascular Surgery]

FACTORS RELATED TO HYDROCEPHALUS AFTER ANEURYSMAL SUBARACHNOID HEMORRHAGE

Naoufel Ouercifani, Mohamed Ghorbel, Rebai Riadh, Mohamed Zaher Boudawara
Habib Bourguiba Hospital, Sfax, Tunisia

INTRODUCTION - OBJECTIVE: The aim of this study was to identify factors predictive of hydrocephalus among patients with spontaneous subarachnoid hemorrhage. The data can be used to predict which patients have a high probability of requiring permanent cerebrospinal fluid diversion.

METHOD: one hundred sixty one patients with spontaneous subarachnoid hemorrhage whatever the aetiology were retrospectively studied, to identify factors contributing to hydrocephalus. With these data, a stepwise logistic regression procedure was used to determine the effect of each variable on the development of hydrocephalus

RESULTS: Overall, 32 of the 161 patients (20%) developed hydrocephalus. Ninety seven of the patients (60%) were female. Of the factors investigated, the following were associated with hydrocephalus, as determined with a variety of statistical **METHODS:** 1) increasing age ($P < 0.001$), 2) poor admission WFNS grade ($P < 0.001$), 3) Arterial Hypertension ($p < 0.001$), 4) thick subarachnoid hemorrhage on admission computed tomographic scans ($P < 0.001$), 5) intraventricular hemorrhage ($P < 0.001$). The sex, intracerebral hematomas, giant aneurysms, or multiple aneurysms did not influence the development of hydrocephalus. In addition, the risk of developing hydrocephalus increases twice with arterial hypertension and twelve times with intraventricular hemorrhage

CONCLUSIONS: The results of this study can help identify patients with a high risk of developing hydrocephalus. This may help neurosurgeons expedite treatment, may decrease the cost and length of hospital stays, and may result in improved outcomes.

EP-141[Neurovascular Surgery]

SURGICAL TREATMENT OF INTRACEREBRAL HEMATOMAS

Rashid Ishmukhametov, Tatyana Kaimak

Department of Neurosurgery, State Medical University of Semey, Semey, Kazakhstan

INTRODUCTION - OBJECTIVE: Until now, the debate is focused feasibility of surgical treatment of non-traumatic intracerebral hematomas. **OBJECTIVE:** to demonstrate the possibility of surgical treatment of NICH in the neurosurgical department' conditions of the region of Kazakhstan Republic.

METHOD: There are 367 patients with NICH in neurosurgery department of the Medical Center of the State Medical University of Semey in 2001-2012 ys. operated: with hemorrhages in the cerebellum - 31 (8.4%) patients, supratentorial localization - 336 (91.6%); from them 141 (38.4%) - subcortical, 135 (36.8%) - a lateral, 60 (16.3%) - mixed hematomas. Operations were carried out on 1-31 day from the onset. The volume of hematoma removal was 30-150 ml at supratentorial hemorrhages and 12-25 ml - with hematomas of a cerebellum. Puncture technique was applied for 198 (54.0%) patients with lateral and mixed hemorrhages: in 95.6% - by the end of the first week and later. The open method was used at 169 (46.0%) patients with subcortical hematomas and mixed; in 87.0% - within the first week. Cerebellar hematoma was removed from paramedial or suboccipital access.

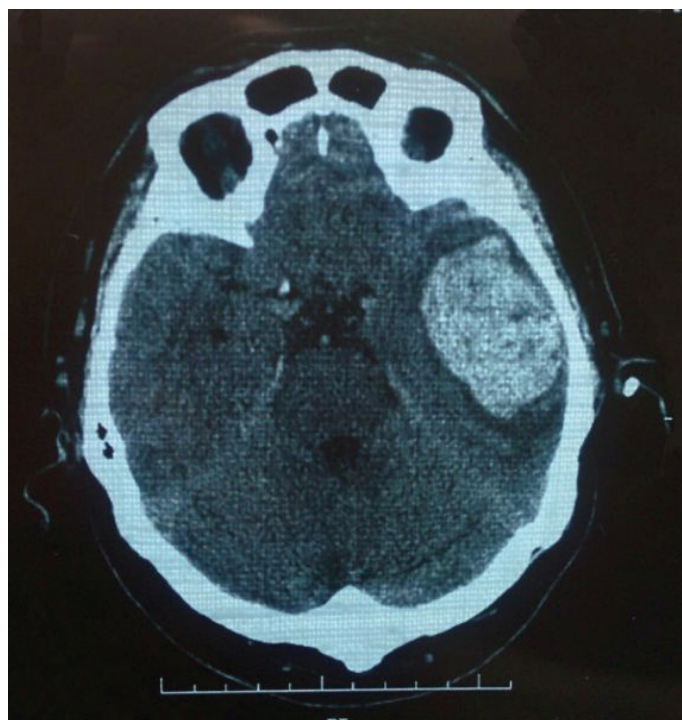RESULTS: 71 patients from 367 operated with hematomas died; with subcortical and lateral hematomas by 17.0%, mixed - 36.7%, cerebellar hematomas - 6.5%. Mortality rate increased from 11.0% for operations in stunning to 76.2% - in a deep coma, from 10.2% in the age range 40-59 years to 63.0% in those older than 70 years.

CONCLUSIONS: An open method is useful when the subcortical and lateral-subcortical hematomas, puncture - with lateral and medial-lateral hematomas have place.

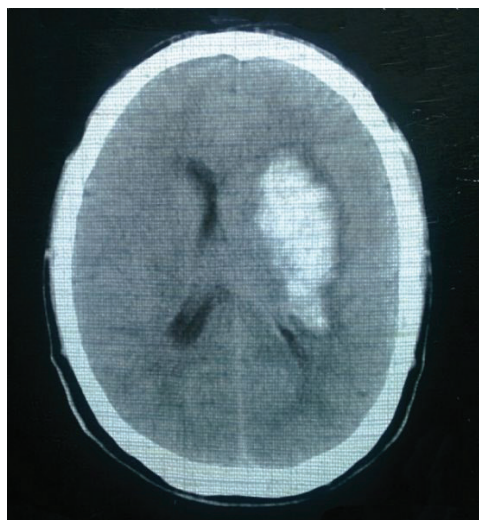
The results of treatment according to localization of NICH

Localization of haematoma	In all	Died	Mortality (%)
Subcortical	141	24	17,0
Lateral	135	23	17,0
Mixed	60	22	36,7
Cerebellar haematomas	31	2	6,5
In total:	367	71	19,3

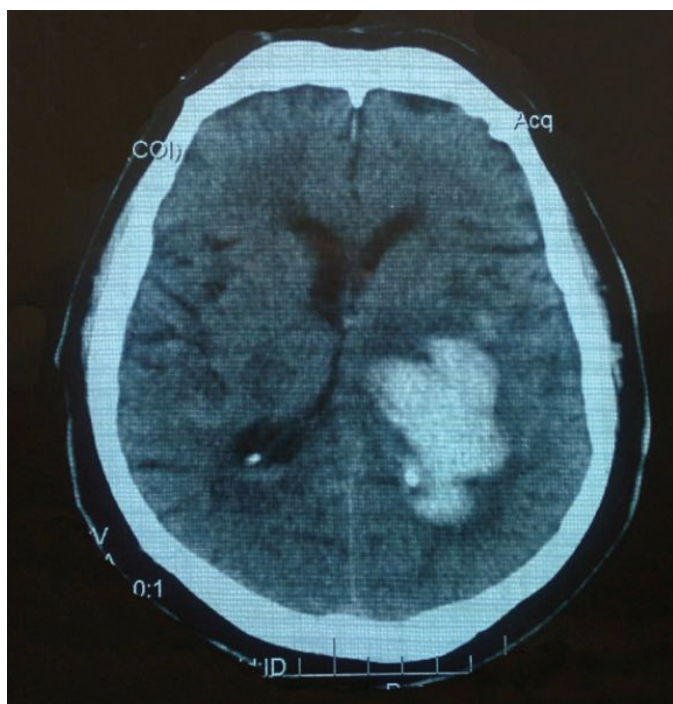
Subcortical haematoma



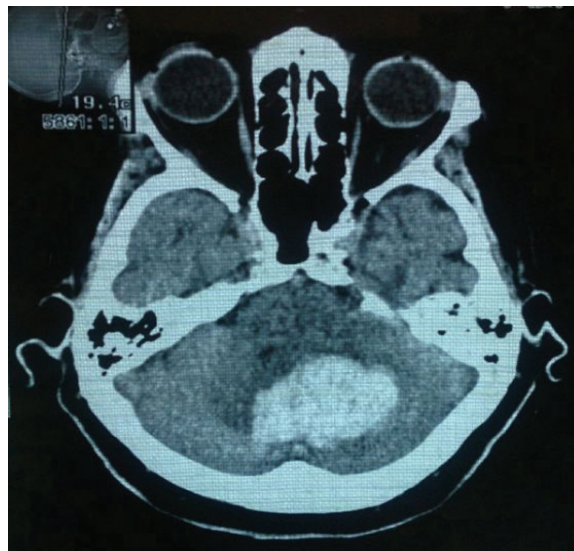
Lateral haematoma



Mixed haematoma



Cerebellar haematoma



EP-142[Neurovascular Surgery]

PRAS40 PLAYS A PIVOTAL ROLE IN PROTECTING AGAINST STROKE BY LINKING THE AKT AND MTOR PATHWAYS

Rong Xie¹, Xiaoxing Xiong², Michelle Cheng², Heng Zhao²¹Department of Neurosurgery, Huashan Hospital, Fudan University, Shanghai, China²Department of Neurosurgery, Stanford University, Stanford, USA

INTRODUCTION - OBJECTIVE: The proline-rich Akt substrate of 40 kilodaltons (PRAS40) protein is not only a substrate of the Akt protein kinase but also a component of the mTOR complex 1 (mTORC1), thus it links Akt and mTOR pathway. Our aim is to investigate the potential protective role and underlying mechanisms of PRAS40 in stroke.

METHOD: The mice with PRAS40 gene knockout (PRAS40 KO) and lentiviral vector with PRAS40 over-expression were included in this study. To test the protective effect of PRAS40, both distal MCA occlusion model and transient MCA suture occlusion model were used. Penumbra and ischemic core tissues were collected 1, 5, 9 and 24 h after stroke for Western blotting and immunostaining. Protein levels of Akt, FKHR (FOXO1), PRAS40, and mTOR were measured. Co-immunoprecipitation was used to detect the interactive effects between Akt and mTOR pathways.

RESULTS: Compared with control group, gene transfer of PRAS40 reduced infarction size in rats by promoting phosphorylation of Akt, PRAS40, and mTOR ($p < 0.05$). In contrast, PRAS40 KO increased infarction size ($p < 0.05$). Although the PRAS40 KO under normal condition did not alter baseline levels of phosphorylated proteins in the Akt and mTOR pathways, PRAS40 KO that underwent stroke exhibited reduced protein levels of p-S6K and p-S6 in the mTOR pathway but not p-Akt, or p-PEN in the Akt pathway. Furthermore, co-immunoprecipitation suggests that there were less interactive effects between Akt and mTOR in the PRAS40 KO compared with wild type mice.

CONCLUSIONS: PRAS40 appears to reduce brain injury by converting cell signaling from Akt to mTOR.

P-143[Neurovascular Surgery]

ENDOVASCULAR TREATMENT RUPTURES BRAIN ANEURISM IN ACUTE STAGE SAH

Mikhail Y Volodiukhin¹, Andrey G Alexeev¹, Valeriy I Danilov², Nail G Shaykhetov¹, Alexandr M Nemirovskiy¹, Roman A Bykov¹¹Interregional Clinic Diagnostical center, Kazan, Russia²Kazan State Medical University, Kazan, Russia

INTRODUCTION - OBJECTIVE: To report our experience endovascular treatment (EVT) rupture brain aneurism in acute stage SAH.

METHOD: Between 2008 and 2013 endovascular method were used to treatment 326 brain aneurism in 335 patients. 69,9% (228 pts) aneurisms were ruptured. In acute stage (during 2 week after rupture) were treated 91 patients. The average age was 48 years, 61% patients were women. According Hunt Hess scale 14,3% had I rate, HH II- 37,4%, HH III- 41,7%. 35,2% aneurisms were located A1-AComA2, MCA - 24,4%, PComA - 29,6%, 8,1%-posterior circulation. In mostly cases were used simple coiling without assistant methods. Chemical angioplasty were used in 20 patients. Balloon angioplasty of ICA and MCA were performed in 5 patients to treatment symptomatic vasospasm.

RESULTS: Technically successful was 98%. In one case EVT was not performed because aneurism had large neck and this patient was treated in late stage of SAH with stent assistant. The rupture aneurism during EVT were observed in 10,8% cases, thromboembolic complication - 14,8%. Procedure related morbidity and mortality were 6,75% and 9,45% respectively. In 40% chemical angioplasty allowed stable decelerates intracranial velocity in MCA (according data of TCD). Delay brain ischemia developed in 8 patients. In 5 were performed balloon angioplasties. In three balloon angioplasty did not performed because the area

of ischemia (DWI ASPECT) were too large. In one case balloon angioplasty was complicated of the fatal damage of MCA.

CONCLUSIONS: EVT can be successful use to treatment rupture brain aneurism in acute stage SAH

EP-144[Neurovascular Surgery]

CLINICAL OUTCOME OF INTRACRANIAL ANEURYSMAL SURGERY

Mumtaz Ali, Bilal Khan Afridi, Mohammad Idris Khan

Department of Neurosurgery, Govt. Lady Reading Hospital, Peshawar.

INTRODUCTION - OBJECTIVE: to know about the clinical outcome of intracranial aneurysmal surgery.

METHOD: this study was conducted in our Department from May 2010 to February 2014. All patients admitted with subarachnoid hemorrhage and undergone surgery for aneurysm were included in the study while those not operated were excluded from the study. Patients age, sex, location of the aneurysm on imaging, GCS status, time from admission till surgery, type of surgery performed were recorded on a designed performa and were evaluated for any neurological deficit post-operatively. Any untoward events per-operatively like rupture of the aneurysm were also recorded. Patients were followed post-operatively for a minimum of three months. Data was entered and analyzed using SPSS version 17 and expressed in the form of tables and charts.

RESULTS: of the total admitted 107 patients with SAH, 49 were operated upon with 28 males and 21 females having male: female of 1.2:1. The age range was from 24 to 62 years and mean age was 45 ± 4.3 years. All surgeries were performed in late period (after 14 days). Anterior Communicating artery aneurysm was present in 23(46.9%), posterior communicating in 8(16.32%), middle Cerebral in 15(30.60%), internal Carotid in 3(6.1%). GCS score in majority(77.55%) was above 10. Clipping was performed in 43(87.75%) patients while in 6(12.25%) wrapping/ICA ligation was done. Intra-operative rupture was encountered in 3(6.1%) patients. 42(84.65%) of patients were functional without any added neurology. Mortality rate was 8.1%(4).

CONCLUSIONS: Aneurysmal surgery in the form of clipping is a good option for patients with SAH with acceptably morbidity and mortality.

EP-145[Neurovascular Surgery]

VEIN OF GALEN ANEURYSMAL MALFORMATION PRESENTED BY DEMENTIA AND IMPOTENCE IN AN ADULT: CASE REPORT

Sherif Rashad, Tamer Hassan

Department of Neurosurgery, Alexandria University, Egypt

INTRODUCTION - OBJECTIVE: Vein of Galen aneurysmal malformations are a rare entity of vascular malformations that present themselves in neonates and infants by congestive heart failure in early days of life or later on by hydrocephalus and macrocephaly; very few reports exist on their presentation in adulthood.

METHOD: In this case report, we review a case of an adult suffering from vein of Galen aneurysmal malformation that was not diagnosed until the early thirties of his life. His main clinical symptoms were dementia and impotence.

RESULTS: Patient was managed by endovascular embolization and showed complete cure of his symptoms. In the presentation we review the possible etiologies for his delayed presentation

CONCLUSIONS: Vein of Galen aneurysmal malformation is extremely rare in adult. We present this case for better understanding of the pathophysiological process of such a rare disorder.

EP-146[Neurovascular Surgery]

DE-NOVO GIANT PARTIALLY THROMBOSED ANEURYSM COMPLICATING STA-MCA BYPASS SITE IN 3 YEARS; CASE REPORT AND REVIEW OF THE LITERATURE

Sherif Rashad, Tamer Hassan, Ahmed Sultan, Tamer Ibrahim

Department of Neurosurgery, Alexandria University, Egypt

INTRODUCTION - OBJECTIVE: Aneurysm formation following STA-MCA bypass is a rare condition with only a handful of cases reported in the literature with various presentations and management strategies. Various theories have been postulated to explain such rare complication and to determine whether it is a de-novo pathology or related to operative techniques

METHOD: 33 years old male patient who had undergone STA-MCA bypass and parent vessel occlusion for a giant cavernous ICA aneurysm 3 years ago. He presented to us with headache and on follow up radiologic investigations a giant aneurysm was found at the bypass site. We present this rare case and discuss its troublesome management.

RESULTS: Patient was evaluated by BOT for assessment of the possibility of sacrifice of the bypass, which concluded that the patient was independent of the bypass and so it was simply occluded

CONCLUSIONS: This is the first case reported with unruptured giant partially thrombosed aneurysm developing on the site of STA-MCA bypass. We discuss its management and possible etiologies for its formation with review of similar cases in the literature for future prevention and/or management of similar cases.

EP-148[Neurovascular Surgery]

SURGICAL TREATMENT OF INTRACEREBRAL HEMORRHAGES IN CASE PREGNANT WOMEN

Rashid Ishmukhametov

State Medical University of Semey, Semey, Kazakhstan

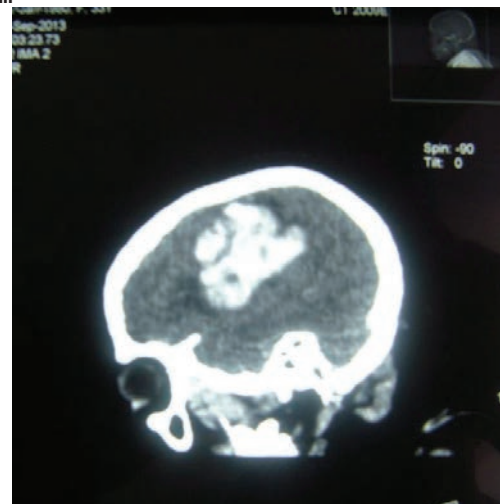
INTRODUCTION - OBJECTIVE: The emergence of urgent neurosurgical conditions in pregnant women is a complex multidisciplinary problem which decision requires participation of experts of several adjacent specialties. **OBJECTIVE:** to show the possibility of surgical treatment of non-traumatic intracerebral hematomas (NICH) in case of women in late terms of pregnancy.

METHOD: there were two women in the late terms of pregnancy with NICH in office of neurosurgery of the Medical center of the State medical university of the Semey city were operated. One of these supervision is given. The woman with pregnancy 31 weeks, after 7 hours from the disease beginning in a serious condition with level of consciousness of 8 points on the Glasgow' coma scale, with a hemiplegia at the left and with a meningeal syndrome arrived. The vital violations are not detected, heartbeat of the pre-natal child was distinct. CT of a brain revealed a subcortical hematoma in the right fronto-parietal area, with a volume more than 80 ml. One hour after admission made open (kraneotomiya, encephalotomy) removal of intracerebral hematoma.

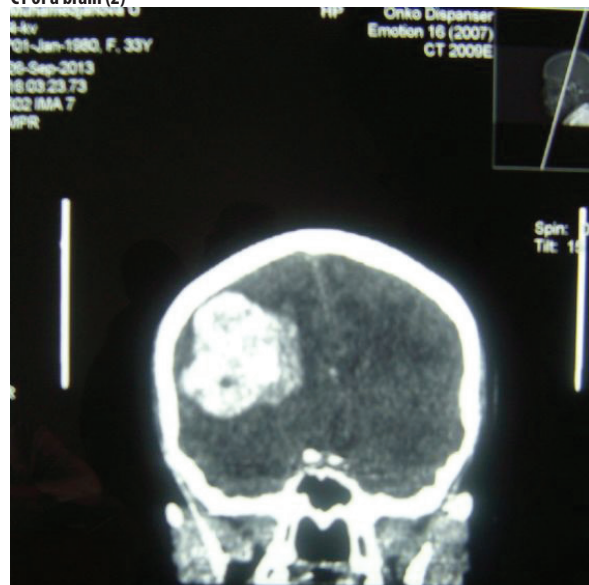RESULTS: The operations of removal of NICH allowed to keep life to women, to provide pregnancy and the birth of viable children.

CONCLUSIONS: The emergence of urgent neurosurgical pathology at the pregnant woman isn't fatal. Timely removal NICH during pregnancy enables saving a woman's life.

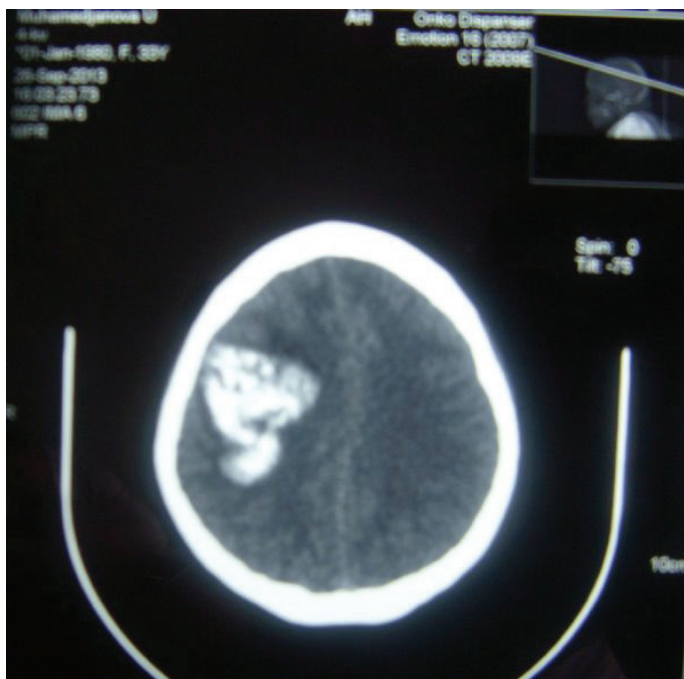CT of a brain



CT of a brain (2)



CT of a brain (3)



cases (96.3%) and poor in three cases (3.7%). Of the 12 cases with carotid endarterectomy and two cases of internal carotid artery ligation, all relative PCT parameters were changed after surgery compared with those before surgery. In one case of aneurysm, brain perfusion decreased after clipping, and improved after repositioning of the clip. Intraoperative CTA showed no cases of unexpected residual aneurysm, parental artery and perforating artery occlusion, residual nidus, or fistula. Twenty-nine aneurysms, one AVM, one DAVF, and 12 carotid stenoses were successfully treated. The outcome after 3–12 months of follow-up was good in 39 cases (97.5%) and poor in one case (2.5%).

CONCLUSIONS: Intraoperative CT is safe, simple, has a short acquisition time, and provides high quality images. This is helpful for identifying unexpected residual aneurysms and AVM, and parental artery and perforating artery occlusion in surgery.

Figure1

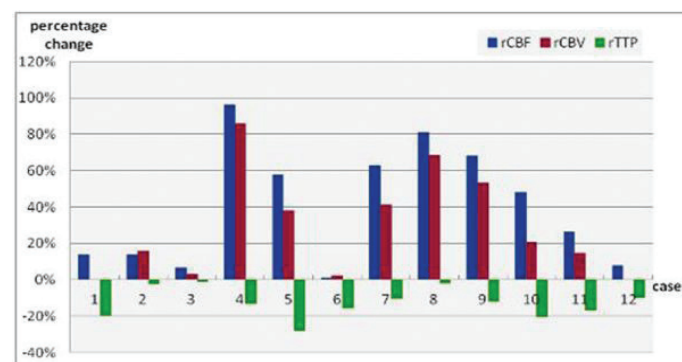


Figure2

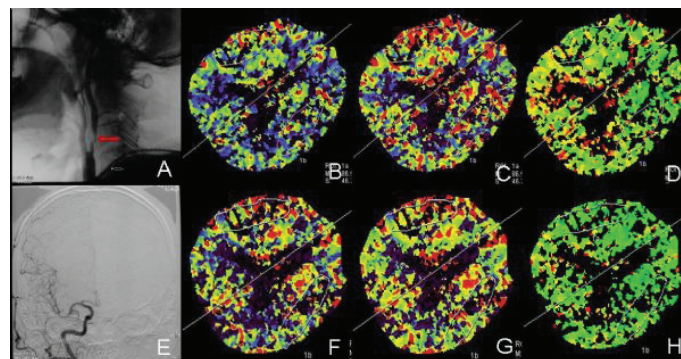
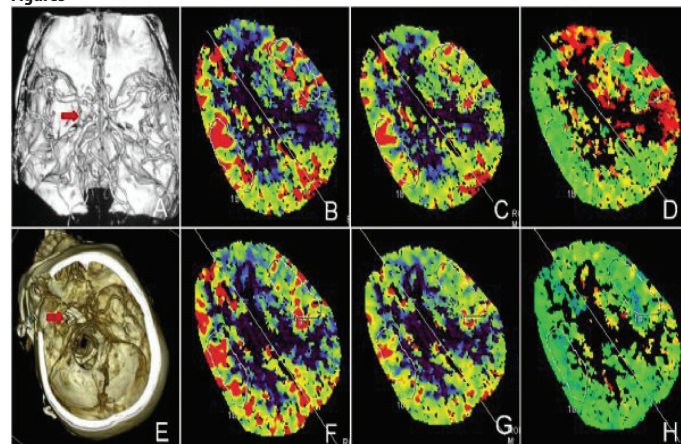


Figure3



EP-149[Neurovascular Surgery]

COMPLICATIONS IN SURGERY OF CEREBRAL ANEURYSMS DEPENDING UPON THE CHOICE OF METHOD OF OPERATION

Shalinder Aul, Andrei Vladimirovich Dubovoy, Konstantin Sergevich Ovsyannikov, Artem Michalvich Perfil, Jamil Afetovich Rzaev

Federal Neurosurgical Center, Novosibirsk, Russia

INTRODUCTION - OBJECTIVE: complications in aneurysm surgery depending upon the method of treatment were analyzed

METHOD: 155 patients operated during year 2013 were analyzed. Microsurgical clipping in 100 patients and endovascular occlusion in 55 patients was performed. All complications and their possible reasons were analyzed.

RESULTS:Complications in microsurgery group: ischemic, hemorrhagic, wound and manipulation related. Reasons for ischemic complications were: clipping of perforating artery, clipping of maternal artery and its branches as well as temporary clipping for a long time, arterial spasm, migration of atheroma in the lumen of parent artery. Hemorrhagic complications: aneurysm rupture, tearing of aneurysm neck from the artery, vein injury leading to the formation of venous infarct. Manipulation complications: traction injury to brain, injury to cranial nerves. Wound complications: CSF leakage, pneumocephaly, wound abscess. Complications in endovascular group: ischemic, hemorrhagic, mass affect by the implanted material, local. Ischemic complications: thromboemboly of the distal arterial course, migration of micro spirals in the lumen of artery, arterial spasm, dissection of the arterial wall. Hemorrhagic complications: rupture and tearing of aneurysm wall during embolization, aneurysm wall inflammation with its ulceration. Impact of implanted material: compression of cranial nerves and brainstem. Local complications: hematoma, abscess.

CONCLUSIONS: Aneurysms of the ophthalmic and communicating segment of ICA should be best operated microsurgically. Aneurysm of the IV segment of vertebral artery and basilar trunk aneurysms should be best stented and should not be embolized in order to avoid compression of brain stem and cranial nerves.

EP-150[Neurovascular Surgery]

APPLICATION OF INTRAOPERATIVE COMPUTED TOMOGRAPHY IN SURGERY OF CEREBROVASCULAR DISEASE

Zhenghui Sun, Fangye Li, Dingwei Peng, Chen Wu, Fuyu Wang, Bainan Xu
Department of Neurosurgery, Chinese PLA General Hospital, Beijing, China

INTRODUCTION - OBJECTIVE: In surgery for cerebrovascular disease, reliable information regarding cerebral hemodynamics and extent of resection of lesions during surgery is required. This study aimed to explore clinical application of intraoperative computed tomography (CT) in surgery of cerebrovascular disease.

METHOD: Forty patients with cerebrovascular disease who underwent microsurgery with intraoperative CT were recruited, including 26 cases with intracranial aneurysm, 12 cases with carotid stenosis, one case with arteriovenous malformation (AVM), and one case with dural arteriovenous fistula (DAVF). Surgical strategy was changed with combined perfusion CT (PCT) and CT angiography (CTA).

RESULTS:Average time for PCT and CTA was (19.96±0.66) minutes. Quality of images was good in 78

EP-151[Neurovascular Surgery] A1 SEGMENT ANEURYSMS: MANAGEMENT PROTOCOL BASED ON A NEW CLASSIFICATION

Sanjay Behari, Kamlesh Singh Bhaisora, Guru Prasad, Awadhesh K Jaiswal, Anant Mehrotra, Arun K Srivastava, Rabi Narayan Sahu
Department of Neurosurgery, Sanjay Gandhi Postgraduate Institute of Medical Sciences, Lucknow, India

INTRODUCTION - OBJECTIVE: Aneurysms of proximal(A1) segment of anterior cerebral artery(ACA) constitute less than 1% of all intracranial aneurysms. This study discusses their management dilemmas utilizing a new classification based upon their location on the longitudinal and circumferential axis of A1-segment.

METHOD: In 14 patients (0.98%; mean age:38.02+15.74 years), the clinical data including sign and symptoms, computed tomographic(CT) scan and CT angiography(CTA)/digital subtraction angiography(DSA) finding, modified Hunt and Hess(H&H) grade, surgical steps and difficulties encountered were recorded.

RESULTS: 14 patients with modified H&H grade I(n=2), II(n=2), III(n=4), IV(n=5) and grade V(n=1) (mean ictus-admission duration 5.07+2.30 days; range:1-10 days) underwent clipping(n=13) or wrapping(n=1). Bilateral lateral ventricle hemorrhage occurred in 8(66%); and, a frontal intracerebral hematoma in 2(16.66%) patients. In one patient, the aneurysm could only be detected following the third angiogram. Two patients had multiple aneurysms. A1 aneurysms were classified as proximal(n=6), distal(n=7), and mid-segment(n=1); as well as anterior(n=2), posterior-inferior(n=7), and posterior-superior(n=5). Follow-up (range:6 months -10 years, mean follow up:2.9 years) recovery correlated with the preoperative status and revealed excellent outcome(GOS 5) in 7(50%); moderate disability(GOS 4) in 2(14.2%); and severe disability in 2(14.2 %). Three mortalities occurred in H&H grade III-V patients with severe vasospasm, pneumonitis and septicemia.

CONCLUSIONS: A1-segment aneurysms have unique properties: small-sized aneurysmal rupture; multiplicity; no visualisation on initial imaging; frequent frontal lobar/intraventricular bleeding; origin from main trunk and not bifurcating points; neck Obscuration by A1 trunk; close proximity to perforators; and, associated A1-segment anomalies. A new classification identifies surgical difficulties at different sites on A1-segment and considerably helps in surgical planning.

Figure 1a and b

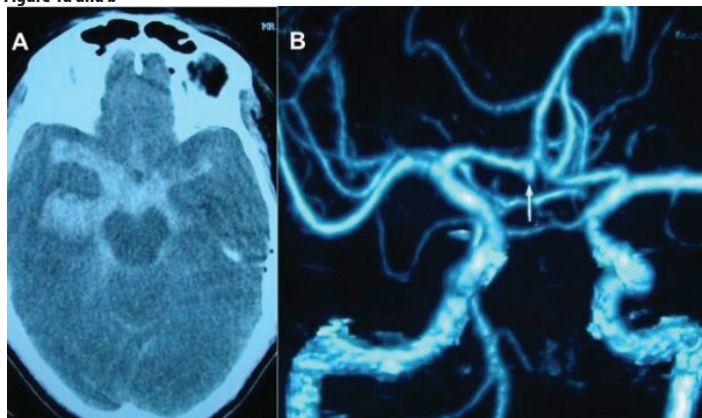


Figure 1 A: CT head obtained at admission showing bleed in interior interhemispheric fissure, basal cisterns and medial temporal lobe on right side; B: CT angiogram showing a distal A1-segment aneurysm directed posteroinferiorly

Figure 2

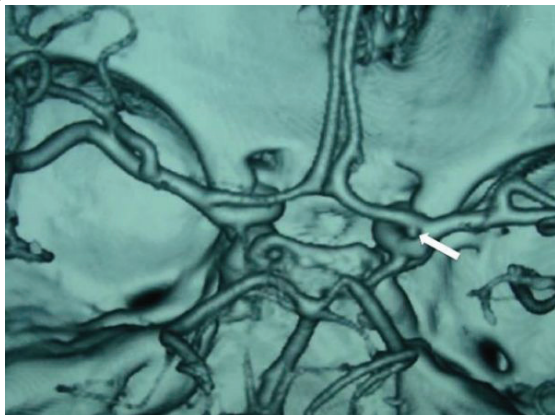
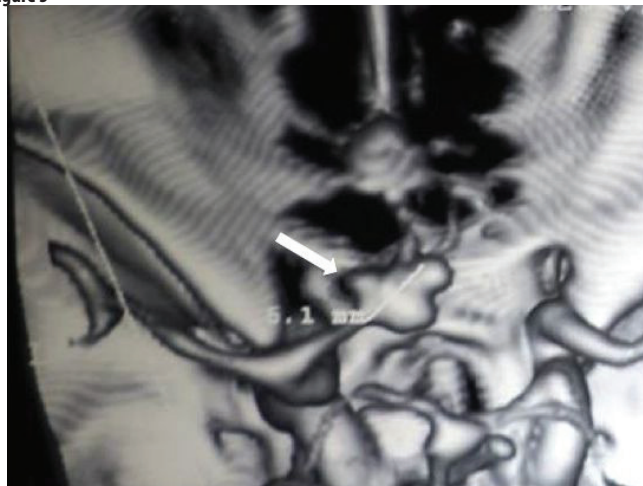


Figure 2: CTA revealing a blister proximal A1-segment aneurysm directed posteroinferiorly. The ipsilateral main A1-segment trunk often obscures the visualization of such aneurysms.

Figure 3



Trilobed fusiform aneurysm on the left A1-proximal segment. Opposite A1 is hypoplastic.

Figure 4a

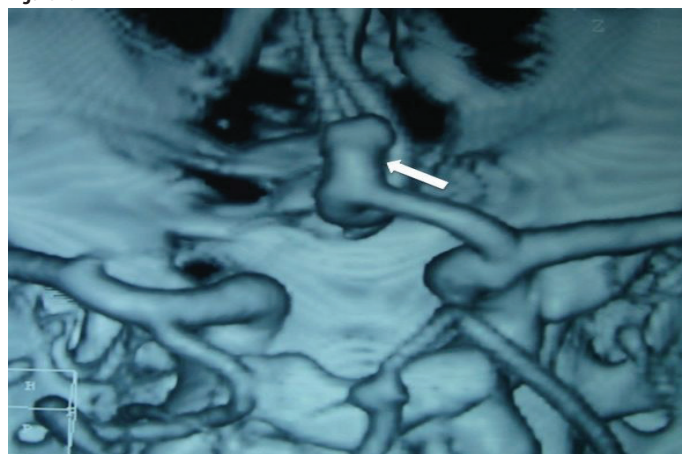
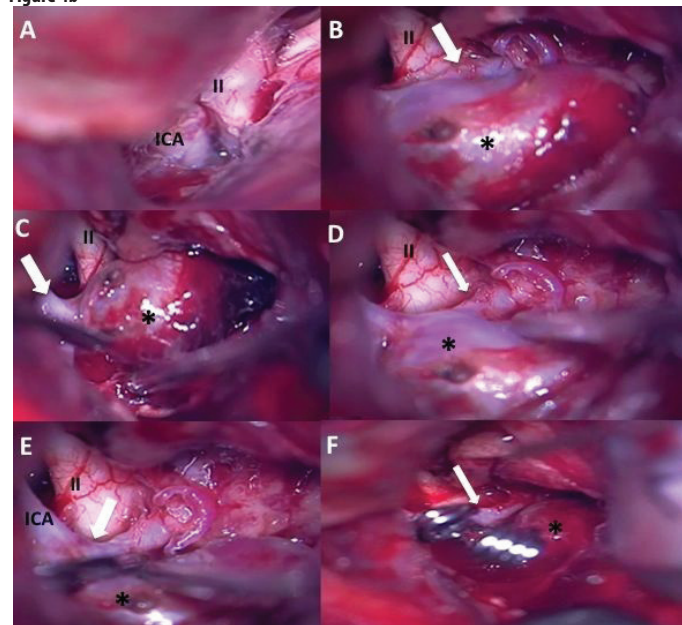


Figure 4 A: A large mid-segment A1 aneurysm directing antero-superiorly

Figure 4b



Operative steps: a: wide opening of sylvian fissure reveals internal carotid artery (ICA) and optic nerve (II); b: excision of orbitofrontal cortex reveals the large aneurysm (*) arising from the mid-segment A1 artery (arrow); c: the proximal A1-segment (arrow) control; d: the distal A1-segment control (arrow); e: a clip applied to the neck of the aneurysm (*). The entire length of A1-segment visualized (arrow); and, f: reinforcing clips applied to neck of aneurysm (*).

Table 1

	Anterior	Postero-superior	Postero-inferior
Proximal A1	1	2	3
Distal A1	0	3	4
Mid-segment	1	0	0

The classification based on the site of origin of the aneurysm on the longitudinal and circumferential axes of the A1 segment

Table 2

	Anomaly	Number of patients* (n=6)
1	Fenestrated A1 artery	2
2	Azygous A2 artery	2
3	Fenestrated anterior communicating artery	1
4	Contralateral hypoplastic A1 artery	2

Vascular anomalies associated with the A1 segment aneurysm. *One patient had both a fenestrated A1 and an azygous A2

EP-152[Neurovascular Surgery]

SPONTANEOUS INTRACEREBRAL HEMORRHAGE. SELECTION CRITERIA FOR MINIMALLY INVASIVE SURGICAL TREATMENT USING LOCAL FIBRINOLYSIS

Condrea Eugeniu, Safta Radu, Timirgazi Valerii
Institute of Neurology and Neurosurgery, Chisinau, Republic of Moldova

INTRODUCTION - OBJECTIVE: Spontaneous intracerebral hemorrhage (SIHC) is one of the leading causes of death and disability in the population. Minimally invasive surgical treatment for spontaneous intracerebral hemorrhage (SIHC) is being advocated as a good option in selected cases. The aim of this study was the appraisal of the indication for surgery and to establish optimal selection criteria for those patients.

METHOD: 54 patients with SIHC were operated in our clinic of neurosurgery starting from March 2011 until March 2014 using the puncture aspiration method with local fibrinolysis (with prourokinase). The selection criteria for surgery included: level of impaired consciousness on admission GCS ≥ 8 points, age from 17 to 80 years old, volume of hemorrhage range from ≥ 30 ml up to 80 ml, distance from cortex surface ≤ 2 cm, onset of symptoms not more than 72 hours, no/or minimal rupture in ventricular system.

RESULTS: From 54 patients 12 patients died (22.2%), 8 of them during hospitalization, the rest 4 patients died within 6 months after surgery. Postoperative functional results were evaluated using GOS score, Rankin Scale and Bartel Index. Good functional recovery was obtained in 14 patients (25.9%), remaining 28 patients showed different levels of disabilities from mild to severe.

CONCLUSIONS: Puncture aspiration and LF is an effective minimally traumatic method of treatment for SIHC, in relatively compensated patients (GCS ≥ 8). Selection criteria should consider size of hemorrhage and distance from cortex surface. Careful selection of patients decreases mortality rate and provides considerable reduction of postoperative complications and improves functional outcome in postoperative period.

EP-153[Neurovascular Surgery]

FORECAST OF VISUAL FUNCTIONS OF PATIENTS WITH TRAUMATIC CAROTID-CAVERNOUS FISTULAE

Dono Salhitdinovna Rakhmatullayeva
Scientific center of Neurosurgery of Republic of Uzbekistan, Tashkent, Uzbekistan

INTRODUCTION - OBJECTIVE: Traumatic carotid-cavernous fistulas (TCCF) represent serious pathology of cerebral vessels that are connected with formation of fistulae of internal carotid artery in the cavernous sinus. Dysfunction of vision with TCCF depends from the degree of changes in an ocular fundus. The objective of this research is to study a condition of visual functions which is dependent from special features of clinic duration of the disease.

METHOD: From the overall number of 58 patients ill with carotid-cavernous fistula, there were 36 observations of TCCF cases.

RESULTS: The degree of dysfunction of visual ability is highly affected by the heaviness of hemodynamic infarctions in the eye as well as in its orbit. In its turn the degree of dysfunction varies from blurred vision down to optic atrophy. Based on five observations it was concluded that patients with optic neuropathy and sharp dysfunction of vascular blood circulation in retina have a high risk of development of optic atrophy which also enrolls total visual disability.

CONCLUSIONS: The possibility of saving the visual functions is significantly higher in case of closing of fistulae in earlier stages of the illness. Therefore it is very crucial to instantly close the fistulae via embolization or micro-spirals.

EP-154[Neurovascular Surgery]

INTERMEDIATE RESULTS OF ENDOVASCULAR TREATMENT IN 77 PATIENTS WITH POSTERIOR CIRCULATION ANEURYSMS

Timur Shayakhmetov, Kirill Orlov, Alexey Krivoshepin, Dmitry Kisilitsin, Anton Gorbatykh, Vadim Berestov, Pavel Selesnev, Dmitry Dentzel

Department of Neurosurgery, Novosibirsk State Research Institute of Circulation Pathology, Novosibirsk, Russia

INTRODUCTION - OBJECTIVE: Retrospective analysis of the results of endovascular treatment of posterior circulation aneurysms.

METHOD: From January 2011 to January 2014 in our institution 77 patients (32 male and 45 female patients) with 83 aneurysms underwent endovascular treatment for posterior circulation (PC) aneurysms. In-hospital surgical mortality and morbidity were assessed by Modified Rankin Scale (mRS).

RESULTS: 31 aneurysms were treated with coiling only, 8 patients were treated using balloon-assisted technique, 20 aneurysms required stent-assisted coiling and 22 aneurysms were occluded with flow diverting devices. 28 patients had unruptured PC aneurysms. In 36 cases ruptured aneurysms were treated during posthemorrhagic period. 13 patients were treated during acute PC aneurysmal SAH. The size of aneurysms varied from 2.5 mm to 32 mm. Intraoperative complications developed in 11 cases. Among them hemorrhage was observed in 7 cases, ischemia was observed in 4 cases. Overall Surgical Mortality comprised 2 (2.6%) patients. Among them one patient deceased due to intraoperative ischemic complications, the other one died due to generalized vasospasm. Morbidity comprised 6 (7.8%) patients, 2 patients were mRS = 4, 2 patients were mRS = 5. Of the morbidity cases were related to intraoperative complications, in one case deterioration was related to the somatic pathology.

CONCLUSIONS: Posterior circulation aneurysms are extremely challenging for surgical treatment. Endovascular treatment allows achieving favorable results with relatively low mortality and morbidity.

EP-155[Neurovascular Surgery]

SURGICAL TREATMENT OF ANTERIOR CIRCULATION ANEURYSMS WITH SAH

Vladimir Tsikarishvili¹, Irakli Toidze¹, Marine Janelidze¹, Mirza Khinikadze², George Shalashvili², Mamuka Khachishvili², Irina Tabidze¹

¹Neurosurgery Department, S. Khachinashvili University Hospital, Tbilisi, Georgia

²Neurosurgery Department, PSP New Hospital, Tbilisi, Georgia

INTRODUCTION - OBJECTIVE: We have analyzed the perioperative clinical outcome data of 60 patients treated with microsurgery technique. Overall 75 anterior circulation aneurysms have been clipped within 1-4 days after subarachnoid hemorrhage.

METHOD: During 2 years (2011-2013) 60 patients with subarachnoid hemorrhage and 75 anterior circulation aneurysms were identified. All of them were surgically clipped within first 1-4 days after SAH. There were 35 female and 25 male. Mean age was 52 years (± 17 years). The distribution of aneurysms by localization: 30 AcomA aneurysm (40%), 23 MCA aneurysm (31%), 19 ICA aneurysm (25%), 3 distal ACA aneurysm (4%). Mean Hunt Hess grade was 2.15. Mean Fisher grade was 2.88. Perioperative clinical condition was evaluated by Modified Rankin Scale (mRS).

RESULTS: Good outcome according to the mRS (0, 1, 2) was achieved in 70% of cases (n=43). In a month after surgery mRS-0 was reported in 15 patients, mRS-1 in 18 patients and mRS-2 in 10 patients.

A moderate and poor outcome (mRS 3, 4, 5 and 6) was observed in 30% of patients (n=18): moderate disability (mRS-3) was observed in 8 patients, moderate-severe disability (mRS-4) in 4 patients, severe disability (mRS-5) in 2 patients and 4 patients died (mRS-6).

CONCLUSIONS: Our results suggested that surgical clipping still remaining to be a gold standard in the treatment of the anterior circulation aneurysms.

EP-158[Neurovascular Surgery]

TRANSILLIARY KEYHOLE APPROACH FOR ANTERIOR CIRCULATION ANEURYSMS. JOURNEY OF AN INDIVIDUAL

Lokendra Singh

Dr. Lokendra Singh, consultant neurosurgeon, central India institute of medical sciences, Nagpur, India

INTRODUCTION - OBJECTIVE: Objective of the article is to establish that key hole/minimally invasive approaches are as effective and safe as traditional approaches.

METHOD: MATERIAL- METHODS: Since 2008 to Feb 2014 total 35 cases have been operated upon using transillary key hole approach. Break is i.e. PCOM art – 23, MCA – 10, and carotid Ophth – 2. In total 22 females and 13 males. Most of them presented with sudden severe headache and neck stiffness. 23 were WFNS grade 1 and 12 were grade 2. All cases were operated through transillary key hole approach. No head fixator used. Lumbar drain was inserted in all cases. 2 cases ruptured during surgery and ICA was reconstructed. Post op. management was as for routine craniotomy cases.

RESULTS: RESULT: Over all results were excellent in 26 cases, who were discharged one week. 7 of them on 5th post operative day and 2 cases on 3rd post op. day. Complications: Meningitis - 1 Old lady with bad chest Chest infection - 2 cases Mortality - 1 died of Meningitis

CONCLUSIONS: Key hole approach is sufficient to tackle Anterior Circulation aneurysm mainly PCOM and proximal MCA, which are in good grade. There is a steep learning curve but once mastered it is a win-win situation for surgeon, patient and hospital.

EP-159[Neurovascular Surgery]

UNILATERAL APPROACH FOR CLIPPING OF BILATERAL MIDDLE CEREBRAL ARTERY ANEURYSMS

Zhenghui Sun, Fangye Li, Zhe Xue, Bainan Xu

Department of Neurosurgery, Chinese PLA General Hospital, Beijing, China

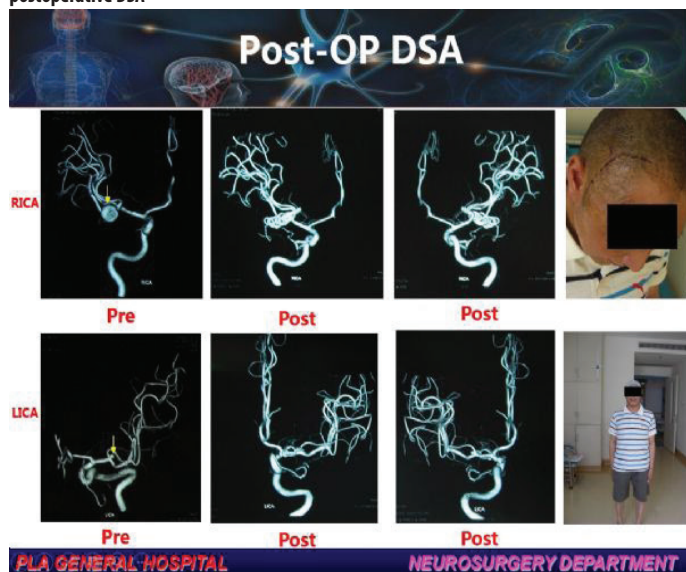
INTRODUCTION - OBJECTIVE: Unilateral approach for clipping of bilateral middle cerebral artery (MCA) aneurysms remains controversial. Our purpose is to explore the feasibility and indication of unilateral approach for clipping of bilateral MCA aneurysms.

METHOD: From Dec 2010 to Nov 2013, 8 cases with bilateral MCA aneurysms underwent unilateral approach for clipping of bilateral aneurysms. The frontotemporal approach was routinely used. The side of craniotomy was decided by the following factors: subarachnoid hemorrhage (SAH), offending aneurysm, size and shape of aneurysm. Surgical strategies and outcomes were summarized.

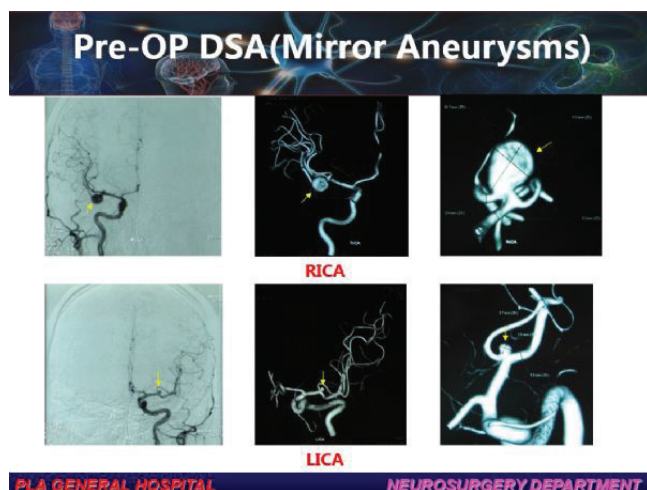
RESULTS: There are 5 women and 3 men in this series, with a mean age of 56 years. All patients had bilateral MCA bifurcation aneurysms. The side of offending aneurysm for SAH, larger or complex ones was always selected as side of craniotomy. The contralateral aneurysms were small, saccular, simple and unruptured ones. Conventional pterional approach was selected. Ipsilateral sylvian fissure was widely opened. Ipsilateral MCA bifurcation aneurysm was not clipped for enough space for manipulation. Supra sellar cistern and optic chiasm cistern were widely open. After contralateral ICA bifurcation was exposed, contralateral sylvian fissure was opened along M1 segment. Contralateral MCA bifurcation aneurysm was carefully clipped after proximal temporary occlusion. Then back to the ipsilateral side, ipsilateral MCA aneurysm was clipped finally. All bilateral MCA aneurysms were successfully clipped. Postoperative DSA confirmed absence of aneurysms and patency of parent arteries. All patients were favorable with Glasgow Outcome Scale score 4-5 at discharge.

CONCLUSIONS: Unilateral Approach for Clipping of Bilateral Middle Cerebral Artery Aneurysms is possible for selected cases.

postoperative DSA



preoperative DSA



EP-160[Neurovascular Surgery]

CLIP LIGATIONS OF BRAIN ANEURYSMS: OUTCOME OF 93 CASES

Shamsul Alam

Department of Neurosurgery, B S M Medical University, Dhaka, Bangladesh

INTRODUCTION - OBJECTIVE: Aneurysm surgery is increasing day by day in our country although the exact timing of surgery is still controversial. The aim of micro neurosurgical management of an aneurysm is the total occlusion of the aneurysm sac by clipping at the neck of aneurysm.

METHOD: There were 93 patients included in this study among them 3 patients expired soon after the admission before surgery could take place. Hence 90 patients underwent clip surgery from July 2005 to March 2014 for 93 aneurysms because 3 patients harbored multiple aneurysms.

RESULTS: Patient's history, clinical finding, Hunt & Hess grading, Fisher grading of CT scan, preoperative & postoperative CT angiography, postoperative outcome were collected and analyzed. Most of the clipping (45 cases) were done in intermediate stage (4th to 10th days), because patients usually referred from peripheral hospital on 2nd or 3rd days after the acute S.A.H. Overall outcome was assessed at 3 months after SAH using the Glasgow Outcome Scale. Good outcome were observed in 74 cases. Total mortality in this series were 14 cases which includes preoperative death while waiting for clipping -3 cases and postoperative death- 11 cases causes of death commonly from post-op Vasospasm, intra operative parent artery occlusion, hydrocephalus.

CONCLUSIONS: There is no reason to postpone clipping surgery in patients who are eligible for surgery at day 5. Although these studies is having high rate of mortality which can be progressively minimize by our continuous improvement of surgical skills.

Distribution of Hunt & Hess Grading

Hunt & Hess Grading	No. of cases
I – II	62
III-IV	27
V	4
Total	93

Distribution of Fisher grade of Aneurysms

Fisher Grading	No. of cases
I – II	67
III-IV	22
V	4
Total	93

Distribution of CT angiographic findings of Location of Aneurysms

Location of Aneurysms	No of aneurysms
ACOM aneurysm	41
PCOM aneurysm	20
MCA aneurysm	14
ICA aneurysm	7
DACA aneurysm	4
Basilar tip aneurysm	4
Paraclinoid aneurysm	2
Vertebrobasilar junctional aneurysm	1
Total	93

Distribution of Size of neck of Aneurysms

Size of of Aneurysms	No of Aneurysms
2mm – 10mm	81
11mm – 25mm	10
<25mm	2
Total	93

Distribution of Name of Surgery

Name of Surgery	No. of cases
Pterional Craniotomy	80
Contralateral Pterional Craniotomy	3
Retrosigmoid suboccipital approach	2
Frontal Craniotomy	2
Orbitopterional Craniotomy	1
Superciliary mini Craniotomy	1
Bifrontal Craniotomy	1
Total	93

Day of Aneurysm Surgery

Day of Aneurysm Surgery	No of aneurysms
1st day – 3rd day	22
4th – 10th day	43
>11th day	28
Total	93

Distribution of Glasgow outcome scale

Good outcome	No. of cases
1. Return to pre-morbid occupation	50
2. Neurologically normal, not returned to pre-morbid occupation	13
3. Independent, mild neurological deficit	11
Poor outcome	
4. Dependent, significant deficit	05
5. Dead (pre-op 3 cases + post-op 11 cases)	14
Total	93

Distribution of Complications of Aneurysm

Complication	No. of cases
Re-rupture while waiting	13
Post Op. Vasospasm	11
VP shunt	09
Post clip re-rupture	05
EVD done	03
No complications	52

EP-161[Neurovascular Surgery]**CEREBRAL REVASCULARIZATION FOR NEUROSURGICAL DISORDERS: EXPERIENCE IN 9 CASES OF COMPLEX INTRACRANIAL ANEURYSMS**

Tamer Ibrahim Metwally, Tamer Hassan Mohammed, Mohammed El Esawey El Fiki, Mohammed Mohammed El Rhmany

Faculty of medicine, Alexandria University, Neurosurgery department, Egypt

INTRODUCTION - OBJECTIVE: Dealing with complex intracranial aneurysms requires basically different thinking as the original modalities of management either direct surgical clipping or endovascular coiling are usually nonfeasible

METHOD: All patients were subjected to full neurological examination, CT brain, cerebral angiography and balloon test occlusion for ICA aneurysms. All patients needed low flow bypass (single or double STA-MCA bypass) and parent vessel occlusion. Patients were followed clinically (mRs), radiologically (CT, CTA and CTP)

RESULTS: dissecting dorsal carotid (2 cases), large/giant cavernous carotid (2 cases), giant paraclinoid (1 case), large ICA bifurcation 9 1 case), large MCA bifurcation (1 case), complex MCA aneurysm as anterior temporal artery was adherent to the neck of aneurysm (1 case) and enlarged previously clipped PCA aneurysm (1 case). All the cases were treated by extracranial intracranial bypass and parent vessel occlusion. Average bypass duration was 38 minutes and all recipients were M4 branches for anterior circulation cases, endangered anterior temporal artery was bypassed for safe clipping and posterior

temporal artery was the recipient in P2 aneurysm. In 2 cases Intraoperative bypass occlusion was found that revised with good final patency One case showed Dysphasia and Rt hemiparesis, One case showed hemianopia and one case developed meningitis that prevented clinical improvement. The other cases did not show new neurological deficit . One case shows no Obliteration of aneurysm and bypass occlusion, otherwise other cases showed Obliterated aneurysms and patent bypass(s)

CONCLUSIONS: Dealing with complex intracranial aneurysms requires basically different thinking. Always think about safety of parent vessel occlusion

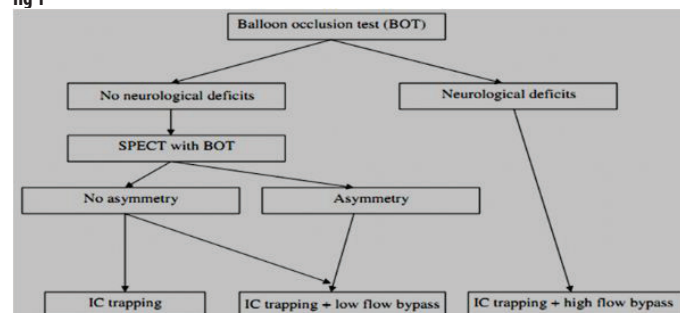
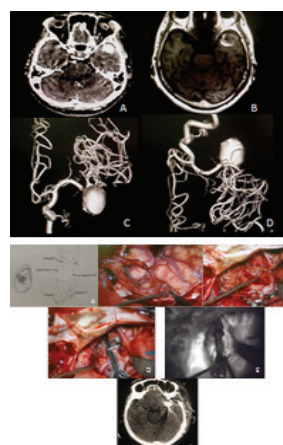
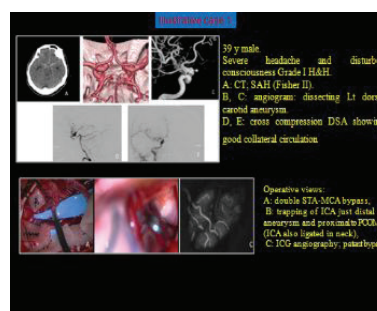
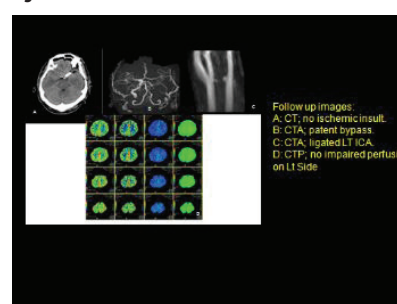
fig 1**fig 2****fig 3****fig 4**

fig 5

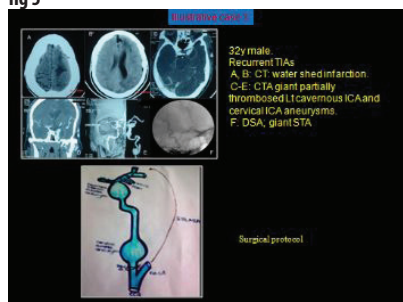


fig 6

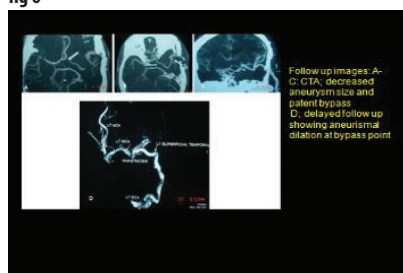
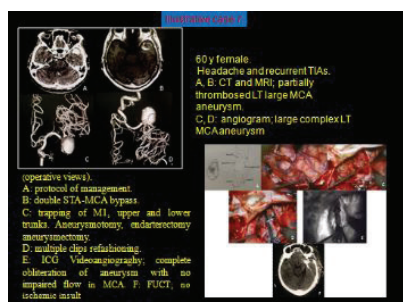

fig 7



master table

Patient	Sex/age	Preoperative TIA or stroke	Aneurysm Location	Microsurgical Approach	Operative Time (min)	Intraoperative Findings	Postoperative Findings
1	M/59	H&H I	Lt dorsal ICA	Dissecting	Double STA-MCA (30 min)	ICA (in neck+ dorsal trapping)	No new deficit, patent bypass, obliterated An.
2	F/75	H&H II	Lt dorsal ICA	Dissecting	Single STA-MCA (35 min)	ICA (in Rt hemiparesis dorsal trapping)	Dysphasia and dorsal patent bypass, obliterated An.
3	M/33		Lt cavernous ICA	Giant	Single STA-MCA (30 min)	ICA (in neck) patent bypass, obliterated An.	No new deficit, patent bypass, obliterated An.
4	F/45	TIAs	Rt paracalcineal ICA	Giant	Single STA-MCA (37 min)	ICA (in neck+ dorsal trapping)	No new deficit, patent bypass, obliterated An.
5	F/45	N	Rt cavernous ICA	Large	Single STA-MCA (32 min)	ICA (in neck) patent bypass, obliterated An.	No new deficit, patent bypass, obliterated An.
6	M/50	Discovered on follow up	Rt ICA bifurcation	Enlarged previously coiled	Double STA-MCA (50 min)	ICA (in neck+ proximal trapping)	No new deficit, patent bypass, obliterated An.
7	F/60	TIAs	Lt MCA bifurcation	Large	Double STA-MCA (40 min)	none	No new deficit, patent bypass, obliterated An.
8	F/38		MCA	Hazard of Ant temporal a	STA and temporal (40 min)	Ant temporal a	No new deficit, patent bypass, obliterated An. Meningitis no

EP-162[Neurovascular Surgery]

POSSIBLE CORRELATIONS BETWEEN HEMODYNAMIC PARAMETERS AND ANEURYSM WALL HISTOLOGY FINDINGS

Peng Hu, Hongqi Zhang, Guilin Li, Chuan He, Xinglong Zhi
Xuanwu hospital, Capital Medical University, Beijing, China

INTRODUCTION - OBJECTIVE: The authors aim to investigate any correlations between computational fluid hemodynamic parameters and aneurysm wall histology finding.

METHOD: Five patients who underwent aneurysm clipping and of whom the aneurysm wall were removed to do histology studies were collected for the current research. The patient-specific aneurysm models were constructed using virtual method, and hemodynamic analysis was conducted with AYSYS CFX 14.0 package. The hemodynamic parameters were then calculated. The aneurysm walls were processed for histology studies to investigate the changes on endothelial layers, smooth muscle cells, internal elastic plate, and any inflammatory cells invasion. The correlations of hemodynamic parameters and aneurysm wall histology changes were analyzed.

RESULTS: The hemodynamic analysis of these five aneurysm models was successfully solved. The endothelial cells vanish, destroyed internal elastic plate, smooth muscle cells reorganization and apoptosis, different inflammatory cells invasion into internal layer were noticed at different part of aneurysm walls. The high wall shear stress (WSS) was found correlating the smooth muscle cells apoptosis and the endothelial cells vanish, while the low WSS was found of correlation with smooth muscle cells reorganization and inflammatory cells invasion into aneurysm walls.

CONCLUSIONS: We supply the initial evidence on the hypothesis that the aneurysm remodeling process was probably introduced by hemodynamic factors. WSS may be one of the factors provoking the histology changes of aneurysm walls and therefore eventually causing the aneurysms rupture.

EP-163[Neurovascular Surgery]

OUTCOMES FOLLOWING PURELY ENDOSCOPIC, EXTENDED ENDONASAL RESECTION OF NON-PITUITARY SUPRASALLER LESIONS: STUDY OF 37 CASES

Shamsul Alam

Department of Neurosurgery, B S M Medical University, Dhaka, Bangladesh

INTRODUCTION - OBJECTIVE: The use of endoscope for the management of non-pituitary suprasellar lesions is not new. The better magnification and illumination provided by the endoscope gives better outcome than microscopic transphenoidal approach. The purpose of the study to find the outcome of endoscopic approaches to different types of non-pituitary suprasellar lesions.

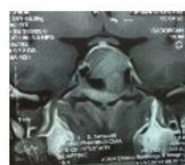
METHOD: We did 37 cases of non-pituitary surgery by endoscopic extended endonasal approach from July 2008 to February 2014. Among them 20 cases of Craniopharyngioma, 12 cases of Tuberculum selle meningioma and 5 cases of Clival Chordoma.

RESULTS: Among 37 cases, male were 15 and female were 22. Ages varies from 10-60 years. Gross total removal was done in 25 cases, subtotal in 6 cases, near total in 4 cases and partial removal was done in 2 cases. Visual improvement was satisfactory. Postoperative visual acuity and visual field was improved or static in almost all cases except 1 case of tuberculum selle meningioma where patient developed blindness following surgery. Temporary D.I. developed in all cases of craniopharyngioma. Over all 6 cases developed meningitis, 3 cases VP Shunt were required, 2 cases of C.S.F. leak, 1 case developed tension pneumocephalus. Electrolyte imbalance developed in all cases of craniopharyngioma. The average duration of follow-up was 12 months.

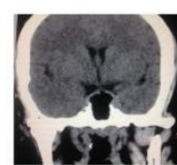
CONCLUSIONS: Endoscopic endonasal pituitary surgery now become a gold standard surgery for most of the suprasellar lesions because of its better advantages in relation to microscopic surgery and less complications and less hospital stay.

Clival Chordoma

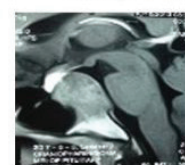
Clival Chordoma



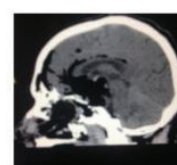
Pre-op



Post-op



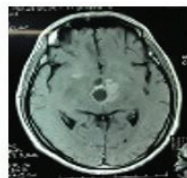
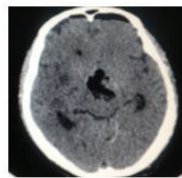
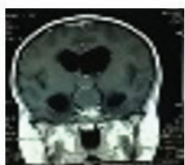
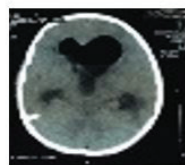
Pre-op



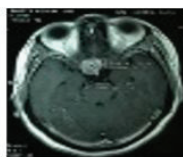
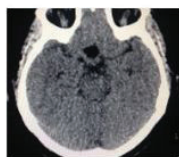
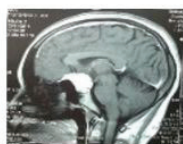
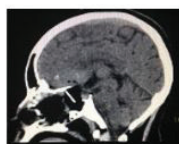Post-op

Craniopharyngioma

Craniopharyngioma

**Pre-op****Post-op****Pre-op****Post-op****Tuberculum selle meningioma**

Tuberculum selle meningioma

**Pre-op****Post-op****Pre-op****Post-op****Extended pituitary**

Extended pituitary	No. of Patient
Craniopharyngioma	20
Tuberculum selle meningioma	12
Clival Chordoma	5
Total	37

Sex

Sex	No. of Patient
Male	15
Female	22
Total	37

Age

Age	No. of Patient
10-20	10
21-30	8
31-40	6
41-50	9
51-60	4
Total	37

Size of tumor

Size of tumor	Number
2-4 mm	30
5-6 mm	5
More than 6mm	2
Total	37

Extent of Removal

Extent of Removal	No. of Patient
Gross total	25
Sub total	6
Near total	4
Partial	2
Total	37

Outcome

Outcome	No of Patients
GOS – 5	26
GOS – 4	9
GOS – 3	2
GOS – 2	0
GOS – 1	0
Total	37

Post op Complications

Complications	No of Patients
Meningitis	6
Morbidity	3
CSF Leak	2
VP Shunt	3
Hyponatremia	1
Pneumocephalus	1
Nil	21
Total	37

EP-165[Neurovascular Surgery]

MANAGEMENT OF ANEURYSM CLIPPING- INSTITUTIONAL EXPERIENCE IN A DEVELOPING COUNTRY

Gulam Mustafa Faisal, Premjit Ray, G Bhaskar, Syed Abdul Jaleel Kirmani, M Sandeep
Department of neurosurgery, ntr university, hyderabad, india

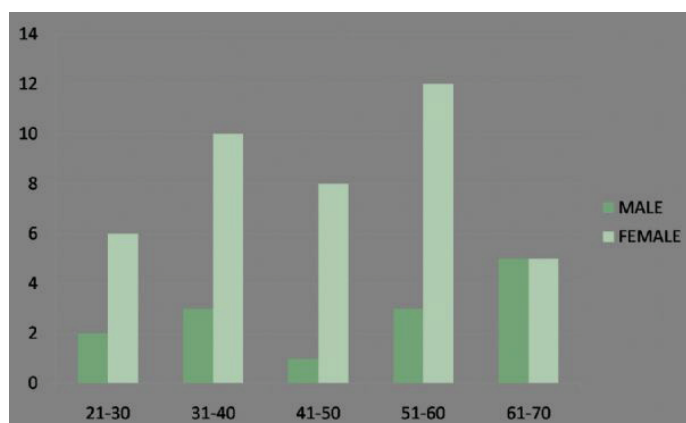
INTRODUCTION - OBJECTIVE: To analyze the clinical data of all the patients who were admitted for cerebral aneurysm clipping. To analyze the outcome of surgery and to assess the factors involved in favorable or unfavorable outcomes in a developing country like India with limited resources

METHOD: Prospective study Period of study: Jan 2010- March 2014. Inclusion criteria: All patients with SAH proved to be due to rupture of saccular aneurysm. Based upon the patient's admission CT the patient is assigned a Fisher grade and upon their neurological status, they are assigned a Hunt-Hess grade. • Outcome was assessed using Glasgow Outcome Scale (GOS) Favorable outcome- as good recovery to moderate disability. GOS 4-5. Unfavorable outcome was death/ vegetative/ severe disability. GOS 1-3.

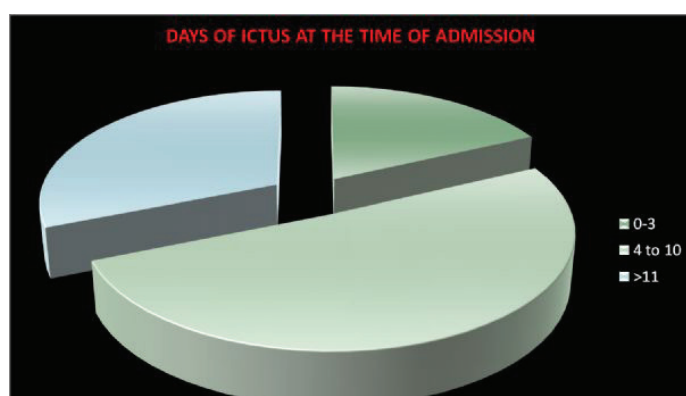
RESULTS: • Peak incidence of aneurysms was seen in 6th decade of life with female preponderance. • 80% of patients reached the hospital at > 4 days after ictus. • Majority of patients were in WFNS Gr 1-2. • Most of the patients were operated in late phase. • Favorable outcome was seen in 72.7% at time of discharge and mortality was 21.8%.

CONCLUSIONS: Patients operated after a delay of > 4 days after ictus did considerably well. Favorable outcome was seen in patients with good grade. Despite limited resources pre & post operatively, the outcome of aneurysm clipping was considerably good.

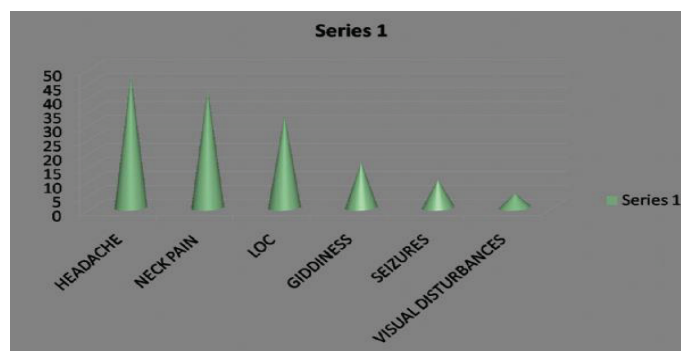
age and sex distribution



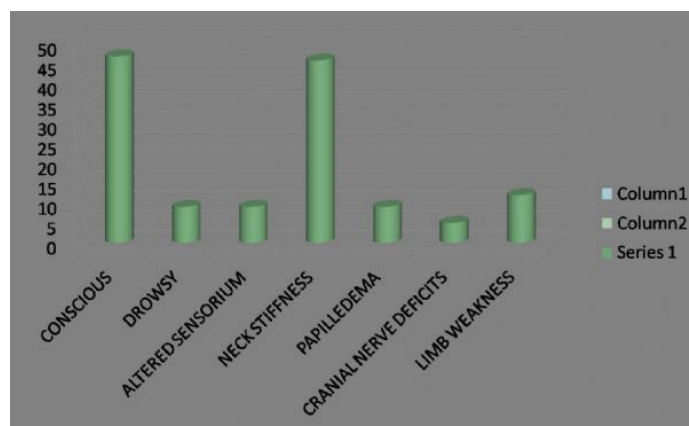
days of ictus at the time of admission



frequency of symptoms



signs



CLINICAL GRADING HUNT-HESS

S. No	Grading at the time of admission	No. of patients	Percentage
1	Gr.I	22	40%
2	Gr.II	18	32%
3	Gr.III	10	18%
4	Gr.IV	5	
5	Gr.V	0	

discharge Glasgow Outcome Scale

Discharge outcome	Number of Patients
1	12
2	0
3	3
4	27
5	13

OUTCOME WITH ANEURYSM SIZE

GOS	< 10 MM	10-25MM	> 25MM
1	4	6	2
2	0	0	0
3	1	2	0
4	7	20	0
5	3	8	2

OUTCOME WITH FISHER GRADE

GOS	Gr.I	Gr.II	Gr.III
1	1	3	8
2	0	0	0
3	0	1	2
4	0	10	17
5	3	8	2

outcome with WFNS

GOS	1	2	3	4	5
1	2	0	0	7	3
2	0	0	0	0	0
3	0	0	1	2	0
4	5	16	2	2	2
5	8	3	0	2	0

EP-166[Neurovascular Surgery]

ENDOVASCULAR TREATMENT OF RUPTURED DISSECTING ANEURYSM INVOLVING THE ORIGIN OF PICA USING NEUROFORM STENT AND COILS – CASE REPORT -

Chul Hoon Chang, Yeoung Jin Jung, Byeong Yeon Choi

Department of Neurosurgery, Yeungnam University, Daegu, Korea

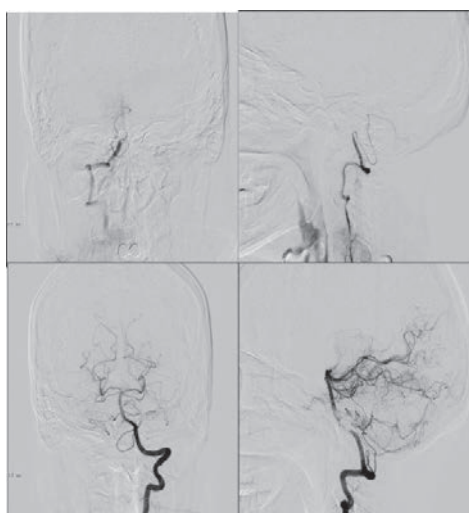
INTRODUCTION - OBJECTIVE: We will report a case of dissecting aneurysm involving the origin of PICA(Posteriorinferior cerebellar artery) treated by endovascular method successfully

METHOD: Case Presentation; 49 years old female patient was admitted via emergency room with chief complain of sudden deterioration of her consciousness level after seizure. On pastmedical history, she had sudden bursting headache two days ago. Initial CT scan showed diffuse subarachnoid hemorrhage and intraventricular hemorrhage. Angiogram revealed dissecting aneurysm on Rt. vertebral artery and the origin of Rt. PICA was in dysplastic segment of Rt. vertebral artery.

RESULTS:She was treated by endovascular method.The weakest point was occluded using coils and dysplastic segment was remodeled with preservation of the origin of Rt. PICA using Neuroform stent. Postoperatively, she had extraventricular drainage. She returned aler consciousness level and had no focal neurological defici . But She had vertigo, intermittently

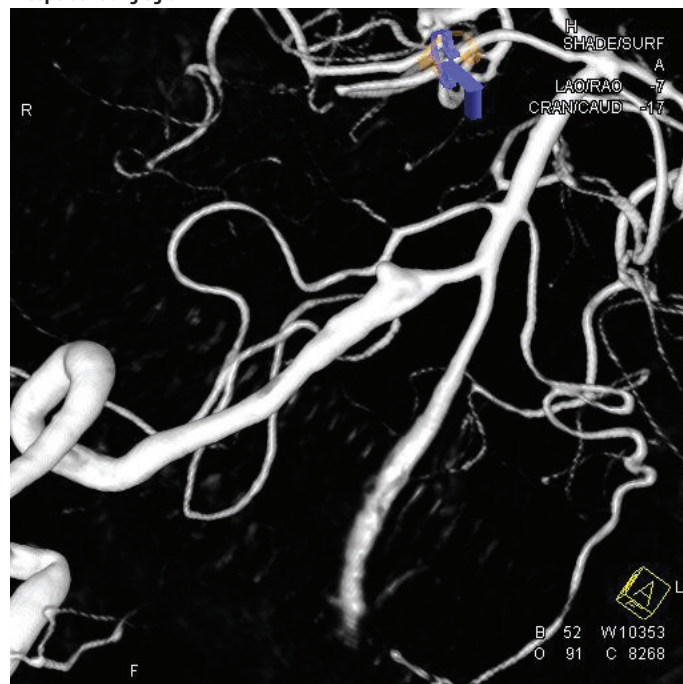
CONCLUSIONS: This method can be a one of the treatment option for the ruptured dissecting aneurysm on vertebral artery involving the origin of PICA.

Postoperative angiogram



dissecting aneurysm was disappeared and Rt-side PICA was preserved. Basilar artery was filled by Lt. vertebral artery.

Preoperative angiogram



3-D-preoperative angiogram showed dissecting aneurysm involving the origin of the PICA on Rt. vertebral artery

EP-167[Neurovascular Surgery]

RESULTS OF SURGICAL TREATMENT OF PATIENTS WITH HYPERTENSIVE INTRACEREBRAL HEMATOMA (HICH)

Kochkor Tolonovich Mendibaev

Department of Neurosurgery National hospital at Ministry of Health of Kyrgyz Republic, Bishkek, Kyrgyzstan

INTRODUCTION - OBJECTIVE: to study results of surgical treatment of patients with HICH depending on timing of the onset of apoplectic attack.

METHOD: We analyzed results of surgical treatment of 25 patients with HICH depending on timing of surgical treatment. Localization of HICH: medial 9, lateral 4, mixed 6, Iobar 6. Patients depending on timing of the operation from the onset of the apoplectic attack were divided into 3 groups. I - group of patients was operated in the first day after the onset of apoplectic attack. II-group of patients was operated from 2 days to 10 days. III-group of patients was operated after 10 days. Results of treatment: surgical results were evaluated one month after surgery on the Glasgow Outcome Scale (GOS).

RESULTS:In group I in all 2 (100%) cases Obtained results GOS 1. In group II of 14 patients GOS 5 had 5 patients, GOS 4 had 3 patients, GOS 3 had 2 patients, GOS 2 had 2 patients, and GOS 1 had 2 patients. In III-group of 9 patients GOS 1 had 5 patients, GOS 2 had 3 patients, and GOS 4 had 1 patient.

CONCLUSIONS: Surgical treatment of HICH most effective on the first day and after 10 days after the apoplectic attack onset. Most poor results of surgical treatment of HICH received between 2 to 10 days after the apoplectic attack onset, this suggests that during this period it is necessary to refrain from surgical treatment to restore autoregulation of cerebral circulation.

EP-168[Neurovascular Surgery] RESULTS OF SURGICAL TREATMENT OF ACUTE ISCHEMIC STROKE IN THE MIDDLE CEREBRAL ARTERY TERRITORY

Aleksandr Kim, Gennadiy Antonov, Valeriy Lazarev, Eduard Miklashevich, Georgiy Mitroshin, Sergey Melnichuk, Stanislav Gladishev, Igor Bogdanovich
Vishnevsky Central Military Hospital, Department of neurovascular surgery, Krasnogorsk, Russia

INTRODUCTION - OBJECTIVE: Identify and justify the optimal diagnostic algorithm and possible tactics of surgical treatment of patients in the acute phase of ischemic stroke in the middle cerebral artery (MCA) territory.

METHOD: In our study were included 129 patients with acute stroke in the MCA territory. The average age was 62 years. Among patients of a male dominated - 113 patients (88%), women - 16 (12%). To assess the adaptive capacities of the vascular system of the brain factor used cerebrovascular reactivity. All of operations were carried out no later than 21 days from the moment of manifestation of the disease. Carotid endarterectomy in 38 patients. The by-pass in 18 cases. Balloon angioplasty with stenting held 20 patients.

RESULTS: Evaluation of the results were conducted in early (1 month), and late post-operative periods. Neurological complications were in 5 cases as form of hyperperfusion syndrome. All these patients had negative reactions on the functional load test with hypercapnia during TCD.

CONCLUSIONS: The likelihood of a favorable outcome of patients in the acute stroke depends on the source of the patient severity condition, as measured by the NIHSS scale and method of treatment. Thus, the maximum positive result is achieved in the group of surgical treatment, if the initial state on a scale NIHSS less than 12 points. Our data also indicate a low risk of reconstructive operations in the acute phase of ischemic stroke, subject to strict diagnostic algorithm, taking into account the adaptive capacities of the vascular system of the brain in the preoperative period.

EP-169[Neurovascular Surgery] MILLARD-GUBLER SYNDROME (MGS) AS A COMPLICATION OF ANEURYSMAL SUBARACHNOID HEMORRHAGE MICROSURGICAL CLIPPING: CASE REPORT

Anas Abdallah, Murad Asiltürk, Betül Güler, Erhan Emel
Bakırköy Research and Training Hospital for Neurology Neurosurgery, and Psychiatry, Department of Neurosurgery, Istanbul, Turkey

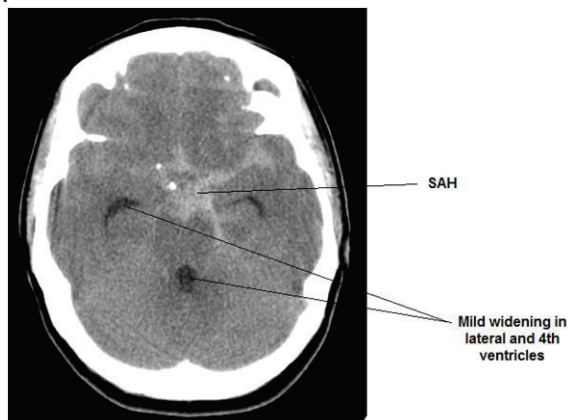
INTRODUCTION - OBJECTIVE: MGS is caused by infarction of the pons. This lesion involves the facial nerve nucleus, the abducent nerve, and the opposite corticospinal tract fiber. The complications of the subarachnoid hemorrhage (SAH) related to adhesions that caused by hemorrhage, the size of hemorrhage that can exert a mass effect, or related to insufficient treatment. This report describes a rare case of MGS as a complication of aneurysmal SAH clipping operation.

METHOD: A 38 year-old female patient presented with severe headache and generalized seizure. Past medical history: 10-15 cigarettes daily. On examination, nuchal rigidity was positive. There was no any neurological deficit. Hunt-hess grade 2. CT: SAH fisher grade 3. After the aneurysm of the left posterior communicating artery was detected, the patient underwent clipping operation.

RESULTS: The patient had no neurological deficits after microsurgical clipping treatment till the postoperative third day when sudden right peripheral facial paralysis so she could not close her eye fully and diplopia in both eyes developed, this was associated with limited outward movement of her right eye and left side hemiparesis which evaluated as 4/5 grade of weakness, i.e, the right (opposite side) MGS.

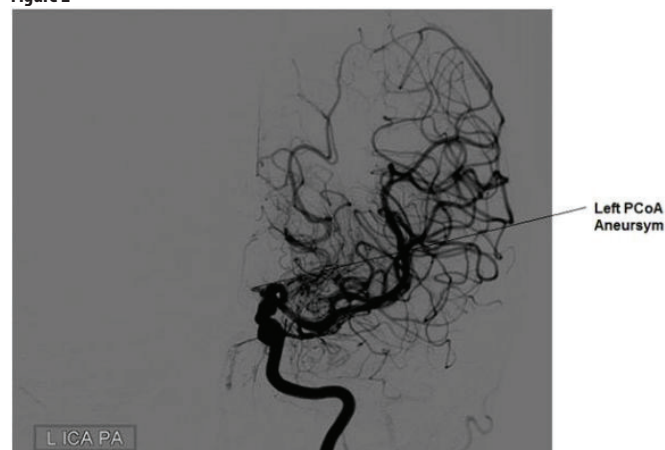
CONCLUSIONS: MGS is usually seen in brainstem tumors, hemorrhage, tuberculoma, parasitic infection, stroke secondary to occlusion of the basilar artery, and brownish softening, as well as secondary to trauma. Up to day, there was no case reported after operation of clipping an aneurysm or aneurysmal SAH like our case, therefore we have to recognize surgery of aneurysm and aneurysmal SAH as causes of MGS.

Figure 1



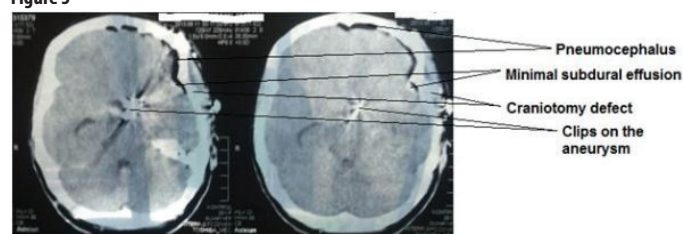
Preoperative CT image of the head was performed. SAH was evaluated as fisher grade 3 and there was a mild widening in fourth and lateral ventricles due to edematous brain.

Figure 2



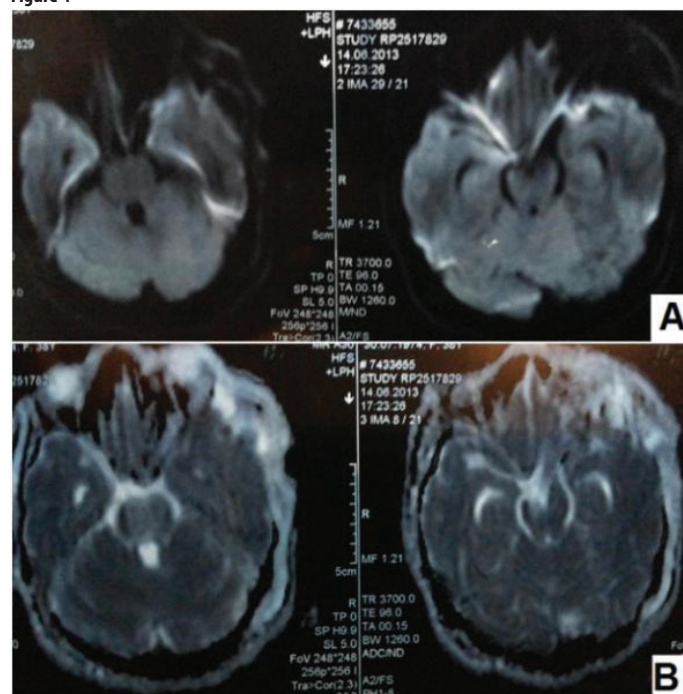
DSA of the patient shows the aneurysm of the left posterior communicating artery.

Figure 3



Postoperative cranial CT that performed 6 hours later after clipping the aneurysm. CT shows clips on the left posterior communicating artery and postoperative changes that happened in the operation field such as pneumocephalus, craniotomy defect and minimal subdural effusion.

Figure 4



Diffusion MRI that performed in the third postoperative day after the MGS of the opposite side clinical symptoms appeared. Diffusion MRI shows no pathological findings that due to MGS; A: Diffusion MR imaging. B: MRI apparent diffusion co-efficient (ADC).

EP-170[Neurovascular Surgery] SURGERY FOR ARTERIOVENOUS MALFORMATIONS

Atul Goel

Seth G.S. Medical College and K.E.M Hospital

INTRODUCTION - OBJECTIVE: Surgery for arteriovenous malformations has a definite, proven and time-tested role in the treatment of arteriovenous malformations. The most important precondition for successful surgery is the selection of an appropriate and the right case.

METHOD: The author will analyze the anatomical and physical characteristics of arteriovenous malformation on the basis of a surgical experience of over 250 cases. The cases of arteriovenous malformation were divided into five grades on the basis of the extent of surgical difficulties that would be encountered during surgery. The grades were 'easy', 'difficult but safe', 'very difficult and risky but possible', 'not safe or possible due to the type of arteriovenous malformation' and 'difficult or risky due to the site of arteriovenous malformation'. The treatment modalities of arteriovenous malformations were divided into six groups namely 'no treatment', 'surgery', 'embolization followed by surgery', 'only embolization' and 'only radiosurgery'.

RESULTS: The factors that determined the extent of surgical difficulties included 'site and eloquence of the area', 'number of feeding territories', 'degree and rate of flow', 'presence of flow-related aneurysms', and the 'physical nature' of the arteriovenous malformation that included the localized, diffuse and multiple nidus.

CONCLUSIONS: The presentation will assess the role of surgery in the present day treatment of these lesions.

EP-171[Neurovascular Surgery] NEUROENDOSCOPIC EVACUATION OF HYPERTENSIVE INTRACEREBRAL AND INTRAVENTRICULAR HEMORRHAGE

Jun Dong

Department of Neurosurgery, 2nd Affiliated Hospital of Suzhou University, Suzhou, China

INTRODUCTION - OBJECTIVE: Some retrospective studies showed no obvious advantages in the conventional microsurgery group vs the medical group for patients suffered from hemorrhagic stroke. Evacuation by endoscopic surgery through a small burr hole is less invasive but is relatively inefficient and unsafe because of poor imaging in hematoma. Modified endoscopic procedures for removing intracerebral hematoma was based on endoscopic skull base techniques and a polypropylene endoscopic sheath. The endoscopic image was produced clearly in air environment with high quality. Image-guided endoscopic evacuation of hypertensive intracerebral hemorrhage were safe, efficient with minimal invasiveness.

METHOD: 39 patients underwent endoscopic evacuation of hypertensive intracerebral and/or intraventricular hemorrhage. The clinical evaluation included pre- and postoperative Glasgow Coma Scale (GCS) score and CT scan, clot removing efficiency, and Glasgow Outcome Scale 6 months later.

RESULTS: Postoperative imaging showed the mean hematoma evacuation rate was 80% 24 hours after surgery. There was 3 intracranial infection and 2 secondary hemorrhage after surgery in all cases. 2 hydrocephalus occurred within 6 months after surgery. All patients were followed up at least for six months. According to the Glasgow Outcome Scale, 9 patients scored excellent, 21 were good, 6 was fair and 3 was poor.

CONCLUSIONS: Neuroendoscopic surgery for intracerebral hematoma with modified instruments is minimally invasive and effective procedure with direct-vision, low complication and mortality. It also produces good neurological outcome and could be a new therapeutic option for hypertensive intracerebral hematomas.

EP-173[Neurovascular Surgery] AN EFFECTIVE METHOD OF FRONTAL SINUS RECONSTRUCTION AFTER BIFRONTAL CRANIOTOMY: EXPERIENCE WITH 88 CONSECUTIVE PATIENTS

Satoru Takeuchi¹, Rokuya Tanikawa², Toshiyuki Tsuboi², Kosumo Noda², Junpei Oda², Shiro Miyata², Nakao Ota², Hiroyasu Kamiyama²

¹Department of Neurosurgery, National Defense Medical College, Saitama, Japan

²Department of Neurosurgery, Teishinkai Hospital, Hokkaido, Japan

INTRODUCTION - OBJECTIVE: Bifrontal craniotomy is effective for the treatment of anterior skull base tumors and anterior cerebral artery aneurysms. However, complications include cerebrospinal fluid leakage and meningitis caused by exposure of frontal sinus (FS) as a result of opening of the covering bone and underlying mucosa. We describe in detail our procedure for sealing exposed FSs during bifrontal craniotomy and present the results and outcomes of the procedure.

METHOD: A prospective review was made of 88 patients who underwent bifrontal craniotomy with reconstruction of the FS using our procedure from November 2010 to February 2014. Our technique is described below. After opening the FS, the mucosal membrane of the FS was dissected from the FS wall and the orifice of the FS mucosa was closed with 7-0 monofilament sutures made in a running manner. At this time, the nasofrontal duct must be kept open by washing thoroughly so as not to leave any bone dust in the FS. And then, the cavity of the FS was packed with abdominal fat.

RESULTS: Of the 88 patients, 59 were female and 29 were male, with an age range from 32 to 90 years (mean, 62 years). The mean follow-up period was 16 months (range: 3-43). Of the 88 patients, cerebral

aneurysm was in 85 (ruptured 16, unruptured 69), arteriovenous fistula was in one, and tumor was in two. One patient (1.1%) suffered intracranial infectious complication.

CONCLUSIONS: The current results indicate the effectiveness of our technique in the prevention of FS-related postoperative complications.

EP-174[Neurovascular Surgery] GIANT AICA ANEURYSM PRESENTING WITH MASS EFFECT AND FOCAL NEUROLOGICAL DEFICIT

Ganesh Kumar Manoharan¹, Raja Annasamy², Jaspreet Singh Dhill², Manoharan Subramanian¹

¹Department of Neurosurgery, Ganesh Priya Hospital, Madurai, India

²Department of Neurosurgery, Adarsha Hospital, Udupi, India

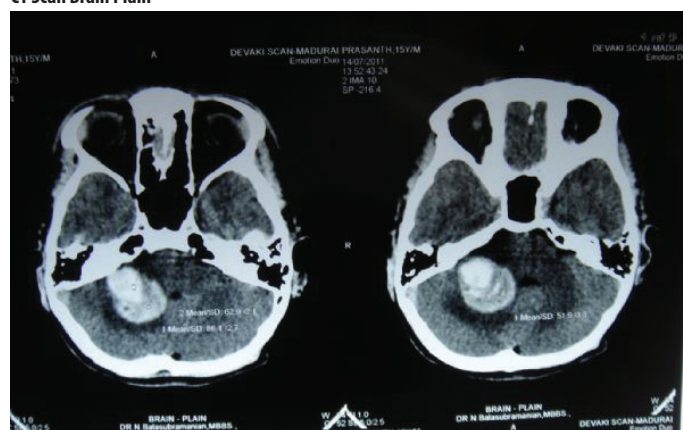INTRODUCTION - OBJECTIVE: Anterior inferior cerebellar artery aneurysms are rare less than 1% of intracranial aneurysms. Giant aneurysms of distal AICA are extremely rare. I present a case of giant AICA Aneurysm to discuss the operative nuances in this extremely rare, surgically challenging lesion.

METHOD: A 14 year old boy presented with headache and ataxia, to our neurosurgery department, clinical examination revealed that he had appendicular cerebellar signs on the right side. An MRI was done that revealed a giant AICA Aneurysm, MR Angiogram and Transfemoral Digital Subtraction Angiogram brain that confirmed a partially thrombosed Giant AICA Aneurysm on the right side. A Retro Mastoid suboccipital craniectomy was performed to approach the lesion and microsurgical clipping and excision of the giant aneurysm was done. Minimal cerebellar contusion noticed at the retractor site that had to be resected.

RESULTS: Post operatively the boy recovered well but had right sided appendicular cerebellar signs, which improved with physiotherapy and came to normal in 3 months. Post op Angiogram was normal.

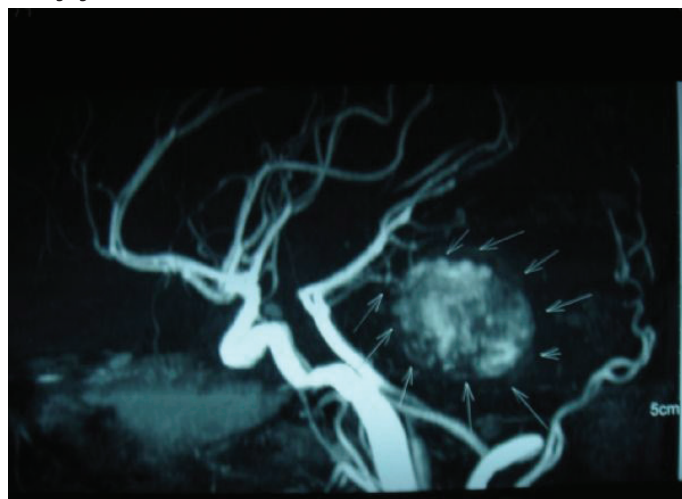CONCLUSIONS: Giant AICA Aneurysm is an extremely rare and can be safely managed, analysis of the collateral vasculature in the angiogram is important. It is advised to excise the lesion after clipping to relieve the patient from neurological deficit.

CT Scan Brain Plain



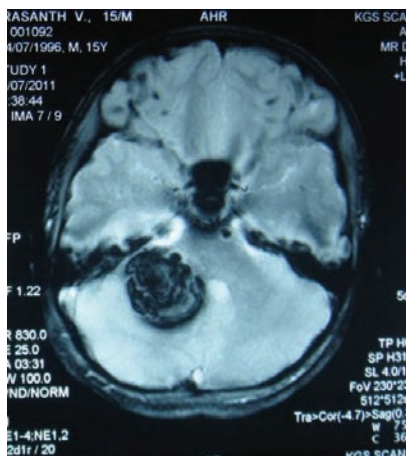
Shows a hyper dense lesion in the right CP Angle

MR Angiogram



MR Angiogram shows the Giant AICA Aneurysm

MRI Brain



Shows the lesion in the right CP Angle that contain blood clot at various stages of clotting... suggestive of partially thrombosed aneurysm

EP-175[Neurovascular Surgery]

MID-TERM POSTOPERATIVE CLINICAL OUTCOMES OF ANEURYSMAL SUBARACHNOID HEMORRHAGE (SAH) MICROSURGICAL CLIPPING: EXPERIENCE OF 274 CASES

Anas Abdallah, Murad Asiltürk, Betül Güler, Hasan Burak Gündüz, Erhan Emel, Mustafa Levent Uysal, Müslüm Güneş, Özden Erhan Sofuoğlu, İlhan Aydın, Rashid Avyasov
Bakırköy Research and Training Hospital for Neurology Neurosurgery, and Psychiatry, Department of Neurosurgery, İstanbul, Turkey

INTRODUCTION - OBJECTIVE: The incidence of SAH is 15 (4-25): 100.000/year. In 85% of cases of spontaneous SAH, the cause is rupture of cerebral aneurysm. In this study microsurgical clipping treatment outcomes of 274 cases have been evaluated.

METHOD: Medical records were retrospectively reviewed in 1014 (502 women and 512 men) cases of spontaneous SAH and only 274 (143 women and 131 men) cases who operated between the years 2011 and 2013 have been evaluated here. Patients surgical outcomes and complications were analysed. All patients underwent a craniotomy then microsurgical clipping all aneurysms had been reached. The aneurysms not appropriate for clipping were warped.

RESULTS: The mean age was 51 (11-82) years. The most common complaint was severe headache (92%). According to localization of the arteries; ACoA (78), MCA (R:39,L:35), ICA (R:11,L:13), PCoA (R:4,L:9), ACA (R:4,L:3), PCA (R:0,L:5), SCA (R:4,L:2) and multiple aneurysms were seen in 67 cases. According to Hunt-Hess scale; (grade 1:39), (grade 2:137), (grade 3:63), (grade 4:26), and (grade 5:9). According to Fisher grade; (grade 1:47), (grade 2:21), (grade 3:33), and (grade 4:173). Mortality rate was 15% (41), morbidity rate was 16.7% (46) and 187 (68.3%) patients were returned to normal their job and daily activities. The complications were hydrocephalus (15), Hematoma (10), CSF leak (6), infarction due to vasospasm (8), seizures (8), and different infections (28).

CONCLUSIONS: After Aneurysmal SAH diagnosis gets ensured we recommend surgical treatment in first 24 hours. We found that rupture of aneurysms located in ICA parafthalmic segments causes high risk of morbidity. Advanced age (>65 years) and high hunt-hess grades of ruptured aneurysms increase mortality rate.

EP-176[Neurovascular Surgery]

BRAINSTEM CAVERNOMAS: SURGICAL MANAGEMENT AND CLINICAL OUTCOME

Ali Ayyad, Firas Hammadi, Martin Glaser, Alf Giese
Department of neurosurgery, Johannes Gutenberg university

INTRODUCTION - OBJECTIVE: Cavernous malformations is one of the major pathologic categories of vascular malformations of the nervous. It affects CNS in 0.4 to 0.9% of the population, and accounts for 8 to 15% of all vascular malformations. In the brainstem (medulla, pons, and midbrain), incidence is estimated to range from 9 to 35%, with a predilection for the pons. The hemorrhage rate of these cavernomas is up to 30 times greater than that of other locations. Due to their anatomy, the hemorrhage is more likely to cause severe neurological deficit.

METHOD: During the period from 1996 till 2013 we have operated on 54 patients with brainstem, they were 28 males 26 females, the age ranged from 17 to 63 years, The most common clinical presentation was cranial nerve deficits and gait disturbances. The surgical approaches were: subtemporal transtentorial in 16, supracerebellar infratentorial median and lateral in 7, transphenoidal transclival 2, transoral transclival 1, retromastoid in 10, telovelar approach in 18 patients

RESULTS: Total excision was achieved in 50 patients. Complications were: Deterioration of neurological status initially in 15 patients 7 of them improved dramatically almost to preop. Status within weeks, Pulmonary embolism in one, wound healing disturbance and infection in one patient

CONCLUSIONS: Brainstem cavernomas represent a formidable treatment challenge because of their

location. Cavernomas can be resected safely with optimal surgical approach microsurgical techniques. Factors that affect the outcome during surgery are preoperative status, size, timing of operation and complete resection. The goal of surgical intervention should be the complete resection of the lesion without any neurological impairment.

EP-177[Neurovascular Surgery]

MID-TERM POSTOPERATIVE CLINICAL OUTCOMES OF INCIDENTAL INTRACRANIAL ANEURYSMS MICROSURGICAL CLIPPING: EVALUATION OF 132 PATIENTS

Anas Abdallah, Murad Asiltürk, Betül Güler, Hasan Burak Gündüz, Rashid Avyasov, Fatih Cesur, Sarper Polat, Abdullah Emre Taçyıldız, Erhan Emel
Bakırköy Research and Training Hospital for Neurology Neurosurgery, and Psychiatry, Department of Neurosurgery, İstanbul, Turkey

INTRODUCTION - OBJECTIVE: The widespread use of MRA and DSA for evaluating nonspecific symptoms (atypical headache, vertigo, dizziness, and the like) and focal neurological symptoms related to cerebrovascular disease has led to increased identification of asymptomatic incidentally discovered unruptured intracranial aneurysms (UIAs). In this study microsurgical clipping treatment outcomes of 132 patients diagnosed as UIAs have been evaluated.

METHOD: Medical records were retrospectively reviewed in 132 (77 women and 55 men) patients who operated between the years 2011 and 2013 have been evaluated. Patients complaints, localization of the aneurysms, pre-postoperative neurological examination, surgical outcomes and complications were analysed. All patients underwent a craniotomy then microsurgical clipping all aneurysms.

RESULTS: The mean age was 49 (17-68) years. The most common complaint was sudden onset of severe headache (62%), followed by vertigo, nausea-vomiting, respectively. According to localization of the arteries; ACoA (34), MCA (R:29,L:19), ICA (R:10,L:14), PCoA (R:0,L:1), ACA (R:1,L:0), PCA (R:0,L:1), and multiple aneurysms were seen in 23 patients. Mortality rate was 3% (4), morbidity rate was 10.6% (14) and 114 (86.4%) patients were returned to normal their job and daily activities. The complications were hydrocephalus (3), Hematoma (3) and CSF leak (2) patients; all of three group patients were surgical treated successfully.

CONCLUSIONS: To reduce operative mortality and morbidity, incidental aneurysm surgery should be the province of the accomplished aneurysm surgeon who has available to him the most modern techniques and equipment. With the clipping of incidental aneurysms, hopefully the number of patients suffering from SAH with its high morbidity and mortality rates can be further reduced.

EP-178[Neurovascular Surgery]

MANAGEMENT OF INTRACRANIAL ANEURYSMS - OUR EXPERIENCE

Sharad S Rajamani
Department of Neurosurgery, Khoula Hospital, Muscat, Oman

INTRODUCTION - OBJECTIVE: Early treatment of aneurysms via a surgical procedure or intervention following an aneurysmal SAH is mandatory with varying concepts of surgical vs endovascular therapy.

METHOD: We analysed our series of aneurysms that were admitted and treated in the department of neurosurgery over a period of 5 years. These patients had all presented with aneurysmal subarachnoid hemorrhage (aSAH) diagnosed by CT angiography.

RESULTS: A total of 156 patients had presented with ruptured aneurysms. Of these patients, 133 were taken up for surgery as the others had presented with hemodynamic instability. 15 of these patients had elevated cardiac enzymes, myocardial bands and regional wall motion abnormalities. Of the 133 patients, 13 of them were taken up for endovascular procedures. The remaining were taken up for surgical intervention. The surgical procedure was performed by a single surgeon over this period of time. We lost ten patients over a one month duration, and another 16 patients with severe neurological deficit. Of the remaining, 27 had mild deficits and had mild neurological deficits and had to be rehabilitated at a different job placement. The remaining 80 patients had returned to their previous jobs. Of these 32 required psychological and psychiatric counselling for changes in behaviour, mood swings, aggression, and short tempered behaviour.

CONCLUSIONS: aSAH is a devastating condition and early aggressive diagnosis and treatment prior to rupture can salvage a large number of our patients as compared to post SAH treatment.

EP-179[Neurovascular Surgery]

MID-TERM POSTOPERATIVE CLINICAL OUTCOMES OF MULTIPLE ANEURYSMS MICROSURGICAL CLIPPING: EVALUATION OF 90 PATIENTS

Anas Abdallah, Murad Asiltürk, Erhan Emel
Bakırköy Research and Training Hospital for Neurology Neurosurgery, and Psychiatry, Department of Neurosurgery, İstanbul, Turkey

INTRODUCTION - OBJECTIVE: The incidence of multiple aneurysm between patients who diagnosed with aneurysm is 15-45%. In this study microsurgical clipping treatment outcomes of 90 patients have been evaluated.

METHOD: Medical records were retrospectively reviewed in 90 (49 women and 41 men) patients who operated between the years 2011 and 2013 have been evaluated. Patients surgical outcomes and complications were analysed. All patients underwent a craniotomy then microsurgical clipping all aneurysms had been reached. The aneurysms not appropriate for clipping were warped.

RESULTS: The mean age was 53.4 (25-82) years. There were 67 patients diagnosed as multiple aneurysms after SAH, and 23 patients were diagnosed incidentally. The most common complaint was severe headache (94%) in SAH group and migraine type headache (60.8%). According to localization of the arteries; ACoA (50), MCA (R:49,L:45), ICA (R:35,L:14), PCoA (R:8,L:4), ACA (R:3,L:3), SCA (1), basilar artery (1), pericallosal (R:3, L:1) and choroidal (1). According to Hunt-Hess scale of SAH group; (grade 1:18), (grade2:38), (grade3:7), (grade4:3), and (grade5:1). According to Fisher grade; (grade 1:0), (grade2:7), (grade3:12), and (grade4:48). Mortality rate was 15.5% (15), morbidity rate was 18.8% (17) and 64.4% (58) patients were returned to normal their job and daily activities. The complications were hydrocephalus(9), Hematoma(2), CSF leak(2), infarction due to vasospasm(2), seizures(2), SSI (1), rhinorrhea (1) and osteomyelitis(1).

CONCLUSIONS: After Aneurysmal SAH diagnosis gets ensured we recommend surgical treatment in first 24 hours. We found that rupture of aneurysms located in ICA parafthalmic segments causes high risk of morbidity. Advanced age and high hunt-hess grades of ruptured aneurysms increase mortality rate.

EP-180[Neurovascular Surgery]

RADICAL RESECTION OF "UNTREATABLE" INTRAMEDULLARY SPINAL ARTERIOVENOUS MALFORMATIONS

Tao Hong, Hongqi Zhang, Xiaoyu Li, Feng Ling

Department of Neurosurgery, Xuanwu Hospital, Beijing, China

INTRODUCTION - OBJECTIVE: Intramedullary spinal arteriovenous malformations (AVMs) with an anterior spinal artery (ASA) contribution are considered difficult to resect or embolize, given their limited surgical exposure and postoperative neurological function impairment. We first introduce the technique of intraoperative digital subtraction angiography (DSA) combined with intra-arterial methylene blue injection angiography to facilitate the complete resection of intramedullary spinal AVMs.

METHOD: 4 consecutive cases of intramedullary spinal AVMs with ASA supply were reviewed between January 2013 and July 2013. Intraoperative segmental artery DSA with the intra-arterial methylene blue injection angiography was performed in all patients. All operative reports, radiographic studies and clinical data were reviewed.

RESULTS: Mean operation time was 435 min. This intraoperative DSA was most helpful to localize the AVM nidus precisely, recognize the remnant after the resection and distinguish the normal vessel with abnormal nidus vessel. Intraoperative methylene blue angiography via the angiographic catheter was useful to quickly recognize the nidus remnant in the operative field. All cases achieved angiographically confirmed complete resection of the nidus after operation. The pre- and post-operative ASIA motor score remained the same after 1 month's follow-up. No angiographic complication was noted.

CONCLUSIONS: Intraoperative DSA combined with methylene blue angiography is an effective technique to achieve the aim of complete resection of intramedullary spinal AVMs with neurological function preservation.

EP-181[Neurovascular Surgery]

COMBINED DIRECT AND INDIRECT REVASCLARIZATION IN TREATMENT OF ISCHEMIC MOYAMOYA DISEASE IN ADULT

He Sheng Xue, Liu Hong Yi, Zou Yuan Jie, Ma Jun Jun, Zhang Yan Song, Huang Qi Jiu, Chen Yong Yan,

Zhang Wen Bin, Liu Yong Yong, Lv Zhu Hai, Liu Xiang Xiang, Luo Zheng Xiang

Department of neurosurgery, Brain hospital affiliated to Nanjing Medical University, Nanjing 210029, China

INTRODUCTION - OBJECTIVE: To make an investigation of the effect of combined direct and indirect revascularization in treatment of ischemic moyamoya disease in adult.

METHOD: Combined superficial temporal artery-middle cerebral artery anastomosis and encephaloduro-myo-synangiosis (EDMS) were performed in 20 adult patients with ischemic moyamoya disease, which were followed up for six months to two years, postoperative outcome was evaluated.

RESULTS: postoperative external carotid angiography at 6 months and 12 months revealed STA-MCA anastomosis was patent in 18 patients, 12 of 18 patients were also patent at 24 months postoperation, extensive development of surgical collaterals through indirect bypass was observed in all patients, the calibers of the STA, MMA and deep temporal artery increased.

CONCLUSIONS: Combined bypass procedures, which include both direct and indirect bypass have the advantage of both procedures. In addition, the STA, dura mater, temporal muscle, and galeal tissue have been used as the pediculate donor tissues in these techniques. We have developed a procedure for combined bypass surgery to supply blood flow over a wide surface of the brain to further improve the long-time prognosis.

EP-182[Neurovascular Surgery]

FLOW DIVERSION TREATMENT WITH DOUBLE STENT IN MULTIPLE BLOOD BLISTER-LIKE ANEURYSMS ASSOCIATED WITH TAKAYASU ARTERITIS

Sook Young Sim

Department of Neurosurgery, Inje University Seoul Paik Hospital, Seoul,

INTRODUCTION - OBJECTIVE: Flow diversion techniques with stent are increasingly used for the

management of wide-neck aneurysm and non-saccular aneurysms. We report our clinical experience of successful treatment with double stent technique in multiple blood blister-like aneurysms at nonbranching sites of the internal carotid artery.

METHOD: A 34-year-old female presented with subarachnoid hemorrhage. Transfemoral cerebral angiography revealed three aneurysms along the supraclinoid nonbranching sites of the internal carotid artery, bilateral subclavian artery occlusion and abdominal aortic aneurysm. Stent overlapping technique was conducted with two Enterprise stent for intracranial aneurysms.

RESULTS: Serial angiographic follow up revealed gradual reduction of blood flow in all of the aneurysms and two blood blister-like aneurysms were completely occluded at 10 month follow up after initial treatment.

CONCLUSIONS: Flow diversion with multiple stent might be another therapeutic option for the complicated aneurysms for which conventional treatments are not feasible.

EP-183[Neurovascular Surgery]

MICROSURGICAL RESECTION OF CEREBRAL ARTERIOVENOUS MALFORMATIONS (AVMs) WITH ZERO MORTALITY

Gopal Raman Sharma

Department of Neurosurgery, NAMS, Bir Hospital, Mahaboudha, Kathmandu, Nepal

INTRODUCTION - OBJECTIVE: Cerebral arteriovenous malformations (AVMs) are one-seventh as common as cerebral aneurysms. 50% of death of patients with cerebral AVMs are due to intracranial hemorrhage. There are different modalities of treatment which include microsurgery, radiosurgery and embolisation. In experienced hands best treatment option is microsurgical resection that usually makes the patient disease free immediately and prevents future bleeding. Aim of this study is to discuss the outcome of microsurgical resection of cerebral AVMs in our institute.

METHOD: Over a period of four years, between November 2009 and July 2013, we performed microsurgical excision of cerebral AVMs on 23 patients at Department of Neurosurgery, Bir Hospital. Follow up period ranged from 8 months to 4 years and outcome was measured by Glasgow Outcome Score.

RESULTS: The male female ratio was 1:0.26 and mean age was 30. 19 patients were presented with intracerebral hematoma (ICH) and four patients with seizure disorder. On cerebral angiogram 2 patients had Spetzler-Martin grade I, 12 patients had grade II, 8 had grade III and 1 had grade IV. 21 AVMs were located supratentorial and 2 infratentorial region. One patient had developed intracerebral hematoma as a postoperative complication. Favorable outcome after surgical excision was achieved in 21 (91.3%), 2 (8.7%) were severely disabled and there was no mortality. This is the largest series of cerebral AVMs surgery produced in Nepal till to date.

CONCLUSIONS: Surgical excision is the best treatment option for cerebral AVMs except giant AVMs which requires multimodality treatment approaches.

EP-184[Neurovascular Surgery]

CRANIOCERVICAL JUNCTION DURAL A-V FISTULA; TREATMENT OPTIONS

Hany Abdelhamid Fikry Eldawoudy¹, Tamer Hasan², Wasem Aziz²

¹Department of neurosurgery, Mansoura university, Mansoura, Egypt

²Department of neurosurgery, Alexandria university, Alexandria, Egypt

INTRODUCTION - OBJECTIVE: Craniocervical junction dural A-V fistula is an unusual condition representing a separate entity between cranial and spinal A-V shunts. This specific disease carries features from both spinal and cranial AVFs. Both endovascular treatment with different embolic materials and open surgical disconnection represent valuable treatment options.

METHOD: Four male patients harbouring craniocervical junction dural AV fistulas were presented to our facility. Ages ranged between 42 and 64 with a mean of 55. Among them, two had SAH and two had progressive quadriplegia. Diagnosis of dAVF was based on CTA, MRA and DSA.

RESULTS: Three patients (75%, 3/4), were treated with endovascular embolization and the remaining one was treated with open surgical disconnection with varix excision. The overall clinical outcomes were good during an average follow-up period of 1 year. In particular, follow-up angiographs performed 6 months later revealed the complete disappearance of dAVF in three patients.

CONCLUSIONS: Endovascular treatment of dAVFs is a valuable option especially in semicomatose patients hemorrhagic presentation. In the presence of venous varix in case of venous hypertension and myelopathy surgical disconnection of the fistula and cord decompression would be the treatment of choice.

EP-185[Neurovascular Surgery]

MANAGEMENT OUTCOME OF SYMPTOMATIC INTRACRANIAL VERTEBRAL ARTERY DISSECTING ANEURYSMS

Dong Jun Lim, Se Hoon Kim, Sung Kon Ha, Jong Il Kim, Bum Jun Kim

Department of Neurosurgery, Ansan Hospital, Korea University Medical Center, Kyunggi-do, South Korea

INTRODUCTION - OBJECTIVE: Vertebral artery dissecting aneurysms (VADA) are challenging disorders for neurosurgeons.

METHOD: Between July 2008 and December 2011, we treated 12 patients for dissecting aneurysms of the intracranial vertebral artery. Eleven were treated by endovascular manipulation, and one was conservatively managed.

RESULTS: Nine patients presented with subarachnoid hemorrhage from the ruptured aneurysm, and three presented with symptoms of abrupt severe headache. No postoperative neurological deficits occurred in patients treated by an endovascular approach. No re-hemorrhage or neurologic symptoms were observed in patients during follow-up.

CONCLUSIONS: The chosen management strategy should be developed according to the patient's clinical

condition and imaging results. Endovascular treatment, which includes several techniques, is the first choice for most patients.

EP-186[Neurovascular Surgery] MANAGEMENT DILEMMAS OF TRAUMATIC ANTERIOR CEREBRAL ARTERY ANEURYSMS: HOW TO CHOOSE?

Ashish Kumar¹, Victor Yang², Peter Howard², Leodante Dacosta²

¹Department of Neurosurgery, Nizams Institute of Medical Sciences, Hyderabad, INDIA

²Division of Neurosurgery, Sunnybrook Health Sciences Centre, University of Toronto, Canada

INTRODUCTION - OBJECTIVE: Traumatic anterior cerebral artery (ACA) pseudoaneurysms are difficult to manage. Difficult diagnosis, delayed presentation and catastrophic end-result usually looms over the overall prognosis of TICAs (Traumatic Intra-Cranial Aneurysms). Clipping or coiling of the aneurysm and/or parent vessel occlusion is the treatment offered. However, surgery and coiling both may be difficult owing to access and parent vessel preservation. Rarely, these aneurysms have to be managed conservatively. **METHOD:** We present 4 such patients of traumatic aneurysms admitted to our center in last 10 months. Three patients had pseudoaneurysms of the distal anterior cerebral artery (DACA) and one had an aneurysm arising from a cortical branch of ACA. Their clinical presentations and management along with outcomes are discussed along with dilemmas associated with them.

RESULTS: Three patients were managed by clipping and coiling while one of them was managed conservatively. The diagnosis was relatively early in three patients while delayed subarachnoid hemorrhage led to diagnosis in the fourth. He was functionally dependent however other three did well. The patient who didn't require any intervention is doing well in the follow up.

CONCLUSIONS: Although the overall prognosis remains grim with high mortality and morbidity rates, both microsurgical and interventional management of these traumatic aneurysms may be useful, if detected early before rupture. Expectant management and surveillance may be required in a select group of patients.

Figure 1

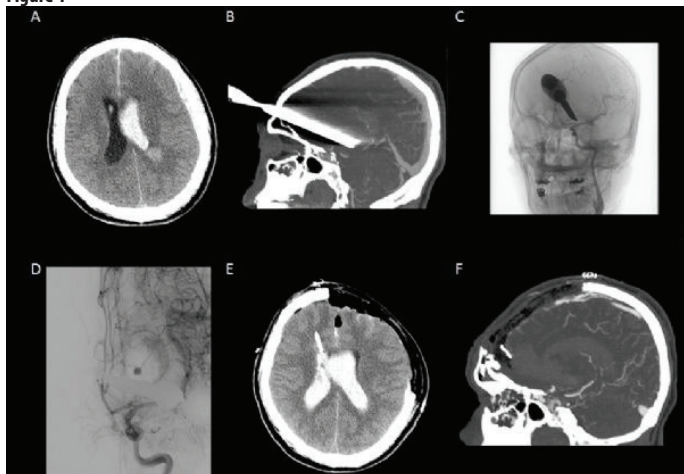
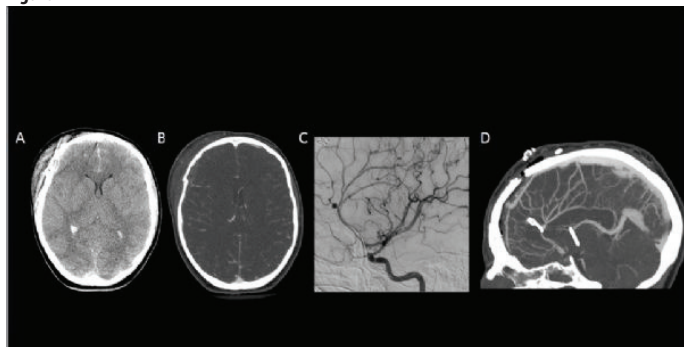


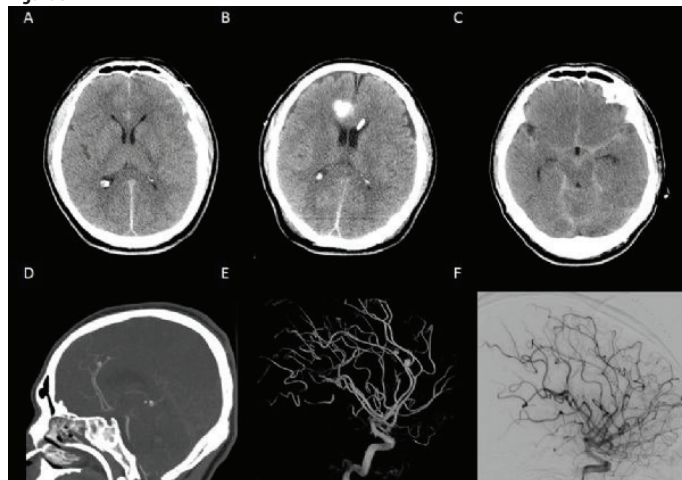
Figure 1: Patient 1: (A, B) CT imaging reveals penetrating body with large IVH in left lateral ventricle with right midline shift. (C, D) DSA imaging shows superficial ACA branch pseudoaneurysm just above the entry site of the penetrating body. (E) Post-op CT shows hematoma expansion. (F) Post-op CTA shows no residual pseudoaneurysm.

Figure 2



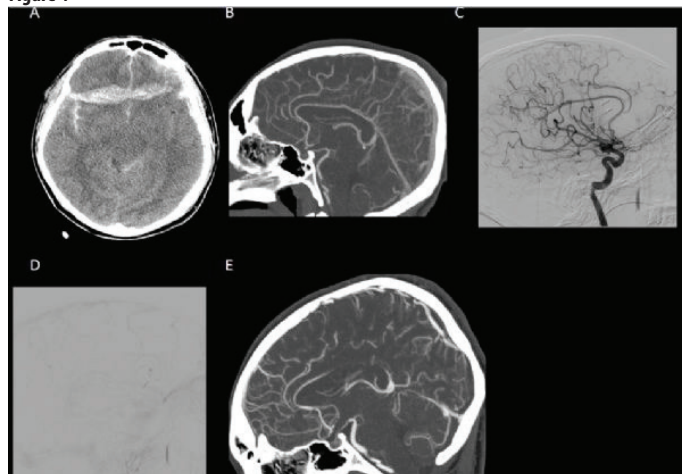
(A) CT findings show hemorragic contusions. (B) Initial CTA negative for pseudoaneurysm. (C) DSA shows pseudoaneurysm arising from left ACA at the origin of the 1st branch of the left callosomarginal artery and very close to the pericallosal vessel. (D) Post-op CTA demonstrates clip with no residual pseudoaneurysm

Figure 3



(A) CT imaging demonstrates left subdural hematomas and a right frontal ICH. (B) Follow-up CT image at 24 hours shows ICH expansion. (C, D) Follow up CT and CTA 1 month post injury shows diffuse SAH, hydrocephalus, IVH, and a pair of pseudoaneurysms related to the pericallosal arteries. (E, F) DSA shows enlarged pseudoaneurysms measuring 6.6 mm and 4.4 mm in diameter and post procedural coiling of the pericallosal artery

Figure 4



CT penetrating injury extending bilaterally within the frontal lobes accompanied by intraparenchymal and subarachnoid hemorrhage. (B) CTA shows bilateral ACA and ACA branch abnormalities and contrast extravasation within the parenchymal hemorrhage. (C, D) DSA confirms a right ACA injury, retrograde A2 segment filling, and small residual traumatic pseudoaneurysm, without proximal arterial access for embolization. (E) Follow up CTA three weeks post injury reveals no residual pseudoaneurysm and persistent vessel occlusion.

Table 1

Serial number	Authors	Artery involved	Age	Delay in diagnosis	Management	Outcome
1	Vin Rong et al. ¹¹ 2013	Pericallosal artery	21 years	5 days	Orise embolization and parent vessel sacrifice	No recurrence, Disabled
2	Kumar et al. ¹² 2013	Pericallosal artery	19 years	None	Orise embolization with parent vessel sacrifice	No recurrence, No deficits
3	Mohamed et al. ¹³ 2012	ACA, ACA segment	26 years	7 days	Clipping and bypass	N/A
4	Venkataram et al. ¹⁴ 2011	Anterior ACA	12 years	3 months	Endovascular obliteration with parent artery preservation	No recurrence after 4 years, Disabled
5	Thakur et al. ¹⁵ 2009	A-cortical artery	43 years	3 weeks	Endovascular obliteration	Moderately Disabled
6	Mohamed et al. ¹⁶ 2009	Distal ACA	18 years	8 months	Orise embolization	No recurrence, No deficits
7	Kim et al. ¹⁷ 2009	Pericallosal artery	7 years	2 weeks	Endovascular obliteration	No recurrence, Good outcome
8	Thakur et al. ¹⁸ 2009	Pericallosal artery	27 years	1 month	Surgical Clipping	No deficits
9	Yang et al. ¹⁹ 2007	ACA	2-46 years	Variable	Endovascular obliteration and clipping trapping	Variable
10	Reza et al. ²⁰ 2007	Orise: marginal artery	18 years	7 days	Surgical Clipping	N/A
11	Kim et al. ²¹ 2007	Pericallosal artery	4 years	1 year	Surgical resection and arterial graft interposition	Good outcome
12	Khalil et al. ²² 2006	Pericallosal artery (Truncus arteriosus)	34 years	None	Surgical clipping	No recurrence, No deficits
13	Colucci et al. ²³ 2003	Pericallosal artery	17, 35 years	10 days, 2 days	Endovascular obliteration with parent vessel preservation	Minor deficits in one patient, 2nd patient died of CVD in 1 year
14	Kim et al. ²⁴ 2004	ACA	3 weeks	8 months	Endovascular obliteration	N/A
15	Kim et al. ²⁵ 2003	ACA	9 months	None	Endovascular obliteration	No recurrence, Good outcome
16	Li et al. ²⁶ 2003	Pericallosal artery	23 years	None	Surgical clipping	No recurrence, No deficits
17	O'Brien et al. ²⁷ 1997	Pericallosal artery	23 years	46 days	Surgical clipping	Mild motor disability
18	Thakur et al. ²⁸ 1994	Pericallosal artery	25 years	9 days	Surgical clipping	Mild motor disability
19	Reza et al. ²⁹ 1991	Pericallosal artery	30 years	8 days	Surgical clipping	Satisfactory
20	Agar et al. ³⁰ 1976	ACA	8 years	23 days, 63 days	Surgical clipping	Unremarkable recovery

Overview of ACA traumatic aneurysms published in the literature and their management

EP-187[Neurovascular Surgery]

SUPRAORBITAL KEY HOLE APPROACH FOR MANAGEMENT OF ANTERIOR CIRCULATION ANEURYSM

Firas Hammadi¹, Elf Giese¹, Philipp Dodier², Ali Ayyad¹¹Mainz University Hospital²Vienna Medical school

INTRODUCTION - OBJECTIVE: The main aim in Surgery is to achieve the greatest therapeutic effect & least iatrogenic injury. The evolution of microsurgical techniques with refined instrumentation and illumination and the enormous development of pre-intraoperative diagnostic tools enable neurosurgeons to treat different lesions through limited and specific keyhole approaches. The concept of keyhole surgery is based on the careful preoperative study of diagnostic images (MRI, CT, Angiography) to determine anatomic windows that provide best access to pathological processes. The special architecture of the anterior fossa offers several anatomic windows to reach deep-seated lesions. However, when the approach is done, the suprasellar anatomic structures are free for surgical dissection and are not hidden by any brain structures.

METHOD: During the period between June 2000 till Dec 2011 we have treated 483 patients with anterior circulation aneurysms: ICA: 144 MCA: 112 ACA: 41 AcomA: 187

RESULTS: The postoperative complications were: 1) permanent partial supraorbital hypesthesia related to a lesion of the supraorbital nerve 12 patients 2) permanent palsy of the frontal muscle related to a lesion of the frontal branch of the facial nerve 10 cases. 3) permanent hyposmia 8 patients 4) wound healing disturbances 5 cases 5) a subcutaneous CSF collection and leak 4 patients

CONCLUSIONS: In our experience, the supraorbital craniotomy allows a wide exposure for deep-seated intracranial areas. The supraorbital craniotomy offers minimal invasive and maximal efficiency with less brain traction, thus contributing to improved postoperative results and shorter hospitalization because of a reduction in the risk of complications, such as bleeding, neurological deterioration, postoperative epilepsy, leakage of CSF, infection. In addition, pleasing cosmetic effect.

EP-188[Neurovascular Surgery]

DIAGNOSIS AND TREATMENT OF INTRACRANIAL CAVERNOMAS: A REPORT OF 40 CASES

Yahiaoui Malika¹, Abzouzi Badra¹, Bouaita Kamel¹, Sahraoui Moahamed¹, Ioualalen Naafa¹, Baba Ahmed Rabea²¹EHS ALI AIT IDIR²CHU B.E.O

INTRODUCTION - OBJECTIVE: Cerebral cavernomas are frequent findings in MRI imaging. The indication for surgery however remains controversial.

METHOD: We compared localization, symptoms and surgical results in 40 patients treated between 2007 and 2013 in our department

RESULTS: 40 patients were diagnosed as cavernomas cases, 21 patients were male and 19 were female, age range was between 12 to 70 years. The most frequent clinical sign was seizures. Bleeding was observed in 5 patients. The cavernomas were solitary in 37 patients. The supratentorial localization was the most frequent. 32 patients were operated: (13 lesions were localized in temporal lobe, 12 were frontals, 4 were parietals, 2 occipitals and 1 lesion was located in the lame tectal). There were 7 patients inoperated (surgical abstention) and 1 patient was treated by radiosurgery. In all operated cases the lesions were totally resected without any mortality. We used a stereotactic guidance and computerized navigation for a minimally invasive surgery.

CONCLUSIONS: Nowadays the navigation technique is used in practice of neurosurgery particularly in deep lesions, especially in cavernomas and in small lesions. The development of several techniques (minimally invasive surgery, neuronavigation, mapping ...) is very useful and necessary for an optimal management of cavernomas with less perioperative risk.

EP-189[Neurovascular Surgery]

SPONTANEOUS CEREBRAL VENOUS SINUS THROMBOSIS. OUR EXPERIENCE IN THE LAST THREE YEARS

Vasileios George Varsos, Athanasios Konstantinos Zisakis, Stauroula Lyra, Christos Kelesis, George Markogianakis, George Hadjigeorgiou, John Mylonakis, George Psilovassilopoulos, Eutykhios Archontakis
Department of Neurosurgery, Red Cross Hospital, Athens Greece

INTRODUCTION - OBJECTIVE: Cerebral venous sinus thrombosis is a rare neuropathological condition, which appears with a prevalence of 3-4 cases in one million population per year. This study aims to present our experience and to compare it with recent literature review.

METHOD: Four cases of cerebral venous sinus thrombosis treated in our department the last three years. In these four cases, 3 were females and 1 was male. All of the cases presented with headaches. In addition, two out of four had dysphasia and one had disorders of vision. All cases underwent computed tomography (CT), magnetic resonance (MRI) and magnetic resonance angiography (MRA).

RESULTS: All the patients' imaging on admission showed an intraparenchymal haematoma, on CT,

which was confirmed by MRI. The MRA revealed cerebral venous sinus thrombosis. The patients underwent anticoagulant treatment with low molecular weight heparin and further medication for the intraparenchymal haematoma. The patients were followed up by MRI-MRA in (1), (3) and (6) months. The follow up of the patients showed an important improvement of the clinical and neurological condition as well as improvement of the neuroimaging.

CONCLUSIONS: Cerebral venous sinus thrombosis is a very rare and peculiar neuropathological condition. Thus, it is a challenge for the neurosurgeon to diagnose and manage these cases, as soon as possible.

EP-190[Neurovascular Surgery]

GIANT SOLID CEREBELLAR HAEMANGIOBLASTOMAS: MANAGEMENT ISSUES

Suresh Nair Narayanan Nair

Sree Chitra Tirunal Institute for Medical Sciences & Technology, Trivandrum

INTRODUCTION - OBJECTIVE: To discuss the management issues of highly vascular giant (>5 cm) solid cerebellar hemangioblastomas and their surgical results.

METHOD: The archived records of 8 patients of highly vascular giant cerebellar hemangioblastomas surgically managed in the department from Jan 1998 to August 2013 were analysed.

RESULTS: Because of their extreme vascularity giant solid cerebellar hemangioblastomas pose considerable surgical challenge and warrant careful pre-operative planning. The study group consisted of 5 males and 3 females. Pre-operative investigations included CT brain, MRI and four vessel cerebral angiography. In two of the patients, the tumor was in an anteromedial location. Three patients underwent pre-operative embolisation. One of the patient with tumor in the anteromedial location underwent surgery under circulatory arrest. All tumors required circumferential dissection after shrinkage with bipolar cautery, coagulation of feeding vessels and intratumoural injection of fibrin glue / cyanoacrylate. Significant bleeding made surgical excision a formidable task in two patients. There was one operative mortality. All the remaining seven patients had good outcome.

CONCLUSIONS: Embolisation of feeding arteries and surgery under circulatory arrest are useful operative adjuncts. Circumferential dissection with shrinking of the tumor volume with bipolar is the key for successful resection

EP-191[Neurovascular Surgery]

RESULTS OF CAROTID ARTERY RECONSTRUCTIVE OPERATIONS IN PATIENTS WITH TRANSFERRED ISCHEMIC STROKE

Adrian Zosim Bodiu, Mihai Iosif Gavriluc, Constanta Dumitru Bodiu, Veronica Gudumac

Laboratory of Neurosurgery, Anesthesiology and Resuscitation, Institute of Neurology and Neurosurgery, Chisinau, R. Moldova

INTRODUCTION - OBJECTIVE: This article aims to analyze carotid arteries reconstructive operations' efficacy performed in 35 patients with occlusive disease of carotid arteries (CA) in patients who have transferred ischemic stroke (IS). We studied carotid artery reconstruction efficacy in patients with transferred ischemic stroke, according to the degree of neurologic deficiency (ND) and the carrying out of operation terms. The study specifies carotid artery reconstruction efficacy in recurrent stroke prevention and after-stroke surgical and neurological rehabilitation.

METHOD: The study deals with cerebral tissue stupefaction phenomenon caused by internal carotid artery stenosis before and after endarterectomy. Carotid endarterectomy was performed in 35 patients who underwent ischemic stroke, selected based on NASCET criteria, after conventional hours of therapeutic window expiration. Following methods were used: neurological examination with sistematization of data according to Barthel and Ashworth indexes, to Fugl Meyer scale, superior and inferior Rivermed scale, investigations (cerebral CT and MRI), carotid vessels' doppler examination, carotid angiography.

RESULTS: Carotid endarterectomy was initially a secondary stroke prevention method, proved to be a good treatment option as well (significant improvement of disability degree in patients who underwent ischemic stroke).

CONCLUSIONS: Study results lead to the conclusion that ischemic cerebral tissue preserves recovery capacity after conventional hours of therapeutic window (stupefaction phenomenon of ischemic cerebral tissue). This is the etiopathogenetic basis of cerebral tissue preconditioning phenomenon, largely described in contemporary scientific medical literature (animal models).

EP-192[Neurovascular Surgery]

SURGICAL MANAGEMENT OF COMPLEX ICA ANEURYSMS - 1 YEAR EXPERIENCE OF 10 CASES

Vamsi Krishna Yerramneni, Aniruddh Kumar Purohit

Nizam's Institute of Medical Sciences, Hyderabad, India

INTRODUCTION - OBJECTIVE: ICA aneurysms are the most common intracranial aneurysms. These may arise from ICA in relation to the origin of ophthalmic segment, superior hypophyseal, posterior communicating, anterior choroidal and bifurcation point. Here we present a single senior surgeon experience with ICA aneurysms operated between 2012 to 2013.

METHOD: Here we present a single senior surgeon experience with ICA aneurysms operated between 2012 to 2013 in the authors institution was analysed from the records. All patients underwent pterional craniotomy and extradural anterior clinoid drilling and opening of the dural rings and clipping of the

aneurysm. one patient underwent ICA, ICA bypass and subsequent trapping of the aneurysm.

RESULTS: All patients were neurologically intact with minimal morbidity and no mortality. 1 patient developed CSF leak and was managed conservatively

CONCLUSIONS: In patients with paraclinoid and also large posterior communicating artery aneurysms extradural clinoid drilling has made a good working space for proximal control and also clipping of the aneurysm. Complex multilobulated aneurysms and those having broad neck are effectively dealt with surgery and clipping

EP-193[Pediatric Neurosurgery]

INTRAOPERATIVE MONITORING DURING SPINA BIFIDA SURGERY COMPLICATED WITH LIPOMA

Igor Aleksandrovich Yugay, Rano Alimjanovna Ismailova, Mahmud Mansurovich Akhmediev, Zera Enverovna Arslanova

Republic Research Center of Neurosurgery, Tashkent, Uzbekistan

INTRODUCTION - OBJECTIVE: Spina bifida with lipoma – complex anomaly of the spinal cord, represents significant surgical problem because of the possibility of severe complications in postoperative period. Aim of the research: evaluate method of intraoperative electrophysiological monitoring during surgery on lipoma with significant adhesion to neural tissue.

METHOD: In our investigation participated 40 patients with spina bifida complicated by lipoma with invasive growth towards nerve roots. Intraoperative electroneuromyography (ENMG) monitoring was used in 19 patients, the rest - without monitoring. Intraoperative ENMG monitoring was done by the use of SYNOPSIS with Neurotech program support in all stages of surgery. Control ENMG was done in 7 days after operation and results were compared in both groups.

RESULTS: Comparison of dynamic ENMG changes in early postoperative period in two groups of patients, made it obvious that results after use of intraoperative ENMG significantly better 38%, as well as without it just 24% ($p < 0.05$). In addition, adverse changes identified in 24% of the core group were significantly lower in expression comparing with control group. In 24% of patients of the main group clinical worsening was identified in 13% of patients and they were temporary. Neurological deficit was persistent and deep in 12% of patients in control group.

CONCLUSIONS: Application of the intraoperative identification of the nerve roots technique during spina bifida surgery with lipoma, can reduce new signs of neurological deficit and avoid of exacerbation already existing neurological disorders in 1.5 times and provides the ability to conduct operations with the utmost radicalism.

EP-194[Pediatric Neurosurgery]

HEMORRHAGIC COMPLICATIONS AFTER SURGICAL RESECTION OF BRAIN TUMORS IN CHILDREN

Akmaljon Mukhamedov, Jamshid Ashrapov, Temur Duschanov

Republican Research centre of neurosurgery, Tashkent, Uzbekistan.

INTRODUCTION - OBJECTIVE: Supratentorial tumors account for 40 to 60% of all intracranial neoplasms in children. Hemorrhagic complications arising in early post-operative period such as bleeding in bed of the tumor, formation of epi - subdural hematomas are occurred in 20-25%, which reduces the quality of life and often results in death. The aim of our study the frequency, risk factors and outcomes of hemorrhagic complications after removal of tumors.

METHOD: We analyzed 46 children treated in our center within 2008-2010. Age ranged from 2-15 years. Distribution of patients according to tumor localization: frontal lobe - 5 (10.8%) patients, temporal - 6 (13%), parietal - 5 (10.8%), occipital - 3 (6.5%), multi-lobular localization - 8 (17.3%), thalamus - 5 (10.8%), optic nerves - 3 (6.5%), III ventricle - 4 (8.6%), lateral ventricles - 4 (8.6%), septum pellucidum - 1 (2.1%). Malignant tumors predominated over benign - 28 (60.8%) and 18 (39.1%), respectively.

RESULTS: At 28 (60.8%) patients tumor removed totally, in 11 (23.9%) - subtotally, 7 (15.2%) - partially. Among 46 patients in 7 (15.2%) were registered hemorrhagic complications, which in 2 (4.3%) cases have been fatal. Hemorrhage in the bed of the tumor occurred in 5 patients (10.8%), the formation of the subdural/epidural hematomas in 2 (4.3%). Postoperative mortality was - 1.2%. Depending on extension of tumor resection, the frequency of bleeding complications increased and in partial removal was more than two times higher than for total and subtotal.

CONCLUSIONS: The frequency of postoperative bleeding complications occurred in 20-25% and mainly depended on extension of tumor resection.

EP-195[Pediatric Neurosurgery]

TETHERED SPINAL CORD SYNDROME

Elgohari Mohamed Elmenshawi

KASR ALAINY SCHOOL OF MEDICINE CAIRO UNIVERSITY

INTRODUCTION - OBJECTIVE: Progressive neurological deterioration localized to lower spinal cord resulting from traction on the conus medullaris has been termed tethered spinal cord syndrome (TSCS) and had been described in children and adults. TSCS is a relatively rare disorder mostly because of a general lack of researches on the disorder, and because the mildest forms may never be detected. Congenital TSCS is initiated by defective closure of the neural tube during embryonic life.

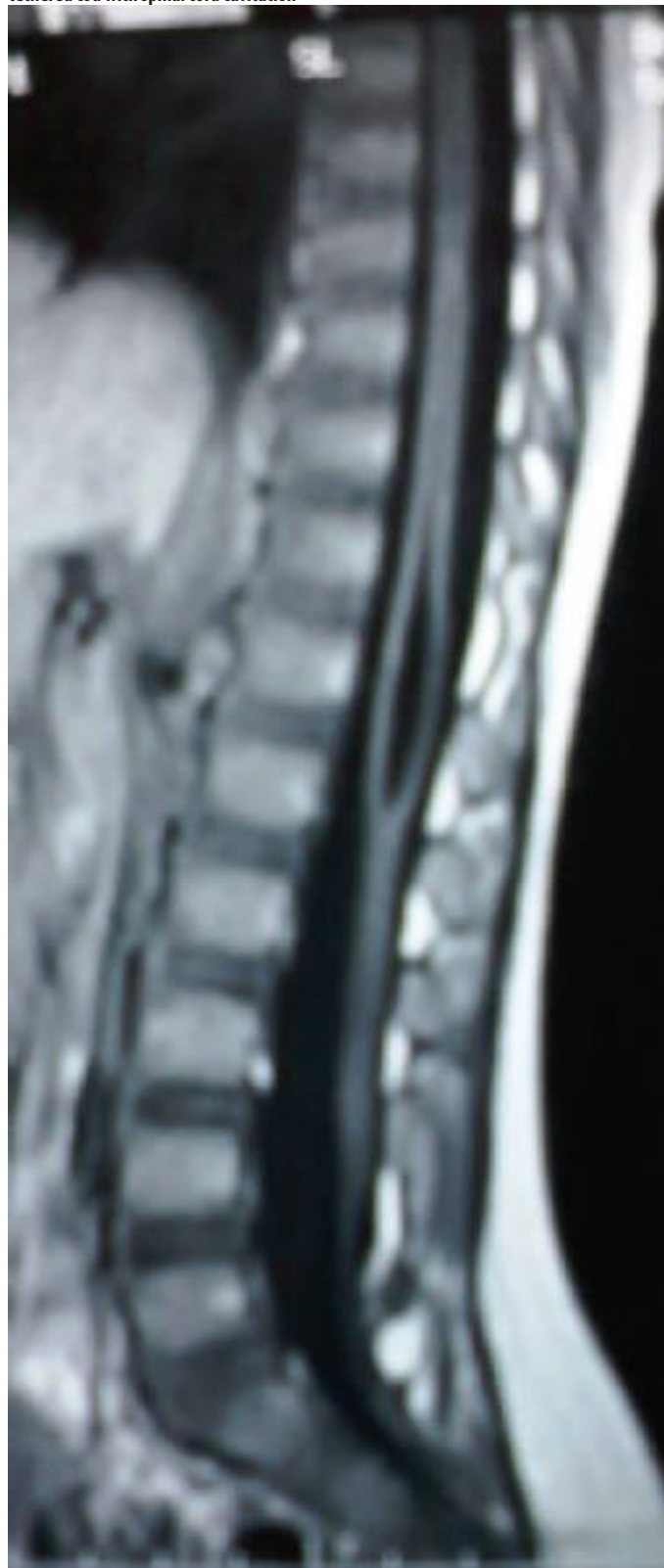
METHOD: METHODS: 15 patients with various types of tethered cord syndrome are presented. Symptoms of TSCS can be visible (foot deformity, scoliosis) or behavioral (incontinence, disturbed gait), signs of TSCS include lipom, angioma, hyperpigmentation and or hairy patches. Early MRI to screen these

patient is an effective diagnostic tool.

RESULTS: Neurosurgeon should keep in mind the possibility of TSCS if any of the symptom and or signs are present. Surgery soon after symptoms emerge appears to improve chances for recovery and can prevent further functional decline produced by the cumulative effect of hyperflexion and hyperextension of the spine during day to day activities.

CONCLUSIONS: If diagnosed and treated early leg weakness and incontinence will improve in children with no progression of symptoms in adults

tethered cord with spinal cord cavitation



ischemia of the spinal cord from tethering can cause cord cavitation

P-196[Pediatric Neurosurgery]

OPEN SPINA BIFIDA PLASTIC ART IN PREMATURE NEWBORNS

Oleg Vladimirovich Volkodav, Svetlana Arturovna Zinchenko Crimean state medical university

INTRODUCTION - OBJECTIVE: The actual task of neonatal neurosurgery is to improve the open spina bifida (OSB) treatment in premature newborns (PN). They are presented myelomeningocele and rachischisis.

METHOD: OSB plastic art method in PN was proposed (Copyright №17679, 21.08.2006., Ukraine), ensures minimal invasiveness, plasticity, functionality and efficiency principles. 25 urgent neurosurgical operations were performed with a minimum weight of newborns 860gramme, gestational age of 26 weeks; in one PN rachischisis Th5-L3. OSB plastic art peculiarities in PN presumes extensive vertebral canal posterior wall defect closing given severe malnutrition soft tissues, rough anatomical structures failure and skin changes with CSF leak prevention.

RESULTS: OSB plastic method includes careful medullar plate selection by the arachnoid crease with the sac contents inspection, spinal cord untethered, skin-fascia flap formation. Follow is the stored hernia sac immersion, medullar plate neurulation, vertebral canal posterior wall reconstruction. Pia-arachnoid membrane fold is formed in the vertebral canal lateral pockets to CSF absorption, spinal blood supply preserve through the pia mater vessels network. Skin-fascia flap have used for shelter - sealing of the hernia gate and vertebral canal, providing plastic reliability and CSF leak prevention.

CONCLUSIONS: This method allows to plastic OSB in PN any forms and sizes with vertebral canal posterior wall reconstruction, minimum risk of bleeding, reliable sealing in conditions of the soft tissue malnutrition, a reduction of the time of surgery and anesthesia.

EP-197[Pediatric Neurosurgery]

SURGICAL TREATMENT OF TETHERED CORD IN THE DISTANT PERIOD OF OPERATED CONGENITAL SPINAL CORD HERNIA IN CHILDREN

Tokhir M Akhmediev¹, Makhmood M Akhmediev²¹Department of Neurosurgery, Tashkent Medical Academy, Tashkent, Uzbekistan²Department of Pediatric Neurosurgery, Republican Scientific Centre of Neurosurgery, Tashkent, Uzbekistan

INTRODUCTION - OBJECTIVE: Despite the improvement in the diagnosis and surgical technique for spinal hernias, the number of complications in the postoperative period remains high. The most common cause of abnormal "fixation" is a seam-adhesive process that develops in the late period of the previously performed operation for congenital spinal hernia of lumbosacral localization.

METHOD: In 80 children with operated congenital spinal hernia, we have marked clinical group of 45 children with the tethered cord. The analysis of MRI determined displacement of the spinal cord on posterior and caudal direction, place of fixation of spinal cord, seam-adhesive process in place from a previous surgery, the residual lipoma, "stretched" and thickened terminal filum, cerebrospinal fluid cyst. We used also EMG with computer system based on software SYNOPSIS Neyrotox (Russia).

RESULTS: Microsurgical intervention technique used in tethered cord. Meningoradiculolysis conducted with the removal of the residual lipoma and epidural seam. During the operation, the phenomenon of migration of the spinal cord in cranial direction was observed on distance of 2.0-4.0 cm. When DM was thinned and perforated plastic materials used which it sheltered to prevent postoperative CSF leakage.

CONCLUSIONS: Thus, the tethered cord disorders characterized by significant EMG dysfunctions, in some cases leading clinical picture, with the possibility of an early diagnosis of subclinical presentation. In the analysis of the postoperative treatment results after 1-4 years in 25% of cases marked regress of neurological symptoms presenting by reduction of paresis in the legs, increase of active movements and the growth of muscle mass in the lower extremities.

EP-198[Pediatric Neurosurgery]

MANAGEMENT OF SPNET IN CHILDREN: A SINGLE-INSTITUTION LONG-TERM RETROSPECTIVE REPORT

Andrii V. Shaverskiy, Yuriy A. Orlov, Pavlo N. Plavskiy, Vadim I. Zybchenko

Institute of neurosurgery named after acad. A.P.Romodanov, NAMSU

INTRODUCTION - OBJECTIVE: A retrospective study of supratentorial primitive neuroectodermal tumors in pediatric patients treated at our institution.

METHOD: Between 1995 and 2011, 73 children with sPNETs were treated at the Institute of Neurosurgery. The patients consisted of 43 (58.9%) male and 30 (41.1%) female children, and the mean age at surgery was 5.5 years (range 1 month – 17 years). 24 (32.9%) cases were infants. In 29 (39.7%) cases tumor was classified as neuroblastoma and in 4 (5.5%) cases - ganglioneuroblastoma.

RESULTS: Total resection was performed in 48 (65.8%) cases, subtotal in 19 (26.0%) cases and partial in 4 (5.5%) cases. Two children had a biopsy. The operative mortality was 5.5%. The presence of tumor cells in the CSF was found in 18 (24.7%) cases, metastasis to other parts of the brain diagnosed in 3 (6.8%) cases and metastases in the spinal cord in 5 (6.8%) cases. Extraneural dissemination in two cases. 57 (82.6%) patients underwent chemotherapy, and 39 (56.5%) patients had radiation therapy. Follow-up data from 1 month to 13 years is available for all patients, average survival rate 31.2 months.

CONCLUSIONS: Supratentorial primitive neuroectodermal tumors in children are relatively rare, and are one of the most malignant brain tumors. Complexity of the surgery, application of radiation therapy and chemotherapy affect the survival rate and overall quality of life of the patient. An aggressive surgical approach is associated with postoperative low mortality and long survival.

EP-199[Pediatric Neurosurgery]

MEDULLOBLASTOMA: A POPULATION-BASED STUDY OF 361 CASES

Andrii V. Shaverskiy, Yuriy A. Orlov, Pavlo N. Plavskiy, Vadim I. Zybchenko, Tat'yana A. Malisheva, Oksana G. Chernenko

Institute of neurosurgery named after acad. A.P.Romodanov, NAMSU

INTRODUCTION - OBJECTIVE: We report a retrospective study of 361 cases of medulloblastoma in pediatric patients treated at our institution in a period of 22 years.

METHOD: Between 1990 and 2011, 361 children with medulloblastoma were treated at the Institute of Neurosurgery. This presented 18.2% of all pediatric brain tumors diagnosed during this time period. 247 were males and 114 females. The main localization was the median line: vermis and 4th ventricle in 86.7% cases.

RESULTS: Complete tumor resection was achieved in 36.8% of the children, and subtotal resection represent in 52% cases, partial in 9.4% and only biopsy was performed in 1.7% cases. Histological diagnosis was as follows: 318 patients had classic medulloblastoma variant, 34 patients had desmoplastic medulloblastoma and the other 9 patients had medulloblastoma with cell differentiation. 83.3% patients underwent craniospinal radiation. 40% children had chemotherapy. Follow-up data from 1 month to 10 years is available for 74.7% patients. The median survival was 18 months and 2- and 5-year survival were 42% and 6%, respectively. Total and near total resection showed no difference in survival outcome. The recurrent rate was 80 (34.3%), second surgery was the first option.

CONCLUSIONS: Medulloblastoma most often occurs within the first decade. They are twice as common in males than in females. Medulloblastoma are midline tumors, most often located in vermis. The outcome for patients with medulloblastoma has been correlation with extend of surgical resection, total removal increased survival time.

EP-200[Pediatric Neurosurgery]

SELECTING THE OPTIMAL METHOD OF TREATMENT FOR CHILDREN WITH HYDROCEPHALUS

Vasily Danilin, German Letyagin, Sergey Kim, Anna Sysoeva

Federal Center of Neurosurgery, Novosibirsk, Russia

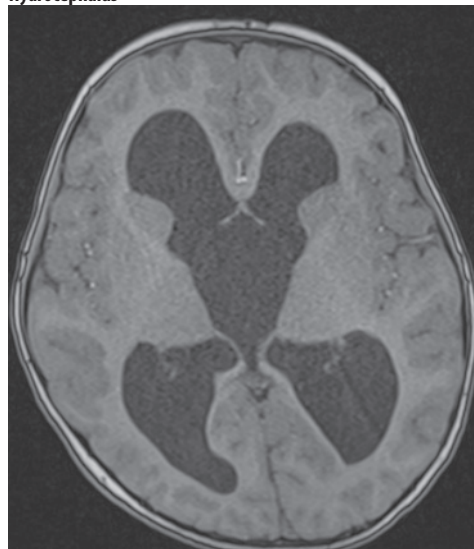
INTRODUCTION - OBJECTIVE: Shunting is the leading method of treating hydrocephalus. This particular method has some significant disadvantages: complexity of shunt selection, shunt-dependency, shunt dysfunction, peritoneal pseudo-cysts and shunt infection. This quite often leads to re-operations. The goal of this study is to observe effectiveness of different methods of treating hydrocephalus for children.

METHOD: The observation includes 176 children from 1 month up to 13 years old, treated in Federal Center of Neurosurgery from December 2012 till February 2014. 43 patients were primary shunted; 27 patients underwent shunt system replacement; 93 patients underwent 3rd-ventriculostomy (ETV); 13 patients underwent endoscopic cyst-ventriculostomy. Patients treated by ETV: 68 patients were primary; 10 patients ETV with removing shunt systems; 11 patients ETV with washing of ventricular cavity in acute period of intraventricular hemorrhage; 4 patients ETV with tumor biopsy.

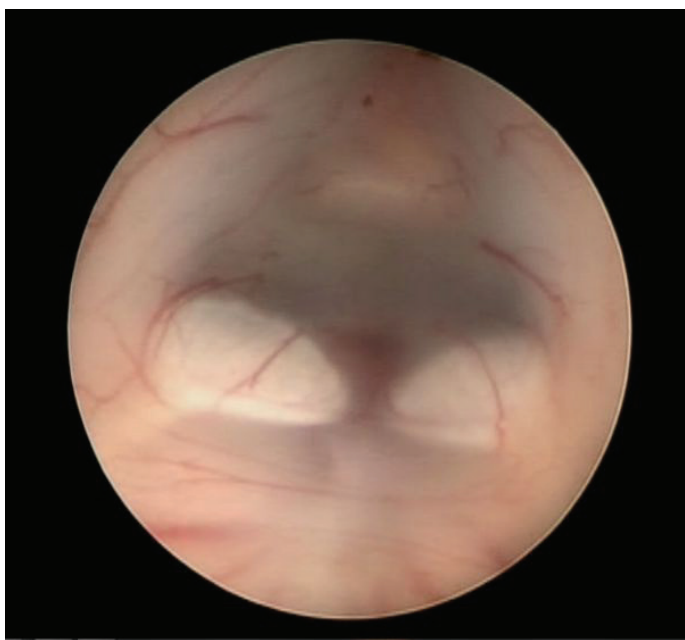
RESULTS: In all cases clinical improvement was observed, proved by MRI data. In seven cases, 1-3 months later after the endoscopy, VP-shunt was placed because of CSF absorption disturbance. Percentage of complications and reoperations in shunting was higher than in the ETV. Lethality has not been observed.

CONCLUSIONS: ETV is highly effective method of treating hydrocephalus, which allows to lower percentage of complications and re-operations. Later observation of this group will allow to estimate long-term effect of operation and prognosis for the children with hydrocephalus.

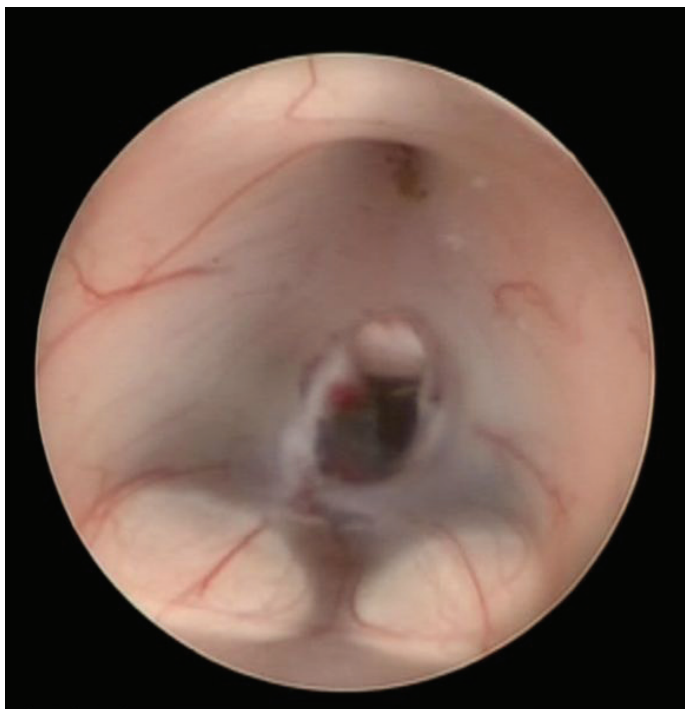
Hydrocephalus



ETV (befor perforation)



ETV (after perforation)



EP-201[Pediatric Neurosurgery] INSERTION OF VAGAL NERVE STIMULATOR IN A LEFT VP SHUNT PATIENT: TECHNICAL NOTE

Mahmoud Taha

Department of neurosurgery, king fahad specialist hospital-Dammam, Saudi arabia

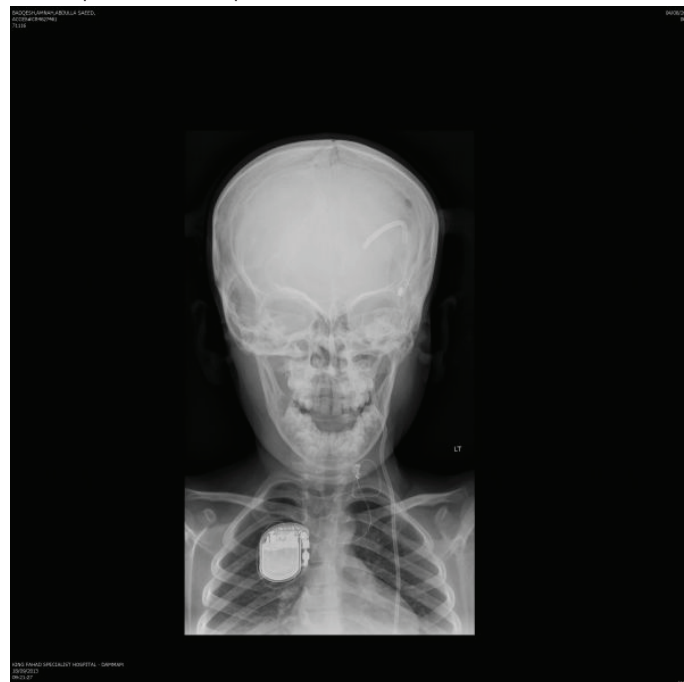INTRODUCTION - OBJECTIVE: Vagal nerve stimulator is indicated in patient with refractory seizures. It is normally inserted in the left side where there are more sensory fibers going to the brain. The generator is normally placed in the subcutaneous tissue in the region of anterior chest wall (below the clavicle) or in the left armpit. A small percentage of the patients with refractory seizures has a right sided VP shunts especially the pediatric group. Insertion VNS is not a major concern in this group of patients.

METHOD: We have dealt with a 4 years old female patient with refractory epilepsy and left sided VP shunt inserted after birth with multiple revisions during the first ear of her life.

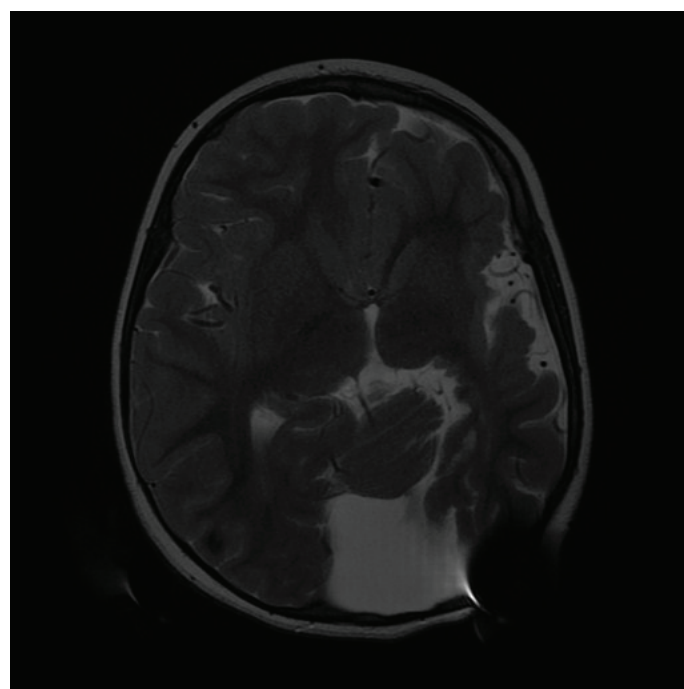
RESULTS: Certain technical points were considered in this **CASE:** The left neck incision was made below the usual site to avoid the contact with the shunting tube. The generator was inserted in the right side of the chest wall to avoid injuring the shunt or the generator in case of future shunt revision. The tunneling

was made in a curved fashion to avoid crossing the larynx or the supra-sternal notch and causing future discomfort. The patient did well after surgery with no problems regarding her shunt or the VNS.

CONCLUSIONS: Special consideration should be taken when inserting VNS in a child with left sided shunt. The technique we used can be adopted for such cases



Plain X-ray after insertion of the VNS showing the left VP shunt and the right-sided generator of the VNS devise.



MRI brain of the patient showing severe left hemispheric cortical dysplasia

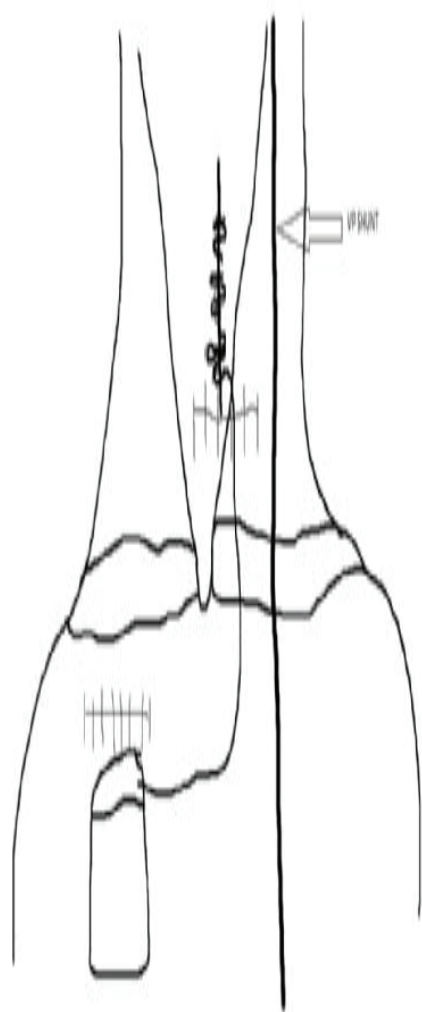
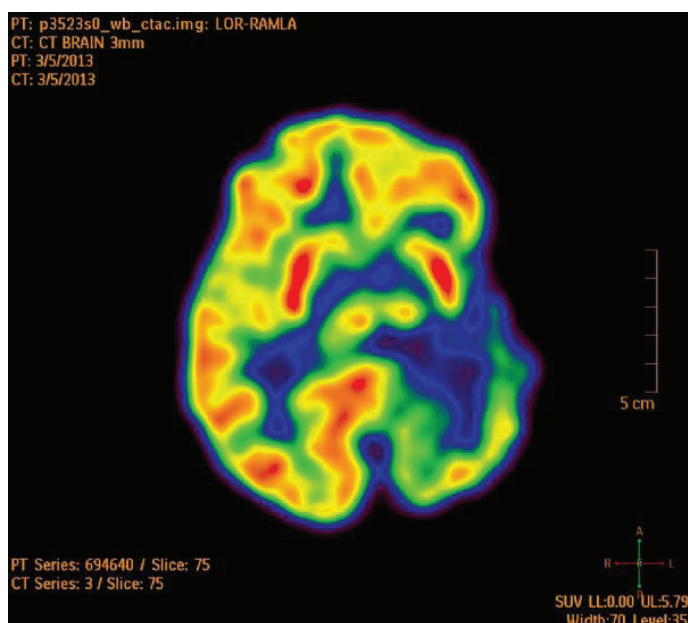


Diagram of the surgical modification.



NM/PET CT 18F-FDG Brain Scan revealed diffuse decrease FDG metabolic rate involving the left hemisphere

EP-202[Pediatric Neurosurgery] THE ANESTHESIA AND PERIOPERATIVE TREATMENT IN CHILDREN WITH CRANIOSYNOSTOSIS

Natalia Anatolievna Kiriek, Vsevolod Vyacheslavovich Luchansky, Eugeny Mikhailovich Karpov
Federal Neurosurgical center, Novosibirsk, Russia

INTRODUCTION - OBJECTIVE: The purpose of the research is to evaluate the efficiency of the preventive blood and plasma transfusion during the craniostomosis operations in children.

METHOD: Methods include the analysis of 10 case histories, in three cases we used the traditional tactics of blood and plasma transfusion after achieving of the standard amount of blood loss, and in seven cases we use preventive tactics, when plasma and blood transfusion began from the very beginning of the surgical procedure. This method, which we call "preventive tactics", includes also: • 1,5 – 2 times enlarged amount of infusion, comparing with the one, calculated by the standard estimation; • analgesia and sedation with the help of dosed infusion of midazolam and trimeperidine; • prolonged mechanical ventilation

RESULTS: The results show that patients from the "preventive" group need less blood transfusions, they had more compensated status of coagulation, less mechanical ventilation and ICU time.

CONCLUSIONS: The conclusion is that the active preventive method of blood and plasma transfusion, inotropic support, sedation and analgesia is more preferable in comparison with the traditional one.

EP-203[Pediatric Neurosurgery] ENDOSCOPIC THIRD VENTRICULOSTOMY (ETV) MY EXPERIENCE

Lasha Bakradze, Lili Chinchaladze, Maka Lortkipanidze
"AVERSI" Clinic, Tbilisi, Georgia

INTRODUCTION - OBJECTIVE: Endoscopic third ventriculostomy (ETV) is a minimally invasive method of treatment of Obstructive hydrocephalus (HCP).

METHOD: To investigate perioperative and intraoperative difficulties, failures and complications of ETV. 56 procedures of ETV were conducted in our department in the last 2 years on 53 patients with HCP of different etiology. In 2 patients we performed ETV twice. In 2 cases we had to repeat the procedure or implant a ventriculo-peritoneal shunt due to recurrence of symptoms.

RESULTS: In our series we had 2 important complications: one thalamic injury and 1 intraventricular hemorrhages. In 3 cases we observed postoperative hyperthermia with the presence of meningeal symptoms. Two cerebrospinal fluid (CSF) leaks were secured with additional stitches and 1 CSF infections were treated with antibiotics. In 1 patient epileptic seizures were observed. Three others complained of nausea and vomiting. The initial success rate of ETV is 84%.

CONCLUSIONS: Based on our material we conclude that ETV is a useful and helpful procedure in non-communicating HCP. It carries 4% perioperative risk of serious complications which can be reduced by proper selection of patients, detailed plan and skilful performance of surgery in experienced hands and meticulous postoperative care.

EP-204[Pediatric Neurosurgery] OPTIMAL METHODS FOR EARLY DIAGNOSIS OF FETAL HYDROCEPHALUS

Galimzhan Mamirbekovich Yelikbayev, Kanatzhau Saukhanbekovich Kemelbekov, Aigerim Aitbayevna Tutayeva
Department of Special Clinical Disciplines, Akhmet Yassawi University, Turkestan, Kazakhstan

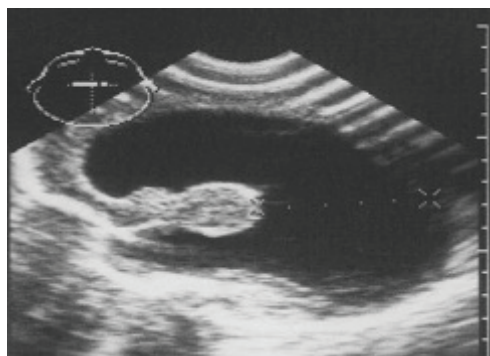
INTRODUCTION - OBJECTIVE: To optimize early diagnosis of fetal hydrocephalus by using introscopy methods.

METHOD: We analyzed the results of a survey of pregnant women in 2012 - 2013, with the purpose of selecting the optimal method in utero early diagnosis of hydrocephalus.

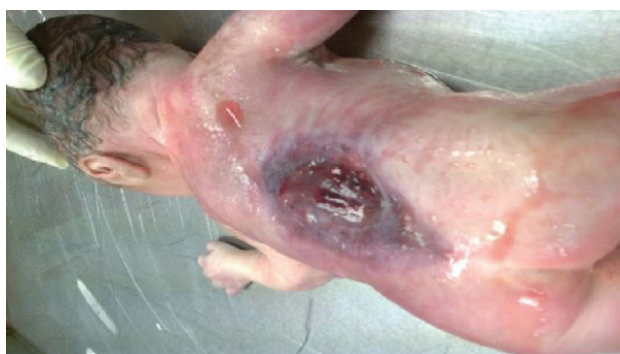RESULTS: Of the surveyed women during pregnancy for the Southern Kazakhstan in 2012 identified 605 (0.97 %) cases with hydrocephalus in utero and in 2013 - 960 (1.4%) cases. During this period, treated 283 children with hydrocephalus in the neurosurgical department of the regional children's hospital in Shymkent. Early diagnosis of progressive hydrocephalus appeared thanks to the introduction into clinical practice of CT, MRI and ultrasound methods, in particular the neurosonography. Neurosonography performed in 150 (53 %) children, CT - 128 (42%), MRI in 14 (5%). In connection with the early detection of developmental abnormalities and increased the number of abortions with malformations incompatible with life: in 2012 - aborted 106 of 149 (71.1 %) for the year 2013 - aborted 140 of 189 (74%). But as practice shows abortion is not always justified, as yet developed guidelines for the doctor tactics detection utero ventriculomegaly and hydrocephalus.

CONCLUSIONS: If you find patients with congenital hydrocephalus in the early stages of the disease is necessary to conduct complex diagnostic examination (neurosonography, MRI or CT of the brain) in order to timely develop appropriate approaches to the treatment strategy.

U.S. baby's brain D., 2 months - progressive hydrocephalus



A child with a spinal hernia (myelomeningocele) and associated hydrocephalus



EP-205[Pediatric Neurosurgery]

RESULTS OF TREATMENT IN CHILDREN WITH NEUROTRAUMA AND NEUROSURGICAL DISEASES IN SOUTH KAZAKHSTAN REGION

Galimzhan Mamirbekovich Yelikbayev¹, Timur Adilovich Begmanov², Kanatshan Saukhanbekovich Kemelbekov¹, Aigerim Aitbayeva Tutayeva¹

¹Department of Special Clinical Disciplines, Akhmet Yassawi University, Turkestan, Kazakhstan

²Regional Children's Clinical Hospital in Shymkent

INTRODUCTION - OBJECTIVE: To analyze the results of treatment of children with neurosurgical diseases and promising ways of development of the service in Southern Kazakhstan.

METHOD: We analyzed the results of examination and treatment of 3907 children from the newborn period to 15 years with neurotrauma and neurosurgical diseases for 2011-2013. Performed 599 operations, including 438 emergency. Surgical activity were 15.3 %.

RESULTS: In South-Kazakhstan region children with craniocerebral injury hospitalized in 2011 were – 89 and 2012 – 888, 2013 were- 996. Over the years, we conducted 98 operations in highly severe craniocerebral injuries. We conducted 95 operations in spinal hernias. Our data show that the best results with disabilities can achieve when performing surgical procedures in the first 48 hours after birth. To address the issue of development of neonatal neurosurgery must provide expensive plastic materials and special devices. Emergency and elective surgery in hydrocephalus performed in 149 children (84emergency, 65planning). In the treatment of hydrocephalus necessary organization with modern medical organizational base and wider implementation in practice of minimally invasive techniques. In scientific terms, requires studies on the features current of hydrocephalus in infants with low birth weight. In the Republican Center for Neurosurgery Portal hospitalization were sent 181 patients, of which the bulk of the children were with volumetric brain formations (49.1%), occlusive hydrocephalus (24.6%), arteriovenous malformations (8.8%) and congenital partial dorsal rahishizis (7.0%).

CONCLUSIONS: Thus, children's neurosurgery in South Kazakhstan region in recent years that significant progress, the decision to allow tasks to improve provided highly specialized care.

EP-207[Pediatric Neurosurgery]

RECURRENT TUMORS OF POSTERIOR CRANIAL FOSSA (PCF) IN CHILDREN

Aleksandr Kim¹, Aleksandr Shapovalov³, Oleg Don¹, Mikhail Kosmachev³, Kirill Poshataev², Von Gi Kim², William Khachatryan¹

¹Department of Pediatric Neurosurgery, Polenov Russian Neurosurgery Research Institute, St. Petersburg, Russia

²Department of Neurology and Neurosurgery FIP and PRS, The Far Eastern State Medical University, Khabarovsk, Russia

³Department of Neurosurgery, Regional Clinical Hospital #2, Khabarovsk, Russia

INTRODUCTION - OBJECTIVE: Estimate efficiency of surgery of PCF's recurrent tumors in children.

METHOD: Recurrent of neuroectodermal tumors (NET) of PCF in period 4 months – 10 years after total removal of primary tumor stated in 81 (23.5%) from 320 patients operated between 1990 and 2010. All patients operated repeatedly. Age range of repeatedly operated patients was from 2 to 18 years. 70 (86.4%) patients operated twice, 7 (8.6%) patients operated thrice, and 4 (5%) patients operated 4-7 times.

RESULTS: Total removal of recurrent tumor performed in 26 (32.1%), subtotal – 39 (48.2%), partial – 16 (19.7%). Within 2 months after operation 2 patients died. In this group appearance or growth of postoperative neurologic deficit is noted in 1/3 cases, cognitive disorders of various severity revealed in 26%. Features of surgery, first of all, were connected with difficulties of definition of localization of cerebellar nucleus in the conditions of its deformation, and also with distribution of neoplastic process on the brainstem and impossibility of definition of eloquent areas of the brainstem. 63 patients with Grade III-IV tumors underwent repeated chemotherapy and radiotherapy.

CONCLUSIONS: The analysis of the non-recurrent period showed interval shortening between repeated operations in process of increase in their frequency rate. The tendency to increase in this interval is noted at blastostatic therapy; however the probability of a total resection of a tumor thus decreases. Informational content of a method of fluorescence, intraoperative mapping of brainstem, evoked potentials monitoring in optimization of surgical tactics of recurrence of NET of PCF is noted.

EP-208[Pediatric Neurosurgery]

LONG-TERM RESULTS OF VENTRICULO-SINUS OPERATIONS FOR TREATMENT OF HYDROCEPHALUS

William Khachatryan

Department of Pediatric Neurosurgery, Polenov Russian Neurosurgery Research Institute, St. Petersburg, Russia

INTRODUCTION - OBJECTIVE: Redundant CSF outflow into the dural sinuses is closer to the natural ways of CSF resorption. In the past century efforts were made to apply these operations. However, these operations didn't find prevalence, while in some cases there were no other choices.

METHOD: A retrospective analysis was done for the results of 98 ventriculo-sinus shunt operations carried out in the period of 1983-2013. These results were compared with the results of 1780 CSF-shunting operations (CSO). The measurement data of ventricular CSF pressure and venous pressure in the superior sagittal sinus-jugular vein system are presented in 46 patients before ventriculo-sinus shunting.

RESULTS: Ventriculo-sinus operations are carried out in 2.7% cases of primary CSO, 7.8% of repeated CSO, and 35.4% of more than 4 repeated CSO. In 38 of 46 patients between the CSF and venous pressures unidirectional and directly proportional correlations existed. CSF shunting into the transverse or sigmoid sinuses proved to be more effective among ventriculo-sinus operations. In the sagittal sinus - jugular vein system venous pressure decreases. Hyperdrainage states observed less frequent in ventriculosinuostomostomy compared with control group. Early occlusion of distal shunt catheter observed somewhat more frequent (up to 12 months after surgery).

CONCLUSIONS: Ventriculosinuostomostomy is the method of choice in the treatment of hydrocephalus, if the use of traditional methods (ventriculoperitoneal, ventriculoatrial shunts) is not possible or feasible. In this operation implantation of a low pressure valve and a pediatric (<1.2 mm) catheter with a low pressure additional valve on its distal end is advisable.

EP-209[Pediatric Neurosurgery]

LARGE CALCIFIED SUBDURAL EMPYEMA - A CASE REPORT

Saumitra Sarkar

Department of Neurosurgery, Mymensingh Medical College, Mymensingh, Bangladesh.

INTRODUCTION - OBJECTIVE: Subdural empyema is a known disease entity; however, calcified subdural empyema is uncommon.

METHOD: The authors present a case of an 11 year old boy in whom there was diagnosed a chronic calcified subdural empyema 10 years after an attack of meningitis. The patient had suffered from generalized tonic clonic seizures occurring 2-6 times in a month.

RESULTS: After a large fronto-temporo-parietal craniotomy, the subdural empyema filled with numerous uncharacteristic tissue fragments with thick pus together with the partially calcified and ossified capsule was removed. No epileptic seizure occurred after surgery.

CONCLUSIONS: we must emphasize the unusual occurrence of the chronic subdural empyema presenting with calcification-ossification and large size as observed in our case.

EP-210[Pediatric Neurosurgery]

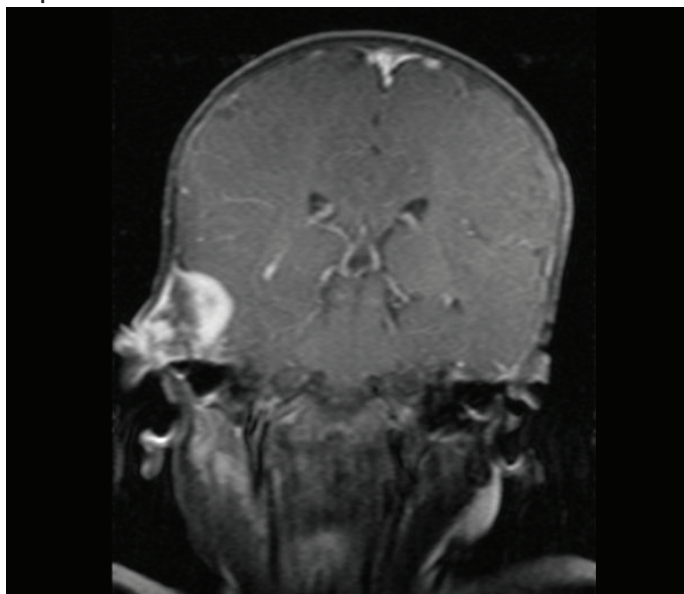
**LOCALLY AGGRESSIVE TUMOR OF THE SKULL IN INFANCY:
A MELANOTIC NEUROECTODERMAL TUMOR**Murat Kocaoglu¹, Selçuk Göçmen², Özkan Çeliker¹, Duygu Çeliker³, Abdullah Topcu¹, Erdal Coşkun¹¹Department of Neurosurgery, Pamukkale University, Denizli, Turkey²Department of Neurosurgery, Private Denizli Surgery Hospital, Denizli, Turkey³Department of Pathology, Pamukkale University, Denizli, Turkey

INTRODUCTION - OBJECTIVE: Melanotic Neuroectodermal Tumour of Infancy (MNTI) occur rare neoplasm of neural crest origin in children during the first year of life. MNTI is a benign tumor but locally aggressive, usually originated from maxilla and mandible. We report a case of MNTI treated surgically and describe clinicopathological and imaging features of this tumor.

METHOD: A 2 month-old infant admitted to head and neck department with a right retro-auricular swelling. Examination revealed a well define, non-tender, non-pulsatile, non ulcerated right retro-auricular swelling. Computed tomography (CT) and magnetic resonance imaging (MRI) showed an extracranial and intracranial lesion with (temporal squama) petrosal ridge bone invasion, underlying dura mater and involvement of tentorium. The tumor was totally resected. Histopathological examination revealed a melanocytic tumor.

RESULTS: Recognition of the diagnostic features of MNTI is important; because they may be differentiate from benign lesions (dermoid, epidermoid cysts, vascular lesions) as well as malignant lesions such as small round cell tumors. A total excision of MNTI is important to prevent a recurrence.

CONCLUSIONS: Even though MNTI is a rare cause of a calvarial tumor in infancy, it should be considered in the differential diagnosis of all patients presenting with head and neck masses. MRI should be performed for a local and aggressive head and neck tumor before the surgery. Although MNTI is considered to be a benign tumor, early diagnosis and aggressive surgery is the essential of these tumors, which extend into the CNS, because of their association with morbidity and mortality.

Preoperative MRI

(MRI) showed an extracranial and intracranial lesion with (temporal squama) petrosal ridge bone invasion, underlying dura mater and involvement of tentorium.

EP-211[Pediatric Neurosurgery]

**A STANDARDIZED PROTOCOL IMPLEMENTATION TO REDUCE
CEREBROSPINAL FLUID SHUNT INFECTION IN DEPARTMENT
OF NEUROSURGERY, HOSPITAL KUALA LUMPUR**Razlinda Zainal Hasnan, Azmi Alias, Mohammed Saffari Mohammed Haspan
Department of Neurosurgery, Hospital Kuala Lumpur, Malaysia

INTRODUCTION - OBJECTIVE: Repeated ventriculoperitoneal shunt failure and infections in pediatric patients (age < 12 years old) lead to significant rate of mortality, morbidity and financial burden to health service. A new standardized shunt protocol was implemented at the Department of Neurosurgery, Hospital Kuala Lumpur following high infection (23%) and poor shunt survival rate (60%) results from a preliminary study conducted in 2009 in our institution. (Ventriculoperitoneal Shunt Among Pediatric Neurosurgical Patient: Infections Rate and 12 Months Survival Outcome).

METHOD: The protocol was prospectively applied to all children (<12 years) undergoing first shunt insertion procedure from 1st January 2010 until 31st December 2010 focusing on 3 contributing factors: 1) timing of surgery, 2) Operation theatre environment and 3) Experience Surgeon. Infections were

defined on the basis of CSF, wound, or pseudocyst cultures; wound breakdown or abdominal pseudocyst. Shunt survival defined as all component of the first inserted ventriculoperitoneal shunt remained intact after 12 months follow up.

RESULTS: The study showed implementation of the protocol for shunt surgery has significantly reduced the risk of shunt complication from 40.6% to 34.8% with reduction of shunt infection of 81.1% (from 22.8% to 4.3%). Following this encouraging results, the protocol and the outcome of VP shunt among children were continuously audited and monitored.

CONCLUSIONS: The concerted quality improvement initiative made by Neurosurgical Department, Hospital Kuala Lumpur by implementation of the new standardized protocol for shunt surgery and continuous audit among children has resulted in reduction of shunt complications and shunt infections.

EP-212[Pediatric Neurosurgery]

**SURGICAL TREATMENT OF COMPLICATED FORMS OF HYDROCEPHALUS
USING ENDOSCOPY AND ULTRASOUND NEURONAVIGATION**Albert Akramovich Sufianov, Iurii Alekseevich Iakimov, Alexandr Anatolievich Belik
Federal center of neurosurgery, Tyumen, Russia

INTRODUCTION - OBJECTIVE: There is a big problem endoscopy in complicated forms of hydrocephalus, which is accompanied by altered anatomy, the poor visibility through the endoscope, etc.

METHOD: We analyzed 64 patients with complicated forms of hydrocephalus who underwent endoscopic third ventriculostomy, endoscopic fenestration of cysts, VPS, aqueductoplasty and/or stenting aqueduct, plasty of Magendie and Lyushka and/or stenting Magendie. All patients were operated using endoscopic technique (rigid and semirigid endoscopes, flexible fiberscopes, flexible videoscope) and neuronavigation techniques. Follow up period was 2.3 years.

RESULTS: All patients had surgery without intraoperative complications and mortality. Success of the operation in the immediate postoperative period was 95.4%, in the long term 84.4%. In the near period the complications after surgery was (4.6%) due to ventricular catheter dysfunction syndrome fused with and disorders of CSF resorption. In the long-term complications after surgery were 15.6% and are associated with reoperation, remote disorders, CSF shunting system dysfunction. Using ultrasonic neuronavigation allows carrying out planning of the surgical operation and implementation of safe equipment operation based on intraoperative intracranial changes. In all cases, preoperative planning and the use of ultrasound neuronavigation allowing precise orientation and holding instruments and an endoscope to determine the place of fenestration, stent placement and trajectory of movement of a rigid and/or flexible endoscope.

CONCLUSIONS: Surgical treatment of complicated forms of hydrocephalus using endoscopy and ultrasound neuronavigation is a safe method of treatment. Necessary to implement these methods in neurosurgical centers, where traditionally widely engaged in the treatment of hydrocephalus.

EP-213[Pediatric Neurosurgery]

**CONGENITAL CNS ANOMALIES: SOCIO-ECONOMIC MANAGEMENT
PERSPECTIVES IN A DEVELOPING COUNTRY LIKE BANGLADESH**Asifur Rahman Bijou
Bangabandhu Sheikh Mujib Medical University

INTRODUCTION - OBJECTIVE: To try to find out discovery to alleviate the agony of babies with congenital CNS anomalies and their parents as well as the society.

METHOD: In the developing world the people are neither that literate nor that affluent to meet the requirements to face these problems appropriately. Moreover the health systems are not up to the mark to confront the condition suitably. These congenital anomalies of the CNS frequently cause severe physical, emotional and financial suffering for both the child and the family as well as for the society.

RESULTS: With recent advances whether diagnosed prenatally or postnatally, in practice it may be very difficult to choose the best option, considering the available facilities, medico-legal issues, religious and social taboos and economic status. During the postnatal period it is more difficult for the parents to manage the child in a country like ours, mainly because of their economic constraints and this remains one of the biggest issues in health sector in a developing country like Bangladesh, either because of the clinical condition of the baby or because of the financial constraints of the parents to bear the cost of surgery, management of complications and rehabilitation. The journey to success still remains a tragic one.

CONCLUSIONS: We feel that, we should concentrate more on prevention than to cure and try to lower the incidence. Once we can successfully develop different strategies aiming prevention, we can truly help the unfortunate babies, parents and our country economically as well as morally.

EP-214[Pediatric Neurosurgery]
**MULTIPLE NEURAL TUBE DEFECTS IN A NEWBORN
WITH NO NEUROLOGICAL DEFICIT**

Senem Alkan Özdemir¹, Nail Özdemir², Volkan Murat Ünal², Esra Arun Özer¹

¹Department of Neonatology, Tepecik Research and Training Hospital, İzmir, Turkey

²Department of Neurosurgery, Tepecik Research and Training Hospital, İzmir, Turkey

INTRODUCTION - OBJECTIVE: The presence of meningocele and/or encephalocele at multiple (two or more) sites along the vertebral axis is a very rare occurring in < 1% of cases. The occurrence of multiple neural tube defects (NTDs) contradicts the traditional "zipper model" of neural tube closure and favors Van Allen's "multi-site closure model". The aim of this article is to report our case and discuss matters revolving the theory of multi-site closure.

METHOD: We are reporting a rare case of multiple NTDs in a newborn with no neurological deficit. Occipital encephalocele, lumbar meningocele and type 1 split cord malformation were present in this patient.

RESULTS: Surgery was performed in two-stages in the same prone position. A 3x3 cm meningocele was explored and excised. A bony spur was identified along the course of the split cord in this region and this spur was excised. Then, 2x2 cm occipital encephalocele was excised. Postoperative course was uneventful.

CONCLUSIONS: Multiple NTDs in the same patient has been reported very rarely in the literature. Split cord malformation with meningocele and/or encephalocele is only one case has been reported in the literature. We report the second case of the split cord malformation with meningocele and encephalocele.

Figure 1

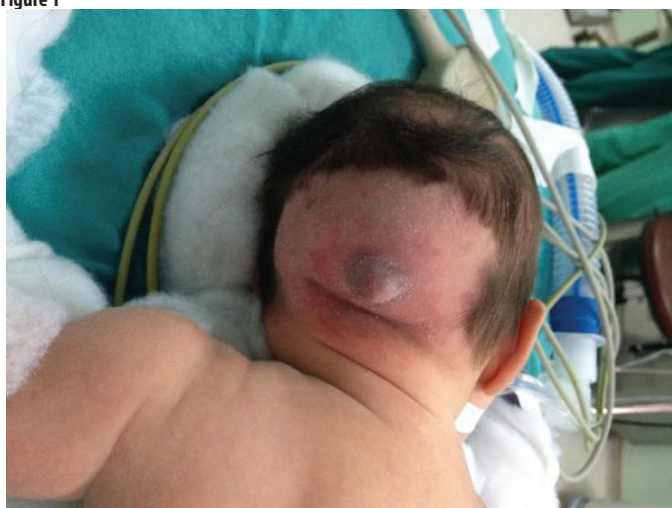


Figure 2

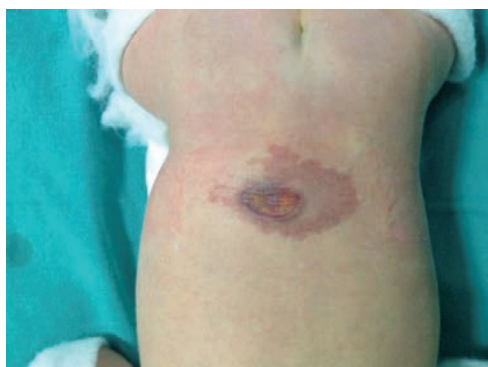

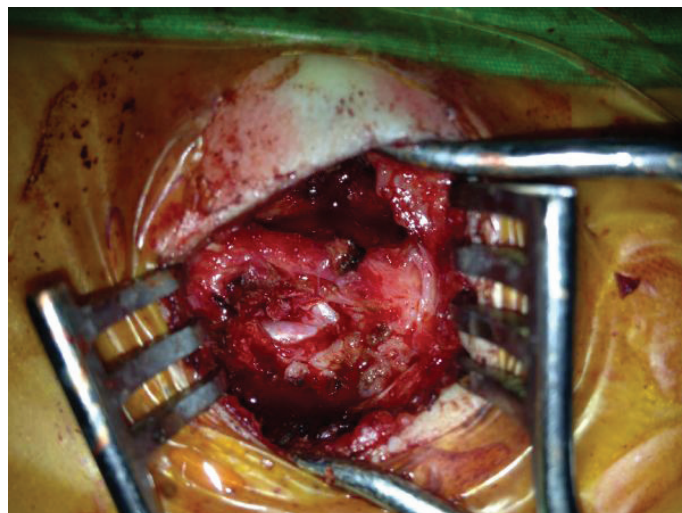
Figure 3

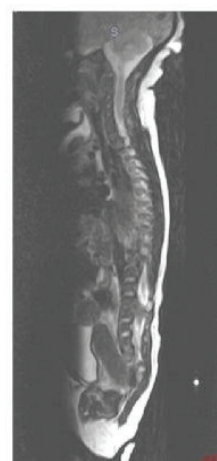

Figure 4



Figure 5



EP-215[Pediatric Neurosurgery]

INTRAOSSEOUS MENINGIOMA MIMICKING OSTEOSARCOMA IN A CHILD

Brahim Eljebbouri, Mohcine Salami, Brahim El Mostarchid

Department of Neurosurgery Mohamed V Military Teaching Hospital Rabat, University of Mohamed V Souissi. Rabat Morocco

INTRODUCTION - OBJECTIVE: Intaosseous meningiomas (IM) are the one of the less frequent benign tumors of the skull. The etiology of IM has not been cleared yet. The frontoparietal and orbital regions are the most common locations for IM. The average age for IM diagnosis is 50.5.

METHOD: A 9-year-old boy with a frontal mass was referred to our hospital. Cranial CT revealed a mass lesion which resulted in expansion in the anterior frontal bone, having lytic and sclerotic regions inside with accompanying irregular cortex in inner and outer tables of the calvarium

RESULTS: Prediagnosis was osteosarcoma according to the imaging studies and after the performed biopsy and consecutive surgery, the lesion was diagnosed as IM. Though CT with bone windows is often useful, it is not always diagnostic.

CONCLUSIONS: Biopsy plays an important role in calvarial vault lesions for planning the treatment. In our case, malignant criteria in radiology did not match the benign histology revealed. Radiological preoperative misdiagnosis of meningioma is possible.

EP-216[Pediatric Neurosurgery]

A BOY WITH ARACHNOID CYST, A FALL, AND TEMPORARY AND REVERSIBLE VISUAL IMPAIRMENT

Ram Kumar Menon¹, Knut Wester²¹Elite Mission Hospital, Thrissur, Kerala, India²Department of Clinical Medicine K1 university of Bergen and Department of Neurosurgery, Haukeland university hospital, Bergen, Norway

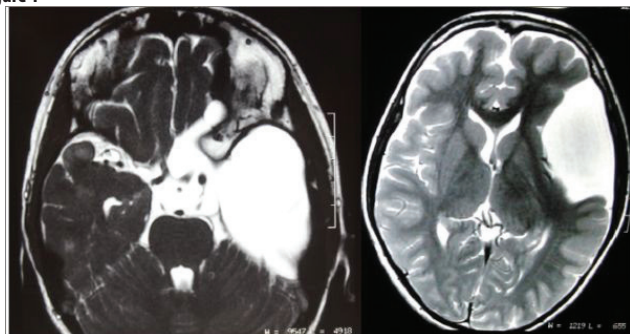
INTRODUCTION - OBJECTIVE: In this case report we describe a boy with a left temporal arachnoid cyst with a sudden onset of visual impairment four days after a mild head trauma. A perimetry revealed a complete nasal hemianopia of the left eye, which normalized rapidly after an emergency craniotomy with cyst fenestration 3 hours after he experienced the reduced vision.

METHOD: This 13 year old child underwent emergency craniotomy and the vision recovered 3 hours after surgery though he experienced transient diplopia.

RESULTS: Case reports indicate that arachnoid cyst also may affect cranial nerves in the posterior fossa, causing symptoms such as vertigo/dizziness and hearing loss or facial palsy. Most likely, these symptoms are caused by direct pressure from the cyst on the cranial nerves or the stretching of them. Most of these case studies report recovery of the impaired functions after cyst decompression. Arachnoid cysts with a para- or suprasellar location may affect the optic chiasm directly; however to our knowledge temporal cysts have never been shown to affect vision.


CONCLUSIONS: The present case indicates that vision may be affected by temporal cysts impinging on the optic nerve or chiasm. Whether this is the case also for symptomatic AC not causing subjective visual deficit, remains to be seen. It is likely that small visual field deficits in one eye will not be easily detected by the patient. We therefore suggest a prospective study with pre- and postoperative perimetry in AC patients

Figure 1



Preoperative MRI (t2) showing a left-sided temporal arachnoid cyst (Galassi type 2 & 3 (40). Left: basal scan showing an extension of the cyst cavity medial to and surrounding the left optic nerve. Right: a more cranial scan showing compression of the ipsilateral ventricle.

Figure 2



Perimetry recordings from the left eye (the right eye had normal vision). Left: immediately preoperative; middle: 16 hours after surgical cyst decompression; right: one month after cyst decompression.

EP-217[Pediatric Neurosurgery]

THE STUDY OF EVALUATING THE THERAPEUTIC EFFECT OF ENDOSCOPIC THIRD VENTRICULOSTOMY FOR PEDIATRIC HYDROCEPHALUS

Zhiqiang Hu, Feng Guan, Hui Huang, Guangtong Zhu, Beibei Mao

Department of Neurosurgery, Beijing Shijitan Hospital, Capital Medical University, Beijing, China

INTRODUCTION - OBJECTIVE: The goal of this study was to validate the proposed Endoscopic Third Ventriculostomy Success Score (ETVSS), which predicts successful ETV outcomes for hydrocephalus on the basis of children's individual characteristics.

METHOD: We compared actual successful rate of 121 cases who were in the neurosurgery department of Beijing Shijitan Hospital from June.2007 to June.2010 at both 6 and 24 months, with Chi-square test and the 95% confidence interval for low, moderate, and high chance of success strata based on the ETVSS. Long-term successful probabilities were calculated using Kaplan-Meier methods.

RESULTS: The 6-month ETV successful rate was higher than the mean predicted probabilities of success for both moderate and low success strata, but slightly lower for the high chance of success strata. The ETVSS accurately predicted outcomes at 24 months; the low, medium, and high chance of success strata had actual success of 74%(37/50), 62%(28/45), and 41%(11/26), and mean predicted successful probabilities of 81.3%, 61.4%, and 34.4%, respectively.

CONCLUSIONS: The ETVSS closely predicted the overall long-term successful rates in high-, moderate-, and low-risk groups. The result of this study suggest that the ETVSS will aid clinical decision making in predicting therapeutic effect of ETV.

EP-218[Pediatric Neurosurgery]

A NEWBORN WITH CERVICAL MENINGOMYELOCELE

Senem Alkan Özdemir¹, Nail Özdemir², Volkan Murat Ünal², Esra Arun Özer¹¹Department of Neonatology, Tepecik Research and Training Hospital, İzmir, Turkey²Department of Neurosurgery, Tepecik Research and Training Hospital, İzmir, Turkey

INTRODUCTION - OBJECTIVE: Spinal dysraphism is a well-known congenital anomaly in neonatology practise. Unlike, the more common thoracolumbar and lumbosacral spina bifida cystica, which has an estimated incidence of 1-2 per 1000 live births. Cervical meningomyelocele is an extremely rare condition, accounting for only 3 to 8% of all cases of spina bifida cystica. The aim of this case report is discussing of different subtypes, clinical characteristics, associated malformations, surgical strategy and prognosis with cervical meningomyelocele.

METHOD: A 27-year-old pregnant woman for delivery was caesarean section, which was performed at term. Apgar scores were 6/8 at 1 and 5 minute, respectively. He has respiratory distress after birth. The neonate was noted to have a 5*5 cm midline purplish soft tissue mass in the posterior midcervical region with dystrophic skin. The newborn had no neurological deficit. Spinal and cranial magnetic resonance imaging demonstrated cervical meningomyelocele, hydrocephalus and Chiari 2 malformation. Three dimensions of computed tomography of the spine revealed a hemivertebrae and rotoscoliosis of the cervicothoracic junction.

RESULTS: Meningomyelocele and hydrocephalus were surgically treated with good cosmetic results and satisfactory neurologic outcome.

CONCLUSIONS: Meningomyelocele of the cervical region differ clinically and structurally from thoracolumbar and lumbosacral meningomyelocele. The prognosis of cervical meningomyelocele is favorable as compared with that of patients with other locations of meningomyelocele.

Figure 1

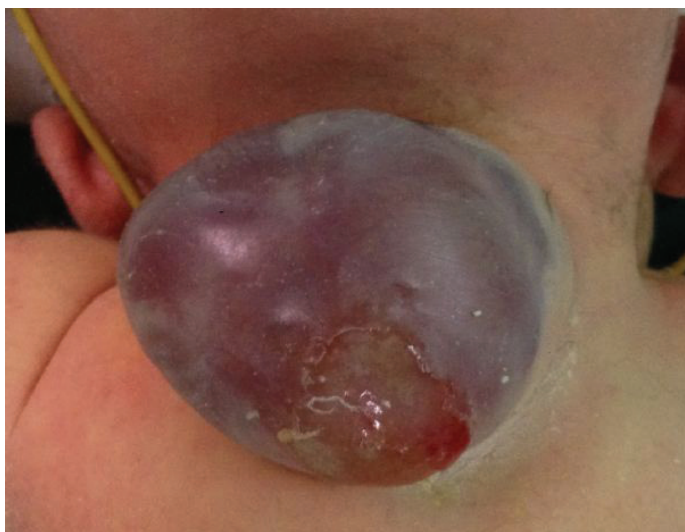

Figure 4

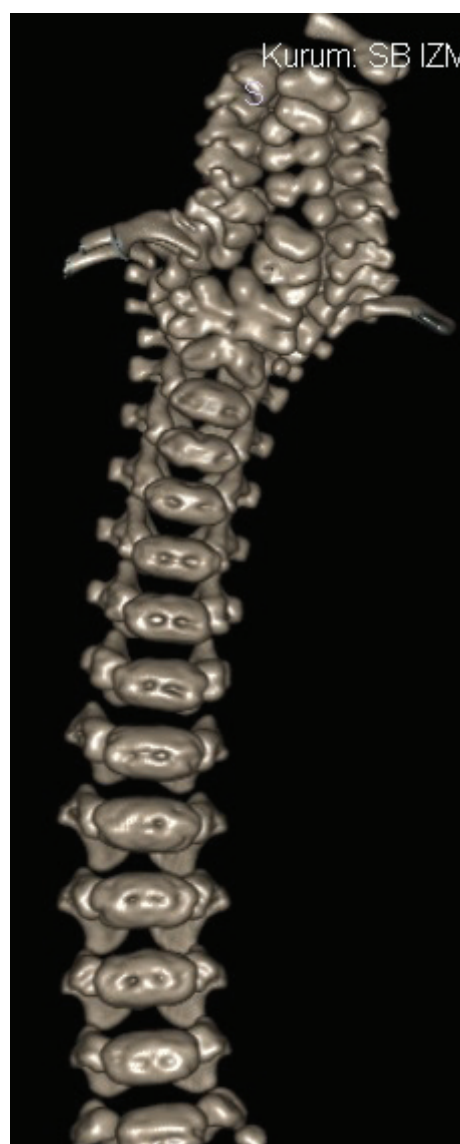


Figure 2

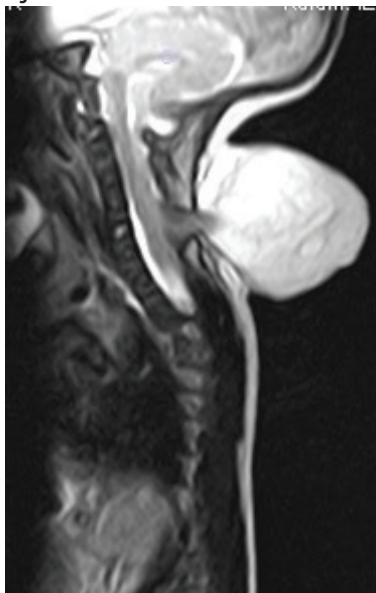

Figure 3

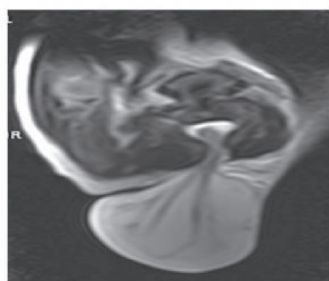
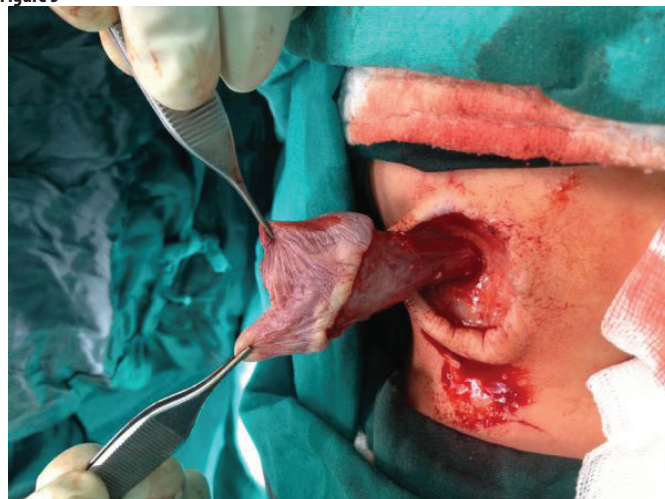

Figure 5



EP-219[Pediatric Neurosurgery]

CONGENITAL THECAL SAC DEFECT TERMINATED IN THE SKIN AT L2-3: CASE REPORT

Anas Abdallah¹, Akin Gökçedağ², Erhan Emel¹, Melih Üçer¹, Betül Güler¹, Akin Öztürk¹, İlhan Aydın¹

¹Bakırköy Research and Training Hospital for Neurology Neurosurgery, and Psychiatry, Department of Neurosurgery, İstanbul, Turkey

²Kanuni Sultan Süleyman Research and Training Hospital, Department of Neurosurgery, İstanbul, Turkey

INTRODUCTION - OBJECTIVE: Meningomyeloceles are the most common congenital anomaly of the central nervous system that account for 98% of open spinal dysraphisms. This report describes a rare case of thecal sac congenital defect that terminated in the child at L2-3 level.

METHOD: A 20 month-old male child was born with the meningomyelocele. At 11th day of life, he had been treated by repairing the thecal sac and closing the skin at the L5-S1 level while at the L3 level

he had a swelling sac which was covered with hairy patch. To avoid the complication may be occurred, the swelling at L2-3 had not been included the surgical procedure. On his 20-month control child was neurological intact. PE: the hypertrichosis and swelling in the back. The urodynamic study demonstrated residue in the bladder after urination. MRI did not prove if there is a neural structure or not in the swelling at L2-3

RESULTS: Intraoperative neurophysiological monitoring was performed. The paramedian vertical midline between L1 to L5 was performed. To avoid cut or incise any neural structure maybe in this swelling the lamina of L2 was found and L2-3 laminotomy was performed. The spina bifida of L3 and L4 were seen, while the thecal sac was terminated in the skin at L2-3 level. Duraplasty was performed. L2, 3 and 4 laminaplasty were performed.

CONCLUSIONS: Laminaplasty and neurophysiological monitoring is essential in children who undergo spinal surgery. More investigations such as urodynamic studies have done in children with meningomyelocele especially those of hairy tufts.

Figure 1

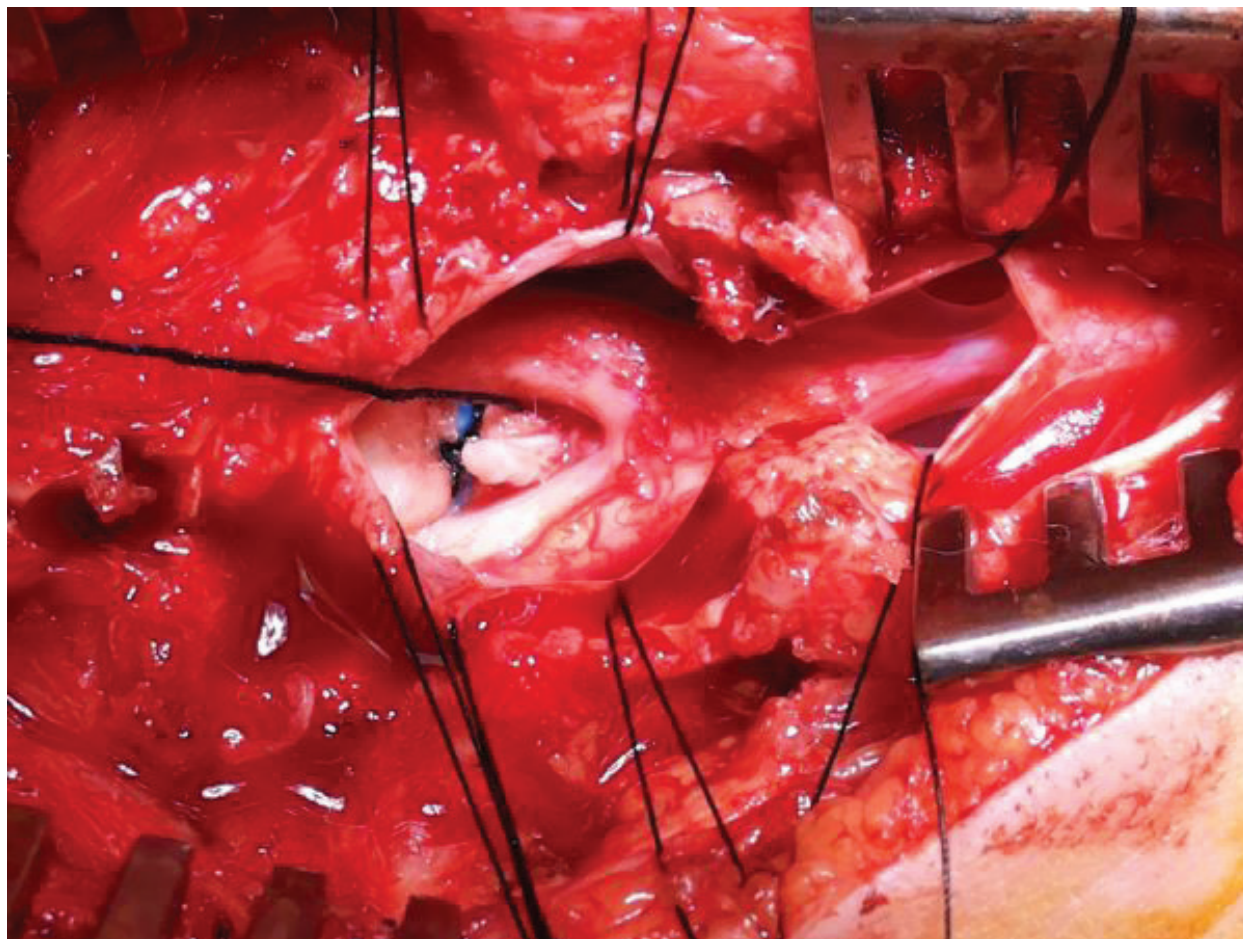


Photo had been taken from operation. Note Opened thecal sac.

EP-220[Pediatric Neurosurgery]

EFFECTIVENESS OF USING INJECTABLE PREPARATION OF CONVULEX IN TREATING SYMPTOMATIC EPILEPTIC STATUS

Syrdankyz Ibatova, Marat Rabandiyarov, Abay Iskanov, Alibek Zharassov
Department of Pediatric Neurosurgery, National Centre for Neurosurgery, Astana, Kazakhstan

INTRODUCTION - OBJECTIVE: Evaluating effectiveness of using injectable preparation of Convulex in treatment of symptomatic epileptic status (ES).

METHOD: We examined 16 pediatric patients with symptomatic ES - 9 boys and 7 girls, 3 months-17 years aged, with follow-up 3-5 days. 68,7% (n=11) had generalized tonic-clonic seizures, 31,2% (n=5) had partial seizures with secondary generalization. 7 patients (43,7%) Obstructive hydrocephalus (OH) in the postoperative period 48 hours; 9 patients (56,2%) had intracerebral tumors in the post operative period for 3-5 days. Convulsion wasn't noted earlier in 2 (12,5%) patients with OH, seizure began after shunt surgery for 2 days. 5 (31,2%) patients with OH have been having symptomatic seizures for 2 years, received valproic acid. Valproic acid was prescribed from the initial identification of all patients with ES (Convulex intravenous injection). Given the condition of the patients in the postoperative period daily dose of 15-30 mg/kg was administered to rapidly achieve and to maintain high concentration in plasma, intravenously 15 mg/kg over 5 minutes and after 30 minutes of infusion initiated at 1 mg/kg per hour for 24 hours.

RESULTS: More than half of patients (87%, n=14) achieved complete relief of ES from time of valproic acid injection. On the second day was transferred to oral administration of Convulex. Convulsion persisted throughout day in (13%, n=2) of patients, with focal component, these patients Diazepamum was additionally administered by age-dependent dose.

CONCLUSIONS: Thus, the injectable preparation of Convulex is convenient, safe and effective to use. It is alternative to phenytoin in all critical seizure cases, including ES of any etiology.

EP-221[Pediatric Neurosurgery]

GUYON'S CANAL SYNDROME DUE TO TORTUOUS ULNAR ARTERY: A CASE REPORT

Melih Üçer, İlhan Aydın, Sarper Polat, Abdullah Emre Taçyıldız, İbrahim Alataş
Bakirkoy Research & Training Hospital for Psychiatry, Neurology and Neurosurgery

INTRODUCTION - OBJECTIVE: To report of a case with Guyon's canal syndrome due to tortuous distal ulnar artery. Although ulnar nerve entrapment has been quite frequently reported due to posttraumatic false aneurysms, thrombosis, or true aneurysms of the distal ulnar artery in Guyon's canal, only three case has been reported due to tortuous distal ulnar artery in literature by now.

METHOD: A 68 year-old man with intermittent pain, intermittent burning sensation and continuous numbness on the ulnar side of her left hand was admitted. Electromyographic examination showed an ulnar neuropathy in the Guyon's canal and an ipsilateral carpal tunnel syndrome.

RESULTS: Exploration of the ulnar nerve in the Guyon's canal at the wrist showed that an S shaped tortuous ulnar artery compressed the ulnar nerve. Ulnar nerve decompression by ulnar artery transposition was performed and carpal ligament was partially excised. After the operation, pain and burning sensation were improved completely in a few hours, but numbness was continued.

CONCLUSIONS: Tortuous peripheral arteries are too rare causes of peripheral nerve entrapment syndromes. Resolution of intermittent pain and burning sensation by ulnar artery transposition in the presented case was suggested that the symptoms might be due to pulsatile pressure like in vascular compression of cranial nerves.

EP-222[Pediatric Neurosurgery]

INTRACRANIAL MIGRATION OF VENTRICULO-PERITONEAL SHUNT CATHETER

Melih Üçer, İlhan Aydın, Sarper Polat, Abdullah Emre Taçyıldız
Bakirkoy Research & Training Hospital for Psychiatry, Neurology and Neurosurgery

INTRODUCTION - OBJECTIVE: The migration of ventriculo-peritoneal shunt catheter is a rare complication of surgical treatment for hydrocephalus. The migration may be in either direction and is more frequent with hard and spring loaded shunt tubes.

METHOD: A male child was born by breech delivery at the 32 week of gestation. Four months later a macrocephalia and a tense fontanel developed. Computed tomography showed an increase of ventricular volume. The child underwent a ventriculoperitoneal shunt (medium pressure). On the 9th postoperative day, the child was discharged. Some days later, the child returned to Kanuni Sultan Süleyman Hospital (Istanbul, Turkey), with signs and symptoms of increased intracranial pressure. Computed tomography showed an increase of ventricular volume, air in right temporal horn and shunt tube in the cranium. The child underwent surgical removal of the tube and a new tube was implanted in contralateral side. On the 7th postoperative day, the child discharged.

RESULTS: Shunt complications have been frequently reported in literature. The intracranial migration of ventriculo-peritoneal shunt is the most rare complication and constitutes 0,1% to 0,4% of all shunt procedures. Distal migration of the shunt has often been reported. The pressure gradient between the cranial and peritoneal cavities decides the direction of migration. The mechanism of shunt migration involves adhesion, necrosis, penetration, perforation, migration and extrusion.

CONCLUSIONS: The treatment consists of removing the migrated shunt and implantation of a new shunt, preferably with a reservoir. Migration of shunt is not prevented by locks and slip clips.

EP-223[Pediatric Neurosurgery]

MIGRATION OF ABDOMINAL CATHETER OF VENTRICULOPERITONEAL SHUNT INTO THE SCROTUM

Melih Üçer, Sarper Polat, İlhan Aydın, Abdullah Emre Taçyıldız, İbrahim Alataş
Bakirkoy Research & Training Hospital for Psychiatry, Neurology and Neurosurgery

INTRODUCTION - OBJECTIVE: A 12 months male neonate presented with migration of the ventriculoperitoneal (VP) shunt tip through the patent processus vaginalis resulting in scrotal hydrocele. The association hydrocephalus may have been a predisposing factor in this rare complication. Development of scrotal swelling or hydrocele in a child with VP shunt should be recognized as a possible shunt complication.

METHOD: Ventriculoperitoneal (VP) shunt is commonly employed in the management of hydrocephalus. Various complications such as dissection or migration may develop besides shunt malfunction. Migration may occur into the lateral ventricle, mediastinum, gastrointestinal tract, abdominal wall, bladder, vagina, or scrotum.

RESULTS: A 12 months male was admitted to the Kanuni Sultan Süleyman Hospital for treatment of hydrocephalus. Postoperative two months bilateral scrotal were swollen, more prominently on the right. The distal tip of the shunt could be palpated in the right scrotum, and appeared on radiography of the abdomen. An indirect inguinal hernia repaired and the distal tip replaced into the peritoneum. A prophylactic operation was performed on the left.

CONCLUSIONS: Migration of the peritoneal catheter into the scrotum through the unobliterated processus vaginalis has been reported previously, but the tube was not dissected in all cases. The development of scrotal swelling or hydrocele in a child with a VP shunt should be recognized as a possible shunt complication in the early postoperative period.

EP-224[Pediatric Neurosurgery]

ARMURED BRAIN: A CASE OF BILATERAL CALCIFIED CHRONIC SUBDURAL HAEMATOMA COMPLICATING INFANTILE HYDROCEPHALUS

Melih Üçer, İlhan Aydın, Sarper Polat, Abdullah Emre Taçyıldız, İbrahim Alataş
Bakirkoy Research & Training Hospital for Psychiatry, Neurology and Neurosurgery

INTRODUCTION - OBJECTIVE: Chronic Subdural haematoma is one of the late complications of shunting procedures. Calcified Chronic Subdural haematoma (CCSDH) which is very rare, follows untreated or asymptomatic Chronic subdural haematomas. When it occurs bilaterally it gives the typical appearance of an "armoured brain" also known as "Matrioska head".

METHOD: He is a 16 yr old male who was first seen at 3 months of age and treated for severe post-meningitic hydrocephalus by a ventriculoperitoneal (VP) Shunt. There was also an associated seizure disorder which was controlled with antiepileptic drugs. A follow-up Computerized Tomography (CT) brain scan done in September 2013 showed a bilateral chronic subdural haematoma.

RESULTS: Chronic subdural hematoma is one of the late complications of shunting for infantile hydrocephalus. The risk of postshunting subdural hematomas in children ranges from 2.8 to 5.4%. Subdural hematomas occur possibly due to over-drainage of the ventricles especially in patients whose cranial sutures have fused but the pathogenesis and mechanisms of calcification are still debatable. There has been no record of this complication in patients who were treated with endoscopic third ventriculostomy. Etiological factors considered include poor circulation, delayed haematoma absorption and stagnation, leading ultimately to calcification.

CONCLUSIONS: Calcified chronic subdural hematomas are rare complications of shunting, whose management is based on the clinical status of the individual patient. Interval CT scans during the long-term follow-up of these patients will detect asymptomatic chronic subdural hematomas that can be treated early to forestall calcification. Surgical excision is feasible but should be limited to symptomatic cases.

EP-225[Spine and Peripheral Nerve Surgery]

LUMBAR MALIGNANT PERIPHERAL NERVE SHEATH TUMOR: A RARE CASE

Sofiene Bouali, Lassaad Aouij, Asma Bouhoula, Adenane Boubaker, Hafedh Jemel
NATIONAL INSTITUT OF NEUROLOGY MONGIE BEN HMDIA TUNIS

INTRODUCTION - OBJECTIVE: Malignant peripheral nerve sheath tumor or malignant Schwannoma is a very malignant tumor, which is rare. Our Objective is to identify this gross pathology, the histopathology, the immuno-histochemistry, and to discuss the treatment, the recurrence rate, the follow-up, the incidence of metastasis and the prognosis.

METHOD: There have been no reports about malignant Schwannoma located at the lumbar region in the medical literature we reviewed. Here, we present an extraordinary case of malignant peripheral nerve sheath tumor arising in the lumbar region. The clinical, radiological, pathological findings and treatment of our patient are discussed.

RESULTS: A 35-year-old woman was operated in our department for a dumbbell-shaped tissue mass arising from the left intervertebral foramen L2-L3 and made extension to the left retroperitoneal region revealed at the CT scan and the MRI of the lumbar spine.

CONCLUSIONS: These tumors may pose a diagnostic and management dilemma. Radical surgical excision of the lesion is still the treatment of choice but the role postoperative radiotherapy or chemotherapy is not clear. Because of the potential for local recurrence, a close surveillance must be established.

EP-227[Spine and Peripheral Nerve Surgery] CLINICORADIOLOGICAL ANALYSIS OF ADJACENT SEGMENT DISEASE IN CERVICAL DISC REPLACEMENT- OUR EXPERIENCE

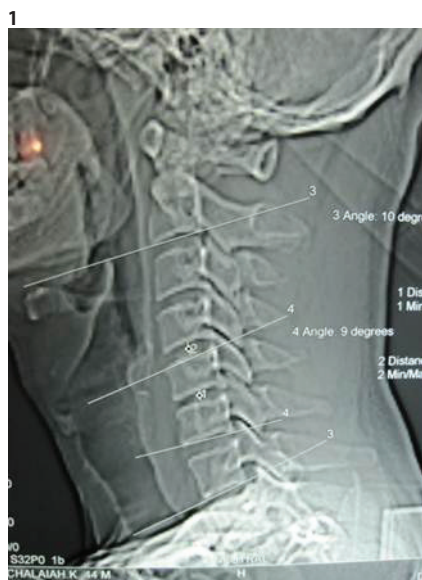Venkata Ramesh Chandra Vemula, Chandramowliwara Bodapati, Kaushal Ippili
Department of Neurosurgery, SVIMS, Tirupati, Andhra Pradesh, India.

INTRODUCTION - OBJECTIVE: To assess the clinical and radiological outcomes in a cohort of patients prospectively enrolled to undergo cervical disc arthroplasty with the Prestige LP cervical disc system (Medtronic Sofamor Danek, Memphis, TN, USA) and to assess the incidence of adjacent segment disease. We present our experience in this field.

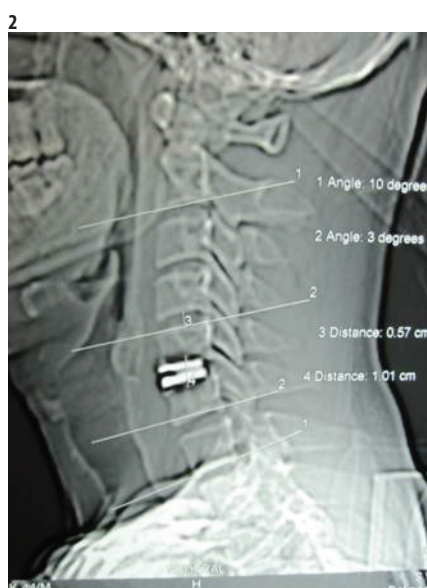
METHOD: All patients admitted to department of neurosurgery, SVIMS, Tirupati, who undergo anterior cervical discectomy and disc arthroplasty fulfilling the inclusion and exclusion criteria were analyzed clinically and radiologically. Patients were evaluated preoperatively and postoperatively by means of neck disability index, visual analog score and radiologically by plain CT topography

RESULTS: A total of 25 patients underwent disc arthroplasty over last 2 years. They included 15 males and 10 females. Mean age was 41.46 yrs. C5/6 was the commonest level that was operated. One patient underwent surgery at 2 levels. There was significant reduction in neck pain, limb pain and NDI postoperatively. The cervical lordosis and functional segmental angle were maintained even after surgery. Range of motion was maintained following the disc replacement. No complications were observed

CONCLUSIONS: Cervical disc replacement can be used to restore and maintain mobility and function of the involved cervical spinal segments. The procedure shows decreased surgical morbidity, avoidance of complications from instrumentation or postoperative immobilization and allows an earlier return to the previous level of function.



preoperative ct tomogram of cervical spine



postoperative ct tomogram of cervical spine

EP-228[Spine and Peripheral Nerve Surgery] TRAUMA OF THE VERTEBRAL AND SPINAL CORD AS A RESULT OF A FALL FROM HEIGHT

Ravshan M Yuldashev
Republican Scientific Centre of Neurosurgery, Tashkent, Uzbekistan

INTRODUCTION - OBJECTIVE: The work purpose - to find communication between a spinal cord damage rate, weight of damages of other bodies and systems with changes in bone structures of a backbone and a spinal cord on MPT; revealing of indicators which influence the result of treatment.

METHOD: A series of 60 patients who experienced vertebral and spinal cord trauma as a result of fall from a height admitted to Clinic of Neurosurgery in Tashkent from 2010 to 2013 has been analyzed. There were 45 males and 15 females, within the age from 19 to 72. Their mean age was 39 years.

RESULTS: The cervical (21 cases), thoracic (13 cases) and lumbar spine (26 cases) were involved. The complete transverse spinal cord lesion was observed in 22 (37%) patients. The relationship between degrees of spinal cord lesion (AIS), multiple trauma severity (ISS) and posttraumatic lesions of spinal cord in MR imaging were revealed in our study. Neurological condition improved in 38 (63%) patients. Successful outcomes were present in patients with partial cord lesion. Statistical calculation approved prognostic value of AIS, ISS and edema, ischemic and hemorrhage contusion focus in spinal cord.

CONCLUSIONS: There is a direct dependence between a damage rate of a spinal cord, weight of the combined trauma and available changes in the spinal cord, revealed on MRI. After operation improvement of a neurologic state was observed in 63% of cases. Such indicators as AIS, ISS, hypostasis, a contusion of vertebrae, hemorrhage and ischemia of a spinal cord influence the result of treatment.

EP-229[Spine and Peripheral Nerve Surgery] THE ADMINISTRATION OF VANCOMYCIN POWDER TO REDUCE THE RISK OF SURGICAL SITE INFECTION IN PATIENTS UNDERGOING NON-TRAUMATIC POSTERIOR SPINAL FIXATION

Babak Ganjeifard
Mashhad University of Medical Sciences

INTRODUCTION - OBJECTIVE: Objective Surgical site infection (SSI) following posterior spinal fixation can be a catastrophic complication in patients. Despite systemic antibiotic prophylaxis, SSI has been reported in 3-12% of instrumented spinal fusion cases. Treatment costs as well as repercussions can be profound. Despite the yet uncertainly as to the efficacy of local vancomycin, it has been reportedly considered as adjunct therapy beside systemic prophylaxis in SSI.

METHOD: This prospective study was to evaluate the efficacy of applying local vancomycin powder to surgical site for SSI prevention. A consecutive number of patients (137) who underwent elective non-traumatic posterior decompression and spinal fixation by one neurosurgeon were given one gram of vancomycin powder locally beside perioperative intravenous Cefazolin for 48 hours. The study was conducted in an academic center in a two-year time bracket from May 2012 to February 2014. The indices under investigation included demographics, infection extent (superficial and deep infection) as well as associated risk factors. All patients were followed between one and 12 months.

RESULTS: The overall incidence rate of infection was 0.73% with only one case of superficial SSI in a 72-year-old paraplegic uncontrolled diabetic plus multiple myeloma, having undergone posterior thoracic decompression and instrumentation. There has been any report of neither adverse clinical nor wound effects in this study. In this study local vancomycin powder application led to reduction of SSI rate

CONCLUSIONS: conclusion Local vancomycin administration is seemingly an effective approach in diminishing the risk of SSI. Further investigation in the form of randomized control trial is required to confirm this finding.

EP-231[Spine and Peripheral Nerve Surgery]

BRYAN CERVICAL ARTHROPLASTY AT K.H.M.C RETROSPECTIVE EVALUATION

Rami Y Alqroom, Nidal H Khasawneh, Mohamd A Alhosban, Feras K Haddad, Anas I Dyab, Wesam Khraisat

ROYAL MEDICAL SERVICES, KING HUSSEIN MEDICAL CITY, AMMAN-JORDAN

INTRODUCTION - OBJECTIVE: The purpose of this retrospective study is to evaluate long term results after cervical disc arthroplasty (BRYAN)

METHOD: We performed a retrospective review of patients presenting with spondylotic cervical myelopathy or radiculopathy and underwent cervical disc arthroplasty (BRYAN) between JAN.2004 and JAN.2010 and had a minimum follow up of 27 months. Radiographic follow-up. Changes in the operated segments were compared to radiographs directly after surgery. outcome was evaluated by a physical exam, pain VAS and NDI.

RESULTS: 112 patients were operated. The mean age at presentation was 51 years, 69 patients were male (61.6%). 43 female (38.4%) and all patients had one level surgery. Minimal Follow of 24 months. 74 patients presented with radiculopathy (66%), 38 with myelopathy (34%). Over all 98 patients presented with limb pain. Pain resolved or improved in 87 (88.7%) cases.. Myelopathy was unchanged in 5 (13,1%), worse in 4 (10,5 %); 29 patients improved (76,3%). In 10 patients (8,9%) we achieved correction of kyphosis. Regarding motion and subsidence at operated levels, no subsidence Observed at 24 follow up in all cases preserved motion except of cases of dislodgment and ossification. Overall There were 2 (0,17%) cases of ossification. One disc dislodgment and one case of injury to the vertebral artery. Most common level C4/C5 for myelopathic patients (55%) and C5/C6 (52%), C6/C7 (48%) for disc herniation.

CONCLUSIONS: Although ACDF is the gold standard procedure for cervical disc pathology with established safety and effectiveness, however the evolved alternative arthroplasty (BRYAN) eliminate it IS restrictions and limitations.

EP-234[Spine and Peripheral Nerve Surgery]

SPONTANEOUS SPINAL CANAL REMODELING AFTER POSTURAL PILLOW REDUCTION AND LORDOTIC, POSTERIOR COLUMN COMPRESSIVE PERCUTANEOUS TRANSPEDICULAR SCREWING IN THORACOLUMBAR BURST FRACTURES

Hyeun Sung Kim¹, Se Jin Jeong¹, Ki Hyun Jeon¹, Woo Jin Choi¹, Kwan Tae Kim¹, Kun Soo Jang², Chang Il Ju², Seok Won Kim², Ho Shin²

¹Department of Neurosurgery, Hurisarang Spine Hospital, Daejeon City, South Korea

²Department of Neurosurgery, College of Medicine, Chosun University, Gwangju City, South Korea

INTRODUCTION - OBJECTIVE: We report on spontaneous canal remodeling in thoracolumbar bursting fractures after two different surgical procedural elements: 1) preoperative postural pillow reduction; and 2) lordotic, posterior column compressive percutaneous screwing.

METHOD: We retrospectively analyzed 34 cases who underwent lordotic, posterior column compressive percutaneous transpedicular screwing for thoracolumbar bursting fractures between the time period of July 2008 and Jun 2012. All patients included in this retrospective study were checked at three different stages with both x-ray and magnetic resonance imaging: 1) preoperative stage; 2) immediate postoperative stage; 3) 6-months after surgery. The study measured the following three outcomes among the cases: 1) spinal canal compromise; 2) fractured vertebral height; and 3) spinal lordotic angle.

RESULTS: Average follow-up period among study participants was 30.68 months. Spinal canal compromise was measured among all study participants with the following results for the preoperative stage, post-operative stage, and 6-month follow-up stage, respectively: 44.37%, 20.04% and 12.06%. The outcomes for fractured vertebral height for the preoperative stage, post-operative stage, and 6-month follow-up stage, respectively: 43.91%, 81.69% and 77.29%. The outcomes for spinal lordotic angle for the preoperative stage, post-operative stage, and 6-month follow-up stage, respectively: -13.86 degree, -0.518 degree and -3.40 degree.

CONCLUSIONS: We assessed the spontaneous spinal canal remodeling after postural pillow reduction and lordotic, posterior column compressive percutaneous screwing in the thoracolumbar bursting fracture. According to the study's result, we recommend that the postural reduction and lordotic, posterior column compressive percutaneous screwing in the cases of neurologically intact thoracolumbar bursting fracture.

EP-235[Spine and Peripheral Nerve Surgery]

SPINAL CANAL COMPROMISE RELATED FACTORS OF SURGICAL SUCCESS IN THE PERCUTANEOUS TRANSFORAMINAL ENDOSCOPIC LUMBAR DISCECTOMY

Hyeun Sung Kim¹, Se Jin Jeong¹, Ki Hyun Jeon¹, Woo Jin Choi¹, Kwan Tae Kim¹, Kun Soo Jang², Chang Il Ju², Seok Won Kim², Seung Myung Lee², Ho Shin²

¹Department of Neurosurgery, Hurisarang Spine Hospital, Daejeon City, South Korea

²Department of Neurosurgery, College of Medicine, Chosun University, Gwangju City, South Korea

INTRODUCTION - OBJECTIVE: The purpose of this study was to evaluate the spinal canal compromise related factors of surgical success in the percutaneous transforaminal endoscopic lumbar discectomy.

METHOD: We check the spinal canal compromise related factors as follows: 1) disc protrusion location, 2) canal compromise, 3) iliac crest level, 4) segmental level, 5) soft tissue foraminal width, and 6) hard bony

foraminal width. The surgical success rate (SSR) were evaluated by sagittal and axial T2 MRI: a. complete (n=88) (score: 10), b. sufficient (n=27) (score: 8), c. incomplete (n=3) (score: 5), and d. fail (score: 0). The clinical results were evaluated by a visual analogue scale (VAS).

RESULTS: Total surgical success rate was 94.05%. The mean VAS was preoperatively 7.836 to the last follow-up 1.086. The mean age was 40.71 years. The mean follow-up period was 21.41 months. In respect to the surgical result (SSR), Weak related factors: 1) Level, 2) Location and 3) Sex. Moderated related factors: 4) Revision, 5) Age and 6) Canal compromise grade. Deep related factors: 7) Soft tissue foraminal width, 8) Hard bony foraminal width and 9) Iliac crest.

CONCLUSIONS: Surgical success of the spinal canal compromise in the percutaneous transforaminal lumbar discectomy related to several factors such as, iliac crest, foraminal width, canal compromise, age and others. If we perform the percutaneous endoscopic lumbar discectomy in selected case, we will Obtain excellent clinical result.

EP-236[Spine and Peripheral Nerve Surgery]

TRAUMATIC ODONTOID EPIPHYSIOLYSIS IN A YOUNG CHILD, CASE REPORT AND LITERATURE REVIEW

Ahmed Elsayed Sultan

Department of Neurosurgery, Alexandria University School of Medicine, Alexandria, Egypt

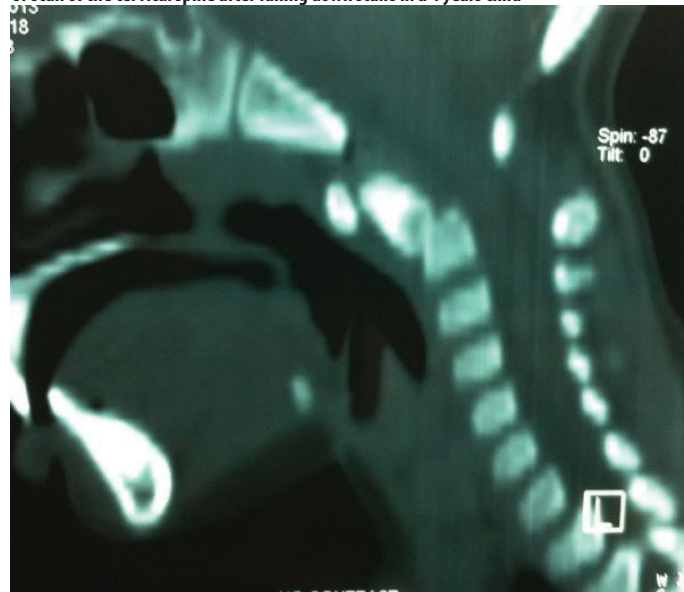
INTRODUCTION - OBJECTIVE: Traumatic Odontoid epiphysiolysis fractures, although rare in the overall incidence of spinal trauma, are one of the more common fractures in young children. The appropriate treatment of this Type of odontoid fractures remains controversial due to rarity of literature reports.

METHOD: The study included a case of Traumatic Odontoid Epiphysiolysis in a 4 years child. The patient was managed by non-operative treatment. External immobilization using Minerva orthosis for 12 weeks was conducted. The patient was followed up clinically and radiologically for 3 months.

RESULTS: Realignment and sound fusion was Obtained after 12 weeks. The patient remained neurologically intact.

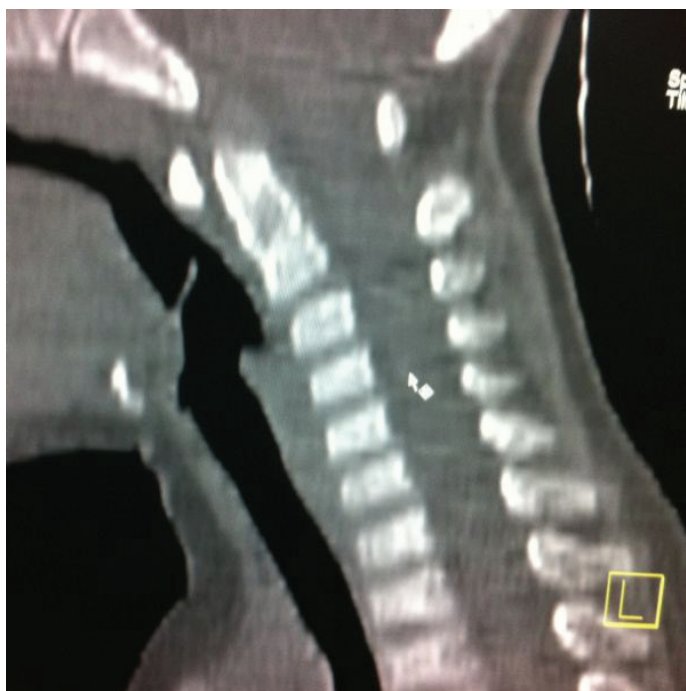CONCLUSIONS: In conclusion, closed reduction and external fixation can be the primary treatment option for TOE with high rate of fusion.

CT scan of the cervical spine after falling down stairs in a 4 years child



CT scan of the cervical spine with sagittal reconstruction showing Traumatic Odontoid epiphysiolysis.

CT scan of the cervical spine with sagittal reconstruction after treatment



CT scan of the cervical spine with sagittal reconstruction showing good fusion

EP-237[Spine and Peripheral Nerve Surgery]

COMPUTED TOMOGRAPHIC MORPHOMETRIC ANALYSIS OF CERVICAL PEDICLES IN A MULTI-ETHNIC ASIAN POPULATION AND RELEVANCE TO TRANSPEDICULAR SCREW FIXATION

Thangaraj Munusamy¹, Ady Thien¹, Mark Gerad Anthony², Ramesh Bakthavachalam¹, Shree Kumar Dinesh¹

¹Department of Neurosurgery, National Neuroscience Institute, Singapore

²Department of Neuroradiology, National Neuroscience Institute, Singapore

INTRODUCTION - OBJECTIVE: Pedicle screw insertion provides optimal stabilization of the cervical spine complex but is associated with risk of neurovascular injury. Sex and ethnic disparities could potentially compromise safety and accuracy. Therefore, a comprehensive analysis of surgical anatomy derived from CT scans is pertinent to determine feasibility and safety in our population.

METHOD: CT cervical spine performed at our institution from 2010 to 2013 were evaluated and 50 patients with normal anatomy were selected. Pedicle width (PW), height (PH) and transverse angle (PTA) were measured from C3 to C7 and analysed for sex and ethnic similarities and differences.

RESULTS: The smallest mean PW was at C4 in males and C3 in females. The largest mean PW was at C7 in both sexes. Mean PW gradually increased caudally from C4 onwards. Mean PW for males was significantly greater than females at all levels ($P < 0.05$; t test). 8% of our population have at least one PW < 4.00 mm. The mean PH in males was significantly greater than females at all levels ($P < 0.05$; t test) but no statistically significant sex difference in PTA values were found. There was significant ethnic difference in mean PW of males at C4, C5 and C7 ($P < 0.05$; ANOVA). In contrast, significant sex differences in mean PH was only found in females at C3, C4 and C7 ($P < 0.05$; ANOVA).

CONCLUSIONS: Cervical pedicle screw fixation is feasible in majority of our population except 8% with PW < 4.00 mm. However, in view of significant morphometric variability between individuals, pre-operative CT evaluation is mandatory to ensure safety and accuracy.

Mean PW, PH and PTA from C3 to C7

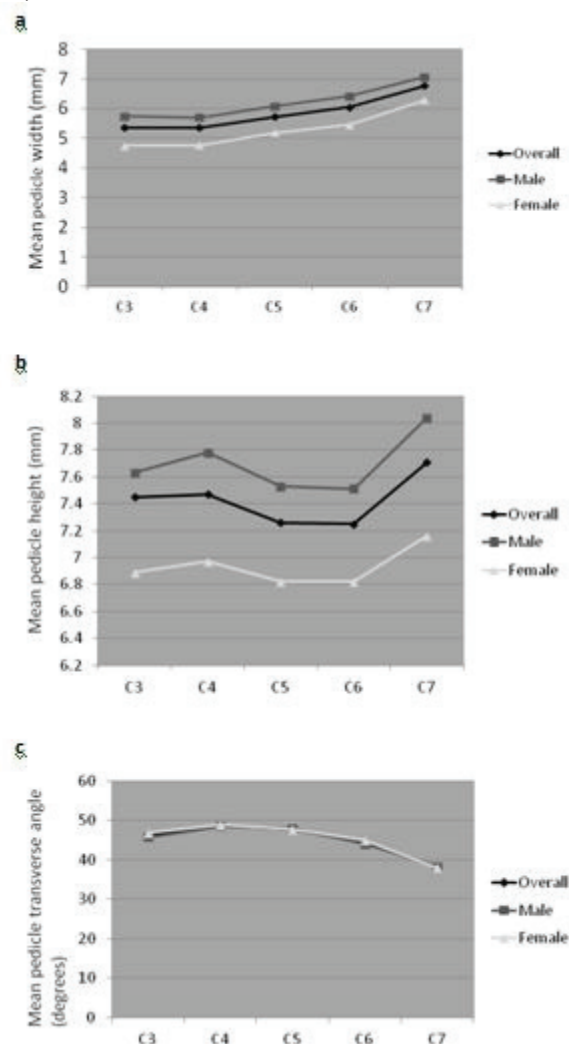


Fig. 2 a The mean pedicle width (PW) in male and female patients. b The mean pedicle height (PH) in male and female patients. c The mean pedicle transverse angle (PTA) in male and female patients.

Measurement of pedicle dimensions

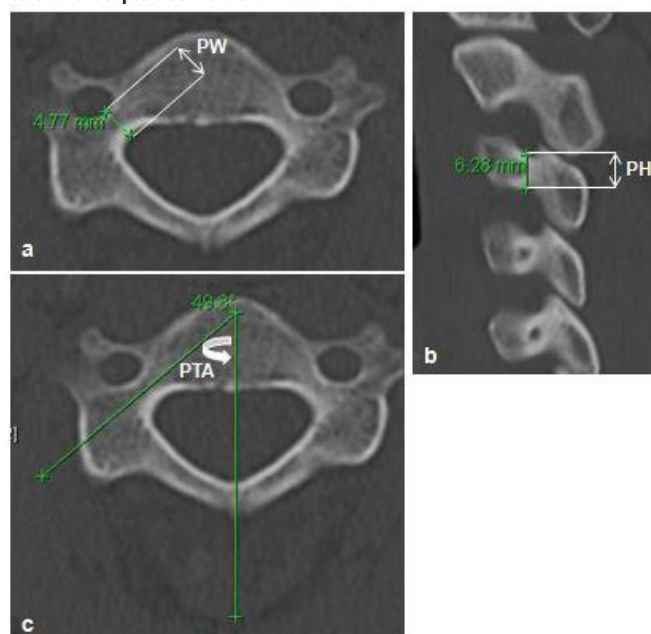


Fig. 1 a Horizontal planar reconstruction image through isthmus of the cervical pedicle used to measure pedicle width (PW). b Vertical planar reconstruction image used to measure pedicle height (PH). c Horizontal planar reconstruction image used to measure pedicle transverse angle (PTA).

PW, PH and PTA of cervical pedicles in females from three ethnic groups using CT measurements

TABLE 3
PW, PH and PTA of cervical pedicles in females from three ethnic groups using CT measurements

Vertebrae		Chinese			Malay			Indian		
		Mean	SD	Range	Mean	SD	Range	Mean	SD	Range
C3	PW	4.87	0.46	3.74 - 5.71	4.73	0.37	4.25 - 5.50	4.32	0.39	3.98 - 5.01
	PH*	6.99	0.68	5.71 - 8.43	7.28	0.82	5.97 - 8.70	6.19	0.90	4.55 - 7.43
	PTA	45.6	2.69	40.1 - 50.0	47.5	4.12	42.0 - 55.6	48.5	5.26	37.8 - 56.2
C4	PW	4.78	0.47	3.82 - 5.65	4.76	0.22	4.44 - 5.24	4.79	0.37	4.36 - 5.40
	PH*	7.12	0.64	6.13 - 8.77	7.27	0.90	5.99 - 8.30	6.24	0.56	5.56 - 7.24
	PTA	48.5	4.31	40.1 - 58.0	48.1	3.93	41.0 - 53.2	50.5	4.61	42.7 - 55.5
C5	PW	5.22	0.46	4.56 - 6.42	5.07	0.35	4.29 - 5.51	5.25	0.51	4.53 - 6.01
	PH	6.90	0.81	5.23 - 8.65	7.04	0.97	5.56 - 8.36	6.35	0.44	5.80 - 7.04
	PTA	47.4	4.02	41.6 - 56.1	47.2	3.47	41.4 - 53.5	48.9	4.31	42.2 - 54.8
C6	PW	5.51	0.33	4.89 - 6.12	5.25	0.43	4.44 - 5.84	5.55	0.39	4.95 - 5.96
	PH	7.00	0.91	5.23 - 8.87	6.76	0.78	5.47 - 7.84	6.47	0.53	5.83 - 7.48
	PTA	44.3	4.83	36.0 - 53.5	43.2	4.81	35.9 - 52.4	48.5	5.86	40.5 - 59.5
C7	PW	6.30	0.66	5.22 - 7.19	6.15	0.47	5.49 - 6.79	6.48	0.80	5.50 - 7.93
	PH*	7.35	0.62	6.07 - 8.32	7.38	1.22	5.93 - 9.13	6.46	0.63	5.67 - 7.54
	PTA	37.0	6.32	28.1 - 51.0	38.0	3.95	32.0 - 45.7	39.8	8.11	29.4 - 57.0

Values are mean ± SD

* Significant ethnic difference, $P < 0.05$

PW, PH and PTA of cervical pedicles in males and females using CT measurements

TABLE 1
PW, PH and PTA of cervical pedicles in males and females using CT measurements

Vertebrae		Overall			Male			Female		
		Mean	SD	Range	Mean	SD	Range	Mean	SD	Range
C3	PW*	5.36	0.88	3.15 - 8.33	5.74	0.89	3.15 - 8.33	4.75	0.43	3.74 - 5.71
	PH*	7.35	0.84	4.55 - 9.23	7.63	0.71	6.05 - 9.23	6.89	0.85	4.55 - 8.7
	PTA	46.1	4.74	35.3 - 58.4	45.7	5.23	35.3 - 58.4	46.7	3.81	37.8 - 56.2
C4	PW*	5.35	0.86	3.04 - 8.26	5.70	0.87	3.04 - 8.26	4.77	0.38	3.82 - 5.65
	PH*	7.47	0.86	5.56 - 9.45	7.78	0.76	6.05 - 9.45	6.97	0.78	5.56 - 8.77
	PTA	48.6	4.51	36.5 - 59.1	48.4	4.69	36.5 - 59.1	48.3	4.26	40.1 - 58.0
C5	PW*	5.73	0.81	4.08 - 8.00	6.07	0.80	4.08 - 8.00	5.18	0.43	4.29 - 6.42
	PH*	7.26	0.87	5.23 - 9.89	7.53	0.79	5.60 - 9.89	6.82	0.81	5.23 - 8.65
	PTA	47.8	4.07	39.1 - 57.6	47.9	4.20	39.1 - 57.6	47.6	3.89	41.6 - 56.1
C6	PW*	6.05	0.83	4.44 - 8.95	6.42	0.82	4.57 - 8.95	5.45	0.38	4.44 - 6.12
	PH*	7.25	0.81	5.23 - 9.26	7.51	0.70	5.54 - 9.26	6.82	0.81	5.23 - 8.87
	PTA	44.3	4.72	31.6 - 59.5	44.0	4.36	31.6 - 59.5	44.9	5.28	35.9 - 59.5
C7	PW*	6.77	0.81	4.86 - 9.12	7.07	0.77	4.86 - 9.12	6.29	0.65	5.22 - 7.93
	PH*	7.71	0.90	5.67 - 9.87	8.04	0.76	6.38 - 9.87	7.16	0.87	5.67 - 9.13
	PTA	38.1	5.54	28.1 - 57.0	38.2	5.17	28.7 - 48.8	37.8	6.18	28.1 - 57.0

Values are mean ± SD

* Significant sex difference, $P < 0.05$

PW, PH and PTA of cervical pedicles in males from three ethnic groups using CT measurements

TABLE 2
PW, PH and PTA of cervical pedicles in males from three ethnic groups using CT measurements

Vertebrae		Chinese			Malay			Indian		
		Mean	SD	Range	Mean	SD	Range	Mean	SD	Range
C3	PW	5.90	0.87	3.82 - 8.33	5.27	0.92	3.15 - 6.35	5.37	0.54	4.84 - 6.07
	PH	7.72	0.76	6.05 - 9.23	7.47	0.55	6.20 - 8.26	7.12	0.43	6.51 - 7.50
	PTA*	44.6	4.78	35.3 - 55.2	48.1	5.41	40.7 - 58.4	51.2	5.21	45.1 - 56.7
C4	PW*	5.88	0.89	3.04 - 8.26	5.29	0.65	4.46 - 6.48	5.05	0.69	4.33 - 5.99
	PH	7.90	0.81	6.05 - 9.45	7.50	0.49	6.34 - 8.23	7.32	0.68	6.77 - 8.29
	PTA	48.2	4.63	36.5 - 59.1	47.9	4.67	40.1 - 55.3	53.4	3.42	50.0 - 57.3
C5	PW*	6.24	0.80	4.08 - 8.00	5.75	0.89	4.58 - 6.83	5.22	0.35	4.71 - 5.45
	PH	7.58	0.85	5.60 - 9.89	7.58	0.42	6.74 - 8.20	6.96	1.00	5.91 - 8.19
	PTA*	47.3	4.04	39.1 - 57.6	48.0	4.14	40.5 - 53.2	53.6	1.96	51.5 - 55.6
C6	PW	6.48	0.80	5.11 - 8.95	6.33	0.79	5.09 - 7.46	6.02	1.25	4.57 - 7.12
	PH	7.56	0.74	5.54 - 9.26	7.58	0.49	6.70 - 8.48	6.87	0.44	6.41 - 7.45
	PTA	43.8	4.85	31.6 - 55.9	43.1	2.58	39.2 - 47.5	48.3	3.18	43.7 - 50.6
C7	PW*	7.16	0.63	5.94 - 9.12	7.17	0.63	6.24 - 8.58	5.73	1.09	4.88 - 7.24
	PH	8.08	0.79	6.38 - 9.87	8.17	0.58	7.23 - 9.04	7.27	0.57	6.65 - 7.99
	PTA	37.7	5.09	28.7 - 48.8	39.1	5.07	30.9 - 47.2	41.3	6.40	34.3 - 47.0

Values are mean ± SD

* Significant ethnic difference, $P < 0.05$

EP-238[Spine and Peripheral Nerve Surgery]

MINI INVASIVE SURGICAL TACTICS AT TRAUMATIC INJURIES OF BRACHIAL PLEXUS

Abdurashid Muminov, Malika Aslanova, Rano Ismailova

Urgent Neurosurgery department, Republican Neurosurgery research center, Tashkent, Uzbekistan

INTRODUCTION - OBJECTIVE: Performance of the traditional extended approach to brachial plexus leads to further disorders of blood circulation in vascular network of brachial plexus due to probable injury of collateral blood vessels.

METHOD: In Republican research center of neurosurgery new method of approach to primary trunks of brachial plexus has been developed and introduced. Over the last 5 years 176 patients were operated by the method. The total paralysis is clinically noted at 26 patients, at 87 patients – a paralysis of Erb, at 63 patients – a paralysis of Dzhherina-Klumpke. All patients were examined electroneuromyographically, at which various degrees of decrease in conductivity of impulses on trunks of a brachial plexus are found out.

RESULTS: Operation is made under local anesthesia. The cut is made parallel to clavicle, in the length of 6-7 cm, 2 cm above from a clavicle. Primary trunks are accessed by displacing vessels and muscles of a neck without their crossing. Neurolysis and endoneurolyse and subsequently electric stimulation of primary trunks are performed. Good results are received at patients with subtotal injury of a brachial plexus – at 126 (84 %) patients, satisfactory result at 24 (16 %) patients. At total injury of brachial plexus at 11 (40 %) patients the satisfactory result is received.

CONCLUSIONS: At surgical treatment of brachial plexus injuries the application of minimal invasive method of approach reduces complications during operation as anatomic integrity of vessels and neck muscles are saved. Application of local anesthesia and electric stimulation allows control the course and efficacy of operation.

EP-239[Spine and Peripheral Nerve Surgery]

TRANSVERSE SACRAL FRACTURES: REPORT OF THREE CASES

Feyza Karagoz Guzey, Azmi Tufan, Mustafa Vatansever, Abdurrahim Tas, Cihan Isler, Ozgur Aktas, Yucel Hitay, Sarper Kocaoglu, Murat Yucel

Department of Neurosurgery, Bagcilar Training and Research Hospital, Istanbul, Turkey

INTRODUCTION - OBJECTIVE: Transverse sacral fractures are rare pathologies that frequently associated with neurological deficit, predominantly with sphincter problems. Their treatment is controversial. There is a trend about using surgery in last years especially in the cases with neurological deficit.

METHOD: Two female and one male patient with transverse sacral fractures were reported.

RESULTS: They were 17, 20 and 34 years old and all of them were brought to the emergency room because of fall from height. Two of them had type III transverse sacral fractures and one had type I. Both patients with type III fractures had thoracolumbar burst fractures and one had multiple pelvic ring fractures. Both of these patients had paraparesis or paraplegia with sphincter disturbance below the level of thoracolumbar fractures. The patient with type I fracture had sphincter disturbance with both S1 and left L5 root involvement. In both patients with type III fractures, decompression and stabilization were performed for thoracolumbar fractures and decompression for sacral fractures. The patient with type I fracture was treated with decompression and stabilization for sacral fracture. All deficits of the patient with type I fracture were disappeared after 32 months follow-up. In the patient who had paraparesis

before treatment, paraparesis was improved from ASIA C to ASIA D, but sphincter disturbance did not improve after 30 months. The patient with ASIA A deficit and sphincter disturbance before treatment did not improve after 20 months.

CONCLUSIONS: Transverse sacral fractures frequently cause neurological deficit, especially sphincter disturbances. In these patients, decompression may provide to improve deficit.

EP-240[Spine and Peripheral Nerve Surgery]

COMPARATIVE EFFECTIVENESS OF TRANSPEDICULAR INSTRUMENTATION VERSUS CONSERVATIVE TREATMENT IN THORACOLUMBAR SPINE TRAUMA

Elbek Sh. Halikulov¹, Gayrat M. kariev²

¹Department of neurosurgery, Tashkent Pediatric Medical Institute, Uzbekistan

²Department of spinal surgery, Republican Scientific Center of Neurosurgery, Tashkent, Uzbekistan

INTRODUCTION - OBJECTIVE: The management of thoracolumbar vertebral body fractures without spinal cord injury remains controversial. In this study, we compared the clinical efficacy of conservative management by wearing thoracolumbar corset with medication and surgery by segment pedicle instrumentation.

METHOD: 14 patients were treated conservatively and 9 patients with segment pedicle instrumentation. All of them were presented with A3 of Magerl classification type without spinal cord injury. Clinical outcomes were evaluated by a Visual Analog Scale (VAS) pre- and postoperatively at least one year follow-up. Radiographic data including the vertebral body height, kyphotic angle, as well as spinal canal compromise was also evaluated. Mean age of the patients of conservative treatment group were 37 ± 2.1 y.o., and surgically treated patients mean age were 41 ± 1.7 y.o. The patients in both groups were similar regarding follow-up period, severity of the deformity and fracture.

RESULTS: VAS score improved more rapidly after surgery. No significant difference was found in VAS score between the two groups at final follow-up ($p > 0.05$). The height of vertebrae and the kyphosis angle showed significant improvement in each group ($p < 0.05$). The postoperative improvement in spinal canal compromise wasn't statistically as significant ($p > 0.05$) as in conservative managed group ($p > 0.05$). At final follow-up, remodeling of spinal canal compromise was detected in both groups.

CONCLUSIONS: Both conservative and surgical management appeared as effective methods for selected thoracolumbar fractures in the short-term. Conservative management had no risk but surgical instrumentation provided a better reduction. Long-time studies should be conducted to support these clinical outcomes.

EP-241[Spine and Peripheral Nerve Surgery]

INTRAMEDULLARY SPINAL CORD METASTATIC MELANOMA – A CASE REPORT

Tofael Hossain Bhuiyan¹, Mohammad Hossain², Habibur Rahman¹, Mostofa Zaman Chowdhury¹

¹Department of Neurosurgery, Rangpur Medical College & Hospital, Rangpur, Bangladesh.

²Department of Neurosurgery, Bangabandhu Sheikh Mujib Medical University, Dhaka, Bangladesh.

INTRODUCTION - OBJECTIVE: Intramedullary Spinal Cord Metastatic Melanoma (IMMST) is extremely rare. Its diagnosis is often very difficult even when the primary tumor is known. Patients are usually present with low back pain with the signs/symptoms of spinal cord compression. MRI is the main diagnostic tool for IMMST. The treatment of metastatic melanoma remains controversial. There is a wide range of treatment protocol for this metastatic melanoma ranging from radiotherapy, chemotherapy or in combination. But none treatment is still proven significantly beneficial.

METHOD: A single case with intramedullary spinal tumor underwent operation and was analysed prospectively.

RESULTS: Patient was diagnosed as spastic paraplegia. MRI investigation revealed intramedullary SOL at D4 level. Patient was operated on 25/01/2014. Intraoperatively tumor was intramedullary, physically clay colour tissue was found. Histopathological report showed malignant melanoma. Patient was referred to oncology department. He was received L-EBRT + chemotherapy. There is no gross improvement of the limbs and bowel & bladder function after completion of full course of chemotherapy & radiotherapy.

CONCLUSIONS: The treatment of intramedullary malignant melanoma is difficult. The best treatment may be a total surgical excision of the lesion, whenever possible, but removal of the tumor generally is incomplete, and radiation therapy often is recommended after surgery. In conclusion, awareness of the unusual presence of melanoma within the spinal cord is important, and the possible presence of this lesion must be considered when MR images depict a spinal cord tumor with paramagnetic properties. The final diagnosis, however, is based on the results of pathologic examination.

EP-242[Spine and Peripheral Nerve Surgery]

PROSPECTIVE VALIDATION OF A BLOOD ORDERING PROTOCOL FOR ELECTIVE SPINE ARTHRODESIS AND ITS IMPACT ON COST REDUCTION

Badar Uddin Ujjan, Muhammad Waqas, Muhammad Shahzad Shamim, Saqib Kamran Bakhshi
The Aga Khan University Hospital Stadium Road Karachi

INTRODUCTION - OBJECTIVE: On the basis of an institutional audit Alam et al., published an individual patient based protocol for pre-operative arrangement of blood products in patients undergoing elective spine arthrodesis. The present study was conducted for prospective validation of the proposed protocol in

reducing cross match to transfusion ratio; and its implications on overall cost.

METHOD: This cross sectional study was conducted over a one year period. All adult patients who underwent elective spinal arthrodesis were included and prospectively observed for the transfusion index. The actual transfusion index (C1/T) was calculated for individual patients (C1 = units of packed RBCs cross matched, T = number of actual transfusions). C1/T was then compared with a theoretical transfusion index C2/T for the same group of patients, (C2 = number of cross matched units according to protocol). The cost difference between C1/T and C2/T was analyzed.

RESULTS: 125 patients were included. A total of 435 units of packed RBCs were ordered (C1), out of which only 108 units were transfused (T), yielding a C1/T of 4.02. The C2 for the same group of patients was 188 units of packed RBCs and the C2/T was thus calculated to be 1.74. Implementation of Alam et al recommendation would reduce per patient cost from PKR 6,676.8 \pm 4,125.8 to 4,700.8 \pm 1712.86 with a p value < 0.001 and an overall reduction of 30%.

CONCLUSIONS: Cross match to transfusion ratio and blood ordering related cost are both significantly reduced with the application of Alam et al.'s protocol.

EP-243[Spine and Peripheral Nerve Surgery]

BRACHIAL PLEXUS SCHWANNOMA IN A PATIENT WITH AXILLARY MASS: A CASE REPORT

Deniz Güzey¹, Hakan Yirgin¹, Musa Çırak², Enis Öztürk³, Serkan Aslan³, Oğuz Iskender Turan⁴, Yasemin Özkan⁴, Damlanur Sakız⁴

¹Department of General Surgery, Bakirkoy Dr. Sadi Konuk Training and Research Hospital, Istanbul, Turkey

²Department of Neurosurgery, Bakirkoy Dr. Sadi Konuk Training and Research Hospital, Istanbul, Turkey

³Department of Radiology, İstanbul Bakırköy Dr. Sadi Konuk Training and Research Hospital, İstanbul, Turkey

⁴Department of Pathology, Bakirkoy Dr. Sadi Konuk Training and Research Hospital, Istanbul, Turkey

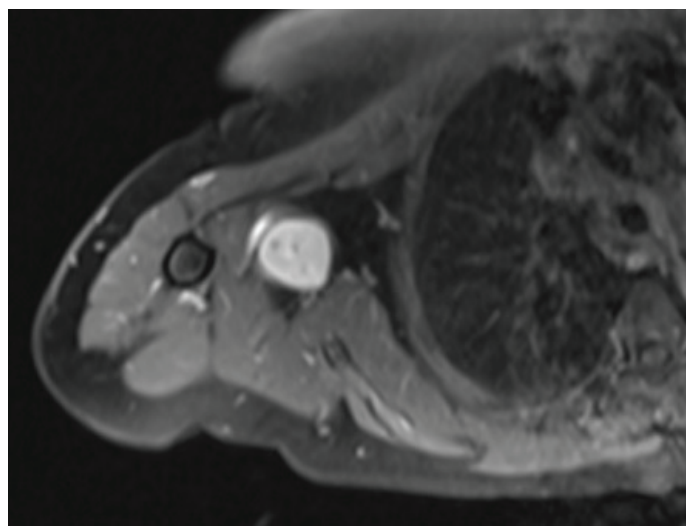
INTRODUCTION - OBJECTIVE: Differential diagnosis of axillary masses includes axillary lymph node metastases from carcinoma, lymphoma, or melanoma, and rarely neurogenic tumors. Only a few cases of axillary schwannoma have been reported. Due to their rarity and complex location they form diagnostic and therapeutic challenges.

METHOD: A 59 year old lady with brachial plexus schwannoma was reported.

RESULTS: A patient was admitted with complaints of right arm pain and painful axillary mass for one year. A BIRADS category 2 lesion was found on her breast examination. Ultrasonography and magnetic resonance imaging were performed for axillary lesion, and also electrophysiological examination for possibility of brachial plexus pathology. Any of these examinations could not show a relationship of the mass with brachial plexus. A biopsy was performed and surgical excision was planned because of pathological diagnosis as a mesenchymal tumor. The mass was totally removed from distal brachial plexus neighborhood, but there was not a tight relation between the tumor and the neural tissue. Intraoperative neuromonitorization did not performed because of prediagnosis of mesenchymal tumor. However pathological examination revealed that it was a schwannoma. After tumor excision, the patient had relief of arm pain but on examination there was paresis of dorsiflexion of wrist and abduction of finger. No recurrence was observed after 14 months.

CONCLUSIONS: Although brachial plexus schwannoma is a rare tumor, it must be kept in mind in differential diagnosis of axillary masses. If surgery is performed with possibility of schwannoma and with necessary preparations such as neuromonitorization, patient may be managed without neurological deficit.

Figure 1a:



Axial T1-weighted (a) and sagittal T2-weighted (b) right axillary MRI sections showed an axillary well-defined mass, 37x37 mm in size, with low signal intensity on T1-weighted sections and heterogeneous high signal intensity on T2-weighted sections. Heterogeneous and intensive enhancement was present after gadolinium administration, with nonenhanced small areas in the center of the mass. The lesion was in close approximation to axillary artery and vein, however, its exact relation to them could not be determined.

Figure 1b:

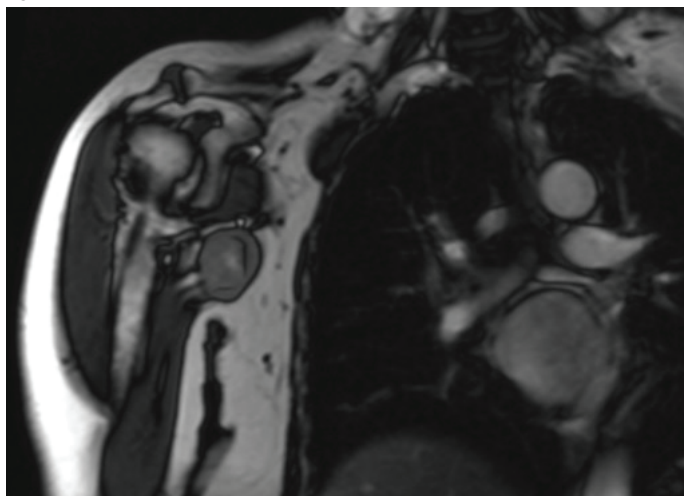
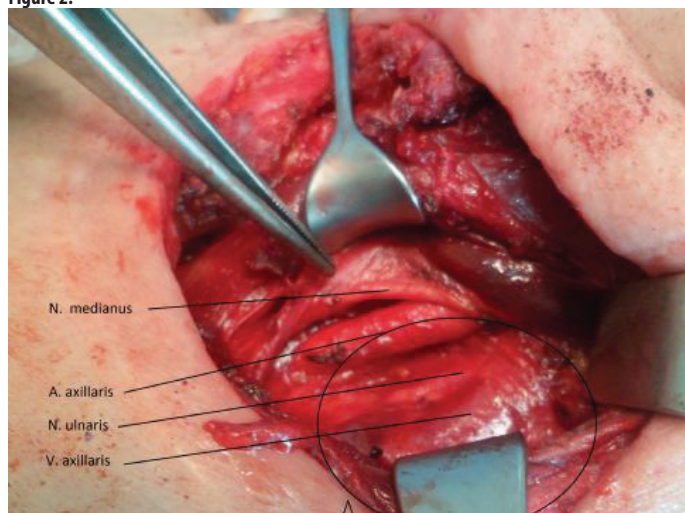
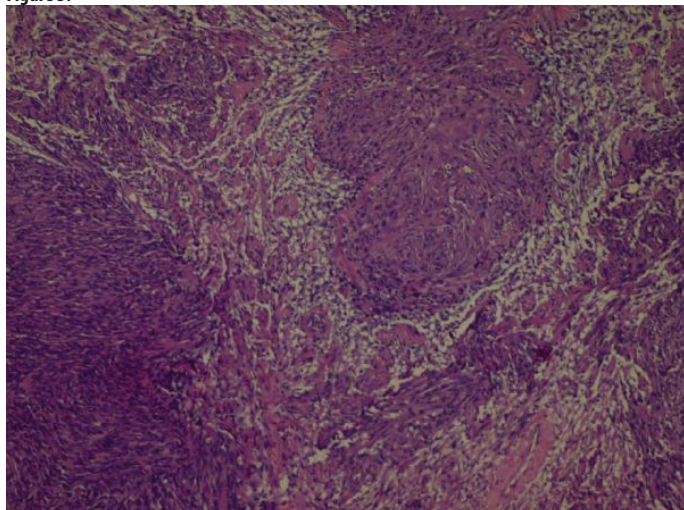


Figure 2:



Operation photograph showed the mass locating posteriorly to the axillary artery and vein. It caused to be pushed the vein anteriorly.

Figure 3:



Photomicrograph of the tumor that was formed spindle cells consisting hypo- and hypercellular areas (Haematoxylin-EosinX100).

EP-244[Spine and Peripheral Nerve Surgery]

PECULIARITIES OF TREATMENT OF ATLANTO-AXIAL DISLOCATIONS AT CHILDREN

Sergey Perfil

Department of spinal neurosurgery, Republican scientific centre of neurosurgery, Tashkent, Uzbekistan

INTRODUCTION - OBJECTIVE: Investigation of the peculiarities of treatment of children with atlantoaxial dislocations of preschool age in comparison with the youth.

METHOD: Children up to 7 years were 14 (group 1), 14-18 years - 11 (group 2). Diagnosis based on clinical examination, data radiography, computed tomography and MRI. 6 transchamontagne subluxation, 4 transdermal and 4 with rotary subluxations atlantis were in the 1st group. Among the 2nd group - 6 with transdermal transchamontagne, 2 rotary-subluxations and 1 fracture type «executioner». All patients of the 1st group were without radicular and conductive disorders, and conduction disorders was at 3 patients of the 2nd group

RESULTS: In the 1st group: application of sedately, moderate relaxation and local anesthesia allowed easy to set subluxation and save the achieved position corset at 8 patients. Lumbar happened after local anesthesia and traction small cargoes at 6. Among patients of the 2nd group: subluxation eliminated by Halo apparatus at 2, managed to mend a closed by under General anesthesia with the use of muscle relaxants at 6. An open setting with establishing a system of occipitoparietal produced in one case because of rough instability. In 2 cases were able to achieve results traction small cargoes with fixation of vertebrae corset.

CONCLUSIONS: Due to the plasticity of the spine and weak ligaments in patients of group 1 with spinal injury was often uncomplicated. Subluxations can be removed without surgical intervention. Halo device showed its effectiveness and safety in the treatment of patients with atlanto-axial dislocations in some cases with the using of occipitospondilidosis.

EP-245[Spine and Peripheral Nerve Surgery]

ERRORS DURING THE INSTALLATION OF TRANSPEDUNCULAR FIXATION OF VERTEBRAS

Sergey Perfil

Department of spinal neurosurgery, Republican scientific centre of neurosurgery, Tashkent, Uzbekistan

INTRODUCTION - OBJECTIVE: Investigation of the frequency of errors during the installation of transpeduncular fixation of vertebrae (TPF).

METHOD: We studied the results of treatment of 164 patients. 83 – were with fractures, 77 with tumors, 4 – with echinococcosis. Age - from 14 to 67 years. Diagnosis was based on clinic, spondilogram, CT and MRI. Compression of the spinal cord and the presence of instability were - indications for surgical treatment. Surgical treatment included a total decompression and installation of TPF under radiological control.

RESULTS: The analysis of postoperative control spondilogram showed that at 25 patients had malotice threaded screws (15.24%). 2 cases of them were used screws, not corresponding to the maximum cross-sectional size of the legs of the bows vertebra; 2 cases screw was installed in a broken leg; 3 – the screws were installing in repeatedly formed the screw channel; in 3 cases – screw was going beyond vertebra, 9 screws were installed outside of the arch root with perforation cortical slices; perforation screw the medial wall of the leg of a vertebra in 6 cases. In 5 cases patients with expressed radicular pain were reoperated with correction of standing threaded screws. Analysis of spondilogram throw 12-24 months showed fractures, migration rods and screws, occurred at 4 patients; loss correction of the deformity or residual deformation at 20 patients that were connected with insufficient adaptation longitudinal rods for slots screw-heads and back surface of the vertebral arches.

CONCLUSIONS: High-quality x-ray control and adaptation of rods to the screws will reduce technical errors.

EP-246[Spine and Peripheral Nerve Surgery]

SURGICAL TREATMENT OF PATIENTS WITH INTERVERTEBRAL DISC HERNIATION

Gabit D. Makhambaev, Sholpan M. Kauynbekova, Alexey N. Ivanchenko

Regional Medical Center, Karaganda, Kazakhstan

INTRODUCTION - OBJECTIVE: Hernias of disc are the most common and most severe manifestation of osteochondrosis. Results of surgical treatment of patients with herniated intervertebral discs in the period from 2011 to 2013 at the Regional Medical Center in Karaganda.

METHOD: Over 3 years in the department of neurosurgery patients treated with 394 intervertebral disc hernia. Of them herniated cervical spine 16, lumbar 378 patients.

RESULTS: In most patients, neurological symptoms manifested like pain radicular syndrome 357 (90%), numbness 323 (82 %) had paresis and paralysis of muscles of the lower extremities 134 (34%), dysfunction of the pelvic organs 27 (6%). For surgical treatment applied microsurgical removal of herniated disc, as well applied to stabilize the rear interbody fusion Cage. All patients with herniated cervical disc set cages and with lumbar spine in 73 patients. As a result, surgical treatment was observed a decrease of pain, the positive dynamics of neurological status as a regression of radicular syndromes, increasing motions volume in the lower extremities, also marked improvement in the pelvic organs.

CONCLUSIONS: Application Cage motivated by the fact that there is still the axis of the spine and vertebral mobility in physiological volume. The above data confirm the feasibility and effectiveness of the Cage, in patients with intervertebral disc herniations. That has allowed us to assert the following: use of stabilizing implants shortens recovery and reduce the risk of relapse.

EP-247[Spine and Peripheral Nerve Surgery]

MICROSURGICAL DECOMPRESSION WITH COFLEX INTERSPINOUS DYNAMIC STABILIZATION FOR TREATING LUMBAR DEGENERATIVE STENOSIS

Hossam Abdelhakim Elnoamany

Department of neurosurgery, Menoufia University, shebin elkhayma, Egypt

INTRODUCTION - OBJECTIVE: Degenerative lumbar canal stenosis is a disease affecting population between 40- 80 years of age and is treated by many surgical modalities. Patients suffering from a single level degenerative lumbar spinal stenosis are included in this prospective cohort study. The purpose of this study is to determine efficacy and safety and to analyze the clinical and radiological results of using Coflex device after microsurgical decompression of a single level degenerative lumbar spinal stenosis.

METHOD: Twelve patients with lumbar spinal stenosis who treated by microsurgical decompression and Coflex stabilization were reported. Coflex stabilization was used after decompression of lumbar canal to treat degenerative segmental stenosis. VAS was used to evaluate leg pain and back pain post procedure. The neurogenic claudication distance was also calculated. The median follow-up period was 24 months. Radiographic data was collected and implant position and spinal segment motion was evaluated.

RESULTS: Back pain was significantly improved in 83.3% of patients ($P < 0.05$), while radiculopathic pain was significantly improved in 91.6% of patients ($P < 0.05$). Also significant improvement in walking distance is achieved in 91.6% of the patients ($P < 0.05$). No expulsions or implant migration in postoperative follow-up occurred. Radiographic analysis revealed a significant decrease in spinal segment motion postoperatively during follow-up period.

CONCLUSIONS: Coflex implantation is safe and effective in treating degenerative lumbar spinal stenosis. It is rapid minimally invasive technique with no reported serious complications. It also, demonstrates excellent results along the whole time of follow-up for improvement of back pain, neurogenic claudication and patient's postoperative satisfaction.

EP-248[Spine and Peripheral Nerve Surgery]

CIVILIAN MISSILE AND NON-MISSILE PENETRATING SPINAL INJURIES: REPORT OF 10 CASES

Cihan Isler, Azmi Tufan, Feyza Karagoz Guzey, Ozgur Aktas, Mustafa Vatansever, Yucel Hitay, Sarper Kocaoglu, Abdurrahim Tas, Murat Yucel, Mustafa Ornek, Eyup Cetin

Department of Neurosurgery, Bagcilar Training and Research Hospital, Istanbul, Turkey

INTRODUCTION - OBJECTIVE: In civilian population, spinal missile and non-missile penetrating injuries are rare. Both injuries are mostly located at thoracic levels. Clinical pictures may vary from normal to complete deficit. Its management must be tailored to case specific.

METHOD: The patients with penetrating spinal injury treated between January 2011 to February 2014 were retrospectively evaluated.

RESULTS: Ten patients were evaluated. All were male and they were 17 to 53 years old. Seven patients had missile and 3 non-missile injuries. There were 6 thoracic, 2 cervical, 1 lumbar, 1 sacral involvement. In 4 patients there was not any deficit. All 3 patients with stab wounds had serious deficit, one complete, and two incomplete lesions at thoracic or cervical levels. Two of them required operations for cerebrospinal fistula. Four of 7 patients with cervical, thoracic or sacral missile injuries were neurologically normal. None of them required surgery. Three patients had serious deficits - two paraplegia due to thoracic lesions, and one incomplete cauda lesion with lumbar migrating missile. These three patients were operated for dura repair or removal of migrating missile. After 2 to 37 months follow-up, complete deficits did not improve. Four patients without deficit did not change, and two patients with incomplete cord and one with cauda involvement were improved.

CONCLUSIONS: Civilian missile injuries are usually low velocity lesions and have benign course if they do not initially affect spinal cord even they cause to fracture of vertebrae. However stab wounds affecting the spinal canal are usually serious because they frequently cause to section of spinal cord.

EP-249[Spine and Peripheral Nerve Surgery]

CHANGE THE SAGITTAL BALANCE IN PATIENTS WITH DEGENERATIVE STENOSIS OF THE LUMBAR SPINE

Ivan Igorevich Vasilenko, Vladimir Sergeevich Klimov, Alexey Vladimirovich Yevsyukov

Federal state budgetary institution of the "Federal center of neurosurgery" Russian Ministry of health (, Novosibirsk)

INTRODUCTION - OBJECTIVE: To study changes in the sagittal balance in patients operated on for clinically significant stenosis of the lumbar spine, caused by degenerative-dystrophic disease in the stage of destabilization.

METHOD: lumbar lordosis, hip angle, the angle of the sacrum, the deviation of the pelvis, lumbar lordosis, the top of lumbar lordosis, upper arch lordosis, the lower arch lordosis, the highest point of lumbar lordosis, deviation lumbar lordosis. Type of lumbar lordosis was determined according to the classification P. Roussouly 2005. The indications for surgical treatment was radiculopathy, the syndrome of neurogenic intermittent claudication, or a combination of pathology at the stage the reason of which was Central, lateral or combined sibilant stenosis of the lumbar spine degenerative disease of the spine of destabilization degenerative cascade. In all clinical observations were performed decompressive surgery.

RESULTS: The most frequent in the preoperative period was the fourth type is encountered in 15 (52.1 %) cases, and the most rare is the first type 2 (4.6 %) patients. The second and third types of lumbar

lordosis was observed in 8 (18.9 %) and 5 (24.4 %) patients, respectively. In the early postoperative period, significant changes lumbar and pelvic balance, we have not recorded ($C2=0.0074$, $PI<0.01$). In time, 3 months after the surgical treatment the marked predominance of the third type of lumbar lordosis ($C2=0.027$, $PI<0.05$).

CONCLUSIONS: The peculiarities of spinal-pelvic balance suggests that the patients with degenerative-dystrophic disease of the lumbar spine change spinal-pelvic relationship in most cases are compensatory and are subject to recourse after elimination of clinical manifestations.

EP-251[Spine and Peripheral Nerve Surgery]

TREATMENT OF THE COMPLICATED TRAUMA OF CERVICAL SPINE

Kamaliddin Djumanov

Department of spine surgery, centre of neurosurgery, Tashkent, Uzbekistan

INTRODUCTION - OBJECTIVE: The trauma of cervical spine is the heaviest pathology among injuries of the spine. Among traumatic injuries of the spine 19-22% fall to the share of traumas of cervical department. Thus the anatomy of cervical department of the spine causes high risk of complete transversal lesion of the spinal cord at fractures and dislocations of vertebrae.

METHOD: The clinical analysis included 39 patients operated in the Department of the spine and spinal cord pathology of the Scientific Center of Neurosurgery of Uzbekistan. In the cases of instability and anterior compression of the spinal cord with instability and a forward compression of a spinal cord there were carried out surgeries by the anterior approach - a discectomy. Spondylodesis could be presented by the interbody arthrodesis with a titanic implant.

RESULTS: Results of surgical treatment have been improved: the good and satisfactory result have been achieved in 70,9% of patients in the studied group.

CONCLUSIONS: The prospects of improvement of the outcomes of surgical treatment seem to us in specification of indications and a careful assessment of all possible contraindications in a choice of a type of surgical intervention and improvement of quality of carried-out preoperative preparation and surgical technique.

EP-253[Spine and Peripheral Nerve Surgery]

FUNCTIONAL OUTCOME OF AUTOLOGOUS STEM CELL TRANSPLANTATION IN PATIENTS WITH COMPLETE SPINAL CORD INJURY

Venkata Ramesh Chandra Vemula, Chandramowliswara Prasad Bodapati, Sanjeev Kumar Akula

Department of neurosurgery, SVIMS, Tirupati, INDIA

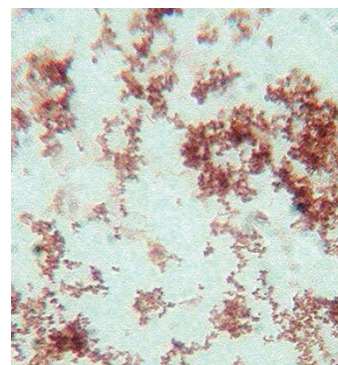
INTRODUCTION - OBJECTIVE: Traumatic spinal cord injury is a devastating condition that causes severe neurological damage. Transplantation of hematopoietic stem cells into the injured spinal cord has been found to improve neurologic functions in experimental animal studies.

METHOD: In present study, we evaluated the therapeutic effects of autologous hematopoietic stem cell transplantation (HSCT) in conjunction with administration of granulocyte-colony stimulating factor (G-CSF) in six complete SCI patients (ASIA grade A). HSCT in the injury site (1×10^6 cells/ml, in a total of 2 mL) and subcutaneous G-CSF administration were performed on six patients. The follow-up periods were from 3, 6 and 12 months

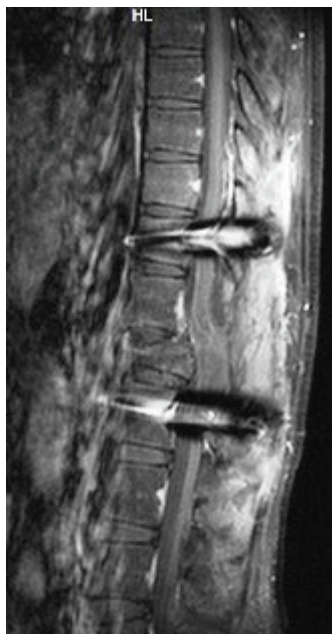RESULTS: Sensory recoveries in the sacral segments were noted at 3 months and motor improvement at 6 months postoperatively. Four patients showed neurologic improvements in their American Spinal Injury Association (ASIA) grade (from A to B). One patient improved to AIS grade D from A and the one patient remained in ASIA grade A. No immediate worsening of neurologic symptoms was found. Side effects of G-CSF treatment such as a fever ($>38^\circ\text{C}$) and myalgia were noted. Serious complications increasing mortality and morbidity were not found. The follow-up study with magnetic resonance imaging at 6 months after injury showed slight enhancement within the zone of HSCT. Syring formation was not found

CONCLUSIONS: This study suggests that transplantation of autologous hematopoietic stem cells into the spinal cord of patients with complete SCI caused no new deficits or serious complications and appeared to be safe and should be made the subject of a more comprehensive multicenter study.

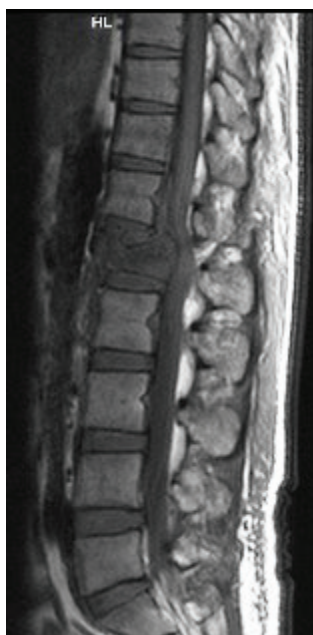fig 1



CD 34+ STEM CELLS



POSTOP MRI SHOWING CONTRAST ENHANCEMENT AT THE SITE OF STEM CELL TRANSPLANTATION



PREOP MRI

EP-254[Spine and Peripheral Nerve Surgery] SACRAL INTRADURAL DERMOID AND EPIDERMOID TUMORS: A CASE REPORT

Abdullah Topcu¹, Mecvi Özdemir¹, Duygu Çeliker², Mustafa Korucu¹, Bayram Çırak¹

¹Department of Neurosurgery, Pamukkale University, Denizli, Turkey

²Department of Pathology, Pamukkale University, Denizli, Turkey

INTRODUCTION - OBJECTIVE: Our aim was to present a rare case with dermoid and epidermoid tumors located intradurally and to discuss treatment methods.

METHOD: A 14-year-old male presented left leg pain and urinary and fecal incontinence. His history revealed a meningomyelocele operation when he was 3 months old. Magnetic resonance imaging showed a dermal sinus tract and 2 intradural extramedullary mass lesions at the S1-2 levels. S1-S2 total laminectomy together with dermal sinus tract and total mass excision was performed.

RESULTS: No complications were observed on the follow-up and the fecal and urinary incontinence recovered. He was discharged on the seventh postoperative day.

CONCLUSIONS: Histopathology evaluation of the excised masses showed one mass to be a dermoid and the other an epidermoid tumor.

EP-255[Spine and Peripheral Nerve Surgery] APPLICATION OF IMPLANTS DAMAGED CERVICAL SPINE VERTEBRAE AND SPINAL CORD

Nurtas I. Tursynov

Department of Neurosurgery and neuropathology, Karaganda State Medical University

INTRODUCTION - OBJECTIVE: In 1995, in the regional medical center introduced the method of open anterior decompression of the spinal cord and stabilize the damaged segment of porous titanium-nickel transplants. It is now necessary to develop optimum tactics of surgical treatment and management of patients in the postoperative period.

METHOD: Investigated the damage of the lower cervical vertebrae and spinal cord in 94 patients who underwent anterior decompression of the spinal cord and interbody fusion screw implants of porous titanium-nickel. Patients ranged in age from 16 to 65 years (20 women and 74 men). Open reduction and anterior interbody fusion screw porous implants in 55 (58.5%) patients were undertaken with fresh damage (in terms of up to 10 days after the injury), 30 (32%) patients with stale (after 11-28 days) and 9 (9.5%) with chronic dislocation of cervical vertebrae (over 4 weeks).

RESULTS: In patients with injuries of the cervical spine including reduction of dislocation Rate during surgery usually is not difficult, porous implant in all cases provide reliable primary stable fixation bodies reduction and underlying vertebrae. 2 days after surgery patients were allowed to get out of bed after 6-8 days the patient is discharged. Within 6-8 weeks. Carried out immobilization of the cervical spine.

CONCLUSIONS: Application of porous implants NiTi alloy with injuries of the cervical vertebrae and spinal cord allows for reliable primary arthrodesis damaged spinal segment without additional trauma patient.

EP-256[Spine and Peripheral Nerve Surgery] RESULTS OF TREATMENT OF THORACOLUMBAR VERTEBRAE INJURIES AND SPINAL CORD

Nurtas I. Tursynov

Department of Neurosurgery and neuropathology, Karaganda State Medical University

INTRODUCTION - OBJECTIVE: Operative methods of treatment for various injuries of thoracolumbar vertebrae using implants with shape memory alloy NiTi possible to Obtain good results.

METHOD: The Observation of 233 patients with fractures of the lower thoracic and lumbar vertebrae, depending on which treatments were divided into three groups. In 1 group consisted of patients in which treatment was used a combined method of single forced followed rear dynamic spondylodesis using implants. Group 2 patients were treated with gradual reclination on a hammock for 24-25 days, followed by the imposition of rigid corset. In 3 groups - patients pneumatic recliner corset kept on the patient a longer time, and then imposed a corset.

RESULTS: 1 group - 60 (26%) patients. Good results in 48 (80%) and 12 (20%); in comminuted fractures in 9 (15%), satisfying 3 (5%). On average, good results have been noted in 38 (63%), satisfactory results in 20 (33%). Unsatisfactory results of 2 (3%). 2 group - 91 (39%). Depending on the type of fracture: a group of the wedge compression fractures of the vertebral bodies - 40 (44%) good results. In the group of wedge-comminuted fractures of the vertebrae good results in 29 (39%), satisfactory 15 (17%). If satisfactory results are comminuted fractures 42 (46%) and bad 2 (2%). Unsatisfactory results - 2 (2%) patient. 3 group - 82 (35%) patients. In the treatment of compression-wedge fractures in 36 (44%) good results. In the group with a wedge-comminuted fractures of the vertebrae good results in 39 (48%), satisfactory in 7 (9%).

CONCLUSIONS: A combined treatment of thoracolumbar vertebrae with injuries alloy NiTi shape memory can improve treatment outcomes.

EP-257[Spine and Peripheral Nerve Surgery] MINIMALLY INVASIVE TECHNOLOGIES IN SURGICAL TREATMENT OF EXTRAMEDULLARY SPINAL CORD TUMORS

Viktor Aleinikov, Talgat Kerimbayev, Yermek Urunbayev, Yermek Kissayev, Baurzhan Yerezhepekov
National Centre for Neurosurgery

INTRODUCTION - OBJECTIVE: The results of surgical treatment of extramedullary spinal cord tumors with ventral localization using minimally invasive technologies is given.

METHOD: From October 2008 to November 2012 136 patients with extramedullary tumors was operated. Intradural localisation was in 77 cases (including 6 cases with extradural component), in 59 cases – extradural localisation. The localisation in the thoracic spine was in 73 cases, the cervical spine 33 cases, the craniocervical region C0-C2 – 15 cases, and lumbar spine - 30 cases. Histological structure of the intradural tumors - 42 meningiomas, 4 cases of atypical and anaplastic - grade II-III tumors, neurofibromas - 34, angiolipoma - 8, metastatic lesions - 1. From extradural tumors - neurofibromas, schwannomas - 17, in one case - anaplastic meningioma. In the remaining 29 cases: Metastatic lesions - 11, hemangioma - 6, fibrosarcoma - 6, osteosarcoma - 2, Ewing's sarcoma - 1, osteoblastoma - 5.

RESULTS: In most cases, at discharge patients showed a significant improvement in neurological status as an increase in the strength and range of motion in the limbs. In 38 cases of the 136 patients the tumor was removed subtotally.

CONCLUSIONS: In most cases, at the time of discharge there was no deterioration occurred in neurologic status.

EP-258[Spine and Peripheral Nerve Surgery] MICROSURGICAL RESECTION OF INTRAMEDULLARY SPINE CORD TUMORS, A SINGLE CENTER STUDY

Talgat Kerimbayev, Viktor Aleinikov, Yermek Urumbayev, Yermek Kissayev, Baurzhan Yerezhepekov
National Centre for Neurosurgery

INTRODUCTION - OBJECTIVE: The analysis of the results of surgical treatment of patients with intramedullary spinal cord tumors is given

METHOD: from October 2008 to October 2013 the 58 patients with intramedullary spinal cord tumors was operated. The number of male and female, respectively 22 and 24, at age of 16 to 64 years, with a mean age of 35 years. The most common localization of the tumor was the cervical and cervico-thoracic level-27(3 cases spread areas of brain stem), rarely in the thoracic level-10, lumbar and thoracolumbar – 7. Histological types (classification of WHO, 2007) were as follows: ependymomas -22 cases (of which mixopapillary grade 1 -16, ependymoma(clear cell, papillary) gr.II -5, anaplastic gr. III -1), astrocytoma – 15(of which pilocytic gr.I -8, diffus , gr.II -5, anaplastic gr.III – 3), anaplastic oligodendroglioma, gr.III -1, choroidal papilloma 2, and 2 hemangioblastoma. The extension of the tumor varied from one(diffuse astrocytoma C3) to eight vertebrae(ependymoma T10-L5).

RESULTS:In 31 cases the tumor was removed totally, in 15 cases subtotal(mainly astrocytomas with infiltrative growth). In 2 cases (anaplastic astrocytoma) patients were re-operated in 8-12 months.

CONCLUSIONS: In most cases, at the time of discharge there was no deterioration or improvement has occurred in neurologic status. Persistent deterioration (up to Group A) was observed in two cases, transient(recovery within 2-4 months to group B) in two cases and to Group C - 2 cases. The use of microsurgical techniques can improve the outcome of surgical treatment.

EP-259[Spine and Peripheral Nerve Surgery] BILATERAL POSTERIOR LUMBAR FUSION BY PRE-CURVED PEEK RODS IN DEGENERATIVE SPINE, CLINICAL OUTCOME AND FUSION ANALYSIS: PRELIMINARY REPORT ON 26 CASES

Viktor Aleinikov, Talgat Kerimbayev, Yermek Urumbayev, Yermek Kissayev, Baurzhan Yerezhepekov
Department spinal neurosurgery, pathology of PNS, National Centre for Neurosurgery, Astana, Kazakhstan

INTRODUCTION - OBJECTIVE: Posterior lumbar instruments made of titanium and its alloys could change the physiological distribution of load at the instrumented and adjacent segments. Posterior lumbar rods made of polyetheretherketone (PEEK) which is a semirigid alternative to titanium and its alloys have been introduced in lumbar fusion. The advantages using this new technology are increased intra- and inter-level load sharing on the anterior column promoting interbody fusion, reduced stress on bone-screw interface decreasing the rate of screw mobilization, intervertebral stability, in the long term, reduced incidence of adjacent level disc degeneration.

METHOD: The authors retrospectively reviewed 26 cases in which posterior fusion was supported by peek rods, analyzing early complications, rate of fusion and clinical outcome. Radiological and clinical outcomes were evaluated, including the fusion rate, visual analog score (VAS) and Oswestry disability index(ODI) and complications. Patients were routinely followed radiographically before surgery, immediately after surgery and at 3 and 12 months after surgery. Fusion was assessed by the operating surgeon using a thin-slice computed tomography (CT) scan.

RESULTS:At an average follow-up of 12 months, both clinical and radiographic results were satisfactory, there were no cases requiring surgical revision for a mechanical complication. It was one case of malpositioning hardware without neurological manifestation.

CONCLUSIONS: The semi-rigid systems using peek rods can now be considered an effective alternative treatment for patients with degenerative lumbar disease in lumbar fusion, although clinical evaluations are necessary in the longer term.

EP-260[Spine and Peripheral Nerve Surgery] MINIMALLY INVASIVE SURGERY FOR STABILIZING THE LUMBAR SPINE IN DEGENERATIVE DISC DISEASES

Viktor Aleinikov, Talgat Kerimbayev, Yermek Urumbayev, Yermek Kissayev, Baurzhan Yerezhepekov
Department spinal neurosurgery, pathology of PNS, National Centre for Neurosurgery, Astana, Kazakhstan

INTRODUCTION - OBJECTIVE: To assess a surgical technique and the postoperative outcomes of a consecutive series of 42 patients treated for degenerative lumbar instability through a minimally invasive unilateral approach associating interbody fusion and percutaneous osteosynthesis.

METHOD: 42 patients were included in this study. All the patients had a signs of lumbar spine instability. Posterior unilateral paraspinal approach through a tubular retractor performed for all cases, the PLIF-cage was inserted in to intervertebral space after discectomy and decompression of a spinal canal. Then after a percutaneous transpedicular fixation was performed. A follow up period for all patients was 12 months. A case control was conducted prospectively at a regular intervals on admission, on the date of discharge and 3 and 12 months after surgery.

RESULTS:There were no complications during surgical procedure in this series. There is a relationship between the learning curve and duration of the operation, showing the necessity of training for the technique. No postoperative neurological deterioration were found. Intraoperative blood loss was less than 200 ml.

CONCLUSIONS: Posterior lumbar interbody fusion through a unilateral approach associated with percutaneous osteosynthesis is a reliable and effective technique in dorsal lumbar spine surgery for unstable segment. The clinical and radiological results are encouraging, with low morbidity and a fusion rate comparable to conventional techniques. However, a longer follow-up will be necessary so as to assess the long-term results of this surgical strategy.

EP-261[Spine and Peripheral Nerve Surgery] DEVELOPING SCLIOSIS PROGRAM IN BRUNEI

Haroon Pillay
dept: of neurosurgery, ripas hospital, Brunei

INTRODUCTION - OBJECTIVE: Scoliosis is a lateral curvature of the spine. Even though it was thought of only as a coronal deformity, now it is well established that it is a 3 dimensional deformity in the sagittal, coronal as well as axial plane. The aim of this presentation is to share our experience in developing scoliosis management in Brunei.

METHOD: Traditionally scoliosis surgery has been the domain of orthopaedic surgeons. Even though neurosurgeons operate on the spine from all angles and do instrumentation, we shy away from doing scoliosis surgery. In Brunei we thought of getting out of this self imposed tradition and start doing managing scoliosis patients. The Ministry of health in Brunei collaborated with AO spine international to bring in experienced scoliosis surgeons and perform and teach scoliosis surgery to the surgeons in our department. As part of our learning process, we also invited young doctors from other countries to participate in the bi annual scoliosis workshops that we conducted in our department.

RESULTS:so far 80 cases of scoliosis has been operated, all with excellent results except one boy who developed a transient neurological deficit. This was because neuromonitoring was not used.

CONCLUSIONS: scoliosis is an exciting field which the young neurosurgeons must think of taking up. It is a fairly safe surgery with excellent and satisfying results especially if neuromonitoring is used. Image guidance or O arm could be an additional tool in the hands of those who are not confident of inserting pedicle screws.

EP-262[Spine and Peripheral Nerve Surgery] MID-TERM POSTOPERATIVE CLINICAL AND RADIOLOGICAL OUTCOMES AFTER MICRODISCECTOMY OF LUMBAR DISC HERNIATION USING TRANSSPINOUS SPLIT TECHNIQUE (TSST): EXPERIENCE OF 12 CASES

Anas Abdallah¹, Erhan Emel¹, Betül Güler¹, Akın Gökçedağ², Mustafa Levent Uysal¹, Müslüm Güneş¹, Ali Ender Ofluoğlu¹, Rashid Avyasov¹, Fatih Cesur¹, Abdullah Emre Taçyıldız¹

¹Bakırköy Research and Training Hospital for Neurology Neurosurgery, and Psychiatry, Department of Neurosurgery, İstanbul, Turkey

²Kanuni Sultan Süleyman Research and Training Hospital, Department of Neurosurgery, İstanbul, Turkey

INTRODUCTION - OBJECTIVE: Both Microdecompression and Microdiscectomy can be achieved using TSST approach. TSST preserves the posterior ramus of the spinal nerve that innervates the paravertebral muscles, so using this technique minimizes atrophy of paravertebral muscles. In this study, postoperative clinical outcomes after microdiscectomy of 12 LDH cases using TSST have been presented.

METHOD: 12 patients operated between the years 2011 and 2013, on the lumbar spine for LDH using high-speed drills under microscope to enter the spinal canal through spinous processes then flavectomy, foraminotomy and microdiscectomy may be achieved. The mid-term clinical and radiological outcomes were evaluated retrospectively. The mean follow-up period was 28 months. The mean age of the patients was 54.9 years.

RESULTS:ODI showed a mean improvement in symptoms from 70.5% to 26.2%, and VAS showed that the intensity of leg and back pain decreased from 8.6 and 8.2 to 2.2 and 2.5 points, respectively. 83.3% of patients indicated that they were satisfied. Dynamic radiographs revealed no postoperative instability after surgery. MRI revealed no paravertebral atrophy less than 8%. One case of those complained of motor deficits did not improve. One patient had been reoperated after 15 months of primer surgery because of her another leg pain.

CONCLUSIONS: The clinical outcomes 2.5 years postoperatively in patients who undergoing TSST for microdiscectomy showed a favorable maintenance of improvement in symptoms. Radiologically had been showed that this approach does not alter the stability of the spine and MRIs revealed no paravertebral atrophy was minimal.

EP-263[Spine and Peripheral Nerve Surgery] SPINAL NAVIGATION IN MIDDLE ASIA: WHERE DO WE STAND?

Abdul Karim Msaddi, Sebouh Kassis, Loay Abukwedat, Catalin Majer, Walid Othman
Neurosurgical and Spinal Department, Neuro Spinal Hospital

INTRODUCTION - OBJECTIVE: Demonstrate the effectiveness of the O-arm based spinal navigation combined to intraoperative pedicle screws stimulation (PSS) in maximizing safety and accuracy of spine instrumentation together with radiation exposure reduction.

METHOD: 64 patients with 405 lumbar pedicle screws were followed in prospective study combining O-arm based spinal navigation with pedicle screws stimulation using 10mA as a threshold for positive response.

RESULTS: 10 screws from 405 (2.5%) needed repositioning, which indicate an accuracy of 97.5% by using O-Arm based navigation. Results of PSS were comparable to 3D scanning in 98%.

CONCLUSIONS: Combining PSS to 3D imaging based spinal navigation maximize the safety and accuracy of instrumentation and avoid unnecessary radiation (in 89% of patients), however this doesn't exclude undetectable screw malposition: 4 patients: 6.2% of the patients (false negative of PSS)

EP-264[Spine and Peripheral Nerve Surgery]

NON TRAUMATIC SPINAL SUBDURAL HEMATOMA: TWO CASE REPORTS AND REVIEW OF LITERATURE

Reza Ghadirpour¹, Antonio Romano¹, Corrado Iaccarino², Anna Pisanello³, Luisa Motti³, Massimo Maggi⁴, Davide Nasi¹, Franco Servadei²

¹Emergency Neurosurgery, Neuromotor Department, IRCCS "ASMN" of Reggio Emilia, Reggio Emilia, Italy

²Neurosurgery Unit, Emergency Department, University Hospital of Parma, Parma, Italy

³Neurology Unit, Neuromotor Department, IRCCS "ASMN" of Reggio Emilia, Reggio Emilia, Italy

⁴Neuroradiology Unit, IRCCS "ASMN" of Reggio Emilia, Reggio Emilia, Italy

INTRODUCTION - OBJECTIVE: Non traumatic spinal subdural hematoma (SSDH) is an uncommon cause of acute spinal cord compression, with initial low back pain, followed by progressive neurological deficit.

METHOD: The authors report 61 cases of non traumatic SSDH (two of their own) from a review of literature from 1998 to 2010.

RESULTS: Case report 1: After a coup cough, a 57-year-old female patient developed back pain and progressive flaccid hemiplegia. The woman was receiving antithrombotic therapy. Case report 2: Two months after surgical treatment for a femur fracture, with anticoagulant prophylaxis with low-molecular-weight heparin, a 75-year-old female patient underwent spinal anaesthesia for persistent dorsal pain without vertebral injury. After five days she developed paraplegia with anaesthesia level from D12. Both patients underwent emergency hemilaminectomy. **RESULTS:** A pure spontaneous aetiology was reported in 36.1% of the all cases, bleeding diatheses in 40.9%, spinal anaesthesia in 16.4% and spinal anaesthesia in patients under anticoagulant therapy in 6.6% of the all cases. The treatment was conservative for 16 patients, aged 51.3±21.7 (AVG±SD), and 45 patients, aged 58.6±20.3 (AVG ± SD), underwent surgery. Paraplegia and anaesthesia distinguished the surgical group.

CONCLUSIONS: The bleeding diatheses represent the main risk factor for non traumatic SSDH but a high incidence of absolute spontaneous onset, without any cause, is reported. The spinal anaesthesia could be an iatrogenic cause especially when performed several times. The surgical evacuation should be performed before paraplegia and anaesthesia are present, while a conservative treatment could be indicated with a minor neurological impairment.

EP-265[Spine and Peripheral Nerve Surgery]

THE ALGORITHM FOR EXAMINATION AND TREATMENT OF PATIENTS WITH SPINAL BONE AND SPINAL CORD DAMAGES

Nurtas I. Tursynov¹, Alexey N. Ivanchenko¹, M. A. Grigolashvili¹, Zh. K. Kalkabaev², A. A. Eskerova², S. E. Ibrayeva², Zh. Kh. Kakimzhanov³

¹Department of Neurosurgery and neuropathology, Karaganda State Medical University

²Regional Medical Center, Karaganda

³Central Hospital of Zhezkazgan

INTRODUCTION - OBJECTIVE: Evaluation of neurological status was conducted by clinical methods patients were distributed into groups, respectively classification of spinal injury ASIA/AMSO.

METHOD: Preoperative design of complicated surgical treatment of unstable spinal injuries: I. Phase - determination of indications for surgical treatment: 1. Determination of localization, extent and type of damage by C. Argenson. 2. Stability or instability of damage 3. Definition of clinical instability by White 4. Determination of the presence and degree of stenosis of the spinal canal, compressing the size and scope of the substrate. II. Phase - development program of surgical correction of existing pathological disorders: 1. Defining the damaged and adjacent segments: deficit injured segment elevation angle and tilt pathological kyphosis III. Phase - determine how surgery: 1. Definitions bone density gradient adjacent vertebral scale Hausfil. 2. Determining the stability of various prosthetic vertebral bodies and discs. 3. Selection of implant size based on available data on the size of the lesion and adjacent segments and height deficit. 4. Determining type of implant. VI. Phase - selection of front locking structure 1. Sizing support vertebrae in the sagittal and horizontal planes with gradient plane bone.

RESULTS: According to the developed algorithm performed planning surgical treatment of complicated spinal injuries.

CONCLUSIONS: Through the use of a large arsenal of surgical interventions on the spine and spinal cord, spinal canal decompression and various types of stabilizing operations, percutaneous vertebroplasty needle, achieved good and satisfactory results.

EP-266[Spine and Peripheral Nerve Surgery]

KYPHOPLASTY - EXPERIENCE OF 94 CASES OF OSTEOPOROTIC VERTEBRAL FRACTURES COMPARED TO OTHERS SURGICAL TECHNIQUES

Lorenza Pereira, Daniel Carvalho Kirchhoff, Luiz Paulo Alves, Fabio Furukawa Okuda, Abel Mitsuo Takey, Rodrigo Gusmao Coimbra, Dierk Fritz Bodo Kirchhoff
Assistencia Neurologica São Bernardo

INTRODUCTION - OBJECTIVE: Approximately 1.5 million fractures secondary to osteoporosis occur in the United States each year; 700,000 of these are spine fractures—more than hip and wrist fractures combined. Worldwide, 1 in 3 women and 1 in 8 men over the age of 50 are affected by osteoporosis

METHOD: We will show in this paper report the positive experience in 94 cases of osteoporotic vertebral fractures, treated with kyphoplasty in compares to others surgical techniques like vertebroplasty We selected only cases with vertebral osteoporotic fractures, with back pain using a simple verbal 0-10 numerical rating scale (verbal NRS).

RESULTS: Kyphoplasty gives surgeons a way to fix the broken bone without the problems associated with open surgery. Unlike open surgery, which involves an incision and the use of larger instruments. The goal of kyphoplasty is to return the fractured vertebra as close as possible to its normal height. This is done by specific and special technique. This reduces pain (verbal NRS) and spine deformity (kyphosis), enabling patients to get back to normal activities

CONCLUSIONS: Our results show kyphoplasty is a safe and effective method to relieve pain (verbal NRS) and correct the deformity associated with an osteoporotic VCF. All patients have a shorter time recovered and pain relieve in 90%, some deficits of strength get also better. The technique are successful about the time in relieving the pain of fractured vertebrae. When well indicated, the method shows better time recovered and pain relieved to the patients

EP-267[Spine and Peripheral Nerve Surgery]

SURGICAL APPROACHES IN THE SPINAL NEUROSURGERY

Nurtas I. Tursynov¹, Gabit D. Mahambaev², Sholpan M. Kauynbekova¹, Alexey N. Ivanchenko¹, Sayat K. Kenzhebaev², A. A. Eskerova²

¹Department of Neurosurgery and neuropathology, Karaganda State Medical University

²Regional Medical Center, Karaganda

INTRODUCTION - OBJECTIVE: During the last decades, neurosurgeons views to the issues of spine surgery significantly transformed. It is now becoming generally accepted view on decompressed stabilizing approach in spine surgery. On the upper cervical common damage transligamentous transdental sprains and Atlant fracture- type "executioner".

METHOD: Surgery is indicated if there are signs of spinal cord compression and the presence of instability in the vertebrae. Spinal fusion creates a reliable primary fixation of the vertebrae. Additional fixation is required. At 4 and 5 types (Francis) "fractures executioner" interbody recommend performing 2-3 spondylosis - cervical vertebrae of parafarinal access and spend together spondylosis interbody implants or autologous bone.

RESULTS: Interbody fusion is performed in several different ways, depending on the installed transplant. Resection of the body's 1-2 vertebral plates developed original titanium retainers, no need for additional fixation. Patients can activate early. Decompressed laminectomy in traumatic injuries continues to be the primary method of eliminating internal, side, rear and front, in some cases spinal cord compression in the thoracic and lumbar spine.

CONCLUSIONS: Achieved goal decompression of spinal cord must be made robust stabilization of damaged segments of the vertebrae. At the final stage of the operation is terminated interbody spondylosynthesis. As Cage clamps apply and shipped clips of the vertebral bodies. Implementation of embedded internal fixation of the vertebrae in the spine surgery allows patients to step up early and begin their rehabilitation.

EP-268[Spine and Peripheral Nerve Surgery]

ALGORITHM OF TREATMENT CERVICAL SPINE INJURY

Nurtas I. Tursynov¹, Gabit D. Mahambaev², Sholpan M. Kauynbekova¹, Sayat K. Kenzhebaev², Alexey N. Ivanchenko¹, Zh. Kh. Kakimzhanov³

¹Department of Neurosurgery and neuropathology, Karaganda State Medical University

²Regional Medical Center, Karaganda

³Central Hospital of Zhezkazgan

INTRODUCTION - OBJECTIVE: Cervical spine injury in more than 44 % of cases are accompanied by spinal cord injury with the appearance of paralysis, the major cause of severe persistent disability. At this level of damage often develop life-threatening disorders in the acute period is due to the upward swelling of the brainstem respiratory depression.

METHOD: Damage stability assessment is key in determining the indications for surgical intervention. We have developed an algorithm of diagnostic measures in spinal cord injury, which is based on the authors' recommendations leading vertebrogenic centers, as well as your own experience. Clinical studies have included an assessment of the degree of disturbance of motor function, physical status and associated injuries involving resuscitation, abdominal and thoracic surgery, urology and trauma. On the basis of a comprehensive assessment of the needs and scope of the alleged interference. Neurological status was assessed by standard clinical methods, followed by the distribution of patients according to the same type of groups according to the 1992 International Society classification Paraplegia Spinal Injury ASIA. On admission all patients underwent spondylography in frontal and lateral projections in the supine position.

RESULTS: Radiographic signs evaluated by the general nature of the damage vertebrae form (angular, sloping) and post-traumatic strain localization, its length, size, nature of the instability of the spinal segment.

CONCLUSIONS: The main methods for determining the degree of compensation of the spinal cord were liquorodynamic sample and multispiral CT, which allowed to choose the method of surgical treatment and efficient access to the affected segment of the spine.

EP-269[Spine and Peripheral Nerve Surgery] NON-TRAUMATIC MYOSITIS OSSIFICANS IN THE LUMBAR SPINE: CASE PRESENTATION

Anas Abdallah¹, Akın Gökçedağ², Erhan Eme¹, Ender Ofluoglu¹, Betül Güler¹

¹Bakırköy Research and Training Hospital for Neurology Neurosurgery, and Psychiatry, Department of Neurosurgery, İstanbul, Turkey

²Kanuni Sultan Süleyman Research and Training Hospital, Department of Neurosurgery, İstanbul, Turkey

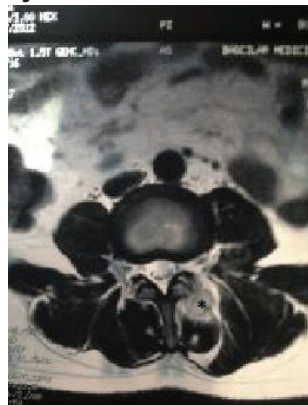
INTRODUCTION - OBJECTIVE: Myositis ossificans (MO) is a non-neoplastic benign reactive bone and cartilage matrix-producing pseudotumor that develops in skeletal muscles adjacent to the joint. The clinical and pathologic appearance of MO will vary depending on the time after heterotopic bone formation. It is rarely occurs in the paravertebral muscle of the lumbar spine. This report describes a rare case of calcifying of myositis ossificans not associated with trauma.

METHOD: A 31 year-old man had referred to our hospital with severe low back pain with restriction of low back motions. Radiological investigation suggested a sclerotic osteoblastic on the left facet joint of L4-5. To confirm the diagnosis, the patient had been managed surgically by total excision of the mass.

RESULTS: The patient had been managed surgically by total excision of the mass which resulted in a good functional recovery. At his 12-month follow-up examination he was neurologically intact, VAS showed that the intensity of the back pain decreased from 10 to 2 points and no recurrence had seen.

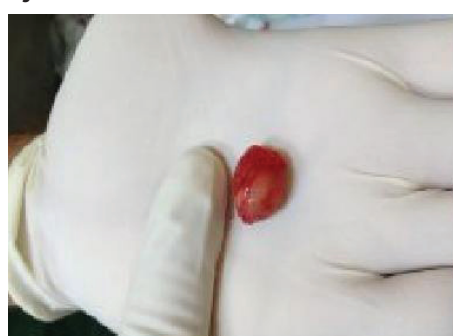CONCLUSIONS: MO appears as a heterotopic, well-defined bone formation in muscles and soft tissues. The etiology is unknown, major injuries or minor traumas are considered as most frequent causes. The most common sites affected are the hip, anterior thigh, anterior arm and in the soft tissues adjacent to elbow joint. In radiological investigations, it is difficult to distinguish this condition from soft tissue and bone malignancy. Therefore, careful correlation of the clinical and radiologic findings with taking a biopsy is necessary to confirm diagnosis of such lesion.

Figure 1



Axial image on T2 weighted MR shows (*): a hyperintense area; inhomogeneous, well-formed shell bony mass above left facet joint of L4-5 that compatible with a sclerotic lesion.

Figure 2



Well-circumscribed, gray-yellow colored and bony solid mass with gritty areas that had excised surgically from the patient.

EP-270[Spine and Peripheral Nerve Surgery] INFLUENCE OF VERTEBRAL BONE MARROW EDEMA ON OUTCOME IN NON ACUTE OSTEOPOROTIC PATIENTS TREATED WITH PERCUTANEOUS VERTEBROPLASTY

Hossam Abdelhakim Elnomany

Department of neurosurgery, Menoufia University, Shebeen Elkaum, Egypt

INTRODUCTION - OBJECTIVE: The influence of bone marrow edema (BME) in non acute osteoporotic vertebral compression fractures (OVCF) on postoperative pain relief in patients treated by percutaneous vertebroplasty (PVP) was investigated in this study.

METHOD: Sixty seven patients with non acute OVCF treated with percutaneous vertebroplasty. They were divided into 56 patients with vertebral BME in their MR images (edema group), and 11 patients with no vertebral BME in their MR images (control group). All patients were treated with PVP. Pain was evaluated two hours, one week, one month, 6 months, and one year post procedure using 10-point Visual analogue Scale (VAS). A statistical analysis including a 2-tailed t test comparing postoperative data with preoperative values were done. Also, medication usage was evaluated as well.

RESULTS: A good clinical response to percutaneous vertebroplasty procedure was seen in all patients. Significant difference was seen between two groups in two hours follow up; in edema group, VAS score decreased from 7.8 before the procedure to 2.4 after (improvement of 5.4). In control group, the score decreased from 7.3 to 4.5 (improvement of 2.8). Regarding pain relief in the other periods of follow up, no

significant difference ($p > 0.05$) was seen between two groups.

CONCLUSIONS: PVP resulted in significant clinical improvement in patients with BME pattern than in those without in two hours follow up period. But the absence of vertebral BME does not influence pain relief in patients with OVCF in one week, one month, 6 months, and one year post procedure follow up periods.

EP-272[Spine and Peripheral Nerve Surgery] MICROVASCULAR DECOMPRESSION OF TRIGEMINAL NERVE ROOT UNDER NEURALGIA OF TRIGEMINAL NERVE WITH USE OF BIODEGRADABLE COLLAGEN HAEMOSTATIC PLATE (BCHP)

Kochkor Tolonovich Mendibaev

Department of Neurosurgery, National hospital at Ministry of Health of Kyrgyz Republic, Bishkek,

INTRODUCTION - OBJECTIVE: To study the results of microvascular decompression of trigeminal nerve root (MDTNR) under neuralgia of trigeminal nerve (NTN) with use of BCHP.

METHOD: Group of 16 patients including 7 males and 9 females of age 41-67. Disease was manifested with paroxysmal pains in innervations zones of the 1st, 2nd and 3rd branches of trigeminal nerve. Length of disease is from 3 to 16 years. 11 patients experienced right-side pains and 5 patients – left-side pains. All patients took various analgesics, had trigeminal nerve alcohol block and microwave destruction. But attacks of trigeminal neuralgia repeated. All patients have undergone brain MRI for the purpose to exclude mass lesion in trigeminal nerve root area. 15 patients had surgery of MDTNR with resection suboccipital trepanation. Microvascular decompression of trigeminal nerve root was carried out using microsurgery techniques and surgical microscope "Carl Zeiss S 88" with 10-12-times magnification. Pressed block of BCHP was input between trigeminal nerve root and a vessel. Only one case has demonstrated lack of neurovascular conflict and rough synechia around the root were disconnected.

RESULTS: During next 24 hours 15 patients with MDTNR reported that neuralgia attacks ceased. 1 patient with disconnected rough arachnoidal synechia reported that trigeminal neuralgia attacks ceased 1 week after surgery. 1 patient reported liquorrhea nasalis which stopped 8 days after surgery. 1 patient reported postprimary septic encephalomeningitis which was cured with strengthened antibiotic therapy.

CONCLUSIONS: MDTNR with use of BCHP under condition of NTN is an effective method of NTN treatment.

EP-273[Spine and Peripheral Nerve Surgery] TREATMENT OF SPONDYLOLISTESIS' HEAVY DEGREE

Feruz Babahanov Hurrarovich, Abdurakhmon Norov Ubaydullaevich

Pathology of spine and spinal cord, Republican Scientific Center of Neurosurgery, Tashkent, Uzbekistan

INTRODUCTION - OBJECTIVE: In spite of achievements in surgery of the spine and spinal cord, spondylolisthesis still remains one of the complex problems of modern neuroorthopedy.

METHOD: In RSCNS since 2000 till 2013 yy. were examined and operated 159 patients, from which 48 patients were with heavy degree of spondylolisthesis. In our analysis we used rethelologic classification of Meyerding for determination the degree of struck vertebra's displacing. Neurogenic claudication lameness were observed within 28 patients, radiculomyeloidischemic syndrome was noted in 10 patients, caudal syndrome was in 5 patients, harbingers of radiculomyeloidischemia were observed in 8 patients, under them we understood temporary vascular breaches of caudal division of spinal cord.

RESULTS: All patients passed the full clinic-neurological and instrumental examination (overview and functional spondilography, computer tomography, magnetic-resonance tomography). All 48 patients with heavy degree of spondylolisthesis were operated. With spondylolisthesis of V degree the operation of Korzh was done to 2 patients, 1 patient was done a 2 grade operation on interbody spondylolysis with out-bone from front access and with imposition of TPF system, 5 patients were made laminectomy with imposition of TPF system, herewith lower screws were entered transcorporally and fixed the omitted vertebra (original method).

CONCLUSIONS: At early postoperative period in 36 patients the root-pain syndrome completely regressed, in 2 patients were saved remaining root pains. Caudosyndrome regressed in 3 patients, radiculomyelohemic syndrome remained in 1 patient. From complications: 2 patients, operated by original methods, was noted the fracture of the heads of lower TPF screws in basis, but herewith the fixation remained reliable.

EP-275[Spine and Peripheral Nerve Surgery] CERVICAL PLATE FRACTURE: AN UNUSUAL COMPLICATION

Veli Çıtışlı¹, Muhammet İbrahimoglu, Serkan Civlan, Murat Kocaoğlu
Pamukkale University, Department of Neurosurgery, Denizli, Turkey

INTRODUCTION - OBJECTIVE: Anterior cervical fusion with plating, anterior cervical spine stabilization for cervical instability in the presence of recognized and this is a technique widely applied in. Anterior approach to the cervical spine surgery in 1955 as the first with the aim of decompression and fusion have been described by Robinson and Smith. Although that this technique was first has been described in the treatment of cervical spondylosis, date cervical trauma, infection, neoplasia, such as kyphosis may develop after laminectomy may be used in iatrogenic instability. In this article we offer, case of operated in our clinic and we apply the two-level cervical plates and cervical plate broken after 2 years of follow-up.

METHOD: After a motor vehicle accident 18 years old male patient was brought to the emergency department. In neurologic examination; confused of consciousness, left hemiparesis and upon detection level of C5-6 dislocation of grade 2 and the patient was operated.

RESULTS: Cervical plaque rupture is one of them, but in this case, as mentioned, albeit short segments can be broken plates. For this reason, patients should be informed about the stabilization of the neck in the postoperative period and demanding excessive neck movement can cause damage to the instrument should be warned.

CONCLUSIONS: The pathology of cervical trauma is stable or unstable about, and which will be banned from the anterior or posterior intervention needs to be done and is still being made in the ongoing debate since time immemorial are available. There are both initiatives their advantages and disadvantages.

Figure 1

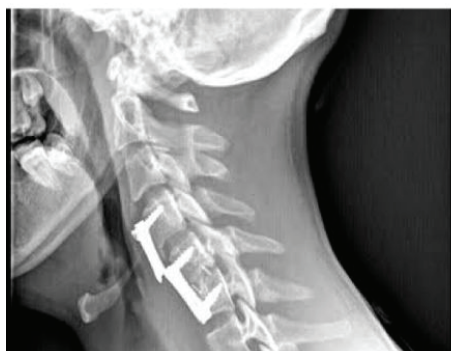

Figure 1: The plate is broken at the level of the C45 anterior disc

EP-276[Spine and Peripheral Nerve Surgery] UNUSUAL PRESENTATION OF MULTIPLE NERVE ENTRAPMENT: A CASE REPORT

Veli Çıtışlı¹, Murat Kocaoğlu¹, Selçuk Göçmen², Mustafa Korumcu¹
¹Pamukkale University, Department of Neurosurgery, Denizli, Turkey
²Private Denizli Surgical Hospital, Department of Neurosurgery, Denizli, Turkey

INTRODUCTION - OBJECTIVE: Cubital tunnel syndrome is the most common form of ulnar nerve entrapment and the second most common entrapment neuropathy of the upper extremity after carpal tunnel syndrome. However, bilateral compressive ulnar neuropathy is a rare condition. Electrodiagnostic studies are a valid and reliable means of confirming the diagnosis.

METHOD: We report the case of a 38-year-old man, a working a cashier, who presented with typical symptoms of bilateral ulnar nerve entrapment and unilateral carpal tunnel syndrome. The diagnosis was confirmed by electrophysiological studies of bilateral ulnar nerve and left carpal tunnel syndrome. The patient fully recovered with surgery. A careful examination of the patient with peripheral nerve entrapment is critical. Multiple nerve entrapment should be investigated differential diagnosis of compressive neuropathies.

RESULTS: As far as we know, both this is the first case of bilateral compression neuropathies described in a cashier and the association of bilateral cubital tunnel syndrome and left carpal tunnel syndrome hasn't been described in cashier exposed to biomechanical risk factors. In so much that, the biomechanical exposure involved in cashier working has not been previously analysed.

CONCLUSIONS: A careful examination of the patient with peripheral nerve entrapment is critical. Multiple nerve entrapment should be investigated differential diagnosis of compressive neuropathies. Fast diagnosis and immediate treatment are mandatory to regain best possible recovery.

Figure 1

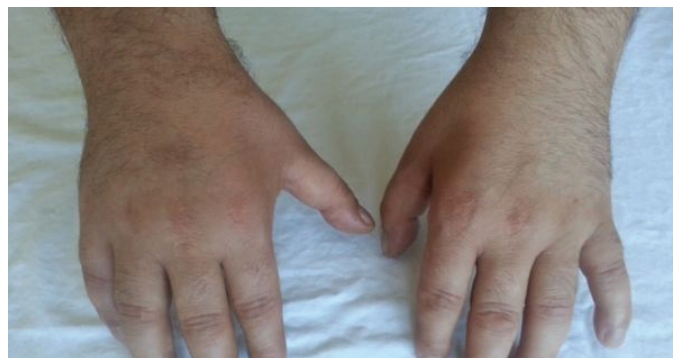

Figure2

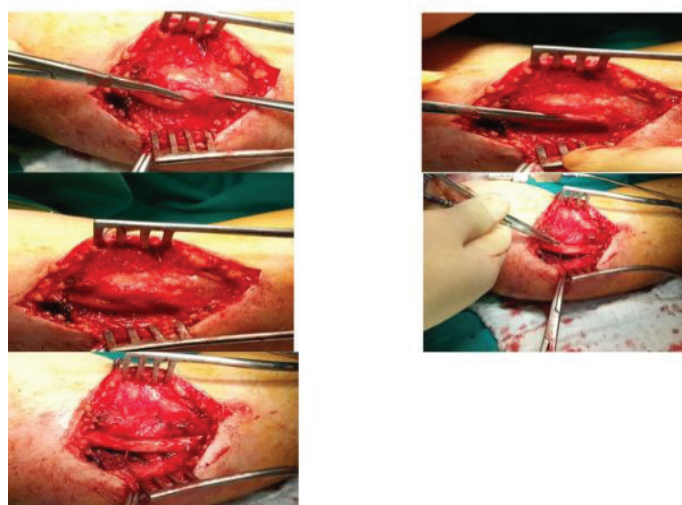


Figure3

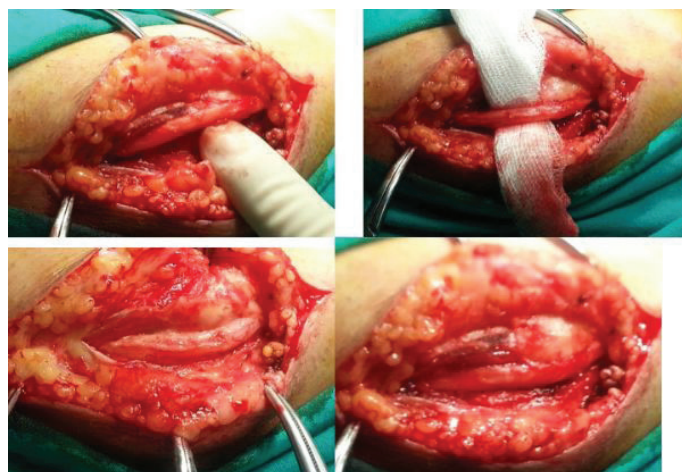


Figure 3: At Operation, The right ulnar nerve was compressed by the adhesive band and muscle

METHOD OF PUNCTURE VERTEBROPLASTY IN THE TREATMENT OF AGGRESSIVE HEMANGIOMAS OF DIFFICULT LOCALIZATION IN THE UPPER THORACIC SPINE

Ramil Tankachev

Department of General Neurosurgery, National Centre for Neurosurgery, Astana, Kazakhstan

INTRODUCTION - OBJECTIVE: The purpose of the study is the estimation of possibility of carrying out transcatheter vertebroplasty in aggressive forms of Th1-Th4 hemangiomas. Percutaneous vertebroplasty was performed to 7 patients with aggressive forms of hemangiomas. Patients with single-level vertebral bodies undergone the surgery. Serious complications after vertebroplasty were not observed.

METHOD: Vertebroplasty was carried out to 4 patients aged 42 to 67 years. There were 2 men (28.5%) and 5 women (71.5%). All of the patients had a diagnosis of aggressive hemangioma. 5 patients (71.4%) had back pain in the clinical presentation. Acute pain syndrome was the indication to perform vertebroplasty. In all these cases only spine surgery performed. Surgeries were performed in the angiosurgical room by using Siemens Somatom Matiz B22 equipment.

RESULTS: Vertebroplasty is preferred to be done under local anesthesia, with the monitoring of vital functions and presence of the anesthesiologist to provide additional analgesia and to avoid unfavorable reactions of the organism. Optimal patient examination algorithm with vertebral body hemangioma must include neurosurgical examination, X-ray, CT, MRI.

CONCLUSIONS: Such signs of aggressive hemangioma as damage (thinning or destruction) of the cortical layer, lesion of 50% of the vertebral body volume, are enough to think about the activity of tumor process. Main indications for the puncture vertebroplasty of patients with body hemangioma are local pain or one or more absolute CT and MRI aggressive signs. Puncture vertebroplasty is the most effective method of treatment of pain syndrome in aggressive hemangiomas.

EP-278[Spine and Peripheral Nerve Surgery] EXPERIENCE OF APPLICATION OF INTRAOPERATIVE NEUROMONITORING WHEN CONDUCTING SURGICAL OPERATIONS ON THE SPINAL COLUMN

Vadim Akhmetzhanov, Ramil Tankachev, Serik Karibay

Department of General Neurosurgery, National Centre for Neurosurgery, Astana, Kazakhstan

INTRODUCTION - OBJECTIVE: To present the experience of the surgical interventions on the spinal column and the peculiarity of conduction anesthesia with the use of intraoperative neuromonitoring.

METHOD: In the period from 2012 to 2014 in the Department of general neurosurgery held surgical treatment using neuromonitoring for 8 patients. According to nosologies patients was as follows: six patients were operated on various degenerative-dystrophic changes of osteochondrosisvertebralis, one patient with benign tumor of spinal cord, and one patient with vertebral compression of the spinal cord due to the spinal injury. Anesthetic management of operative interventions were performed with the use of infusion of propofol and fentanyl. All patients neuromonitoring was carried out using a system NIM Eclipse of company Medtronic with application software "Surgeon directed".

RESULTS: By holding IONM was controlled function of the spinal nerve root, registering electromyographic muscle activity and the function of the spinal cord with a record of motor evoked potentials. Five of the six patients were observed regression radicular pain syndrome when hernia excision, patients with a tumor of the lumbar spine and in a patient with closed spinal injuries to spinal cord compression noted improvement in motor function in lower limbs, increase strength in the legs. In one case, the clinical effect of the surgical intervention remained the same.

CONCLUSIONS: The use of neuromonitoring can improve the results of surgical interventions and to reduce neurological deficit, reducing the frequency of postoperative complications and recovery time.

EP-279[Spine and Peripheral Nerve Surgery] THE INDICATIONS FOR ANTEROLATERAL SPINAL FUSION IN COMPLICATED FRACTURES OF THE THORACOLUMBAR VERTEBRAE

Alexey N Ivanchenko

Department of Neurosurgery and neuropathology, Karaganda State Medical University

INTRODUCTION - OBJECTIVE: Damage to the cervical and lumbar spine constitute 75.4% of all spinal fractures and fractures of the thoracolumbar vertebrae complicated 22% of all fractures that level. **OBJECTIVE:** To determine the indications for anterolateral spinal fusion in complicated fractures of the thoracolumbar vertebrae with current classifications.

METHOD: In 2006-2014 years. 164 hospitalized patients with fractures of the thoracolumbar vertebral level at the age of 18-68 years. All patients underwent puncture with CSF analysis, survey spondylography, myelography, CT. Stable fractures were found in 80 degree compression 1:-80; 2 degrees: -34; Grade 3: -25, explosive-fractures in 25. There were 42 complications in the spinal cord and roots. Anterolateral spinal fusion produced 38 cases, laminectomy-1. Currently, the choice of surgical tactics used classification Denis, and P.Meyer. American Association of spinal injuries suggested unified assessment (scale ASIA).

RESULTS: In complicated vertebral fractures in 95% of cases, there is a front and spinal cord compression of the anterior spinal artery, which creates the need for early anterolateral decompression and interbody spondylodesis stabilization of metal structures. Indications for surgery was: 1) Narrow spinal canal Th11-Th12 over 30-35% 2) Syndrome front artery, venous outflow obstruction 3) Increase in neurological symptoms from the spinal cord 4) Blockage of cerebrospinal fluid pathways 5) Failure of one or two middle pillars 6) Displacement of the vertebral bodies relative to each other by 25 % 7) Pathological kyphosis angle of 20 degrees 8) Decrease in body height by more than 1/3.

CONCLUSIONS: In the presence of 1-4 readings required anterior decompression of the spinal cord; at 5-8 readings needed to stabilize the vertebral-motor segment.

EP-280[Spine and Peripheral Nerve Surgery] RETROSPECTIVE EVALUATION IN SPINAL CORD INJURIES: A SAMPLE AT UNIVERSITY HOSPITAL IN TURKEY

Filiz Altuğ¹, Ayşe Ünal¹, Veli Çitışır², Erdoğan Kavlak¹, Uğur Cavlak¹

¹Pamukkale University, School of Physical Therapy and Rehabilitation, Denizli, Turkey.

²Pamukkale University, Faculty of Medicine, Department of Neurosurgery, Denizli, Turkey.

INTRODUCTION - OBJECTIVE: This study was carried out to evaluate the patients with Spinal Cord Injuries (SCIs) who followed in last ten years in Pamukkale University Hospital.

METHOD: 495 (239 female; 256 male) patients with Spinal Cord Injuries (SCIs) were evaluated retrospectively.

RESULTS: Their mean age was 48.28±18.94 years. They had Spinal Cord Injuries caused by trauma 320 (64.4%), spinal tumors 121 (24.4%) and congenital anomalies 54 (10.9%). Injury levels were recorded as follows: 158 (31.9%) in the lumbar level, 145 (29.3%) in the thoracic, 115 (23.2%) in the cervical, 36 (7.3%) both thoracic and lumbar spine, 10 (2%) both cervical and thoracic and 31 (6.3%) in the other levels. While 51.7% were males and 239 (48.3%) were females.

CONCLUSIONS: This results show that the main reason led to Spinal Cord Injuries was trauma. That's why, education is vital in order to prevent trauma.

Figure 1

Figure 1. Distribution of Gender

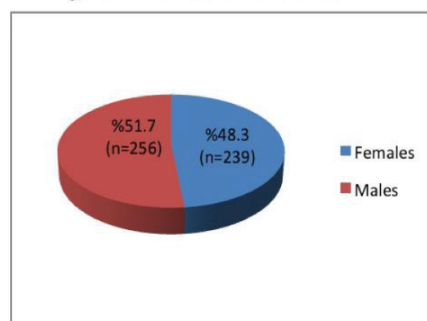


Figure 2

Figure 2. Distribution of Causes of Injury

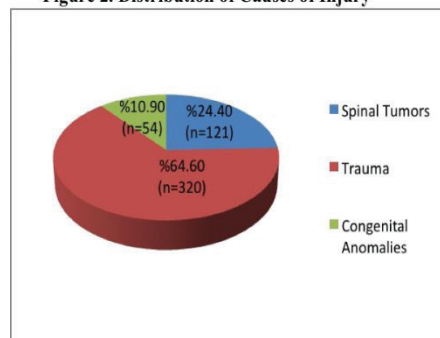


Figure 3

Figure 3. Distribution of Level of Injury

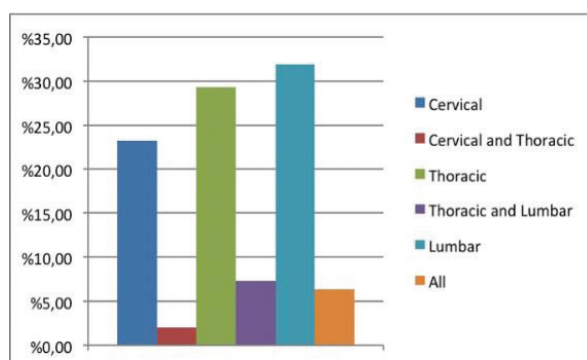


Table 1
Table 1. Demographic Characteristics of Patients with SCIs (N=495)

	N	%
Gender		
Male	256	51.7
Female	239	48.3
Age (Years)		
0-10	11	2.2
11-20	30	6.1
21-30	54	10.9
31-40	81	16.4
41-50	91	18.4
51-60	89	18.0
61-70	72	14.5
71-80	55	11.1
81-90	12	2.4

Table 2
Table 2. Distribution of Injury Causes and Levels

	N	(%)
Injury Causes		
Trauma	320	(64.4)
Spinal Tumors	121	(24.4)
Congenital Anomalies	54	(10.9)
Injury Levels	n	(%)
Lumbar	158	(31.9)
Thoracal	145	(29.3)
Cervical	115	(23.2)
Thoracal + Lumbar	36	(7.3)
Cervical + Thoracal	10	(2)
Others	31	(6.3)

Table 3
Table 3. Distribution of Gender According to Years

Years	Genders		
	Male (%)	Female n (%)	Total n (%)
2005	16 (37.2)	27 (62.8)	43 (100)
2006	42 (53.2)	37 (46.8)	79 (100)
2007	45 (59.2)	31 (40.8)	76 (100)
2008	37 (50.7)	36 (49.3)	76 (100)
2009	26 (55.3)	21 (44.7)	47 (100)
2010	27 (57.4)	20 (42.6)	47 (100)
2011	19 (47.5)	21 (52.5)	40 (100)
2012	25 (46.3)	29 (53.7)	54 (100)
2013	16 (53.3)	14 (46.7)	30 (100)
2014	3 (50.0)	3 (50.0)	6 (100)

Table 4

Years	Injury Causes	n (%)	Injury Levels	n (%)
2005	Trauma	21 (48.8)	Lumbar	17 (39.5)
	Spinal Tumors	18 (41.9)	Thoracal	10 (23.3)
	Congenital Anomalies	4 (9.3)	Cervical	8 (18.8)
			Thoracal + Lumbar	4 (9.3)
			Others	
	Total	43 (100)	Total	43 (100)
2006	Trauma	46 (58.2)	Lumbar	24 (30.4)
	Spinal Tumors	21 (26.6)	Cervical	23 (29.1)
	Congenital Anomalies	12 (15.2)	Thoracal	16 (20.3)
			Cervical + Thoracal	1 (1.3)
			Thoracal + Lumbar	7 (8.9)
	Total	79 (100)	Total	79 (100)
2007	Trauma	53 (69.7)	Thoracal	33 (43.4)
	Spinal Tumors	18 (23.7)	Lumbar	20 (26.3)
	Congenital Anomalies	5 (6.6)	Cervical	14 (18.4)
			Cervical + Thoracal	1 (1.3)
			Thoracal + Lumbar	8 (10.5)
	Total	76 (100)	Total	76 (100)
2008	Trauma	51 (69.9)	Lumbar	23 (31.5)
	Spinal Tumors	13 (17.8)	Thoracal	22 (30.1)
	Congenital Anomalies	9 (12.3)	Cervical	18 (24.7)
			Cervical + Thoracal	4 (5.5)
			Thoracal + Lumbar	4 (5.5)
	Total	73 (100)	Total	73 (100)
2009	Trauma	31 (66.0)	Lumbar	16 (34.0)
	Spinal Tumors	16 (34.0)	Cervical	12 (25.5)
			Thoracal	12 (25.5)
			Cervical + Thoracal	2 (4.3)
			Thoracal + Lumbar	3 (6.4)
	Total	47 (100)	Total	47 (100)
2010	Trauma	31 (66.0)	Thoracal	18 (38.3)
	Spinal Tumors	8 (17.0)	Lumbar	15 (31.9)
	Congenital	8 (17.0)	Cervical	5 (10.6)
			Cervical + Thoracal	1 (2.1)

EP-281[Spine and Peripheral Nerve Surgery] PERCUTANEOUS VERTEBROPLASTY: A FIRST LINE TREATMENT IN TRAUMATIC NON-OSTEOPOROTIC COMPRESSION SPINAL FRACTURES

Hossam Abdelhakim Elnomany

Department of neurosurgery, Menoufia University, Shebeen Elkawm, Egypt

INTRODUCTION - OBJECTIVE: Vertebroplasty is commonly used for osteoporotic and neoplastic compression fractures, yet little evidence exists for its use in traumatic non-osteoporotic compression fractures. The purpose of this prospective cohort study is to document and evaluate the clinical and radiological results of percutaneous vertebroplasty as first line treatment in traumatic non-osteoporotic compression fractures.

METHOD: Twenty three patients with traumatic non-osteoporotic compression fractures and normal bone mineral densitometry scores had been treated with percutaneous vertebroplasty are included. Vertebroplasty consists in the injection of cement (PMMA) in the damaged vertebral body to prevent further collapse of non-osteoporotic spinal fractures. Pain was evaluated two hours, one week, one month, 6 months, and one year post procedure using 10-point Visual analogue Scale (VAS). Ronald-Morris disability Questionnaire (RDQ) scores were also collected. A statistical analysis including a 2-tailed t test comparing postoperative data with preoperative values were done.

RESULTS: Twenty three patients with average age 36 years and 69.5% of them females. Significant improvement in VAS scores both at rest and with motion and in RDQ scores ($P < 0.05$) was achieved. Low rate of insignificant complications was recorded (13%). Radiological data during the follow-up periods showed no collapse in all the injected vertebrae. Significant decrease in rate of medication consumption post procedure was also recorded ($P < 0.05$).

CONCLUSIONS: From this study, it is concluded that vertebroplasty can be used successfully as first line treatment in patients with non-osteoporotic compression spinal fractures. It is also, an effective method to decrease pain, increase mobility, and decrease narcotic administration.

EP-283[Spine and Peripheral Nerve Surgery]

TETHERED CORD SYNDROME IN ADULTS AND ADOLESCENTS: EXPERIENCE OF 23

Erhan Emel¹, Anas Abdallah¹, Özden Erhan Sofuoğlu¹, Ali Ender Ofluğ¹, Betül Güler¹, Akın Gökçedağ², Burak Hasan Gündüz¹, İlhan Aydın¹, Rashid Avasov¹, Fatih Cesur¹

¹Bakırköy Research and Training Hospital for Neurology Neurosurgery, and Psychiatry, Department of Neurosurgery, İstanbul, Turkey

²Kanuni Sultan Süleyman Research and Training Hospital, Department of Neurosurgery, İstanbul, Turkey

INTRODUCTION - OBJECTIVE: Tethered cord syndrome (TCS) is not rare pathological entities especially in children borned for mothers who suffered from folate acid deficiency and usually they are treating surgically. Often leading to termination of pregnancy, the number of children with TCS has been reduced dramatically in Western countries. In contrast, TCS in adults surgery was recommended as soon as neurological symptoms were present. In this study surgical treatment outcomes of our 23 patients of TCS have been evaluated.

METHOD: Medical records were retrospectively reviewed in 23 (15 women and 8 men) cases of TCS who operated between the years 2011 and 2013. The mean follow-up period was 28 months. The clinical outcomes were evaluated. All patients underwent a laminectomy before the filum or the tethering components were transected. The surgery included correction of the additional pathologies if is required. To avoid serious complications, intraoperative neurophysiological monitoring and laminoplasty were performed.

RESULTS: The most common additional pathologies were diastematomyelia (38%) and scoliosis (38%). Seven patients of eight patients whom were seen scoliosis as additional pathologies were underwent posterior instrumentation. The mean of correction angle was 38 degree. Only two patients of six patients whom were detected syringomyelia were underwent surgery for to place T-shunts. 17 patients had been managed successfully, 5 patients had not been improved completely, while one patient had persistent complaints.

CONCLUSIONS: TCS usually is associated with additional pathologies, One of our 23 patients has not additional pathologies, therefore, both of spinal and cranial scanning is needed before planning the surgical treatment.

EP-284[Spine and Peripheral Nerve Surgery]

DIAGNOSTICS AND TREATMENT OF POSTOPERATIVE DISCITIS

Abdurakhmon Norov, Murod Muminov, Mukhsin Rajabov
The Bukhara Branch of RSCEM, Bukhara, Uzbekistan

INTRODUCTION - OBJECTIVE: In the present work given of data of diagnostics and treatments postoperative discitis at the 32 patients for the period 1999-2008 years. The age of patients varied from 18 till 62 years. Men were 22, women 10. To all patients have been performed removing lumbar intervertebral disc herniation.

METHOD: The clinical examination, blood test and MRI was the methods of diagnostics discitis in our research.

RESULTS: The shooting back pain amplifying and irradiating in buttocks and feet at insignificant movements of a spine was the basic symptom of disease at all patients. Intensity of pains was various degree of expressiveness. At 19 (59,4%) patients the temperature were subfebrile, at 3 (9,4 %) patients the temperature were high. Strong paroxysmal painful attacks were observed at 24 (75 %) patients. Pains basically amplified in the evening and irradiated in buttocks, feet, perineum. In 8 (25 %) cases pain irradiated to sacrum and to testicle. At all patients discitis proceeded with spasm paravertebral muscles. At all patients disease has begun in 1-3 weeks after operation. Increase ESR was one of characteristic changes of blood. MRI allowed to reveal presence postoperative discitis in early terms from the disease beginning. Treatment of discitis included antibacterial therapy during 4-6 weeks depending on expressiveness of disease. Immobilization of a lumbar spine with corset 8 weeks. Also patients had relaxants, anti-inflammatory therapy.

CONCLUSIONS: 1. The basic method of diagnostics of postoperative discitis is MRI. 2. Antibacterial therapy and immobilization are methods of choice in treatment of postoperative discitis.

EP-285[Spine and Peripheral Nerve Surgery]

DIAGNOSIS AND TREATMENT OF SPINE HYDATID DISEASES

Abdurakhmon Norov¹, Mukhsin Rajabov², Murod Muminov²

¹Republican Research Centre of Neurosurgery, Tashkent, Uzbekistan

²The Bukhara Branch of RSCEM, Bukhara, Uzbekistan

INTRODUCTION - OBJECTIVE: To confirm that hydatid cyst should be considered in the differential diagnosis for any mass discovered in the spine region and to suggest optimal way of treatment.

METHOD: Under our supervision were 19 patients between 2005 and 2011. In our series the sex ratio was predominant for males, and the mean age was 36 years.

RESULTS: Clinically, patients predominantly presented with a motor deficit: paralysis in 6 cases, plegia in 5 cases and both of them in 4 cases. The MRI confirmed the bone lesion in all of the 9 cases explored, with an intradural cysts in 4 cases and a paravertebral collection in 7 cases. Location of the cysts in lumbosacral part of the spine 9 cases, thoracic spine-6 cases. Medical antihelminthic treatment was indicated as the

sole treatment in two inoperable cases. The recent patients were operated, and the adjunctive specific medical treatment was associated in all cases. Using a posterior approach in 16 cases, the operative technique was consisted in a laminectomy and in achieving by this of the spinal cord decompression. During the postoperative follow-up none of patients died, 6 improved and 11 patients remained unchanged. In two cases developed complications- fistulous course, from which scant discharge and chitin membranes. Recurrence was observed in 11 cases. In 11 cases, a reoperation was indicated and performed from 2 to 4 times.

CONCLUSIONS: Hydatid disease of the spine is rare should be considered in the differential diagnosis. Surgical therapy instituted and chemotherapy administered to achieve optimal and lasting results.

EP-286[Spine and Peripheral Nerve Surgery]

OSTEOBLASTOMA OF THE ODONTOID

Ram Kumar Menon, Praveen K.V

Elite Mission Hospital, Thrissur, Kerala, India

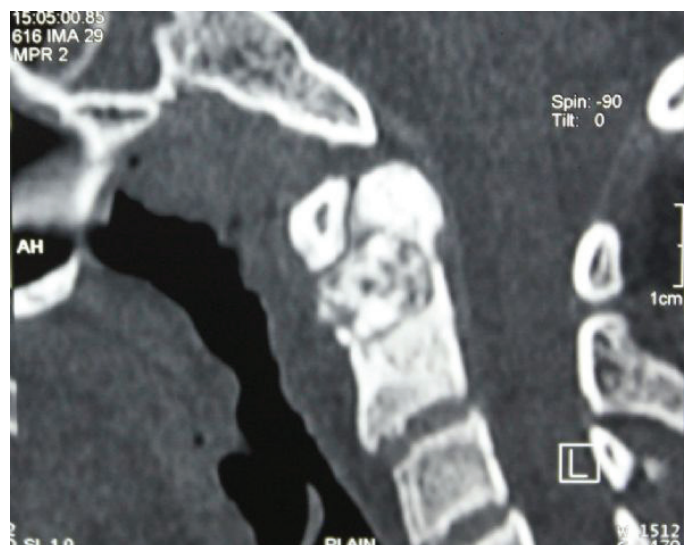INTRODUCTION - OBJECTIVE: We report a case of osteoblastoma of the odontoid in a twelve year old child who presented with intense neck pain, worse at night with sleep disturbance of six months duration. Clinical evaluation revealed torticollis. CT (Computed Tomogram) scan of the cervical spine revealed an expansile heterogeneous lesion with altered morphology with areas of hyperdensity and lytic areas in the odontoid. She underwent transoral odontoidectomy followed by posterior stabilization of the atlas and axis in the same sitting. She was relieved of the pain and the torticollis resolved. Histopathology confirmed the lesion to be consistent with osteoblastoma. In view of the total excision she did not merit further treatment and is presently symptom free 12 months post surgery.

METHOD: The child underwent transoral resection followed by post C1 C2 stabilization

RESULTS: At one year follow up the child is symptom free

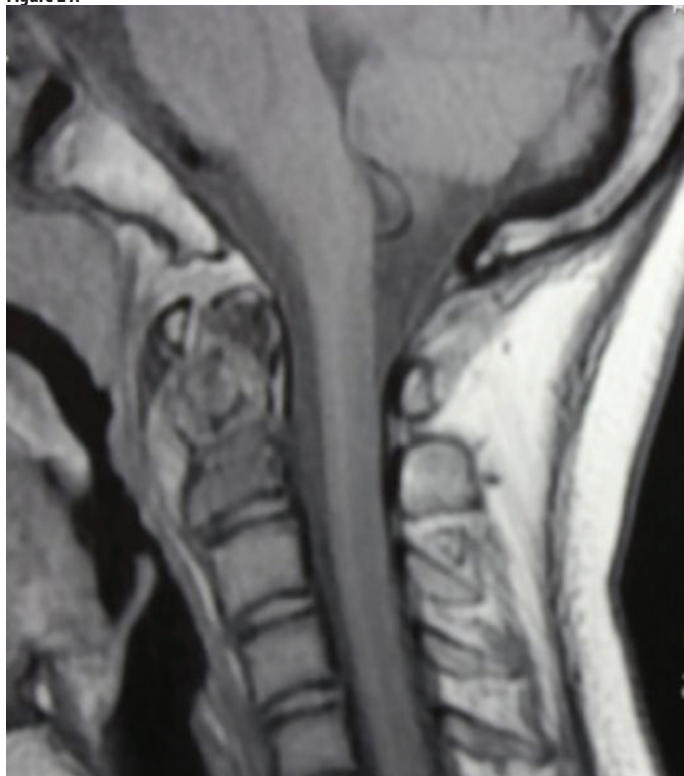
CONCLUSIONS: The optimal treatment involves total resection. Incomplete surgical excision can lead to recurrences. Our child had torticollis and in such cases of torticollis a higher incidence of epidural invasion has been reported, though we could not corroborate the same finding. This was probably the reason the torticollis resolved soon after the surgery. A transoral route provided good access and visualization which helped us in achieving total resection. Radiotherapy and chemotherapy can be used for osteoblastomas, but the potential risk of post-radiation sarcomas must be kept in mind. This case is reported in view of the rarity of C2 osteoblastoma

Figure 1



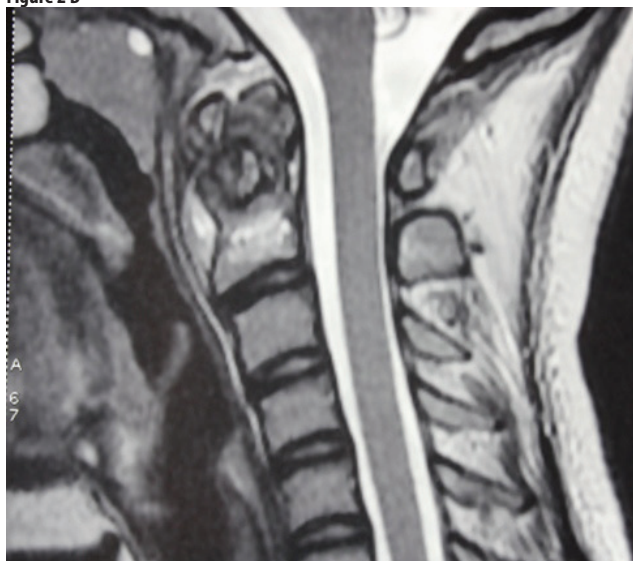
Sagittal CT (Computed Tomogram) of the cervical spine revealed an expansile heterogeneous lesion with altered morphology of the odontoid. The lesion was confined to the base of odontoid and the dens appeared free

Figure 2 A



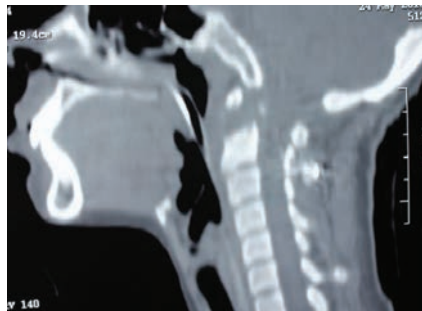
Sagittal T1W image showing the heterogenous expansile lesion involving the odontoid

Figure 2 B



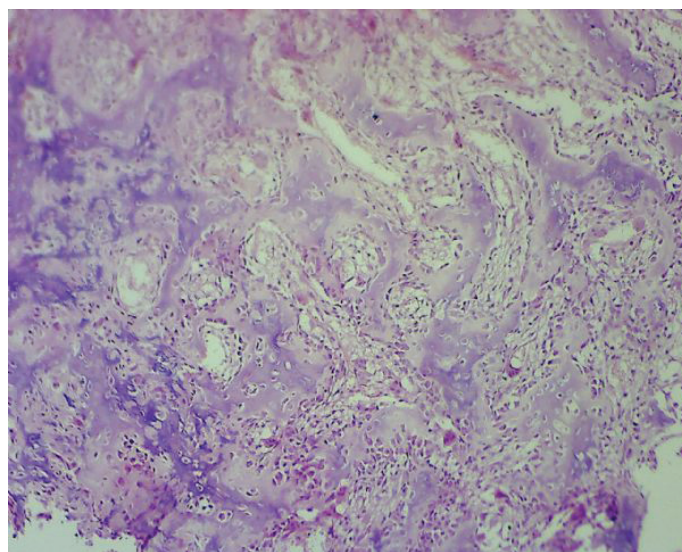
Sagittal T2W image showing the lesion to be predominantly hypointense with areas of hyperintensity. There is evidence of marrow edema at the C2 body. Small prevertebral soft tissue hyperintense lesion noted.

Figure 3



Postoperative sagittal CT scan showing total resection of the odontoid with intact C1 arch and the posterior hardware of the atlas and axis

Figure 4



H&E (X 400) stain showing multiple fragments of a lesion composed of osteoid, some with evidence of mineralization lined by prominent osteoblasts. The osteoid was closely intermingling with highly vascularized connective tissue showing bland spindle cells and small vascular channels

EP-287[Spine and Peripheral Nerve Surgery]

INSTRUMENTATION IN CASES OF SPONDYLODISCITIS AS A VALID TREATMENT OPTION IN THE PRESENCE OF ACTIVE INFECTION

Khaled M.F. Saoud, Ahmed Al Ayouty, Amr Al Shehaby

Department of Neurosurgery, Ain Shams University, Cairo, Egypt

INTRODUCTION - OBJECTIVE: Spondylodiscitis is rare, but it is currently increasing due to reactivation of latent infections, more drug resistant agents, and more immune compromised patients. The role of spinal instrumentation in the presence of active infection is still controversial.

METHOD: In the current study we were trying to find out the effect of single stage debridement and spinal instrumentation on the outcome of patients with active infection.

RESULTS: The study included 21 males (70%) and 9 females (30%) and the mean age was 50 ± 4 years, ranging from 22 to 62 years. The mean VAS score was 8 ± 1 (range, 6-10) before surgery and 2 ± 1 (range, 1-4) at the end of the follow-up period with a highly significant p-value (<0.001) and there was no recurrence of infection in all patients till the end of the follow-up period.

CONCLUSIONS: We can conclude that instrumentation after aggressive debridement is a highly effective and safe method in the treatment of spondylodiscitis in selected patients.

EP-288[Spine and Peripheral Nerve Surgery]

STRATEGY PLANNING AND DECISION MAKING IN ACQUIRED ADOLESCENT DEFORMITY, CASE PRESENTATIONS

Walid I. Attia, Khaled Almusrea, Mohamed Alfawareh

Spine Department, NNI, KFMC, Riyadh, KSA

INTRODUCTION - OBJECTIVE: The type and extent of surgeries carried out in the management of adolescent spine deformities still lacks evidence-based medicine proof. It is up to the health care provider's sound judgement and expertise to do what is needed for the patient. Management challenges include yet not limited to; decompression near vital vascular or neural structures, decompression at a blind angle, difficult deformities corrections and difficult trajectories for instrumentation. The use of intraoperative CT-quality O-arm, and neuronavigation are still tested as aiding tools in such operative modalities.

METHOD: Among our 600+ cases operated with guidance of O-arm and Neuronavigation since 2008, we randomly selected 3 cases of complex spine modalities that were operated upon in our institute by the first two authors to be included in this retrospective study. Cases include traumatic spinal fractures, infective, inflammatory, benign and malignant neoplasms affecting different parts of the spinal column. All of them had technical challenges regarding adequacy of decompression or safety of instrumentation. All had undergone a combination of decompression deformity correction, and instrumentation of different modalities and/or bone grafting. In all cases the Medtronic O-arm® and Medtronic StealthStation® were used as intraoperative mapping tools.

RESULTS: Intraoperative navigation tools were so useful in securing adequate neural decompression, neural and vascular tissue safety together with tough bony purchases of the hardware from the first and only trial of application.

CONCLUSIONS: The intraoperative use of the O-arm and StealthStation is very useful in different modalities of complex spine surgeries.

EP-289[Spine and Peripheral Nerve Surgery]

MULTIFOCAL INTRADURAL EXTRAMEDULLARY EPENDYMOMA: CASE REPORT

Anas Abdallah¹, Akın Gökçedağ², Erhan Emel¹, Betül Güler¹¹Bakırköy Research and Training Hospital for Neurology Neurosurgery, and Psychiatry, Department of Neurosurgery, İstanbul, Turkey²Kanuni Sultan Süleyman Research and Training Hospital, Department of Neurosurgery, İstanbul, Turkey

INTRODUCTION - OBJECTIVE: Ependymomas are the most common intramedullary tumors and occur predominantly in adults. The literature review yielded 19 cases of multifocal intradural extramedullary ependymoma (with the exception of those occurring at the conus medullaris and terminal filum). This report describes the 20th case of such spinal ependymomas.

METHOD: A 31 year-old man had referred to our hospital with low back and left leg pains with progressive paresthesia in the lower limbs, gait disturbance, and urinary incontinence during the last 6 weeks. MRI suggested a multiple intradural extramedullary lesions in the T12-L2 and sacrum that were predominantly isointense on T1-weighted images and hyperintense on T2-weighted images. Intraoperative neurophysiological monitoring was performed. T12-L3 and Sacral bilateral laminectomies were performed at the site of the lesions which detected on MRI. Brownish intradural extramedullary tumors were immediately apparent after opening the dura. Tumor components were soft and they had been total resected surgically by total excision of the mass. The histological examination revealed a WHO Grade II ependymoma.

RESULTS: Postoperatively, preoperative motor deficit of left lower limb remained stable. After 14 days of rehabilitation he was capable of walking independently without support and the distal muscles of the left lower extremity were improved to 4/5 strength, but the urinary incontinence complaint still persistent. On follow-up after 12 months neither recurrence nor progression was occurred.

CONCLUSIONS: Gross-total resection with preservation of neurological function is a choice of treatment. To avoid new deficit or more complications we recommend intraoperative neurophysiological monitoring.

EP-290[Spine and Peripheral Nerve Surgery]

MISSILE INJURY TO THE SPINE SURGICAL OUTCOME AND PROGNOSIS

Ali Hikmat Aziz

Department of neurosurgery, Mosul University, Mosul, Iraq

INTRODUCTION - OBJECTIVE: **OBJECTIVES:** This study was carried out to evaluate the surgical outcome in surgical management of Missile Injuries(MIs) of the spine in comparison to a non-surgical management. Setting: The study was conducted at the Neurosurgical Department of Ibn-Sina Teaching Hospital in Mosul City from August 2010 to October 2011. **BACKGROUND:**

METHOD: Patient and **METHODS:** This is a case series study of (20) patients with MIs to the spine who were managed in the Neurosurgical unit at Mosul Teaching Hospital. The mean age of the patients was thirty years range from eleven to forty four years. In twenty one (52.5%) patients surgery was done, while the rest nineteen (47.5%) patients were managed non-surgically. The main indications for surgery in our patients were: cauda equine injury, spinal cord, nerve root compression and decompression and intra spinal bullet removal. The outcome in these groups were evaluated regarding neurological improvement and mortality. The mean follow up period was five months range from two to eight months.

RESULTS: All these patients had complete radiological assessment including plain X-rays and CT scan examination of the spine of the appropriate spinal level. MRI of the spine was done as indicated and was needed in one patient who has through and through bullet injury.

CONCLUSIONS: **CONCLUSION:** Patient with incomplete neurological injuries especially in cauda equine and cervical injuries showed better surgical outcome compared to non surgical cases in comparison to non-surgical management. There were no difference between the outcome of surgical or non surgical management of complete neurological injuries of the spine.

EP-291[Spine and Peripheral Nerve Surgery]

SINGLE DOSE ANTIBIOTIC PROPHYLAXIS IN LUMBAR STENOSIS OR DISC SURGERY: A REVIEW OF 117 CASES

Zohreh Habibi¹, Zaker Saedinejad², Owrang Eilami²¹Department of Neurosurgery, Children's Hospital Medical Center, Tehran University of Medical Sciences, Tehran, Iran.²Department of Infectious Diseases, Yasouj University of Medical Sciences, Yasouj, Iran

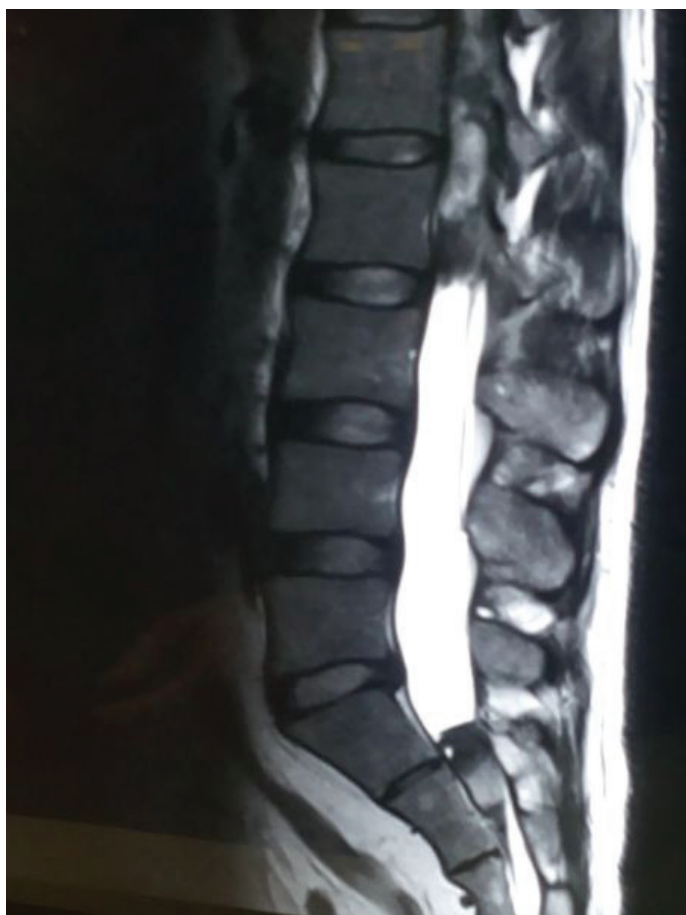INTRODUCTION - OBJECTIVE: Administration of prophylactic antibiotics for disc surgery is accepted by most surgeons, but no universal protocol exists. A retrospective study was conducted to determine the safety and effectiveness of single dose preoperative antibiotics alone in preventing wound infections following single level lumbar laminectomy with or without discectomy.

METHOD: We reviewed 117 consecutive patients (68 males and 39 females) who underwent single-level lumbar laminectomy and medial facetectomy for lumbar stenosis, with or without discectomy during a 10-month period. 2 gr intravenous cefazolin was administered at the induction of general anesthesia. During postoperative period, either in hospital or at home, extra antibiotic prophylaxis was not administered. The wounds were inspected on the first day of surgery at the time of indwelling catheter removal, 10-14 days after surgery for suture removal, and 4 to 6 weeks after discharge.

RESULTS: Superficial wound redness was detected in 2 patients (1.7%) which improved with oral antibiotic, and 1 patient (0.85%) developed discitis that improved with nonsurgical management. None of the patients needed surgical re-exploration for infection or other complications.

CONCLUSIONS: The current retrospective study proved that our antibiotic prophylaxis protocol is safe and efficacious. Assuming that a wound infection rate of about 2% is considered acceptable after a clean spinal operation, a 1.7% rate of superficial incisional wound infections is promising. Also, as the incidence of discitis following discectomy is reported at between 0.75% and 3.0%, 0.85% rate of discitis in our series seems acceptable.

Figure 1



Dorsolumbar MRI of patient.

EP-292[Spine and Peripheral Nerve Surgery] C1 AND C2 MORFOMETRIC EVALUATION BASED ON MULTISLICE COMPUTED TOMOGRAPH SCAN

Gibran Aditiara Wibawa, Firman Adi Sanjaya, Eko Agus Subagio
departement of Neurosurgery, Airlangga University, Surabaya, Indonesia

INTRODUCTION - OBJECTIVE: C1 and C2 cervical spine has different anatomical structure than other cervical spine. Knowledge of anatomical measurement could help during screw insertion to that.
METHOD: A retrospective Observational study evaluate MSCT of C1 and C2 cervical spine. Simple random sampling is used to count the population sampling of the patient undergone MSCT examination between January to December 2012 periods of time in Mitra Keluarga General Hospital Surabaya.

RESULTS: The average width of right C1 lateral mass was 12,59 mm. The average width of left C1 lateral mass was 12,63 mm. The average length of right C1 lateral mass to rostral part of posterior arch was 25,67 mm. The average length of left C1 lateral mass to rostral part of posterior arch was 25,49 mm. The average width of right C2 pedicle was 10,45 mm. The average width of left C2 pedicle was 10,29 mm. The average length of right C2 pedicle was 24,87 mm. The average length of left C2 pedicle was 24,90 mm. The average width of right C2 lamina was 7,03 mm. The average width of left C2 lamina was 7,02 mm. The average length of right C2 lamina was 37,07 mm. The average length of left C2 lamina was 36,75 mm. The average length of C2 odontoid was 36,91 mm.

CONCLUSIONS: C1 and C2 instrumentation procedure have to consider morfometric anatomy to determine the size of the screw. There was no significant different size between right and left side of cervical spine.

EP-293[Spine and Peripheral Nerve Surgery] INTRADURAL EXTRAMEDULLARY PARANGLIOMA AT S1 LEVEL: CASE REPORT

Anas Abdallah¹, Erhan Emel¹, Özden Erhan Sofuoğlu¹, Melih Üçer¹, Akın Öztürk¹, Betül Güler¹, Akın Gökçedağ², Rashid Avasov¹, İlhan Aydın¹

¹Bakırköy Research and Training Hospital for Neurology Neurosurgery, and Psychiatry, Department of Neurosurgery, İstanbul, Turkey

²Kanuni Sultan Süleyman Research and Training Hospital, Department of Neurosurgery, İstanbul, Turkey

INTRODUCTION - OBJECTIVE: Paranglioma (PG) is benign tumor that one of the rare tumors of dispersed neuroendocrine system. Spinal PGs are rare entities. This report describes a rare case of PG presented to our outpatient polyclinics of neurosurgery department with radicular and local low back pain.

METHOD: A 43 year-old woman had referred to our outpatient polyclinics of neurosurgery department with low back pain and both legs pain (in left leg was more) for 4 months which started suddenly. Neurological examination was unremarkable. MRI revealed on predominantly isointense on T1-weighted images and hyperintense on T2-weighted images with diffuse contrast enhancement of the intradural extramedullary lesion located between L5-S1 and there was a herniation of L4-5 which extruded to press on the left L5 root. Total L5 and partial L4 laminectomies were performed. Solid weight-coloured, intradural extramedullary tumor was immediately apparent after opening the dura. Tumor had been total resected surgically by total excision of the mass. L4-5 microdiscectomy was performed.

RESULTS: Tumor cells showed Synaptophysin(-), S-100(minimal +), Glial fibrillary acidic protein(-) and Chromogranin(+) with hypercellular nodules showing a Ki 67 index of 10%; so all these findings prove that the lesion was PG. Postoperatively, CSF leak was seen as complication. The patient had been managed surgically resulted in a good functional recovery. Postoperative MRI confirmed total excision of the tumor. On follow-up after 3 months neither recurrence nor progression was occurred.

CONCLUSIONS: The vast majority of these tumors are intradural, and found within the cauda equina. Gross-total surgical resection is possible in most cases.

EP-294[Spine and Peripheral Nerve Surgery] USE OF MICROSCOPIC EQUIPMENT AT A DISCECTOMY ON LUMBAR DISC HERNIATION

Ibragimbek Galiev, Serik Karibay, Ramil Tankacheyev
General Neurosurgery Department, National Center for Neurosurgery, Astana Kazakhstan

INTRODUCTION - OBJECTIVE: OBJECTIVES: Hernia of an intervertebral disc is the most frequent pathology of a spine. Now neurosurgeons continue to use a set of methods of surgical treatment for a herniated lumbar disc: with application of binocular optics, under control of endoscopes, various optical systems. Use of an operational microscope and microsurgical tools considerably expands visualization during removal of hernia of a disc and a decompression of structures of the spinal channel.

METHOD: MATERIAL- METHODS: Microscopic removal of herniated lumbar disc is executed to 180 patients. Earlier the binocular optics was used. Operations under control of a microscope were performed from the minimum access with use of the principle of Key-Holl. Manipulations carried out under control operational microscope Carl-Zeiss, used retractors, microsurgical tools.

RESULTS:RESULTS: Intraoperative complications it wasn't Observed. Use of a microscope allowed keeping small vessels of the spinal channel, to track totality of removal of structures of a hernia bulge. Regress of clinical symptomatology and radicular pain syndrome was noted at all patients. Sensitivity violations in the postoperative period regressed at 126 (70%), at 54(30%) – in the form of a weak hypoesthesia and a paraesthesiae. Force of muscles of feet considerably increased. In the early postoperative period physiotherapy, medical gymnastics, early activation, acupuncture that improved rehabilitation was carried out.

CONCLUSION: use of a microscope and microsurgical equipment at a discectomy of lumbar disc herniation allows controlling an interoperation situation and most to reduce appearance of surgical treatment complications.

EP-295[Spine and Peripheral Nerve Surgery] MOTION PRESERVATION SURGERY: ANTERIOR CERVICAL MICROFORAMENOTOMY- HOW I DO IT

Sim Khairun Nabi Khan, Robert Ahmed Khan, Moshir Rahman, Md. Ruhul Kuddus
department of neurosurgery, BSM Medical University, Dhaka, Bangladesh.

INTRODUCTION - OBJECTIVE: The cervical spine is the most mobile part of the spinal column. It is a great concern of the spine surgeons to preserve the motion of the segment in the same time dealing the pathology, whenever possible. Elimination of the motion of a cervical segment is likely causes extra load on the adjacent segments and hence early degeneration.

METHOD: To address this problem various surgical techniques and artificial cervical disc have been proposed. Anterior cervical micro-foramenotomy is one of the surgical technique where the natural disc is preserved at the same time only the herniated portion of the disc is removed. In the presentation, I will discuss a surgical technique of managing the pathology with preservation of the functioning intervertebral disc.

RESULTS: Total 18 cases were treated. Male-12, female -06. Age range from 25-47yrs. all patient showed improvement of radiculopathy.

CONCLUSIONS: Anterior cervical microforamenotomy excellent surgical technique for treating lateral cervical disc prolapse causing radiculopathy without myelopathy.

EP-296[Spine and Peripheral Nerve Surgery] PERCUTANEOUS VERTEBROPLASTY: A NEW TECHNIQUE MINIMIZING CEMENT LEAK

Hossam Abdelhakim Elnoamany
Department of neurosurgery, Menoufia University, Shebeen Elkaum, Egypt

INTRODUCTION - OBJECTIVE: Since introduction of vertebroplasty to clinical practice, the cement leak is considered the most frequent and hazardous complication. In literature, the cement extravasation ranged from 26-97% of the time. This study discussed a new technique for injecting cement in the affected vertebra.

METHOD: A hundred and twenty three patients were treated by vertebroplasty using the current technique. The package of the cement powder and the solvent was divided into five equal parts. Each part of the powder and the solvent was mixed as a single dose and injected to the affected vertebra. The duration between subsequent injections was 10 minutes. Each injection is formed of 1- 1.5 ml. of cement.

RESULTS: This new technique gives the surgeon enough time to make multiple separate injections with the same package. The time interval between injections makes cement harden enough and makes it not pushed by the next cement injection. This technique of injection gives time to the injected cement to seal off the cracks and cavities in the vertebra and subsequently leads to a highly significant decreased in cement leak ($P < 0.001$) compared to the literature.

CONCLUSIONS: This report demonstrates a previously unreported technique for vertebroplasty that adds more safety to the procedure by significantly decreasing cement leak. It also, gives the surgeon much more relaxation and confidence during performing the procedure.

EP-297[Spine and Peripheral Nerve Surgery] REVIEW MORPHOMETRY THORACAL VERTEBRAE 1-12 BASED ON MSCT

Zaky Bajamal, Achmad Zamroni, Eko Agus Subagio
Departement of Neurosurgery, Airlangga University, Surabaya, Indonesia

INTRODUCTION - OBJECTIVE: Each thoracic vertebra spine have different anatomical structure. To know morphometry description vertebra thoracal 1-1

METHOD: This study is Observational description study to know morphometry description vertebra thoracal 1-12 at patient with MSCT examination in Mitra Keluarga Hospital Surabaya January-December 2012, age 18-60 years old without past traumatic or vertebra thoracal anomaly.

RESULTS: Total population in this study 26 with male 17 and female 9. Axial pedicle diameter T1(6,87mm), decline until T4(3,84mm) and increase until T12(6,63mm), Male axial pedicle diameter (4.35mm-7.52mm) greater than female (3.7mm-6.7mm), The smallest sagittal pedicle diameter T1 increase until T12, Male average T1-T12(9.11-13.72mm) and female T1-T12(8.15-13.38mm), Angulation curve narrow from T1-T12, T1(29,94o)-T12(5,61o), Pedicle length increase from T1(12,53mm) until T12(19,18mm), The shortest pedicle-corpus length T1(21,55mm) the longest at T12(29,53), The shortest sagittal corpus length at T1(20,17mm) longer T12(27,51mm)). Spinal canal to transverse process-costae line distance and the longest extrapedicle line T1(11,92mm), shorter until T9(6,26mm) and longer again until T12(7,31mm), The widest extrapedicle angulation T1(51,24o) decrease until T9(32o) and wider until T12(32,74o)

CONCLUSIONS: Thoracal morphometry useful in instrumentation procedure transpedicle and extrapedicle. In instrumentation application, length and diameter thoracal screw every level must be differentiated, adapted with length and diameter measurement every level, there were different between male and female size, right and left size is the same.

EP-298[Spine and Peripheral Nerve Surgery]

ANALYSIS OF PATIENTS OPERATED WITH FULL ENDOSCOPIC LUMBAL DISCECTOMY

Osman Boyali, Yavuz Aras, Pulat Akin Sabancı, Aydın Aydoseli, Altay Sencer, Nail Izgi, **Onur Öztürk**
Department of Neurosurgery, Istanbul Medical Faculty, Istanbul University, Istanbul, Turkey

INTRODUCTION - OBJECTIVE: Percutaneous endoscopic lumbar discectomy (PELD) is a method aiming to protect the stability and mobility of the spine by decrease tissue trauma and fibrosis, depending on this to make patients get back to their normal daily life in a short period and avoid the iatrogenic complications. As a minimal invasive surgical intervention PELD is executed frequently in the last decade and leads to change routine spinal surgical interventions as result of development of radiological imaging, endoscopic devices and surgical devices upto endoscopy.

METHOD: The cases of the patients with lumbar disc herniation that underwent interlaminar or transforaminal endoscopic lumbar surgery between August 2009 and January 2012 in the department of Neurosurgery of Istanbul Medical Faculty are evaluated retrospectively. The demographic characteristics, symptoms, finding, the sides and the levels of disc herniations, pre and postoperative neurological examinations, the choice of the surgery (interlaminar or transforaminal), pre and postoperative MRI finding, pre and postoperative Oswestry and VAS scores and the complications of the patients were evaluated.

RESULTS: The preoperative mean visual analog pain scale scores decreased from 8 (min:5 – max:10) to 2 (min:0 – max 7) postoperatively. The mean preoperative Oswestry score were 38 (17-50) and it was found to be 13.5 on the third month and 9 on the sixth month control.

CONCLUSIONS: This study shows PELD is a safe and effective method. Additionally this is the first study that compares radiological and clinical results. And also as a result PELD is a minimally invasive method in terms of epidural scar formation and radix edema.

EP-299[Spine and Peripheral Nerve Surgery]

METASTATIC PROSTATE CARCINOMA TO THE INTRADURAL EXTRAMEDULLARY SPINAL COMPARTMENT: A CASE REPORT

Melih Üçer, İlhan Aydın, Sarper Polat, Abdullah Emre Taçyıldız, İbrahim Alataş
Bakirkoy Research & Training Hospital for Psychiatry, Neurology and Neurosurgery

INTRODUCTION - OBJECTIVE: prostate cancer is second only to lung cancer as the leading cause of cancer-related deaths in men. It is the third most common carcinoma and accounts for approximately 10% of all cancers in men, with a noted increased incidence in African Americans. Considering all cancers, presentation in the intradural extramedullary space is rare, occurring in fewer than 5% of patients. Although adenocarcinomas are the most common tumors to metastasize to the intradural extramedullary space, prostate cancer in this location is extremely rare, with only three cases reported in the literature.

METHOD: our case 61-year-old male patient with previously undiagnosed cancer. The back pain worsened with coughing, sneezing, straining, and particularly, recumbency. Only partial pain control was achieved despite maximal medical therapy. He did not complain of headache, weakness, or sphincter dysfunction.

RESULTS: Spinal MR imaging revealed diffuse metastatic disease involving multiple vertebral levels but no evidence of epidural compression. We also observed a contrast-enhancing L1–2 intradural extramedullary lesion filling the spinal canal.

CONCLUSIONS: Metastases to the intradural extramedullary space are rare, occur in the advanced stages of cancer, and are associated with a high incidence of synchronous brain metastases. In particular, prostate carcinoma metastases presenting as focal masses to this spinal compartment are extremely rare. The intraoperative and neuroimaging finding, in conjunction with patients' short survival times, suggest that even focal involvement of the intradural extramedullary space by metastatic disease should be considered part of the spectrum of leptomeningeal carcinomatosis.

EP-300[Spine and Peripheral Nerve Surgery]

CENTRAL CORD SYNDROME AND CERVICAL SPINE SUBLUXATION

Anna Karakouti, Dimitrios Koutentakis, Vasilios Moraitis, Dimitrios Arvanitakis
NEUROSURGERY CLINIC VENIZELEIO GENERAL HOSPITAL HERAKLION GREECE

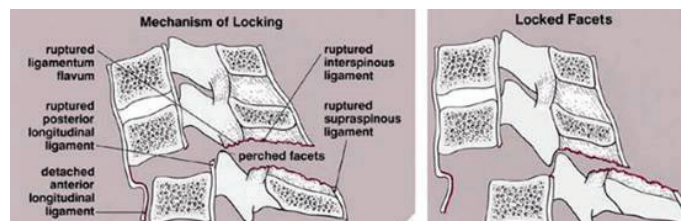
INTRODUCTION - OBJECTIVE: Male 52 years was admitted after falling on 3 meters high. He developed comminuted bilateral fractures of the rear arches A6, A7, T1 vertebrae with accompanying full dislocation and sliding 5th grade to A7 on the T1 vertebra (spondyloptosis), so that the rear surface of the A7 comes into contact with the front surface of the T1 vertebra (subluxation). During the clinical evaluation, patient with normal mobility and sensibility of the upper and lower extremities.

METHOD: Performed posterior approach with cranial traction and laminectomy of C7 – T1 by removing the articular apophyses which has been developed bilateral (unlock the locked facets) and restoration of subluxation of the C7 on T1 by about 50% and finally a posterior fusion to A5–I3.

RESULTS: At the 10th postoperative day, the patient has experienced numbness of the upper limbs and took conservative treatment with corticosteroid pharmaceutical formulation for a period of 10 days. At the 20th postoperative day performed anterior cervical interbody A7–I2 in situ and marked improvement of clinical symptoms of the numbness to upper limbs.

CONCLUSIONS: After 7 days the patient was discharged ambulatory, hemodynamically stable, afebrile, with no focal neurological signs. In this report we are referring to the signs of a central cord syndrome.

Picture1



EP-301[Spine and Peripheral Nerve Surgery]

THE EFFICIENCY OF PERCUTANEOUS VERTEBROPLASTY ON OSTEOPOROTIC VERTEBRAE FRACTURES

Ahmet Ozdilmaz¹, Osman Nuri Turkmenoglu¹, Halit Cavusoglu², Adem Yilmaz¹, Ahmet Murat Musluman¹, Songul Meltem Can¹, Yunus Aydın²
1ŞİŞLİ ETİFAL EDUCATION AND RESOURCE HOSPITAL, İSTANBUL

²MEMORIAL HOSPITAL, İSTANBUL

INTRODUCTION - OBJECTIVE: Osteoporosis is a chronic disease, commonly seen in elderly, that effects their daily lives negatively. The major complication of it is osteoporotic vertebra fracture, the aim of the therapy in these fractures is to provide stabilization, to decrease pain and returning to daily routine life with early mobilization of the patient.

METHOD: This study includes 172 patients with osteoporotic fractures of vertebra, 102 women and 70 men, all treated with percutaneous vertebroplasty between January 2002 and January 2013, and results are evaluated statistically and compared with the literature.

RESULTS: Percutaneous vertebroplasty is a minimal invasive procedure, biocement is injected percutaneously into the affected vertebra through a needle placed into the vertebra transpedicularly. Patients were evaluated before, 24 h after and 1 month after the operation with VAS method and ODI test. With the data we got from these tests, we determined the change in the intensity of pain and quality of their lives. This statistical comparison proved that, PV remarkably decreases pain and provides early returning to daily life.

CONCLUSIONS: As there are so many similar studies in the medical literature, our study also makes us to conclude that percutaneous vertebroplasty in osteoporotic vertebra fractures, is a safe, effective, fast and minimally invasive method.

EP-303[Stereotactic and Functional Neurosurgery]

INITIAL EXPERIENCE OF MICROVASCULAR DECOMPRESSION IN TREATMENT OF HEMIFACIAL SPASM

Azat Shpekov, Yerbol Makhambetov, Chingiz Shashkin, Faizulla Smagulov, Mynzhylky Berdikhojayev, Assylbek Kaliyev
Department of Vascular and Functional Neurosurgery, National Centre for Neurosurgery, Astana, Kazakhstan

INTRODUCTION - OBJECTIVE: An initial experience of surgical treatment of hemifacial spasm (HFS) is presented.

METHOD: From May 2009 to April 2013, 16 patients underwent microvascular decompression (MVD) for hemifacial spasm at our Institute. Based on the operation and medical records, the intraoperative findings and post-operative outcomes were obtained and analyzed.

RESULTS: A total of 16 patients (13 female and 3 male) who underwent MVD during the time period specified were identified. Their mean age was 47 years (range 25–62 years). The symptom duration was 4 months–21 years (mean duration 10.4 years). Postoperative outcomes were determined by reviewing records and through telephone interviews. The median follow-up duration in all cases was 3 years (range 1–5 years). 10 (62.5%) patients experienced immediate relief and 3 (20%) had resolution of symptoms within three months of surgery. Thus, complete remission of facial spasm occurred in 13 (86.7%) of 16 patients. 1 (6.7%) patient had recurrence after 3 months and 2 (13.3%) patients had no improvement. 1 (6.7%) patient had CSF rhinorrhea, which was managed by surgical re-exploration and leak repair. Transitory facial weakness occurred in one (6.7%) patient (Grade II on the House-Brackmann scale). Permanent hearing loss occurred in no patients.

CONCLUSIONS: It is hard to draw any conclusions, given the small number of patients and the relatively short duration of follow-up. Although the absence of intraoperative monitoring should not prevent neurosurgeons from performing MVD in patients with HFS, an attempt is made to develop of neurophysiological support.

EP-304[Stereotactic and Functional Neurosurgery]

EXPERIENCE WITH LUMBER PUNCTURE FOR OBSTRUCTIVE HYDROCEPHALUS PATIENTS FOLLOWING ENDOSCOPIC SURGERY

Zhiqiang Hu¹, Zhuang Kang¹, Guangtong Zhu¹, Jian Tu², Hui Huang¹, Feng Guan¹, Bin Dai¹, Beibei Mao¹
¹Department of Neurosurgery, Beijing Shijitan Hospital, Capital Medical University, Beijing, China

²The Prince of Wales Hospital, University of New South Wales, Sydney, Australia

INTRODUCTION - OBJECTIVE: Currently Endoscopic third ventriculostomy (ETV) has been the preferred procedure for Obstructive hydrocephalus. The goal of this study was to explore the effect of postoperative lumbar puncture following ETV for Obstructive hydrocephalus patients.

METHOD: 145 patients presenting with Obstructive hydrocephalus underwent ETV in our department between 2008 and 2013. Following ETV, all patients received lumbar punctures 1 and 3 days after surgery.

RESULTS: For 106 patients, intracranial pressure (ICP) returned to normal levels and symptoms associated with high ICP ceased. In 39 patients, intracranial pressure remained high and they continued to receive lumbar punctures every other day for a period of 11 days post-surgery. These patients were divided into two groups for analysis: group A (<18 years old) and group B (>18 years old). Intracranial pressure of both groups increased initially before decreasing to normal values. Peak values of ICP for groups A and B occurred on days 3 and 5, respectively.

CONCLUSIONS: Overall, postoperative lumbar puncture is important to determine the effect of surgery or treatment on transient high ICP after ETV. For most of these symptomatic patients with Obstructive hydrocephalus, lumbar punctures were effective in bringing about fast normalization of ICP and cessation of adverse symptoms.

EP-305 [Stereotactic and Functional Neurosurgery] BILATERAL PALLIDOTOMY BY USING DEEP BRAIN STIMULATION ELECTRODE IN PARKINSON'S DISEASE

Feridun Acar¹, Selçuk Göçmen¹, Murat Kocaoglu¹, Serkan Civlan¹, Chingiz Shashkin², Göksemin Acar³

¹Department of Neurosurgery, Pamukkale University, Denizli, Turkey

²Department of Neurosurgery, National Center for Neurosurgery Astana city, Republik of Kazakhstan

³Department of Neurology, Pamukkale University, Denizli, Turkey

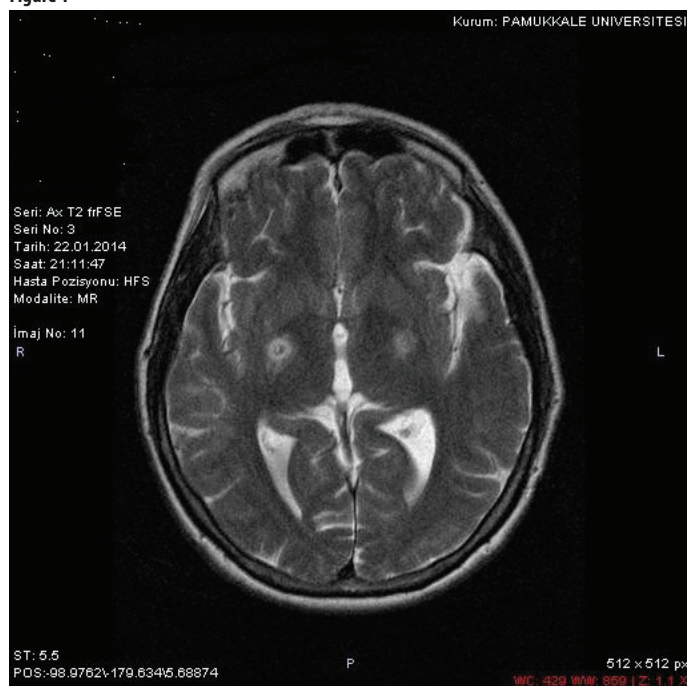
INTRODUCTION - OBJECTIVE: There are reported cases in the literature of deep brain stimulation (DBS) electrodes used effectively to perform unilaterally radiofrequency lesions in the treatment of movement disorders. In some patients, deep brain stimulation (DBS) electrodes may need to be removed due to hardware infection. We report a case who underwent bilaterally pallidotomy using DBS electrodes.

METHOD: A 49-year-old woman with Parkinson's disease who had undergone bilateral globus pallidus interna deep brain stimulation, developed skin erosion over the DBS hardware. The hardware was removed due to repeated infections. Radiofrequency bilateral pallidotomy was performed by using the existing DBS electrodes (3387-40; Medtronic, Inc., Minneapolis, Minn., USA). The lesions were created at 100mA for 60 seconds (NT-1100 Neurotherm RF generator). The tip of the electrode was heated 60 seconds. The tip was then withdrawn 2 mm and heated for another 60 seconds.

RESULTS: Lesion position and size were confirmed with magnetic resonance imaging. After the bilaterally pallidotomy, the patient had good and stable control of PD.

CONCLUSIONS: The RF lesioning technique by a DBS electrode is a safe technique and can produce therapeutic benefit.

Figure 1



After bilaterally pallidotomy by using DBS electrode

EP-307 [Stereotactic and Functional Neurosurgery]

A CASE OF INTRACRANIAL HYPOTENSION COMPLICATED WITH HYDROCEPHALUS

Melih Üçer, İlhan Aydın, Sarper Polat, Abdullah Emre Taçyıldız

Bakirkoy Research & Training Hospital for Psychiatry, Neurology and Neurosurgery

INTRODUCTION - OBJECTIVE: Intracranial hypotension may have variable clinical presentation. The imaging characteristics of intracranial hypotension are especially well depicted on magnetic resonance imaging studies. Although the clinical and radiological manifestations of spontaneous intracranial hypotension are increasingly recognized in many reports, many other abnormalities in this disorder and complicating cases still exist.

METHOD: A 16-year-old patient suffering from nausea, vomiting and blurred consciousness was admitted to the hospital. MRI showed diffuse pachymeningeal thickening resembling intracranial hypotension and ventricular enlargement like compensated hydrocephalus. The patient was investigated and treated using endoscopic third ventriculostomy.

RESULTS: The authors presented a case of intracranial hypotension complicated with hydrocephalus.

CONCLUSIONS: Specific causes for intracranial hypotension as well as additional new treatment options will also be discussed.

EP-308 [Stereotactic and Functional Neurosurgery]

RECONSTRUCTIVE SURGERY IN CRANIOBASAL LESIONS COMPLICATED WITH LONG-TERM CSF LEAKAGE

V. Okhlopkov, A. Potapov, A. Kravchuk, L. Likhterman, D. Kapitanov, A. Gavrilov

The Burdenko Neurosurgical Institute, Moscow, Russia

INTRODUCTION - OBJECTIVE: Results of surgical treatment of long-term basal CSF leakage depending on the type of intervention are presented.

METHOD: 253 patients aged 3-71 years (mean 27,6) were operated from 1988 to 2013. CSF leakage was complicated by meningitis in 44,8% of all cases. Time between CSF leakage occurrence and surgery varied from one month to 25 years, average 2,7 years. We used autologous tissues alone for plastic reconstruction in all patients. 135 of them were operated with the application of fibrin-thrombin glue.

RESULTS: Intracranial intervention was combined with recurrent lumbar punctures following surgery - 46 cases; CSF leakage recurrence was revealed in 10 Observations (21,7%). Later on (136 cases) methods of intra- and postoperative external drainage of the lumbar CSF (average - 8 days) were used. CSF leakage recurrence was marked in 15 cases (11,1%). In the first 17 cases we performed percutaneous drainage installation; 23,5% of meningitis in this series. By a «long-tunnel» method of the CSF drainage (119 patients) meningitis was observed in 6 patients (5,1%). In 5 cases, when CSF leakage was combined with intracranial hypertension, the skull base plasty was carried out together with the shunting operation; CSF leakage recurrence was marked in 2 cases (40%). CSF fistula closure was performed by the transnasal approach in 51 cases; CSF leakage recurrence was marked in 8 cases (15,7%). Shunting operation alone was performed in 15 patients. CSF leakage recurrence with decreased CSF leakage volume was marked in 3 cases (20%).

CONCLUSIONS: Best results of surgical treatment of long-term basal CSF leakage with the verified CSF fistula were achieved by using combination of intracranial intervention and intra- and postoperative CSF drainage.

EP-309 [Stereotactic and Functional Neurosurgery]

MEDICAL JUDGMENT OF A NEUROSURGEON

Leonid Likhterman, Alexander Potapov, Alexander Kravchuk, Vladimir Okhlopkov

The Burdenko Neurosurgery Institute, Moscow, Russia

INTRODUCTION - OBJECTIVE: to define the role of medical judgment in high tech neurosurgery.

METHOD: 3852 verified cases of surgically significant head injury sequelae; analysis of neuroimaging techniques and conceptual approaches to treatment.

RESULTS: modern neurosurgery experiences technological boom and crisis of medical judgment and ethics. Medical judgment is a reliable antidote against: 1) a loss of skills of neurological examination (hyposkillia) and imaging-based diagnosis; 2) a syndrome of doctor-patient disconnection and disregard for patient's personality. Medical judgment in preventive neurosurgery allows to see an asymptomatic person behind an abnormal image (CT or MRI scan) and make a decision about surgery (is it necessary, and (if the answer is "yes") when and how to perform intervention) based on probability of danger to patient's health in future. Efficacy of medical judgment which fosters the use of minimally invasive surgery is illustrated by marked improvement of outcomes of posttraumatic basal CSF-leakage, hydrocephalus, chronic subdural hematomas, skull defects etc.

CONCLUSIONS: a neurosurgeon should be educated in philosophy, methodology and ideology. In order to remain a humane physician and avoid becoming a cog in the modern neurosurgery machine he or she should master medical judgment at full breath.

EP-310[Surgical Neuroanatomy]

SPONTANEOUS CEREBROSPINAL FLUID RHINORRHEA: TWO CASE REPORTS

Veli Çitışlı¹, Funda Tümkaya², Necdet Ardic²¹Pamukkale University, Department of Neurosurgery, Denizli, Turkey²Pamukkale University, Department of Ear, Nose and Throat, Denizli, Turkey

INTRODUCTION - OBJECTIVE: Spontaneous nasal cerebrospinal fluid (CSF) fistula represents a rare clinical entity. In our study isolated cribriform plate defects and bony defect between the extra- and intracranial space were found in both two patients and the aim was to assess the real effectiveness of an endoscopic endonasal approach for treating cerebrospinal fluid leaks of the congenital cribriform plate defects.

METHOD: We had two adult cases with defect in the left cribriform plate was Observed in cranial tomography of the paranasal sinuses. The patient was operated together with the department of ENT (Ear, Nose and Throat) and Neurosurgery.

RESULTS: During the operation CSF flow was Observed in the junction of left middle concha lateral and the laminated kribroz. The ethmoid bulla and then ethmoid cells by proceeding from the lateral anterior were opened. Muscle and fascia graft getting from right postauricular incision from the temporal muscle was placed and secured with tissue adhesive in the defective area. Middle concha was used as a flap. Antibiotic prophylactic therapy was used. Preoperative and postoperative complications were not seen.

CONCLUSIONS: Endoscopic repair of anterior skull base CSF fistulas has a high success rate and lower morbidity and mortality when compared with open approaches. Transnasal endoscopic repair of cerebrospinal fluid fistulas is recommended for patients with CSF leaks who do not respond to conservative treatment. It is a safer and more successful than transcranial surgery. In the case of both cribriform plate defect, cranial bone graft also may an excellent material for endoscopic reconstruction of skull base defects.

Figure 1

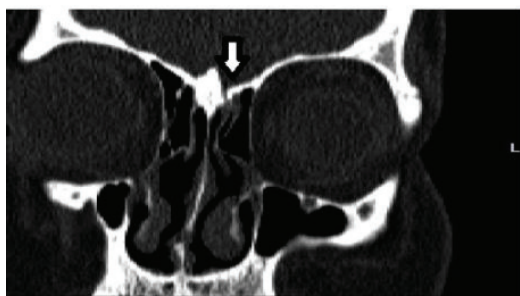


Figure 1: Paranasal CT view of 41 years old the patient with congenital defect in cribriform plate

Paranasal CT view of 41 years old the patient with congenital defect in cribriform plate

Figure2

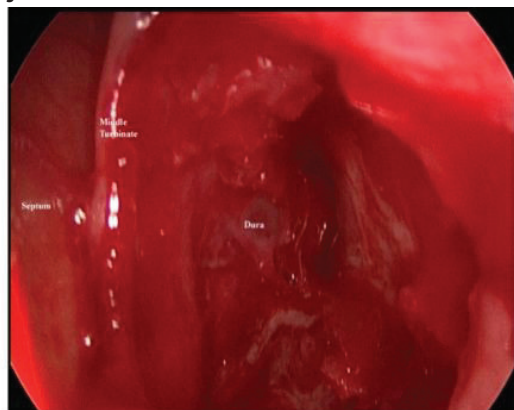
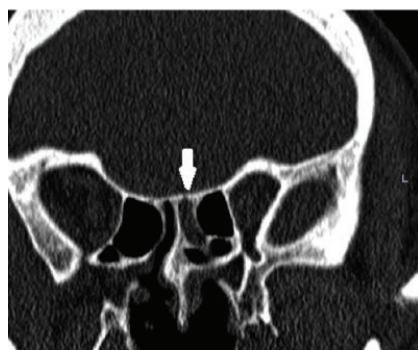


Figure 2: Intraoperative view of 41 years old the patient with congenital defect in

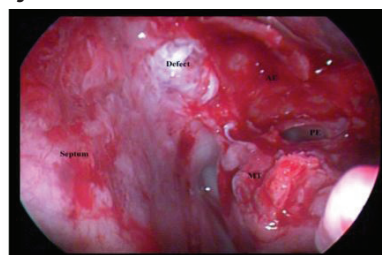
Intraoperative view of 41 years old the patient with congenital defect in cribriform plate

Figure3



Paranasal CT view of 50 years old the patient

Figure4



Intraoperative view of 50 years old the patient with congenital defect in cribriform plate. AE: Anterior ethmoid, PE: Posterior Ethmoid, MT: Remnant of middle turbinate

EP-311[Surgical Neuroanatomy]

SUPERFICIAL TEMPORAL ARTERY TO PROXIMAL POSTERIOR CEREBRAL ARTERY BYPASS VIA THE ANTERIOR TEMPORAL APPROACH

Satoru Takeuchi¹, Rokuya Tanikawa², Toshiyuki Tsuboi², Kosumo Noda², Junpei Oda², Shiro Miyata², Nakao Ota², Hiroyasu Kamiyama²¹Department of Neurosurgery, National Defense Medical College, Saitama, Japan²Department of Neurosurgery, Teishinkai Hospital, Hokkaido, Japan

INTRODUCTION - OBJECTIVE: The superficial temporal artery (STA) to proximal posterior cerebral artery (PCA) (P2 segment) bypass is one of the most difficult procedures because proximal PCA is located deep and high within the ambient cistern. The STA to proximal PCA bypass is usually performed by subtemporal approach or presigmoid transtentorial approach, and is rarely performed via transsylvian approach. The aim of this study was to describe the operative technique of STA to proximal PCA bypass by a modified transsylvian approach.

METHOD: We applied the STA to proximal PCA bypass by a modified distal transsylvian approach (anterior temporal approach) in three cases with intracranial aneurysm. We describe the details of the surgical technique.

RESULTS: In all cases, the STA was successfully anastomosed to proximal PCA. One patient suffered hemiparesis due to anterior thalamoperforating artery territory infarct. No bypass-related complications occurred in any patient postoperatively.

CONCLUSIONS: The STA to proximal PCA bypass can be performed via anterior temporal approach in selected patients. However, high level skills are required to achieve bypass in a deep surgical field.

EP-312[Miscellaneous]

HOW USEFUL THE CRANIOMAPPER IS, FOR 2-D LOCALISATION OF LESION DURING CRANIOTOMY

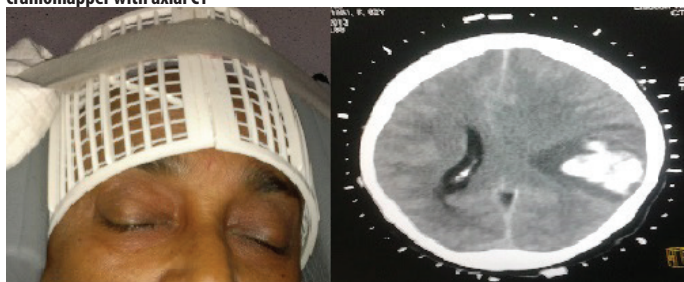
Pralaya Kishore Nayak
neotia getwel healthcare centre

INTRODUCTION - OBJECTIVE: Localizing smaller lesion in brain and while marking for craniotomy is sometime a difficult and cumbersome task. At time we miss the margin by few millimeters, which lead to the use of brain retraction and or bone resection. This is particularly true in high convexity area where the landmarks are Obscured and reference bony points are far.

METHOD: Craniomapper (Surgiwear, India) is an external plastic frame, embedded with radio-opaque markers placed around the patient head during CT scanning. CT topogram is superimposed over the frame. The radio opaque markers are visible on axial plane

RESULTS: The author tried the use of Craniomapper in two patients with high parietal convexity spontaneous bleed where wide craniotomy was not indicated. In all the cases craniotomy was centred exactly over the pathology.

CONCLUSIONS: It is safe to use the frame and need no special training. It is also not costly and can address the issue, where image guidance/stereotactic system are not available.

craniomapper with axial CT

EP-313[Miscellaneous]

RETROMASTOID CRANIOTOMY AND EXCISION OF CPA TUMOURS IN ONE STAGE: REVIEW OF RESULTS OF 73 CASES

Mohammed Nuruzzaman Mohammed Nuruzzaman Mohammed Nuruzzaman
Neurology Centre-Central Defence Hospital

INTRODUCTION - OBJECTIVE: There are controversies to do or not to a CSF drainage procedure before CPA tumour surgery. Our team practiced one staged retromastoid craniotomy and tumour excision. It not only avoids VPS, but surgical time and expenditures also. We have studied 73 cases operated upon.

METHOD: Our hospital are enriched with a trained neurosurgical team of 3 surgeons 2 anaesthesiologist, CT scan, MRI and DSA facilities. Our standard equipments are (1) 14 position micro-neurosurgical OT table, Mayfield and Sugita head-frame type II, microsurgical instruments, self-retaining retractor, ultrasonic aspirator and microscope. All the diagnosed cases of CPA tumours are entered for the review study. Duration was July 1992-june 2013. Patients data were entered into study proforma.

RESULTS: Duration was July 1992-june 2013 and number of patients were 117 of which 73 were operated by retromastoid craniotomy and tumours were excised in one stage. Male were 29 and female 44, aged 26-54 yrs. Stage I-13, Stage III-38, stage IV-22 cases. Hearing and CNS functional recovery were satisfactory-29 cases, good-24, no change 09 and worsen 10 cases. We keep EVD in 23 cases for brain swelling. Our study showed reduction of surgeons hours, hospital stay and cost of treatment. Mortality were 3/73.

CONCLUSIONS: Our review study concludes retromastoid procedure for CPA tumours is an operation demands high skill and support of anaesthetic procedures, post operative NICU and required instruments. One stage retromastoid craniotomy and excision of CPA tumours reduces surgeons working hours, hospital bed occupancy and cost of treatments.

EP-314[Miscellaneous]

CHOICE OF SURGICAL TREATMENT TACTICS AT CHIARI MALFORMATION

Bekzod Abdullaevich Saidov¹, Laziz Usmonov¹, Rano Ismoilova¹, Gayrat Kariev²

¹Republican research center of neurosurgery

²Tashkent medical Pediatrics Institute

INTRODUCTION - OBJECTIVE: Presently, the problem of surgical treatment of Chiari malformation in spite of numerous researches is still actual. The purpose of the research is to analyze the results and to choose the best surgical tactics in patients with Chiari malformation.

METHOD: The work is based on results of surgical treatment of 41 patients with Chiari malformation treated in the Centre of neurosurgery since 2010. According to the presence of hydrocephalus all patients were divided into 2 groups: First group has made 30 patients with clinical features of cerebellum tonsils ectopy into the foramen magnum without signs of hydrocephalus. 11 patients from the second group

presented basically with the symptoms of increased intracranial pressure. MRI images showed the hydrocephalus with tonsils ectopy up to 32 mm. Acoustic brainstem evoked potentials showed irritation of the upper olivary complex in both groups.

RESULTS: The depth of surgical intervention was defined under the monitoring of evoked acoustic brainstem potentials. Single decompression of craniocervical angle was performed at 20 patients from the first group. 10 patients were undergone the additional resection of tonsils with duraplasty. At 6 patients in second group due to severity of hypertensive syndrome two stepped surgery was performed. Before the decompression of craniocervical angle the recovery of CSF circulation was reached by ETV or shunting. At 5 patients the resection of tonsils with duraplasty was performed.

CONCLUSIONS: Application of intraoperative monitoring is the proved method of efficacy of surgery at Chiari malformation.

EP-315[Miscellaneous]

THE RESULTS OF SURGICAL METHODS OF TREATMENT DURING REMOVING OF ABSCESES OF THE BRAIN

Abdurakhmon Mamatkulovich Mamadaliev, Saodat Abdurakhmonovna Mamadalieva
Neurosurgery Department of Samarkand State Medical Institute, Samarkand, Uzbekistan

INTRODUCTION - OBJECTIVE: The aim of the presented investigation is to improve the results of surgical interventions of AB on the basis of devised and improved methods of surgical treatment. In this investigation it has been included 101 surgically operated patients during the period from 2001 to 2013.

METHOD: The age of the patients varies from 5 to 59 years old. In 65,1% of patients it was diagnosed contact abscesses, in 21,7% of patients it was diagnosed abscesses of the metastatic etiology and in the left 13,2% of patients it was diagnosed abscesses of posttraumatic genesis; for the 75,9% of patients it was performed computer tomography, for the 24,1% of patients it was magnet resonance imaging and in 45,8% of cases it was determined unicameral, in 27,8% of cases it was determined 2-3 cameral and in 26,5% of multi-cameral abscesses.

RESULTS: Depending on the localization, sizes and amounts of AB, to the patients it has been performed different surgical operations: due to the indications it was used total removing (with capsule) of AB or puncture of abscess cavity with the following drainage and with placing of flash-ti t system which was devised by in our clinic. As a result of this system it has been decreased mortality rate from 23% to 17%, it has been accelerated neurological deficits with restoration of the brain function with the different compensation degrees.

CONCLUSIONS: So, placing of "flash-ti t" drainage system after surgical operations due to AB could increase the effectiveness of the treatment and early rehabilitation of the patients.

EP-316[Miscellaneous]

MICROSURGICAL RESECTION OF INTRACRANIAL DERMOID

Mumtaz Ali, Akram Ullah, Ramzan Hussain, Bilal Khan Afridi
Department of Neurosurgery, Govt. Lady Reading Hospital, Peshawar, Pakistan.

INTRODUCTION - OBJECTIVE: Microsurgical resection is the prime modality for treating intracranial dermoids. To know about the outcome of the microsurgical resection of intracranial dermoids

METHOD: this descriptive study was conducted in Neurosurgical Department between July 2010 to September 2013. All the patient with suspected intracranial Dermoids on imaging study pre-operatively or diagnosed per-operatively were included. Patient with recurrent dermoid (initially encountered), not willing for surgery and those who were not fit for surgery were excluded. The demographic record, clinical and radiological feature were documented before surgery on a predesigned Proforma, per-operative findings and natural history after removal was also documented. Data was entered and analyzed using SPSS version 16 and was expressed in the form of tables and charts.

RESULTS: a total of 27 patients were operated during the study with 12 males and 15 females. The age range was from 13 to 39 years. The most common presentation was headache. The lesion was located in the midline in 11(40.7%) patients, 16(59.2%) were laterally located including temporal lobe and Cerebellopontine angle. There was an associated dermal sinus tract in 6(22%) of the lesion in the midline and 4(14.80%) patients were having infected dermoids. Per-operatively the lesion was containing keratin and skin appendages in 22(81%) patients. Two patients with suspicion of glioma were diagnosed intra-operatively as dermoids. Total was removal possible in 21(77%) patients. Four patients (14.81%) were re-operated for recurrence of the lesion.

CONCLUSIONS: Microsurgical resection gives good result with minimal complications when patients are operated in time.

EP-317[Miscellaneous]

THE POSSIBILITIES OF APPLICATION OF TRANSCUTANEOUS NEUROSONOGRAPHY THROUGH POSTOPERATIVE DEFECT IN THE SKULL

Elena Pastukhova

Department of neurodiagnostics, Republican scientific centre of neurosurgery, Tashkent, Uzbekistan

INTRODUCTION - OBJECTIVE: The aim of our study was to determine the prospects of the method of transcutaneous neurosonography (TCNSG) in structural diagnostics of pathological changes in the brain at patients with a defect in the skull by comparison of results of ultrasonic examination opinions MRI and CT.

METHOD: TCNSG was held to 229 patients for 3 years. TCNSG was conducted in the first days after surgery to 147 patients and after 6 months, 1 year or more after surgery to 82 patients. CT also produced to all these 82 patients. Ultrasound examination was carried out on B-mode ultrasound devices Mindray dp6600 and SonoDiagnost 360 by convex and linear sensors.

RESULTS: The structural changes of the brain, the shape and dimensions of the ventricular system of the brain, the position of the median structures, the presence and size of areas of brain edema, abnormal formations (cyst, hematoma, air) took place in the interpreting of scanograms. The comparison of results TCNSG and CT or MRI scan showed a prevalence of reliability CT in 11 cases. Such pathological changes, such as swelling of the brain, the expansion of the ventricular system, porencephaly, large postoperative bleeding have been equally identified as CAT and TCNSG. It is worth noting that previously identified intracerebral hematomas at transition in extensive stage was not visible on CT scan, but was visualized on ULTRASOUND scanogrammy.

CONCLUSIONS: TCNSG with the purpose of exception of early and late postoperative complications and recurrences helps to choose optimal strategy of further diagnostics and treatment.

EP-318[Miscellaneous]

INTERNATIONAL NEUROSURGICAL COLLABORATION WITHIN CAMBODIA

Virak Tiv, Kee Park, Vycheth Iv, Sokret Touch

Department of neurosurgery, Preah Kosamak Hospital, Phnom Penh, Cambodia

INTRODUCTION - OBJECTIVE: To assess the impact of international neurosurgical collaboration in Cambodia.

METHOD: A careful and thorough review of all past and current international neurosurgical collaborative effort was performed. And the impact of the effort was assessed through interviews of leaders of neurosurgery in Cambodia.

RESULTS: International neurosurgical collaboration has had a significant impact on the neurosurgical care in Cambodia. Some of the more effective ways included training of Cambodian neurosurgeons at the established neurosurgical centers in developed countries as well as training provided by visiting surgeons at Cambodian hospitals.

CONCLUSIONS: International neurosurgical support and collaboration play a valuable role in development in neurosurgical services and expertise in developing countries and Cambodia is clearly a successful example of international collaboration. Continued collaboration is beneficial for the improvement of neurosurgical care in Cambodia.

EP-319[Miscellaneous]

BRAIN ABSCESS WITH CHAETOMIUM SPECIES OF 28 YR OLD FEMALE

Syed Imam

*Section of Neurosurgery, A K U Hospital Karachi Pakistan

INTRODUCTION - OBJECTIVE: Exposure to fungi on human health have become prominent in recent years. Chaetomium species is one of the largest within the Sordariales order. It may be found nearly everywhere. A lot of them inhabit compost, seeds, wood, wallpaper, paper, bird feathers, and animal feces and may be found in soil, ponds and plants with the optimal temperatures range of 25–28°C [15, 32]. Exposure can indeed cause adverse health effects, including infections

METHOD: 28 Yr old female admitted in AKUH on 1/04/12 with cerebral haemorrhagic abscess. Brain abscess with chaetomium species growth. This patient is a known case of vasculitis diagnosis at discharge by dept of Neurology was left basal ganglia haemorrhage and right caudate nucleus infarct.

RESULTS: CT intracranial angiography. 14/03/12 No evidence of aneurysm formation seen. There is no arteriovenous malformation MRI Brain Scan 4/04/12 Compared with previous examination dated 23/02/2012 previously seen large left basal ganglia haemorrhage is unchanged. New development of abnormal enhancing areas, abnormally enhancing ventricular walls and hydrocephalus as described above, are suggestive of infective process with ventriculitis

CONCLUSIONS: Operative Procedure 5/04/12 Neuro Navigation Drainage of Brain Abscess. Types of Specimen for C/S taken as follows: pus for Bacterial, Fungal, AFB, and Cytology. HISTOPATHOLOGY 5/4/12 Pus effusion smear preparation reveal many degenerated acute inflammatory cells, few macrophages and lymphocytes against a necrotic background mixed with necrotic debris. Biochemistry Serum K 3.3 and CR 0.4 was throughout low in pattern

EP-320[Miscellaneous]

ENHANCEMENT OF EFFICIENCY AND SAFETY OF ANESTHESIA AT PATIENTS WITH SPINAL INJURIES

Yorgin Qurbanov, Rakhmon Egamberdiev

Republican Research centre of neurosurgery, Tashkent, Uzbekistan.

INTRODUCTION - OBJECTIVE: The choice of the most effective and safe methods of anesthesia at spinal and vertebral injuries is an actual problem of neuro anesthesia. The purpose is to increase efficiency and safety of anesthesia at spinal and vertebral injuries.

METHOD: In our center operated 36 patients with spinal injuries within 2010 – 2013. Among them 23 were men and 13 women. At all patients premedication and induction was carried out by a standard method. According to method of maintenance of anaesthesia we divided patients into 3 groups. 1. «Ketamine+ GABA+ Fentanyl» group – used at 14 patients. 2. «Tiopental+ GABA+ Fentanyl» group – at 12 patients. 3. «Propofol+ Fentanyl» group – at 10 patients. To assess adequacy of anaesthesia used complex clinical **METHODS:** intraoperative monitoring of blood pressure, heart rate, central venous pressure, capnography, SaO2 and calculated percentage of fluctuations. Time of awakening of patients and extubation was also investigated.

RESULTS: In the first group observed following fluctuations: blood pressure 7-11 %, heart rate 13-18 %, central venous pressure 18-25 %, capnography 12-15 %. In the second group: blood pressure 9-15 %, heart rate 10-14 %, central venous pressure 11-24 %, capnography 8-14 %. In the third group - blood pressure 5-10 %, heart rate 6-8 %, central venous pressure 7-11 %, capnography 4-6 %. Relative stability of these indicators was observed at third group.

CONCLUSIONS: Developed method of maintenance of anesthesia at spinal and vertebral surgical operations allows to adequate and effective protection, stability of circulatory dynamics at all stages of operation.

EP-321[Miscellaneous]

OUTCOME OF TRANS-SPHENOIDAL SURGERY FOR SELLAR- SUPRASellar LESIONS

Mumtaz Ali, Zahid Khan, Seema Sharafat

Department of Neurosurgery, PGMI, Lady Reading Hospital, Peshawar, Pakistan

INTRODUCTION - OBJECTIVE: To evaluate outcome and results of Trans-sphenoidal surgery for Sellar- Suprasellar lesions

METHOD: This Observational study was conducted at the department of Neurosurgery, Post-graduate medical institute, Lady Reading Hospital Peshawar from July 2011 to December 2013 (2.5 years). A total of 63 consecutive patients who undergone Trans nasal transsphenoidal surgery with age more than fourteen years were included in the study irrespective of their gender. These patients were followed up to 2 months for clinical results and complications.

RESULTS: Out of 63 patients, there were 52.4% males and 47.6% females. Majority (34.9%) of patients were in the age range of 31-40 years, followed by 28.6% patients in age group of 21-30 years. Headache and visual deterioration was common presentation in 84.1% cases. Post operatively 77.8% patients had improvement in vision. Almost 66.7% patients had no residual tumor. Among post-operative complications diabetes insipidus was noted in 7.9% cases, Postoperative CSF leak was recorded in 4.8% cases and meningitis was observed in 1.6% case.

CONCLUSIONS: We conclude that transsphenoidal surgery is a safe and effective approach to sellar-suprasellar lesions having good results and acceptable post operative complications.

EP-322[Miscellaneous]

INNOVATED SUCTION, IRRIGATION AND DISSECTING MICRO-NEUROSURGICAL FORCEPS WITH SEPARATE DOUBLE CONTROL FOR BOTH FUNCTIONS SEPARATELY

Mohamed Ahmed Fahmy Mohamed Mostafa Zeid.

Department of NeuroSurgery, Faculty of Medicine, University of Alexandria, Alexandria, Egypt.

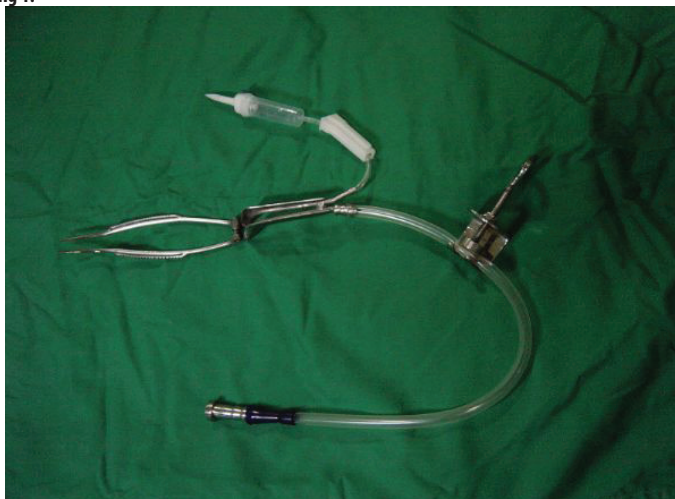INTRODUCTION - OBJECTIVE: The operating surgeons usually using the dissection forceps while the assistants continuously keeping the surgical field clear and dry by irrigation and suction through suction tube and another one for irrigation which might lead to "Crowded" operative field by four (4) instruments under magnification.

METHOD: Through a single dissecting Metal (Stainless Steel) forceps using one shaft of that forceps for controlled irrigation & while the other shaft passing through it a tube for controlled suction. The two metals tube ending on the back side of the forceps separately without mixing the lumen of each one together. The back end of one tube go for accurate controlled suction while the back end of the other tube go and fit exactly to the tube of the regular intravenous saline set. By the irrigation power which is controlled by the intravenous system & while the suction power is controlled accurately by the suction machinery control. Meanwhile the tip of the shaft of the forceps has one hole for controlled irrigation while the other tip of the shaft has got three holes for the suction.

RESULTS: It used for experimental surgery on animal & Recently A pro-type of that forceps have used in two of our patients, One of them a video clip was taken.

CONCLUSIONS: The use of the single instruments for dissection, irrigation and suction actually facilitate micro-surgical operation especially tumor capsule dissection and excision instead of three instrument working simultaneously in a limited field of the microscope.

fig 1.



The Suction & Irrigation Dissecting Forceps.

fig 2

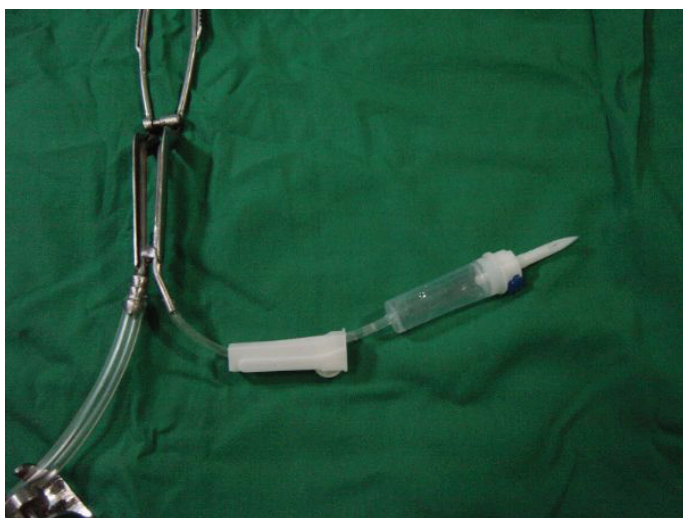

fig 3

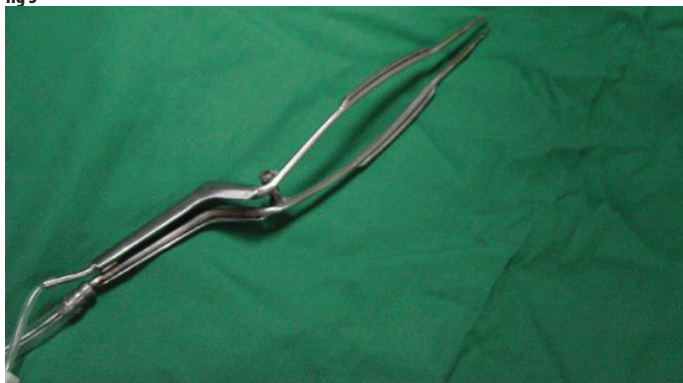

fig 4

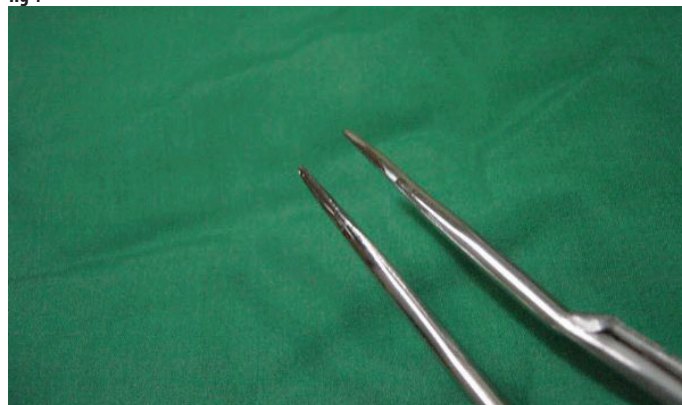

fig 5



EP-323[Miscellaneous]

ROLE OF SUCTION TECHNIQUE IN ENDOSCOPIC MANAGEMENT OF THIRD VENTRICULAR LESIONS

Muhammad Idris Khan, Bilal Khan Afridi, Mumtaz Ali Shah

department of neurosurgery, Lady Reading Hospital, Peshawar, Pakistan

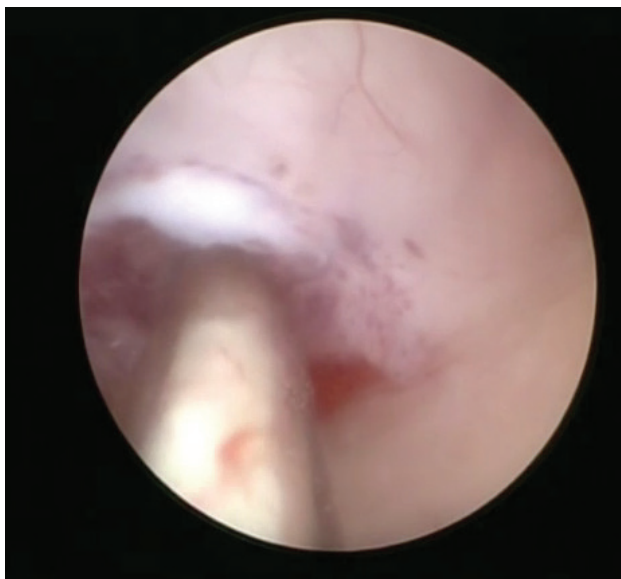INTRODUCTION - OBJECTIVE: To know about the effectiveness of suction technique in endoscopic surgery

METHOD: this study was conducted in our department between March 2012 and January 2014. All patients who had undergone endoscopic surgery for various indications in our Department in which suction technique was employed during this period were included while those who have not undergone this technique were excluded from the study. The patient's demographics like the age, gender, indications for surgery, use of the technique with a pediatric nasogastric tube size 8, extent of tumor/ cyst removal and complications if any were noted. The patients were kept in ICU post op. Data was entered and analyzed using SPSS version 20.

RESULTS: A total of 13 patients after following the exclusion criteria were included. There were 8 (61.5%) males and 5 (38.4) females. The age range was from 9 years to 57 years. The indications for surgery were colloid cyst in 7 (53.8%), third ventricular tumor in 2(15.3%) and pineal region tumor in 4. Complete removal and biopsy was possible in 6 patients (46.15%). Shunt was placed in 3 patients (23.7%). Bleeding was encountered in all six patients, which was completely controlled with irrigation in 4(30.7%) while in 2 (15.38), EVD was placed. No CSF leak was encountered. Mortality was in one patient that is 7.6%, who was initially in low GCS.

CONCLUSIONS: Suction technique is an effective way for removal of colloid cyst and endoscopic biopsy/ removal of the tumor.

picture



Biopsy plus removal of tumor by suction technique

complications

complications	number of patients
Bleeding	6 (46%)
Meningitis	none
Wound infection	none
CSF leak	none

demographics

No of male patients	No of female patients
8 (63%)	5 (37%)

total patients were 13

extent of tumor removal

number of pts with complete removal	number of patients undergoing debulking/biopsy
6 (46%)	7 (54%)

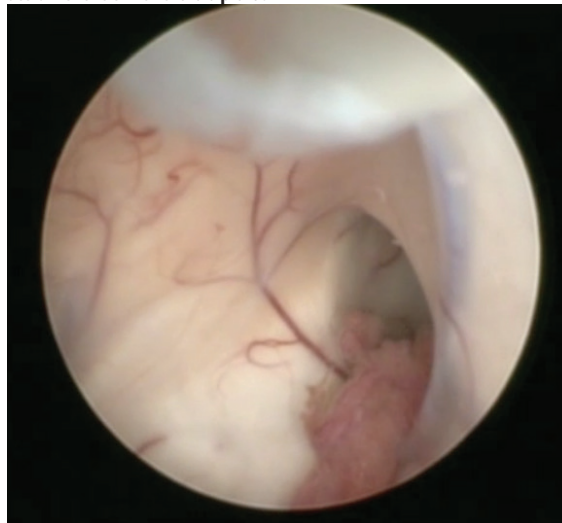
management of bleeding

number of patients treated with irrigation	number of patients treated with EVD
4 (66%)	2 (33%)

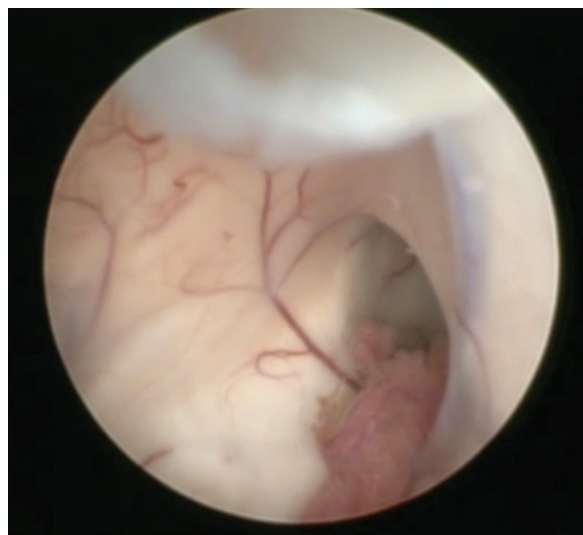
types of tumors

Type of lesion	Number of patients/%
Colloid cyst	7 (54%)
Pineal region tumor	4 (34.72%)
Third ventricular tumor	2 (15.36%)

lateral ventricle with choroid plexus



picture



endoscopic picture showing foramen of monro

EP-324[Miscellaneous]**THROMBOELASTOMETRY FOR THE EARLY DIAGNOSIS OF INFECTION IN NEUROSURGERY INTENSIVE CARE UNIT (ICU) AS COMPARED TO ESTABLISHED BIOMARKERS**

Deepak Agrawal, Renu Saini
All India Institute of Medical Sciences

INTRODUCTION - OBJECTIVE: We investigated whether thromboelastometry (TEG) variables can be used for the early detection of infection in Neurosurgery Intensive care unit (ICU) as compared to established biomarker.

METHOD: In the Observational cohort study over 1 year, blood samples were obtained from patients who admitted to the neurosurgery ICU on admission day 0 and subsequently samples were collected at day 3 and day 5. Later on patients were classified into two groups, who developed infection at day 3 (n=60) and who did not develop infection till day 5 (n = 40). Infection was defined as culture positivity on urine, blood or tracheal cultures. TEG variables were measured at all three time points for both the groups. In addition, procalcitonin, interleukin 6, and C-reactive protein levels will also be determined simultaneously at all three points for comparison. Baseline characteristics, demographic data, biochemical parameters were obtained at the time of inclusion.

RESULTS: Both groups were well matched in demographic profile, admission GCS and ventilator days. No difference in serum Procalcitonin, interleukin 6, and C-reactive protein concentrations was found on day 0, 3 and 5 between both groups (p>0.05). In comparison with noninfectious group, patients with infection showed significantly prolonged clot-formation time (R time) (p<0.001) on Day 0.

CONCLUSIONS: This study demonstrates that early involvement of the hemostatic system is a common event in infection. R time on TEG proved to be a more reliable biomarker of infection in adults as compared to procalcitonin, interleukin 6, and C-reactive protein.

EP-325[Miscellaneous]

ADULT LEFT LATERAL VENTRICULAR NEUROENTERIC CYST:
CASE REPORT AND REVIEW OF THE LITERATUREpenglai zhao¹, Zhengxiang Luo¹, Yoshikazu Okada²¹Department of Neurosurgery, Nanjing Brain Hospital Affiliated to Nanjing Medical University, Nanjing, China²Department of Neurosurgery, Tokyo Women's Medical University, Tokyo, Japan

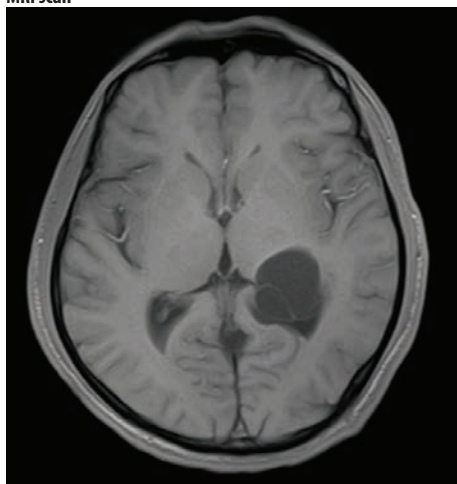
INTRODUCTION - OBJECTIVE: Intracranial supratentorial neuroenteric cysts are very rare, benign lesions in the central nervous system. We describe a histologically well-documented adult case of a left lateral ventricular neuroenteric cyst. In comprehensive literature reviews of neuroenteric cysts, no one published case is documented as occurring in the lateral ventricle, this is the first report of neuroenteric cyst arising in the lateral ventricle. To analyze our experience with an rare neuroenteric cyst in the left lateral ventricle and review the literatures.

METHOD: The left lateral ventricular neuroenteric cyst was achieved subtotal resection because cyst wall appeared strongly adherent to the surrounding normal structures. The literatures were reviewed and the clinical, radiological, operative, and pathological finding of the patient were discussed.

RESULTS: Intraoperatively, the lesion appeared as very thin arachnoid-like wall containing clear fluid. The final diagnosis was verified by histopathological analysis and immunohistochemistry. The patient had headache aggravation but no fever after surgery. CSF specimens examination excluded intracranial infection, but protein content in CSF was 0.88g/L. The headache was relieved successfully with regular lumbar punctures. The patient was discharged 2 weeks after surgery. He is healthy and showed no signs of tumor recurrence at 10-month follow-up.

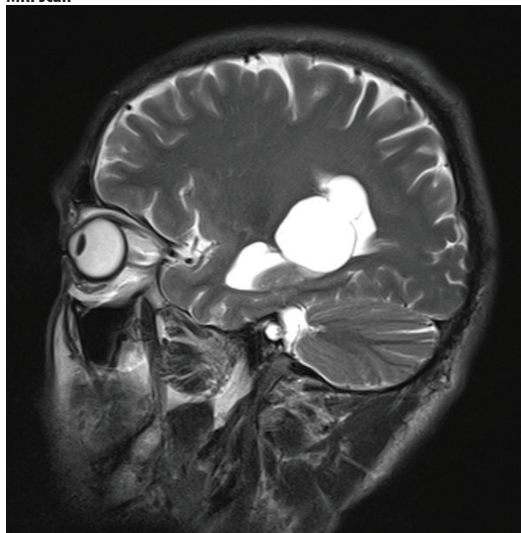
CONCLUSIONS: Intracranial supratentorial neuroenteric cysts are even rarer in patients. Due to the lack of specific imaging features, neuroenteric cysts may be misdiagnosed as arachnoid cysts, epidermoid cysts, ependymal cysts and so on preoperatively. Surgical excision is the only treatment in patients presenting with a symptomatic NC.

MRI scan



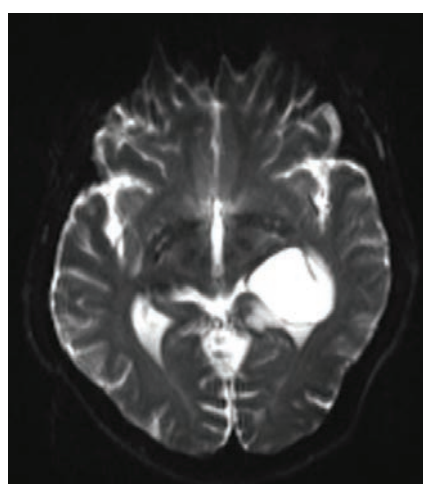
Preoperative axial T1-weighted MRI showing a hypointense cystic lesion in the left lateral ventricle.

MRI scan



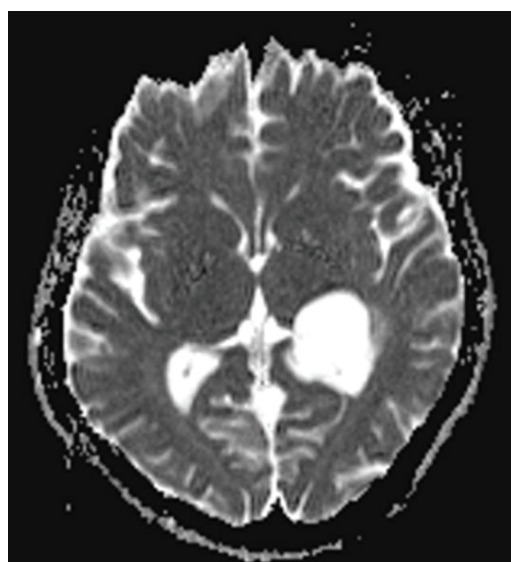
Preoperative sagittal T2-weighted MRI showing a hyperintense cystic lesion in the left lateral ventricle.

MRI scan



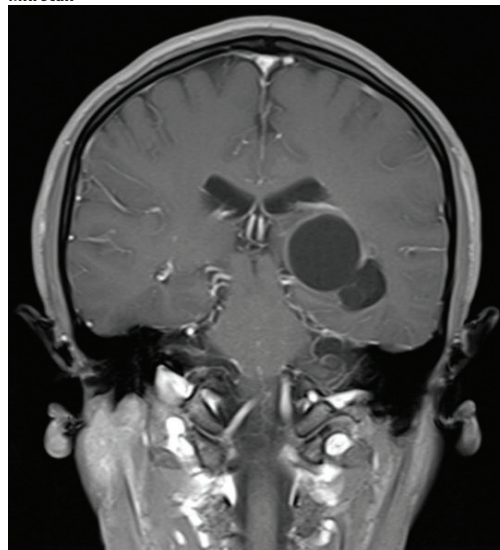
Preoperative axial fluid-attenuated inversion recovery (FLAIR) Sequence showing hyperintense cystic lesion in the left lateral ventricle.

MRI scan



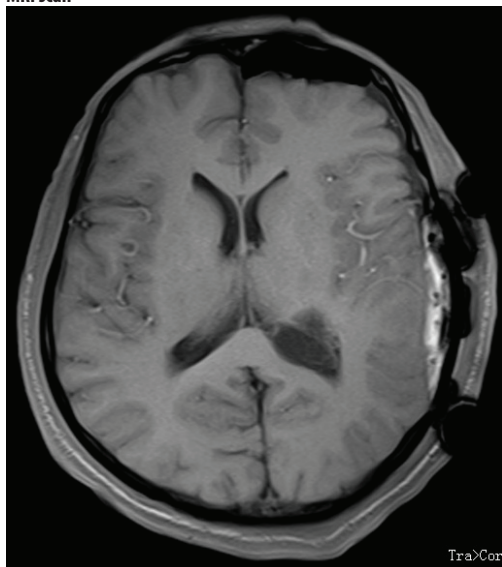
Preoperative axial diffusion-weighted image (DWI) showing hyperintense cystic lesion in the left lateral ventricle.

MRI scan

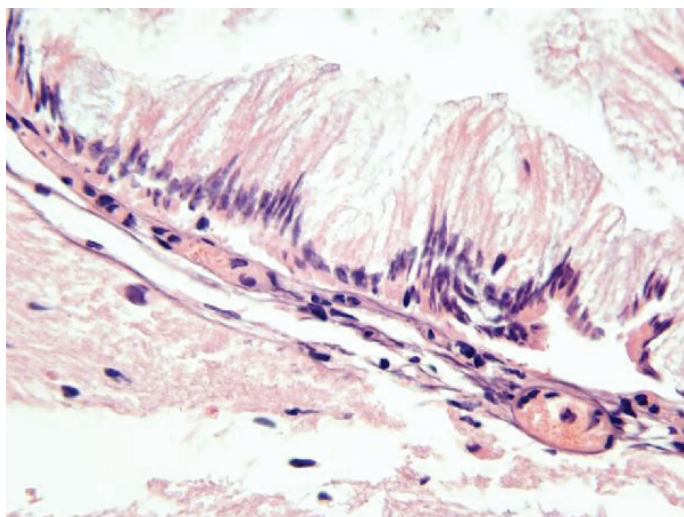


Preoperative coronal gadolinium-enhanced T1-weighted MRI scan showing mild capsule wall and septation enhancement after the administration of Gd-DTPA

MRI scan

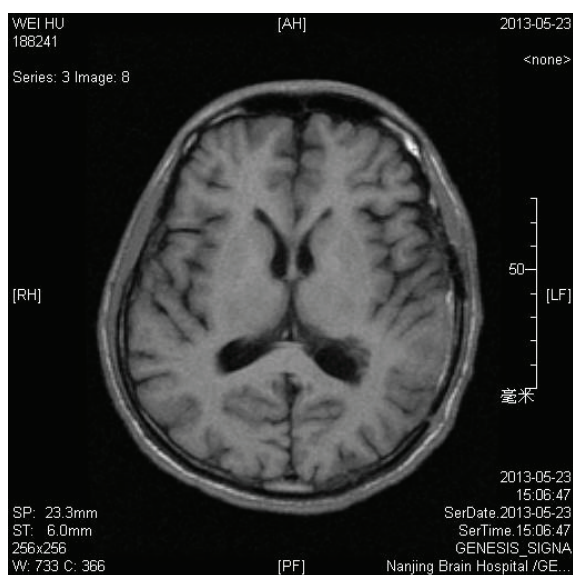


The 1st day of postoperative axial T1-weighted MRI showing subtotal resection of neuroenteric cyst. **pathological examination**



Postoperative pathological findings showing pseudostratified ciliated columnar epithelium with a basement membrane (hematoxylin and eosin; original magnification, *400)

MRI scan



Postoperative axial T1-weighted MRI of 2 month follow-up showing no recurrence.

EP-326[Miscellaneous]

TECHNIQUE OF STAGE-BY-STAGE RESTORATION OF MOTIVE SKILLS IN REHABILITATION OF SPINAL PATIENTS

Kuat Bulatovich Nurgalyev¹, Yerzhan Boranbaevich Adilbekov², Yermek Valerevich Kisaev³, Gulnara Sharipbekovna Mambetova⁴, Zhanerke Erkinovna Sagatbekova⁵, Asem Toleybekovna Imangozhaeva⁶

¹Kuat Nurgalyev - Head Neurorehabilitation Department, National Center of Neurosurgery, Astana, Kazakhstan

²Yerzhan Adilbekov - Deputy Medical Officer, National Center of Neurosurgery, Astana, Kazakhstan

³Yermek Valerevich Kisaev - Doctor Department, National Center of Neurosurgery, Astana, Kazakhstan

⁴Gulnara Sharipbekovna Mambetova - Doctor Department, National Center of Neurosurgery, Astana, Kazakhstan

⁵Zhanerke Erkinovna Sagatbekova - Doctor Department, National Center of Neurosurgery, Astana, Kazakhstan

⁶Asem Imangozhaeva Toleybekovna - Doctor Department, National Center of Neurosurgery, Astana, Kazakhstan

INTRODUCTION - OBJECTIVE: The main tasks of rehabilitation of patients with spinal injury are the prevention of venous disorders, contractures and stiffness, the recovery of superficial and deep sensitivity, the recovery of motor skills. Studying the results of the methodology application of the gradual recovery of motor skills in early neurorehabilitation of patients with spinal injuries.

METHOD: The patients with spinal trauma which hospitalized in the Neurorehabilitation Department of JSC "NCN" in the period from November 2012 to March 2014 were analyzed and studied. Results evaluation of the methodology application was carried out by using the sensory loss rating scale (U.S. National Institutes of Health Stroke Scale - Brott), the 5-point scale of muscle strength evaluation, the Ashworth scale of grading spasticity, as well as the visual criteria for appearance of any movements and motor skills.

RESULTS: Significant positive effect in the dynamics was observed in the Observational group in the acquisition of motor skills. 100% of spinal patients learned to move sideways, from back to stomach and backward; 87 % of patients could sit all by themselves, 60% of patients could stand and walk on all fours, 48 % of patients began to stand with support keeping the pelvis and knees.

CONCLUSIONS: Conducting rehabilitation of spinal patients through early using the gradual recovery of motor skills technique helps recover the movement and motor skills, acquire daily living skills, increase self-motivation, and improve the quality of patients life.

EP-327[Miscellaneous]

ENDOSCOPIC TREATMENT OF SYMPTOMATIC CAVUM SEPTUM PELLUCIDUM

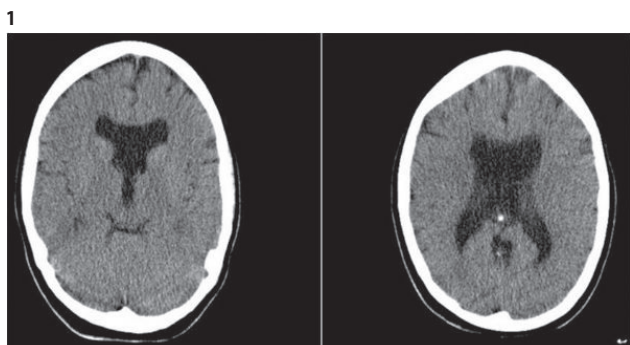
Seyedali Mousavinejad, Mohammad Samadian, Guive Sharifi, R za Jabbari, Omidvar Rezaie department of neurosurgery, loghman hospital, shahid beheshti university, tehran, iran

INTRODUCTION - OBJECTIVE: We present two patient with symptomatic cavum septum pellucidum (CSP) that underwent neuroendoscopic fenestration.

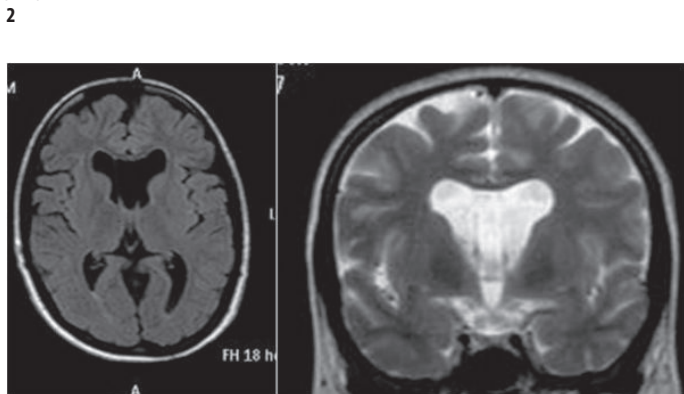
METHOD: case1: The was a 27-year-old woman complained from headache for 3 years. She did not have history of seizure, vertigo and visual disturbance. Her neurological exam was normal. The brain CTscan and MR imaging show A large cyst of the septum pellucidum. There was mild ventriculomegaly but no transependymal edema. There were no abnormalities of the size or signal characteristics of the basal ganglia, diencephalon, or limbic structures. case2: The patient was a 16 years old boy with headache and intermittent nausea and vomiting for six months. His neurological examination was normal. Radiologic studies showed a cavum septum pellucidum with mild hydrocephaly. After general anesthesia, a right coronal burr hole was placed (8 centimeter behind the nasion and 2 centimeter lateral to the midline). A small cruciate dural opening was obtained and a straight ventricular catheter was directed into the ventricle and then with endoscope we entered to right lateral ventricle. After identification of the lateral ventricle the cystoventriculostomy was performed.

RESULTS: immediately after surgery the patient was asymptomatic.

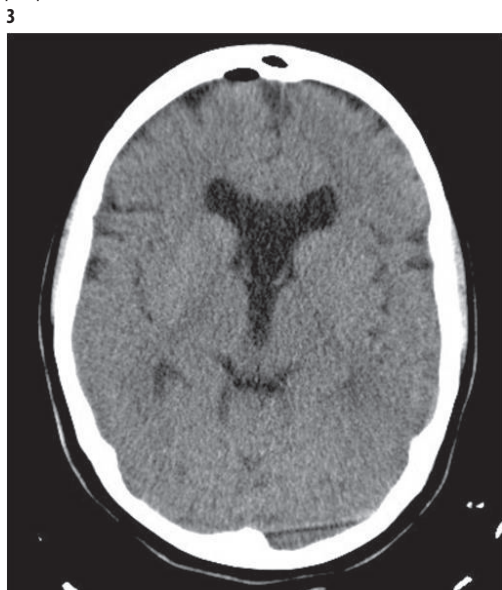
CONCLUSIONS: Endoscopic fenestration offers an attractive alternative to direct fenestration and shunting because it allows visual inspection of the interventricular foramina for evidence of fibrosis or intermittent obstruction by flattened cyst walls and obviates the long-term commitment to a shunt. In the majority of patients, symptomatic improvement occurs rapidly following treatment.



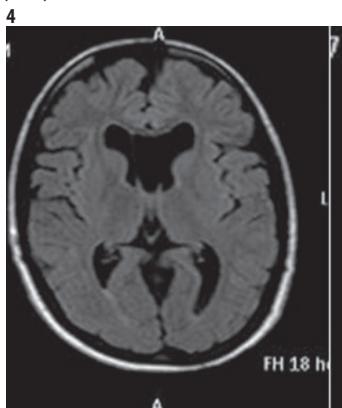
pre op ct scan of case 1



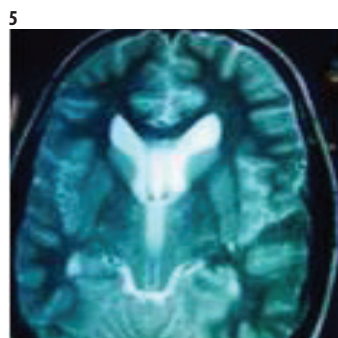
pre op mri of case 1



post op ct scan of case 1



pre op mri of case 2



pre op T2 MRI OF CASE 2

EP-328[Miscellaneous]

COMPONENT ANALYSIS OF CENTRAL NERVOUS SYSTEM MALIGNANT TUMORS DYNAMICS IN ECOZONE OF KAZAKHSTAN

Yerzhan Boranbaevich Adilbekov¹, Yermek Valerevich Kissayev²¹Yerzhan Adilbekov - Deputy Medical Officer, National Center of Neurosurgery, Astana, Kazakhstan.²Yermek Kissayev - National Center of Neurosurgery, Astana, Kazakhstan

INTRODUCTION - OBJECTIVE: Analysis of morbidity with MT CNS in the studied ecological zone in the dynamics showed a slight increase in crude indicator, with a total increase of $T = 0.420 / 0000$, the growth rate depended mainly on the changes associated with the risk of getting sick ($\Sigma = \Delta P = +0,360 / 0000$).

METHOD: Comparison of the proportion of the age composition of the population in ecological zone of Kazakhstan for 2003 and 2012 revealed a decrease in the age groups under 30 years (1.7%), 30-39 years (0.4%) and 60-69 years (0.6%), and in other ages marked increase, mostly indicated in 50-59.

RESULTS: On the basis of the component of the analysis of the dynamics of disease with MT CNS in ecological zone of 2003-2012 we can say that the number of patients in the study area as a worldwide, including in Kazakhstan is growing, but it is necessary to consider that the reason for the overall growth of the MT CNS hitherto not fully understood, but according to most researchers, it is associated with the evolution risk factors for this disease.

CONCLUSIONS: Thus, the number of patients with MT CNS in ecological zone Kazakhstan increases. The growth is mainly based on to the expense of the population growth, the joint effect of changes in population size and age structure, changes in the risk of getting sick, the joint effect of changes in the risk of getting sick, and the age structure of the population.

EP-329[Miscellaneous]

EFFECTS OF INTRALIPID AND CAFFEIC ACID PHENETHYL ESTER ON NEUROTOXICITY, OXIDATIVE STRESS, AND ACETYLCHOLINESTERASE ACTIVITY IN ACUTE CHLORPYRIPHOS INTOXICATION

Ümit Özkan¹, Arif Ösün¹, Kağan Başarslan², Serkan Şenol³, İbrahim Kaplan⁵, Harun Alp⁴¹Department of Neurosurgery, Dumlupınar University, Kutahya, Turkey²Department of Neurosurgery, Mustafa Kemal University, Hatay, Turkey³Department of Pathology, Medeniyet University, Istanbul, Turkey⁴Department of Pharmacology, Mustafa Kemal University, Hatay, Turkey⁵Department of Biochemistry, Dicle University, Diyarbakır, Turkey

INTRODUCTION - OBJECTIVE: Chlorpyrifos is the most widely used organophosphate (OP) insecticide in agriculture with potential toxicity. Current post-exposure treatments consist of anti-cholinergic drugs and oxime compounds. We studied the effects of intralipid and caffeic acid phenethyl ester (CAPE) on chlorpyrifos toxicity to compose an alternative or supportive treatment for OP poisoning.

METHOD: Forty-nine rats were randomly divided into seven groups. Chlorpyrifos was administered for toxicity. Intralipid (IL) and CAPE administered immediately after chlorpyrifos. Serum acetylcholinesterase (AChE) level, total oxidant status (TOS), total antioxidant response (TAR), and histologic examination of cerebellum and brain tissue with Hematoxylin-Eosin and immunohistochemical dyes were examined.

RESULTS: Serum enzyme levels showed that chlorpyrifos and CAPE inhibited AChE while IL alone had no effect, chlorpyrifos and CAPE intensifies the inhibition effect. Significant difference at AChE levels between the chlorpyrifos + IL and chlorpyrifos + CAPE verified that IL has a protective effect on AChE inhibition. TAR levels were significantly increased in all groups except chlorpyrifos group, TOS levels revealed that CAPE and IL decrease the amount of oxidative stress. Histologic examination revealed that neuronal degeneration was slightly decreased at chlorpyrifos + IL group, but CAPE had a significant effect on protection of neuronal degeneration.

CONCLUSIONS: The results of this study gave us three key points. 1) AChE activity is important for diagnosis of OP intoxication but it has no value for determining the neuro-degeneration. 2) CAPE inhibits AChE activity and may increase the muscarinic-nicotinic hyperactivation. 3) IL decreases the severity of neurodegeneration and symptoms of OP intoxication and it can be used as a supportive agent.

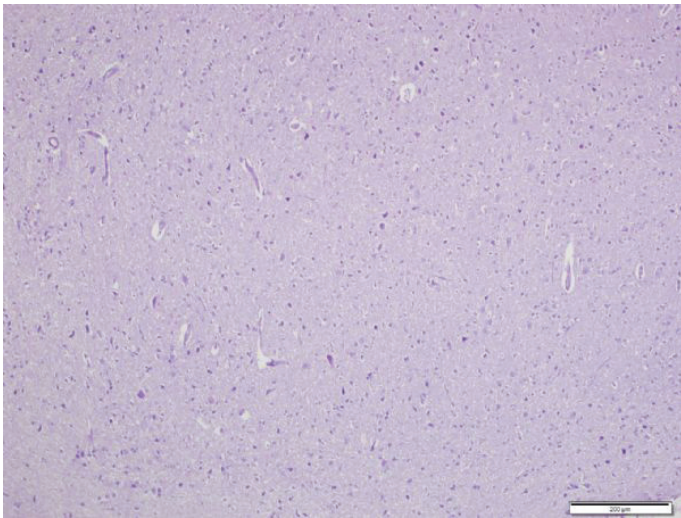
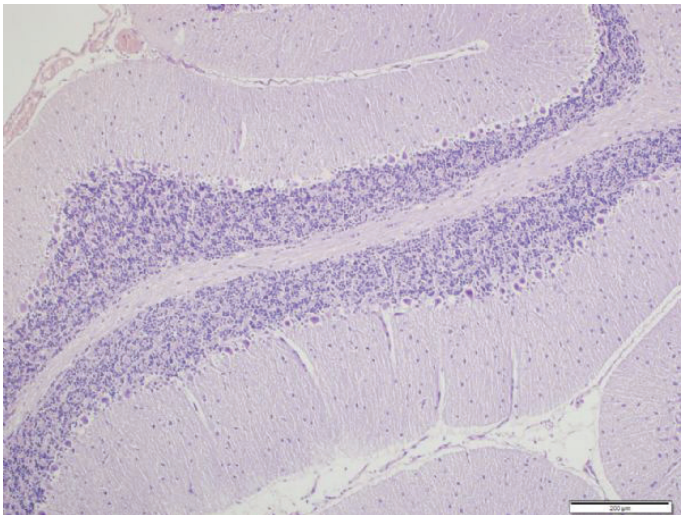
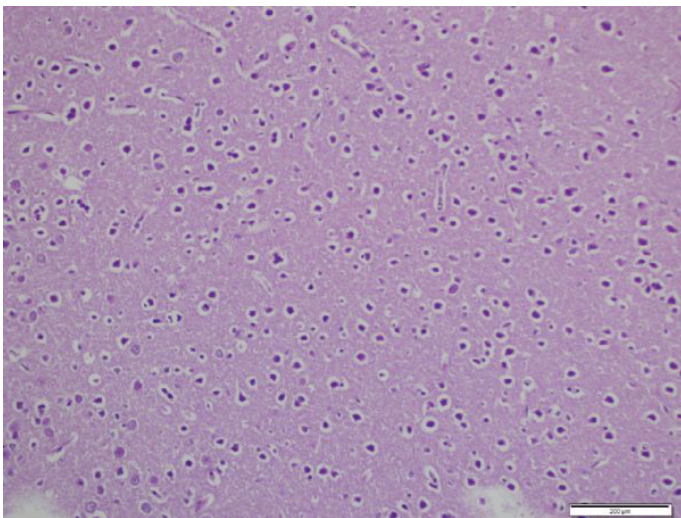
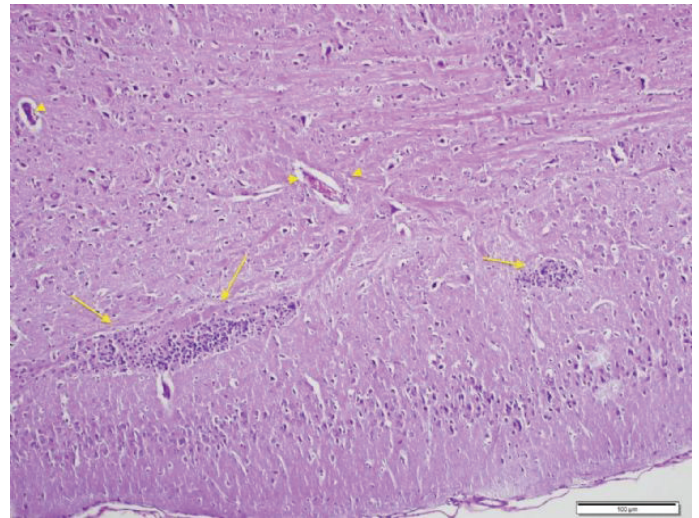
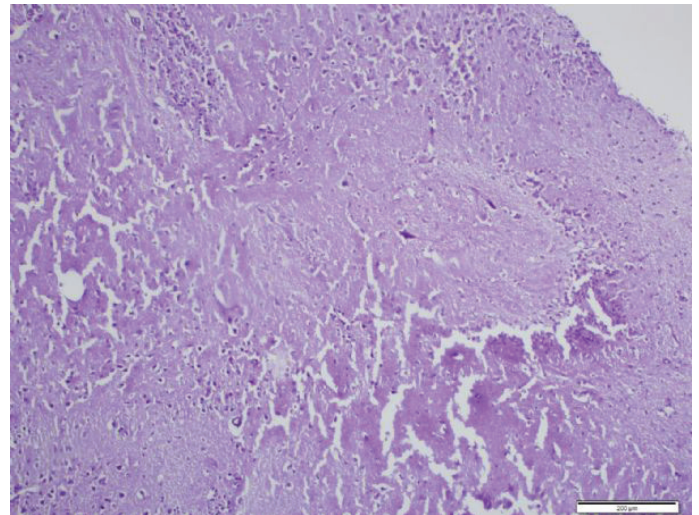
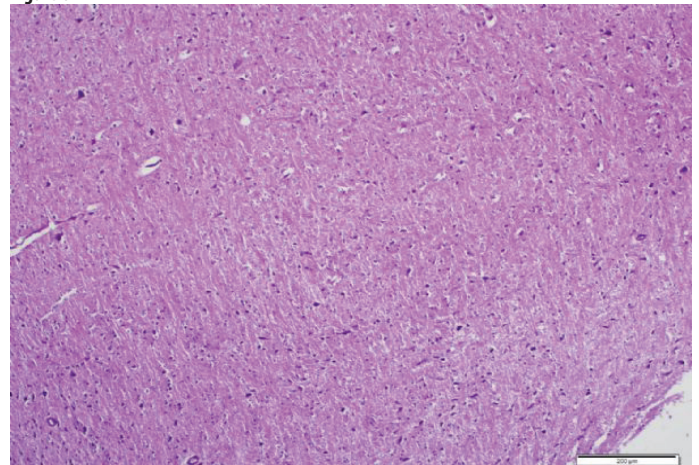
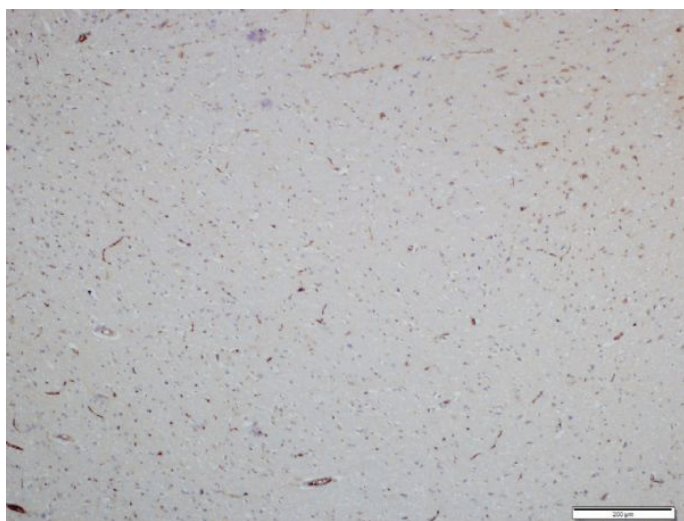
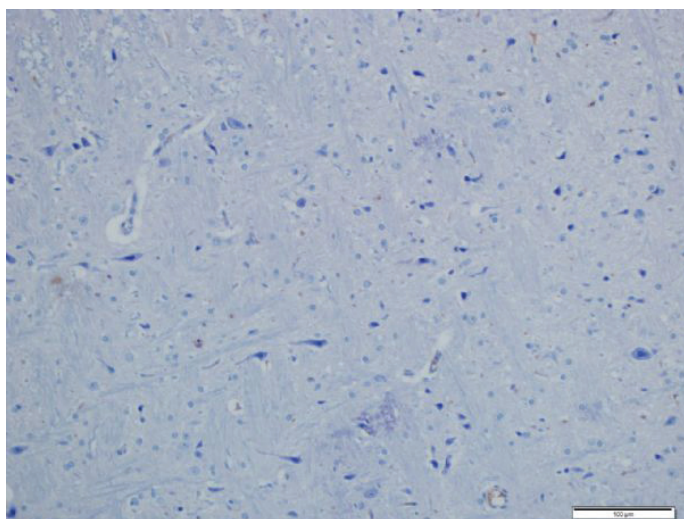
Figure 1*Normal histologic view of rat brain cortex (H&E x200).***Figure 2***Normal histologic view of rat cerebellum (H&E x200).***Figure 3***Vacuolar degeneration, dark picnotic nucleus and shrunken cytoplasm (H&E, x400).***Figure 4***Besides degenerative findings, inflammation (arrow) and congestion (arrow head) can be seen (H&E x200).***Figure 5***Cortical necrosis (H&E, x400) in CPF group***Figure 6***Histologic examination of CPF+CAPE group. Degeneration findings are significantly fewer than CPF group (H&E, x100).*

Figure 7



Immunohistochemical examination with caspase-3, bcl-2 and bax antibodies. CPF group had significant apoptotic cells (IHC x100)

Figure 8



Immunohistochemical examination with caspase-3, bcl-2 and bax antibodies. CPF+CAPE group had fewer amount of apoptotic cells than CPF group (IHC x200)

EP-330[Miscellaneous]

PROTECTIVE EFFECTS OF INTRALIPID AND CAFFEIC ACID PHENYL ESTHER (CAPE) ON NEUROTOXICITY INDUCED BY ETHANOL IN RATS

Seyyit Kagan Basarslan¹, Arif Ösün², Harun Alp³, Ümit Özkan², Serkan Şenol⁴, İbrahim Kaplan⁵

¹Mustafa Kemal University, Medical Faculty, Department of Neurosurgery, Hatay/TURKEY

²Dumlupınar University, Medical Faculty, Department of Neurosurgery, Kutahya/TURKEY

³Mustafa Kemal University, Medical Faculty, Department of Pharmacology, Hatay/TURKEY

⁴Medeniyet University, Goztepe Eğitim ve Araştırma Hastanesi, Department of Pathology, İstanbul/TURKEY

⁵Dicle University, Medical Faculty, Department of Biochemistry, Diyarbakır/TURKEY

INTRODUCTION - OBJECTIVE: Ethanol also causes oxidative degradation of the mitochondrial genome in brain. This effect could contribute to the development of brain injury in some alcoholic patients. Ethanol can cause alcohol intoxication when consumed. We investigated the protective effect of caffeic acid phenyl ester and intralipid on oxidative stress and neurotoxicity induced by ethanol intake.

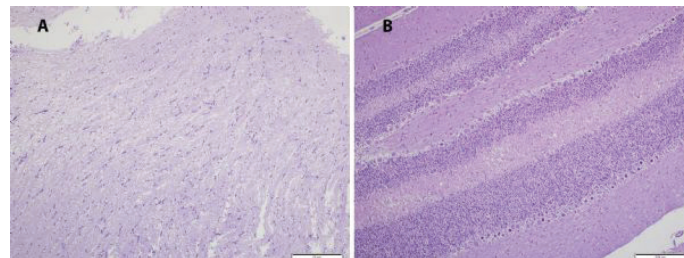
METHOD: The forty-nine rats were randomly divided into seven groups. Ethanol was administered for acute toxicity. Intralipid (IL) and CAPE administered immediately after ethanol intake. Total oxidant status (TOS), total antioxidant response (TAR), and histologic examination of cerebellum and brain tissue with Hematoxylin-Eosin and immuno-histochemical dyes were examined.

RESULTS: In ethanol group, TAR levels were significantly lower than other groups and this finding indicates that toxic effect of ethanol reduces antioxidant levels. In ethanol group, TOS levels were significantly higher than other groups. These results showed that ethanol induced oxidative stress. For

all that CAPE and IL treatment increase TAR levels, and decrease TOS levels against ethanol toxicity. There was correlation between TAR and TOS levels. Also, histopathologic results confirmed to these biochemical results.

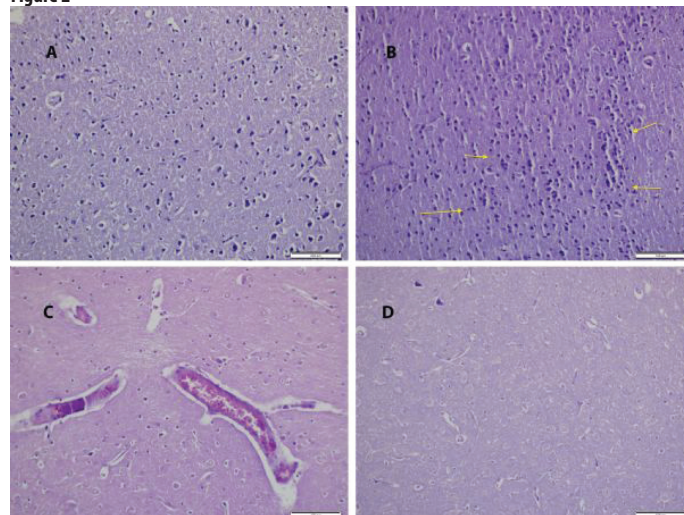
CONCLUSIONS: CAPE and IL treatment could be effective course of therapy to enhance therapeutic efficacy and may provide a promising approach for the treatment of neurotoxicity and oxidative stress induced by ethanol in clinic.

Figure 1



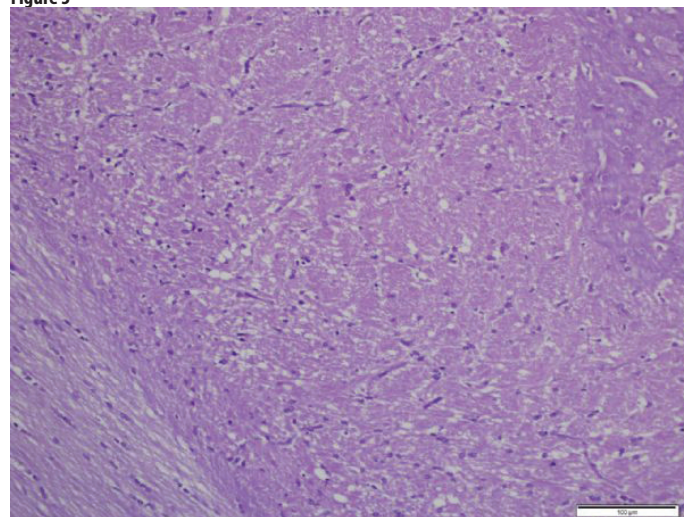
Normal brain (A) and cerebellum (B) tissue of rat (HE X100)

Figure 2



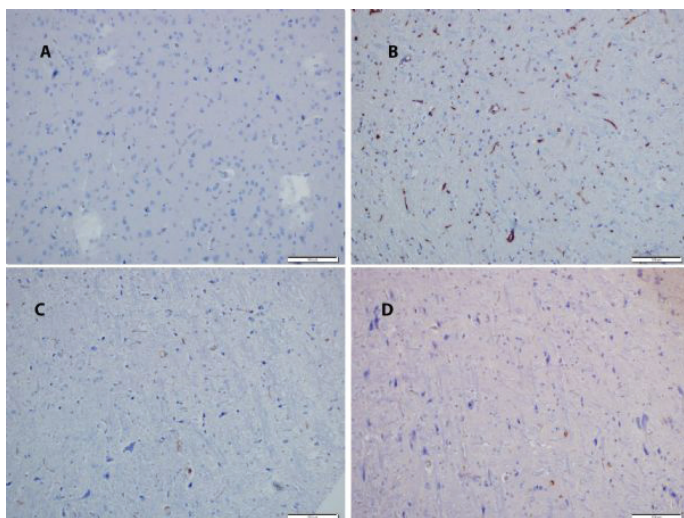
Histologic examination of Ethanol group; (A): there was significant neuronal degeneration with the findings of dark picnotic nucleus, vacuolation and shrunken cytoplasm, (B): significant inflammation, (C): significant oedema, congestion and degeneration and (D): necrosis (HE X200).

Figure 3



E+IL+CAPE group; all of the degeneration findings were significantly fewer than ethanol group (HE X200)

Figure 4



Immunohistochemical evaluation; (A) Normal brain tissue of the rat, (B) Ethanol group revealed that there is significant apoptosis, (C) E+CAPE+IL group showed mild apoptosis (IHC X200)

EP-331[Miscellaneous]

ENTRAPMENT OF TEMPORAL HORN: FIRST CASE OF BILATERAL OCCURRENCE AND REVIEW OF LITERATURE

Reza Ghadirpour¹, Corrado Iaccarino², Antonio Romano¹, Vania Ramponi², Francesca Fossi², Edoardo Viaroli², Massimo Maggi³, Rosario Pascarella³, Franco Servadei²

¹Emergency Neurosurgery, Neuromotor Department, IRCCS "ASMN" of Reggio Emilia, Reggio Emilia, Italy

²Neurosurgery Unit, Emergency Department, University Hospital of Parma, Parma, Italy

³Neuroradiology Unit, IRCCS "ASMN" of Reggio Emilia, Reggio Emilia, Italy

INTRODUCTION - OBJECTIVE: The entrapped temporal horn is a rare entity, caused by an obstruction of the trigone of the lateral ventricle which seals off the temporal horn from the rest of the ventricular system. Clinical presentation is often with headache, seizures, hemiparesis, and visual field deficit.

METHOD: A 50-year-old male patient with partial seizures was admitted for the first time, due to a one-month progressive history of gait disturbance, subjective vertigo, headache. He reported a nine-year history of episodic migraine, and partial seizures. He underwent clinical and neuroradiological follow-up under antiepileptic therapy. A first CT scan two years later disclosed no brain pathologies. A first MRI, after further three years, showed a bilateral enlarged septed temporal horns. The stationary size of the temporal horns was observed until emergency admission, where an emergency CT scan disclosed a further expansion of the temporal horns. MRI examination with paramagnetic contrast confirmed the asymmetric dilatation (right > left) of the temporal horns with intraventricular septa.

RESULTS: The patient underwent insertion of ventricle catheters through bilateral burr holes, with the aid of the neuronavigation, to ensure the tube position for the entire length of the temporal horns. The postoperative neuroimaging controls showed the decrease of ventricles size.

CONCLUSIONS: To the best of our knowledge this is the first case of bilateral entrapped temporal horn. The enlargement of the entrapped horn due to the sealing off of the CSF circulation suggest always an invasive management.

EP-332[Miscellaneous]

BRAINSTEM ABSCESS. WHAT TO DO? EXPERIENCE WITH 12 CASES

Daniel Carvalho Kirchhoff, Lorenza Pereira, Luiz Paulo Alves, Fabio Furukawa Okuda, Abel Mitsuo Takey, Rodrigo Gusmao Coimbra, Dierk Fritz Bodo Kirchhoff
Assistencia Neurologica São Bernardo

INTRODUCTION - OBJECTIVE: Generally all pathologies of Brainstem are of difficult resolution and causes catastrophic neurological deterioration for the patient. Retrospective study of twelve cases of this rare pathology treated during twenty years period in our Service, considering the clinical presentation, etiology, co-morbidities, choices of clinical surgical treatment (craniotomy or stereotactic aspiration) and complications in each case reported.

METHOD: The brainstem abscess represents 0.5 to 6% of all brain abscess. Its etiology is spreading in a hematogenic way, being the most frequent causes the pulmonary arterial-venous fistula and heart diseases as arrhythmia. In the case of immunodeficiency, we must take into account all the particularities of these patients. In 12 cases, we have 6, where the development of symptoms were very fast instead of medication. We operate these cases with aspiration of pus, and washed the cavity with saline and gentamicin.

RESULTS: We present 12 cases of brainstem abscess, most of them in the Pons, being 3 treated by open

surgery 3 per stereotactic aspiration and 5 treated only with specific drugs. 1 patient with a bulbar abscess without clinical conditions of treatment have a fast bad evolution.

CONCLUSIONS: The two surgical approaches used, did not show difference in survival or sequelae of cases. The clinical drug treatment must be discussed with the Infectologist in each singular case. Literature was consulted and shows different and similar dealing with, that will be discussed.

EP-333[Miscellaneous]

LITERATURE REVIEW ON SKIN COMPLICATIONS AFTER DECOMPRESSIVE CRANIECTOMY - HOW TO PREVENT IT?

Daniel Carvalho Kirchhoff, Lorenza Pereira, Luiz Paulo Alves, Fabio Furukawa Okuda, Abel Mitsuo Takey, Rodrigo Gusmao Coimbra, Dierk Fritz Bodo Kirchhoff
Assistencia Neurologica São Bernardo

INTRODUCTION - OBJECTIVE: Decompressive craniectomy is a well-known neurosurgical procedure, initially applied in trauma context and posteriorly used in malignant hemispheric infarction. It can be lifesaving although the own nature of brain trauma or occlusion of middle cerebral artery is devastating. The patient usually survives, but damage secondary to the primary incident seldom improves.

METHOD: Literature review was made in order to understand scalp anatomy and irrigation, verify details about decompressive craniectomy that could influence wound complications and gather scientific articles on this subject.

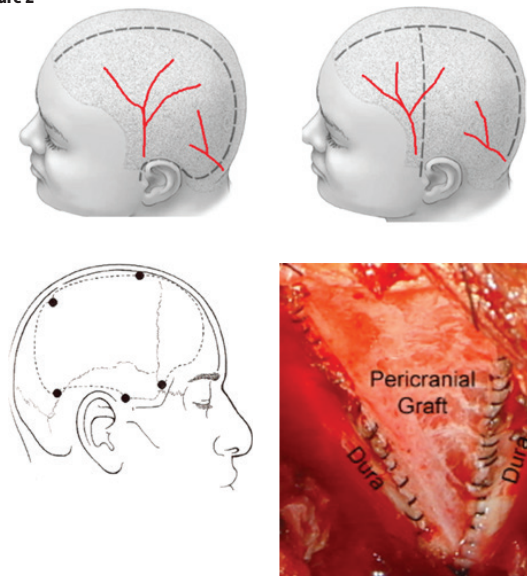
RESULTS: Decompressive craniectomy is performed through scalp "inverted question mark" or T-shaped incision. The advantage of the later over the first one is less dependence of temporalis superficial artery which can be accidentally damaged during surgery. Scalp exposition should allow access to area wide enough to perform a craniectomy of at least 12 cm thus avoiding brain herniation. Durotomy is then performed followed by duroplasty. The dura matter can be left open, but this leads to poor cerebral fluid circulation. Duroplasty provide brain protection, avoid adherence of the galea to the underlying brain tissue and may prevent the development of postoperative hygromas and CSF leakage.

CONCLUSIONS: Wound complications can lead to infection caused by S. Epidermidis, meningitis and consequently higher morbidity and mortality rates. In order to try to prevent wound complications, it is important to understand scalp anatomy and irrigation. Reducing wound tension through small incisions in the galea to provide elasticity to the skin and/or suturing the galea and using running suture with Monocryl 4-0, can improve scalp cicatrization.

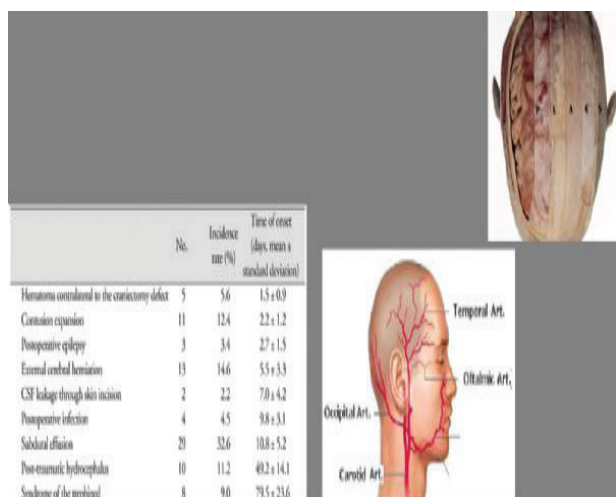
Picture 1

Study	Study Type	Inclusion Criteria	Treatment Arms	Follow-Up	Outcome
DECRA trial (Cooper et al., ¹⁷ 2011)	Multicenter RCT	Severe diffuse TBI and intracranial hypertension refractory to first-tier therapies	Two arms: 1. DC + standard care (n = 73) vs 2. Standard care alone (n = 82)	6 mo	DC group had less time in ICU and less time with high ICP. On Extended Glasgow Outcome Scale DC patients performed worse than patients who received standard care (OR 1.84) and had a greater risk of unfavorable outcome (OR 2.21). Death rate in DC group (19%) and in standard-care group (18%) was comparable.
RESCUEicp (Hutchinson et al., ¹²¹ 2006)	Multicenter RCT	Severe TBI; ICP refractory to optimal, protocol-driven conservative therapy	Two arms: 1. DC vs 2. Medical management	—	Ongoing

Picture 2



Picture 3



Picture 4

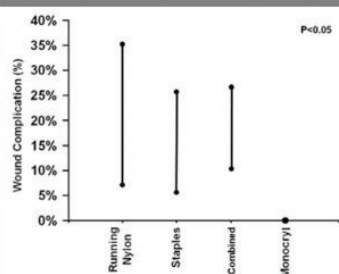
Table 1
(a, upper) Comparison of clinical characteristics of the patients in this study and (b, lower) mechanisms of injury for the patients in this study

	Monocryl	Running nylon	Staples	p-level
No. of patients	219	40	58	
Age (years, mean ± SE)	48 ± 3.6	38 ± 2.4	39 ± 2.1	p < 0.05
Gender (M/F)	236/0	31/9	46/12	P = NS
Admitt GCS score (mean ± SE)	8.2 ± 0.8	7.1 ± 0.7	7.8 ± 0.6	P = NS
Complex wounds (%)	45/20 (21%)	7/160 (1.0%)	3/58 (5%)	P = NS
Open skull fractures	5/20 (17%)	5/40 (1.3%)	3/58 (5%)	P = NS
Mechanism		No. of patients (%)		
Fall		46/127 (36)		
Pedestrian versus automobile		19/127 (15)		
GSW		12/127 (9)		
Round down		10/127 (8)		
Bike versus automobile		7/127 (6)		
Assault		7/127 (6)		
Other ¹		19/127 (15)		
Intracerebral hemorrhage		7/127 (6)		

F = female, GCS = Glasgow coma scale, GSW = gun shot wounds, M = male, SE = standard error.

¹ Includes being hit by a train, motorcycle accidents, and skateboard accidents.

² Of 132 patients, five had wound closure using the vertical mattress suturing technique and were not analyzed, leaving 127 treated as shown.



EP-334[Miscellaneous]

NEW ELECTROSURGICAL DEVICE TO STOP THE BLEEDING

Galimzhan Mamirbekovich Yelikbayev, Adilet Azretovich Yernazarov
Department of Special Clinical Disciplines, Akhmet Yassawi University, Turkistan, Kazakhstan

INTRODUCTION - OBJECTIVE: Aim of this study was to develop a versatile device for hemostasis, provide optimal conditions dissection with simultaneous coagulation of biological tissues without significant changes in the depth of tissue necrosis in compliance with the sterility of the working electrode and the tissue site of exposure.

METHOD: Device thermocoagulation electrode comprises an electrode clamp for fixing a removable cutting heads which are located inside the electrical and thermal isolation of the tubular handle. Two electrode terminals connected to the supply wire, which is connected to a regulated power supply. On the work surface around the tubular device handles installed reflector with ultraviolet light-emitting diodes, which destroy the infection at the time of dissection and coagulation.

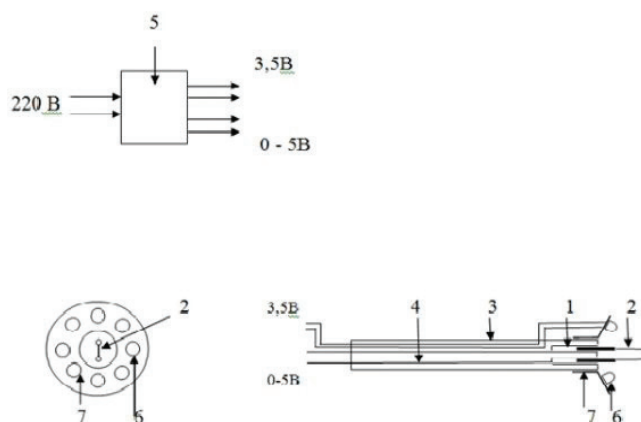
RESULTS: Prerogatives of the proposed electrosurgical thermocoagulators to see that the electrocoagulators is removable cutting nozzle, it is possible to disinfect the cutting elements and the selection of cutting nozzles for different types of surgical procedures, as well on the working surface mounted ultraviolet light-emitting diodes, which destroys infection during dissection and coagulation.

CONCLUSIONS: Mobile device and not complex in structure, and the existing reflector with ultraviolet light-emitting diodes and removable cutting heads can effectively use the device in an outpatient and field conditions.

General view of the electric thermocoagulator



Scheme of thermocoagulator



EP-336[Miscellaneous]

BRADYARRHYTHMIAS DURING ENDOSCOPIC THIRD VENTRICULECTOMY, COMPARISON OF PROPHYLACTIC VERSUS THERAPEUTIC USE OF ANTICHOLINERGICS

Muhammad Irfan Butt¹, Mumtaz Ali²

¹Department Of Anaesthesia, PGMI, Peshawar, Pakistan

²Department of Neurosciences, PGMI, Peshawar, Pakistan.

INTRODUCTION - OBJECTIVE: To compare prophylactic versus therapeutic use of glycopyrrolate in treating bradyarrhythmias occurring during endoscopic third ventriculectomy (ETV).

METHOD: Sixty patients of ages ranging from 1-60 years planned for ETV were included in this comparative randomized control trial after approval from institutional ethical committee and written informed consent. These patients were randomized based on convenience sampling into study Group A (who were given glycopyrrolate before induction of GA) and controlled Group B (who were not given glycopyrrolate prophylactically). The data collected from the anaesthetic charts were analyzed at 7 periods: before induction (period 1), surgical incision (period 2), endoscopic exploration (period 3), perforation of the third ventricle floor (period 4), balloon dilatation (period 5), the end of skin closure (period 6), and after extubation (period 7). HR, SBP, DBP, SPO2 and ECG values were listed according to these periods.

RESULTS: All patients in study Group A did not show any significant change in HR, SBP, DBP, SPO2 and ECG values through all seven periods during monitoring. In controlled Group B, 93% (N=28) patients went into bradyarrhythmias during perforation of the third ventricle floor (period 4) and balloon dilatation (period 5) and were treated with glycopyrrolate successfully.

CONCLUSIONS: Preinduction single dose of glycopyrrolate is very effective in avoiding bradycardia during ETV compared with treating severe bradyarrhythmias intraoperatively.

EP-337[Miscellaneous]

THE EFFECTIVENESS OF USING THE SENSORY ROOM IN PSYCHO-CORRECTIONAL WORK WITH NEUROSURGICAL PATIENTS

Kuat Bulatovich Nurgalyev, Klara Kenzhina, Botagoz Jamantayeva
Department of Neurorehabilitation, National Centre for Neurosurgery, Astana, Kazakhstan

INTRODUCTION - OBJECTIVE: The main aim of the present research is to reveal the effectiveness of using the sensory room in psycho-correctional work with neurosurgical patients.

METHOD: 16 patients (23 - 68 years) with impaired emotional functioning, depressive states and increased anxiety were under Observation within 21 days after neurosurgery in neurorehabilitation department of the ISC "National Centre for Relaxation method was used along with the application of colour and light therapy (sensory room equipment), sound therapy (natural sounds of nature and the birds singing), music (classical music). Initial and repeated psychological evaluation techniques, such as the Hamilton Depression rating scale (HDRS), the Taylor Manifest Anxiety Scale, the Montgomery-Asberg depression rating scale (MADRS) were applied.

RESULTS: 13 patients (81%) with Parkinson's disease, with consequences of stroke, spinal and cord injury had positive changes in the emotional sphere, reducing anxiety and had less depressive episodes, while 3 patients (19%) with severe consequences of traumatic brain injury had less positive improvements due to the presence of psycho-organic syndrome, where additional medical treatment was required.

CONCLUSIONS: According to the results of the treatment, it can be concluded that the rational, thoughtful and methodically well organised usage of the sensory room within the complex rehabilitation measures can have a substantial health restorative and corrective effect on patients with disorders affecting emotional sphere. Sensory room – is an important tool for people whose abilities to perceive the world have been limited by diseases.

EP-338[Miscellaneous]

CRANIAL BONE PRESERVATION FOLLOWING CRANIECTOMY: CURRENT VARIATIONS IN PRACTICE AMONG NEUROSURGEONS

Liew Boon Seng¹, Mohammad Jaweed², Gee Teak Sheng¹, Azmin Kass Rosman¹, Johari Siregar Adnan³

¹Department of Neurosurgery, Hospital Sungai Buloh, Selangor, Malaysia

²School of Medicine Taylors University, Lakeside Campus Subang, Kuala Lumpur, Malaysia

³Department of Neurosurgery, Hospital Sultanah Aminah, Johor Bahru, Johor, Malaysia

INTRODUCTION - OBJECTIVE: Craniectomy is usually performed when decompression of intracranial space is needed. The common indications for such surgical procedure include ischemic stroke, post-traumatic brain injury, cerebral edema or any causes of elevated intracranial pressure refractory to medical treatment. Common surgical options include hemicraniectomy and bifrontal craniectomy. The removed bone flaps are usually kept with intact sterility and to be replaced later when brain swelling subsided. The two common methods of cranial bone preservations include abdominal subcutaneous implantation of bone flap and cryopreservation via the usage of bone bank. The choice of storage depends on the availability of the facilities, risks of bone resorption and infection.

METHOD: A questionnaire was conducted among neurosurgeons attended the recent 15th World Federation of Neurosurgery (WFNS) Congress in 2013. Four options of preferred methods of cranial bone preservations were given. For those who practising bone preservation, they were asked on the average duration of bone storage before cranioplasty.

RESULTS: A total of 38 respondents who completed the questionnaire were included in the study. 17 respondents preferred abdominal subcutaneous implantation, while 14 respondents preferred cryopreservation method. 3 respondents practised both methods of bone preservation without any preferences. Only 4 respondents do not practising any bone preservation. (Table 1) The mean duration of bone storage was 2.5 months in subcutaneous group and 5.2 months in cryopreservation group. The difference between two groups was statistically significant ($p=0.05$)

CONCLUSIONS: Neurosurgeons who preferred cryopreservation method of cranial bone storage have tendency to perform cranioplasty at a later date than those who preferred subcutaneous implantation method.

Figure 1: Choice of Bone Preservation after decompressive Craniectomy

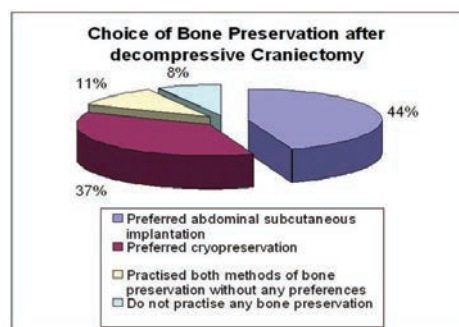


Table 1: Methods of cranial bone flap preservation

Method of bone preservation	Frequency	Percentage
Abdominal subcutaneous implantation	17	44.7
Cryopreservation	14	36.8
Both methods	3	7.9
Not practising any bone preservation	4	10.5
TOTAL	38	100.0

EP-339[Miscellaneous]

PITUITARY HYPERPLASIA DUE TO HYPOTHYROIDISM IN HIMALAYAN ENDEMIC REGION - A CASE REPORT

Shabal Sapkota

Koshi Zonal Hospital, Biratnagar, Nepal

INTRODUCTION - OBJECTIVE: Pituitary hyperplasia due to hypothyroidism is a rare entity. Iodine deficiency endemic goiter is the most common type of hypothyroidism worldwide. Himalayan endemic goiter leading to pituitary hyperplasia has never been reported in literature.

METHOD: We report a case of a 12 years old girl who presented with headache, and fatigue for the last 6 months. She was referred from city hospital for neurosurgical evaluation, with her brain CT showing enlarged and enhanced pituitary gland. She had a palpable diffuse neck swelling with coarse skin and appeared short for age. Her neurological examinations were normal. Her serum TSH and Prolactin were higher than normal whereas FT4 and FT3 were low. Other endocrinological assays and thyroid antibody tests were normal. FNAC was suggestive of iodine deficiency colloid goiter.

RESULTS: Regression of Pituitary mass on CT scans with improvement of symptoms and normalization of hormonal assay was demonstrated after instituting Levo thyroxine and fortified iodine salt intake for 4 months

CONCLUSIONS: Unnecessary surgery could be eliminated by recognizing of the association between reversible pituitary hyperplasia and hypothyroidism. Iodine deficiency hypothyroidism must also be considered for causing pituitary hyperplasia in endemic regions.

CT Head - Pituitary Hyperplasia due to Hypothyroidism

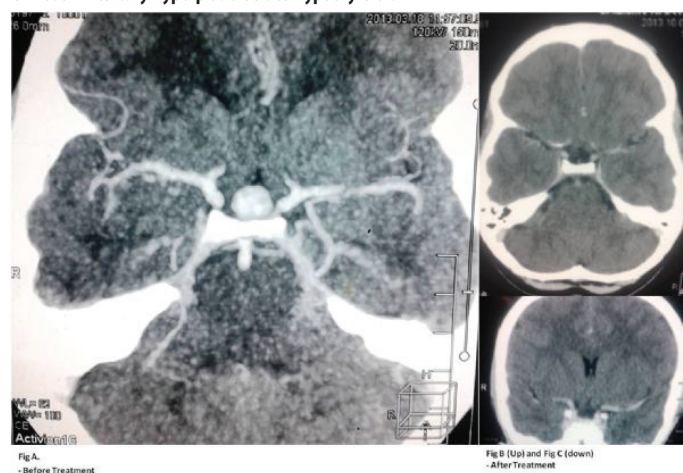
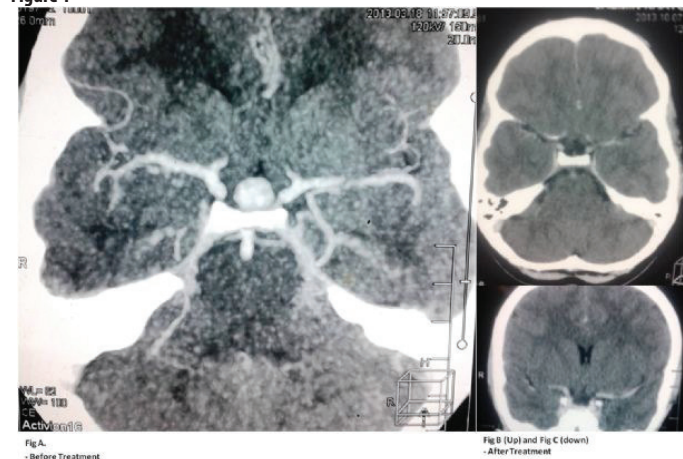


Figure 1



12 years old girl with enlarged and enhanced pituitary gland on CT Scan (a) which disappeared after Levo thyroxine therapy and fortified iodine.

EP-341[Miscellaneous]

RHOMBOID FLAP FOR CLOSURE OF HUGE MENINGOCELES DEFECT

Dalia Mofreh Elsakka

plastic and reconstructive surgery, Menoufi a university, Egypt

INTRODUCTION - OBJECTIVE: Neural tube defects are a congenital anomaly, which occur in approximately one in 1,000 live births per year in the USA and result from failure of fusion of the vertebral arches during primary neurulation, 18–28 days after fertilization. Early closure of MC is advocated as it reduces infection rates even though it is not associated with improved neurological outcome. The most common complication of primary closure is wound separation or breakdown.

METHOD: Designing of rhomboid flap or closure of meningocele defect in 7 patients

RESULTS: The follow-up period ranged from 1 to 18 months, with an average of 10.6 months. All of the defects were repaired successfully in one stage with a tension-free closure of good-quality tissue. There was no flap loss, necrosis, wound dehiscence and leakage of cerebrospinal fluid

CONCLUSIONS: rhomboid flap for closure of a large meningocele defect is a tension free and reliable flap with minor complications

Patient demographics

pa-tients	Level of lesion	Weight (grammes)	Age at operation (days)	Mode of delivery	Sex	Associated Chiari abnormality	Hydrocephalus
1	S2–S3	1920	1	Caesarean section	M	No	No
2	S1–S5	1950	2	Homebirth	M	yes	No
3	L5–S1	2750	2	Caesarean section	F	No	yes*
4	S2–S3	3200	1	Caesarean section	M	yes	No
5	S2–S3	3000	2	Homebirth	M	No	yes*
6	S1–S5	2870	3	Caesarean section	F	No	No
7	L5–S1	2450	3	Caesarean section	F	yes	No

*Ventricular–peritoneal shunt inserted 4 days post-birth and 3 days post-myelomeningocele repair

EP-343[Miscellaneous]

3D-PRINTING-GUIDED NEUROSURGERY: A CASE REPORT OF TUBERCULAR MENINGIOMA BASED ON AN INDIVIDUALIZED REALISTIC MODEL

Xuejun Li¹, Siyi Wanggou¹, Shenghui Liao⁴, Wenzheng Li², Xiaoping Yi², Xianrui Yuan¹, Junhui Huang³¹Department of Neurosurgery, Xiangya Hospital, Central South University, Changsha, China²Department of Radiology, Xiangya Hospital, Central South University, Changsha, China³Department of Oncology, Xiangya Hospital, Central South University, Changsha, China⁴Department of computer science, Institute of information science and engineering, Central South University, Changsha, China

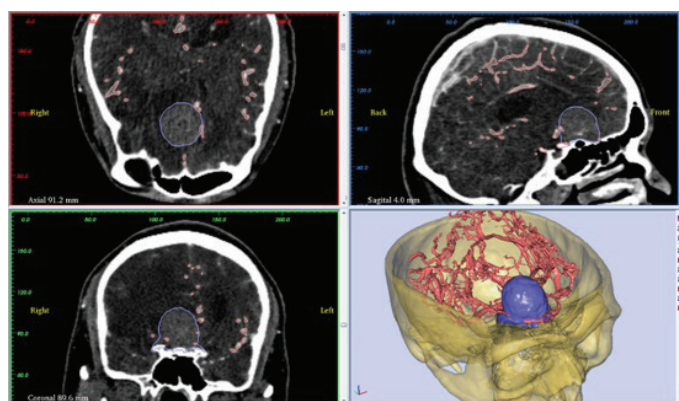
INTRODUCTION - OBJECTIVE: In the medical field, 3D printing has been used for several years. However, there are few examples of neurosurgery operations guided by 3D-printed models. To explore and test the utility of 3D-printed models in neurosurgery and determine whether this technology improves the surgical safety.

METHOD: A 47-year-old male patient with tubercular meningioma was selected by our group. Image data was loaded to the E-Feature digital medical 3D design system and realistic model was created by 3D printer. Microsurgery was conducted under the guidance of the model. This study was carried out from January to February in 2014. Microsurgery with the right sub-frontal approach under the guidance of a 3D-printed model was conducted. Precision of the 3D model, preservation of important intracranial structure, extent of tumor resection and patient outcome were considered as main outcome measurements of the study.

RESULTS: The full-scale model of skull base, vessels and tumor was accurately reconstructed. Important structures around tumor were well preserved intra-operatively. The patient received a successful and total surgical resection and achieved a perfect recovery with a Karnofsky performance score of 90 upon hospital discharge.

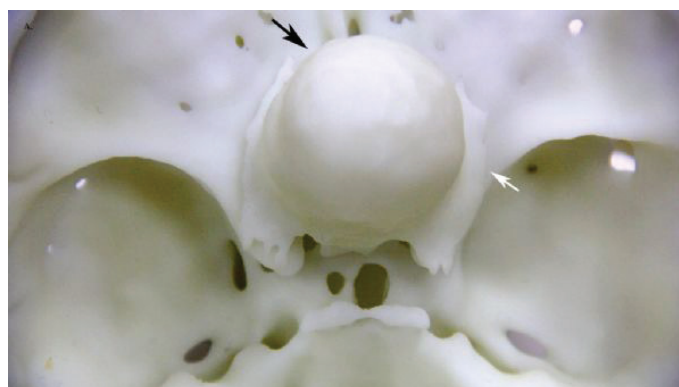
CONCLUSIONS: We suggest that 3D printing is important to neurosurgeons for surgical planning, teaching and practicing and could be a revolutionary technology that improves the safety of neurosurgical treatments.

Figure 1. The 3D model construction process.



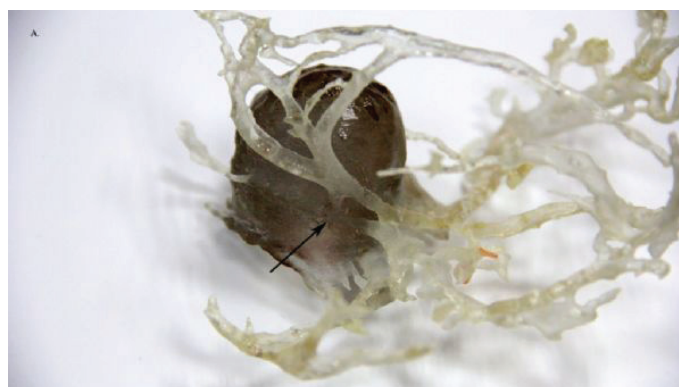The E-Feature digital medical 3D design system was used to finish the image construction.

Figure 2. 3D model showing the relationship between the tumor and the anterior skull base.



The black arrow shows the margin of the tumor mass, and the white arrow shows the dural tail of the tumor creeping into the tuberculum sellae and sellae platform.

Figure 3. 3D model showing the relationship between the tumor and major cerebral vessels.



The black arrow indicates where the A2 segment of the left ACA was invaded and enclaved by the tumor.

EP-344[Miscellaneous]

ABOUT POTENTIAL YEARS OF LIFE LOST AT MORTALITY FROM MALIGNANT TUMORS OF CENTRAL NERVOUS SYSTEM

Marat Kulmirzayev

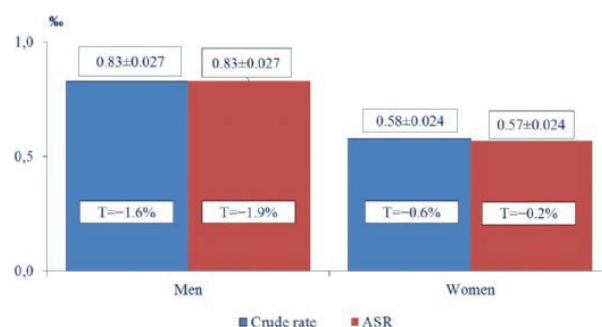
JSC «National Center for Neurosurgery», Astana, Kazakhstan

INTRODUCTION - OBJECTIVE: Cancer takes one of the leading places among the causes of death, which affects the average life expectancy of the population and causes considerable economic damage. Below a results of brief assessment of the potential years of life lost (PYLL) of Kazakhstan population due to mortality from malignant tumors of the central nervous system (MT CNS) are presented.

METHOD: The data from the Agency of Statistics of RK concerning the patients died from MT CNS (form C51) for 2004-2011 were used. PYLL was calculated according to the method proposed by M.Dempsey, standardized indicators are applied. The average value, mean error, 95% confidence interval (95%CI), average annual growth/decline rates (T,%) were determined.

RESULTS: During the 2004-2011 3,830 death from MT CNS were registered. Average annual average age of death's over the republic was 48.3 ± 0.39 years (95% CI=47.5-49.1), $T=+0.4\%$. Average number of person-years of life lost equalled $10,439 \pm 246.5$ (95% CI=9,956-10,922), $T=+0.1\%$. In the dynamics crude PYLL rates decreased from $0.73 \pm 0.007\%$ to $0.67 \pm 0.007\%$, standardized rates decreased from $0.72 \pm 0.007\%$ to $0.66 \pm 0.006\%$. Average annual standardized PYLL rate was $0.70 \pm 0.021\%$ (95% CI=0.66-0.74), $T=-1.2\%$. Expected average age of death increased from 46.0 to 47.4 years, in average amounting to 46.1 ± 0.39 years (95% CI=45.3-46.8), $T=+0.4\%$.

CONCLUSIONS: There was a slight positive trend in mortality from MT CNS among the population, increase of death age, reduction of crude and standardized PYLL rates. The data Obtained will allow timely to carry out activities for the prevention and early detection of cancer and reduce the damage from able-bodied population loss in Kazakhstan.



EP-345[Miscellaneous]

MODIFIED VENTRICLE OCCIPITAL HORN PUNCTURE IN VENTRICLE-PERITONEAL SHUNT FOR TREATMENT OF HYDROCEPHALUS: ANALYSIS OF 20 CASES

Qian Chunfa, Hu Xinhua, Huang Qingjiu, Zhang Rui, Chen Yongyan, Zhang Wenbin, Ma Jun, Liu Hongyi
Department of neurosurgery, Nanjing Medical University, Affiliated Nanjing Brain Hospital, Nanjing, China

INTRODUCTION - OBJECTIVE: To explore the value of modified ventricle occipital horn puncture in ventricle-peritoneal shunt (V-P) for the treatment of hydrocephalus patients.

METHOD: Twenty hydrocephalus patients underwent CT or MR scan. Located scanning baseline in external auditory canal plane and chose largest ventricle as puncture plane and designed hypothetical puncture path on axial slice radiographic film. Located occipital horn puncture point (A) and puncture path extend to contra-lateral frontal (Point B). Connected A and B (AB line) and made AC line parallel to scanning baseline on the skin surface. Intra operation turned head to another side and made AB line horizontal position, puncture needle parallel to AC line and horizontally puncture. Analyzed follow-up results including clinical symptoms, ventricular size, position of catheter and complications.

RESULTS: Success rate of the only one puncture reached 90% (18 cases), another 2 cases succeeded in second time puncture after a little adjustment; Follow-up CT scan disclosed smaller ventricular in all cases, right position of catheter; clinical symptoms relieved or vanished.

CONCLUSIONS: Modified ventricle occipital horn puncture in ventricle-peritoneal shunt is convenient, time saved, accurate and without obvious complication.

EP-346[Miscellaneous]

MORTALITY FROM MALIGNANT TUMORS OF CENTRAL NERVOUS SYSTEM: POTENTIAL YEARS OF LIFE LOST ACCORDING TO SEX

Nurbek Igissinov¹, Serik Akshulakov², Marat Kulmirzayev²¹NGO «Central Asian Cancer Institute», Astana, Kazakhstan²JSC «National center for neurosurgery», Astana, Kazakhstan

Figure 1. The dynamics of average number of person-years of life lost from malignant tumors of central nervous system in Kazakhstan for 2004-2011

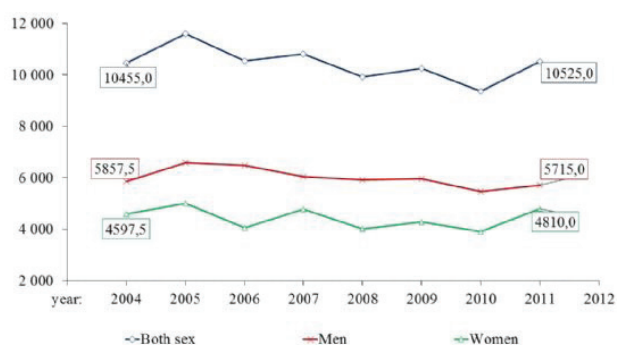


Figure 2. Crude and age-standardized PYLL rates from malignant tumors of central nervous system in Kazakhstan for 2004-2011 (both sex)

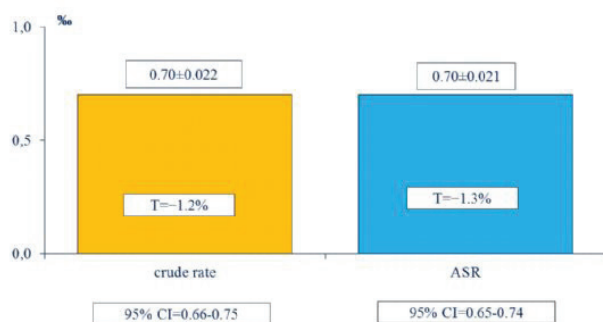


Figure 3. Crude and age-standardized PYLL rates from malignant tumors of central nervous system in men and women in Kazakhstan for 2004-2011

INTRODUCTION - OBJECTIVE: Cancer is one of the leading cause of death and significantly affects the average life expectancy. Below results of brief assessment of the potential years of life lost (PYLL) of Kazakhstan population due to mortality from malignant tumors of the central nervous system (MT CNS) according to gender are presented.

METHOD: The data about patients died from MT CNS for 2004-2011 were Obtained from the RK Agency of Statistics (form C51). PYLL was calculated using the method proposed by M.Dempsey, standardized indicators are applied. The average value, mean error, 95% confidence interval (95%CI), average annual growth/decline rates (T,%) were determined.

RESULTS: During the study period 3,830 death from MT CNS were registered, of which 55% men, 45% women. Average number of person-years of life lost (NPYLL) in men equalled $6,006 \pm 124.2$ (95% CI=5,727-6,285), $T=-0.4\%$, women – $4,433 \pm 159.9$ (95% CI=4,119-4,746), $T=+0.6\%$. In dynamics standardized PYLL rates in men decreased from $0.86 \pm 0.011\%$ to $0.75 \pm 0.010\%$, in average amounting to $0.83 \pm 0.027\%$ (95% CI=0.78-0.89), $T=-1.9\%$. In women average annual standardized PYLL rate was $0.57 \pm 0.024\%$ (95% CI=0.52-0.62), $T=-0.2\%$. In dynamics this indicator decreased from $0.60 \pm 0.009\%$ to $0.59 \pm 0.009\%$. Expected average age of death among men increased from 46.2 to 48.1 ($T=+0.6\%$), women from 46.4 to 46.8 ($T=+0.1\%$).

CONCLUSIONS: Reduction of NPYLL in men and increase in women were revealed. Among men there was a more positive trend in mortality from MT CNS. The data Obtained can be used to assess the impact of health promotion screening programs and reduce risk factors in order to increase the life expectancy of the total population.

EP-347 ALMATY NATION INSTITUTE OF IMPROVEMENT OF DOCTORS THE DEPARTMENT OF NEUROSURGERY

A. R. Halimov, A.S. Zhailaubayeva

Story of the department of neurosurgery

Story of development of neurosurgery started in former Soviet Union since 20-20 years of twenties century, when there was reorganization of neurosurgery into independent medical specialization. In Kazakhstan for the first time, neurosurgical work was organized like doctor's course of neurosurgery of Almaty Nation Medical Institute in hospital surgery in 1959 (head of a department is professor V. V. Zikeev). In 1964 department of neurosurgery was organized, that combined into structure of again setting up institute of improvement of doctors and it was a foundation of preparing neurosurgical specialists, medical and methodical consultative center of Republic of Kazakhstan.

Evgeniya Andreeva Azarova managed this department from moment of organization till 1978 year. She is highly-qualified neurosurgeon and a talented teacher, who made a big work in coming into being neurosurgery in Almaty and in our country at all. In 1973 in Alma-Ata on E. A. Azarova's initiative conference of neurosurgeries Central Asia and Kazakhstan was held under the leadership of the Ministry of Health of the Kazakh Soviet Union of Republic.

Anel Abdulovna Beremzhanova directed a department since 1978 till 1989 who paid a lot of attention for preparing of residents – neurosurgeon, since department had All-Union meaning of those years. Residents came from regions of Soviet Union. After that she was relieved the head at that department by doctor Vadim Evgenievich Elginson, who worked for department from the moment of its establishment. At that time base of department was the second city clinical hospital with sections of neurotraumatology and targeted neurosurgery. In 1996 S. K. Akshulakov was head of department after he graduated from a doctorate at research institute of neurosurgery named after N. N. Burdenko, who managed it before 2008. In different years there were a lot of honorary doctors and scientist of Kazakhstan such as R. B. Smolisky, A. H. Statenina, V. P. Bondarenko, M. K. Kozhekov, V. I. Anokhin, Zh. M. Ermekov, K. Sh. Shuraeva.

Since 2008 year Duisenbekov Yermek Kavtaevich has been directing it. He is a head of the department of neurooncology and head of the Center Neurosurgery of the seventh city clinic hospital. It has become traditional to hold scientific conferences on neurotraumatology, neurooncology, cerebrovascular diseases and neurorehabilitation by the department with leading specialist from Russia, Germany, Austria, Israel. On the eve of the anniversary of the Institute, the department of neurosurgery has been living as before its weekdays solving immediate problems, making plans for the future and always honoring the traditions of the school and the Kazakh Soviet Neurosurgery. These days considerable experience was accumulated and there is great potential for the implementation of scientific and practical plans to improve the health of our citizens.

EP-348(AWNA) FEMALE NEUROSURGEONS IN KAZAKHSTAN

Aigerim Zhumadildina
National Centre for Neurosurgery, Astana, Kazakhstan

INTRODUCTION - OBJECTIVE: Nowadays there are 269 neurosurgeons in RK. Only 13 (4.8%) of the total number of neurosurgeons are FN, and 3 are trained in residency. Their experience in neurosurgery varies from 3 years to 27 years, there is no academic degrees among FN. 4 of 13 (31%) FN are pediatric neurosurgeons. The cities of republican status have high neurosurgical service density, Astana (54 physicians) and Almaty (55 doctors) and, accordingly, the largest number of FN work in these cities: Almaty (4 doctors, 2 resident) and Astana (4 doctors, 1 resident). FN work in other regions: in Karaganda region 2 physicians, in AkTobe region 1 physician, 1 physician in East Kazakhstan region, 1 physician West Kazakhstan region. FN possess all kinds of neurosurgical operations that are performed on the territory of Kazakhstan. There is no FN involved in vascular neurosurgery.

CONCLUSIONS: • Nowadays there are precious few FN only 13 (4.8%) physicians, including 4 pediatric neurosurgeons. • The largest number of FN are working in Astana and Almaty. • FN possess all kinds of neurosurgical operations that are performed on territory of the RK, except for vascular surgery.

EP-349(Pediatric Neurosurgery) CRANIOCERVICAL INSTRUMENTATION DURING CHILDHOOD

Andreas Röhrig

Departement of Pediatric Neurosurgery, kAsklepios Pediatric Hospital, Sankt Augustin, Germany

INTRODUCTION - OBJECTIVE: We would like to report about our experience in craniocervical instrumentation during childhood.

METHOD: Patients and methods. • 14 children between 3 and 17 of age (mean 10,14), treated from 2007 till 2014. • CT-scan with sagittal and coronar reconstruction pre- and postoperative. • Excluded were acute traumata and posttraumatic lesions, long segment instrumentations, tumors and inflammatory diseases.

RESULTS: 7 of 14 patients had syndromal diseases (4 Klippel-Feil, 1 Ehler-Danlos syndrom, 1 Down syndrom, 1 neurofibromatosis). 1 child suffered from craniocervical meningocele with C1 hypoplasia and consecutive instability. Myelopathia was confirmed in 4 of the 14 children. All of them had a syndromal disease. A Gardner-decompression was performed in 5 of the 14 cases, of which all of them had a Chiari I and one with myelopathia before reposition. Diameter of the spinal canal before surgery: mean 17.3 mm,

after mean 28.9 mm. Clivovertebral angle before surgery: mean 115 (range 79 - 148), after: mean 133 (range 104 - 148)

CONCLUSION: Craniocervical instability in childhood leads to a high risk of ventral protrusion and consecutive compression of the myelon or lower part of the brainstem (12 of 14). 50% of the children suffered a syndromal disease. The diameter of spinal canal of the syndromal patients was significantly narrower than in non-syndromal patients (mean 10.7 mm compared to 21.6 mm). The risk of myelopathia was surely higher in syndromal patients. The outcome of the reposition in our patient - collective was not related to pre-operative extension or age of the patient.

EP-363[Miscellaneous] CONDITIONING IN CEREBROVASCULAR ACCIDENTS: A SURGEON'S PERSPECTIVE

Mohsen Nouri¹, Yoko Kato²

¹Department of Neurosurgery, Razi Hospital, Zahedan University of Medical Sciences, Saravan, Iran

²Department of Neurosurgery, Fujita Health University, Toyoake, Aichi, Japan

INTRODUCTION - OBJECTIVE: Major advances have been made in recent years in acute management of cerebrovascular accidents (CVAs). Medical revascularization with intra-venous or intra-arterial Alteplase is considered a major breakthrough in treatment of CVA in recent decades. However, the narrow time window to prevent complications has made it applicable to only a small percentage of CVA patients. Risk of intra-cerebral hemorrhage (ICH) increases after a few hours from the ischemic attack and current studies have not showed any benefit for the patients undergoing revascularization after 6 hours.

METHOD: The main reason is ischemia reperfusion injury (IRI) that results in ICH after restoration of blood flow. As IRI has become a limiting factor in extending the time window for reperfusion of the ischemic brain, we require some strategies to prevent or reduce the effects of IRI. In CVA cases, there is no place for pre-conditioning tactics as ischemia has already happened. However, post-conditioning strategies are still a viable approach to reduce IRI morbidity and allow for late revascularization.

RESULTS: In this presentation we will discuss how some surgical and medical techniques can be used in the future studies to prevent IRI and reduce the incidence of post-revascularization ICH. Some of these modalities may be used to increase the time window and help more people suffering from CVA.

EP-364[Miscellaneous] FLOW 800

Mohsen Nouri

Department of Neurosurgery, Razi Hospital, Zahedan University of Medical Sciences, Saravan, Iran

INTRODUCTION - OBJECTIVE: Importance of intra-operative angiography in cerebrovascular surgeries - ICG videoangiography (VA) and its applications - FLOW 800: what it adds to ICG VA

METHOD: FLOW800 software Software produces two types of images - Colour coded images - Flow versus time curves

RESULTS: Specific applications of FLOW800 Describe advantages and limitations of each - AVM surgeries - Aneurysm surgeries - Others (bypass, CEA, etc)

CONCLUSIONS: - What we do or we can do in the future - Limitations

EP-365(AWNA) DEVELOPING NEUROSURGERY SERVICE AT RURAL HOSPITAL 2 YEARS EXPERIENCE

Eveline Ndraha

Neurosurgery Department Siloam Hospitals Balikpapan, East Borneo, Indonesia

INTRODUCTION - OBJECTIVE: Neurosurgery service need adequate equipment to support diagnose and especially to perform surgery. Fast development in neurosurgery operation technique need more sophisticated and complete surgery equipment.

METHOD: Starting and developing neurosurgery service in rural hospital has this unique challenge and need creative thinking and more effort. Several neurosurgery cases can be done in rural hospital.

RESULTS: In 2 years experience in rural hospital in east Borneo, I have 81 surgery cases, mostly is traumatic cases (31 cases), 18 spine surgery (including 4 complicated spinal surgery), 16 Cerebrovascular cases, 5 tumor (including 3 pituitary adenoma), 1 peripheral nerve case, and 6 other cases.

CONCLUSIONS: Perform brain and spinal surgery in rural hospital with limited resources is possible, it can be done with the good outcome.

EP-366[Neurovascular Surgery] EMBOLIZATION OF CAROTID CAVERNOUS FISTULA BY BALLOON INSERTION

Thomas Tommy¹, Harsan Harsan², I. Japardi¹, Eka Julianta Wahjoepramono²

¹Dept. of Neurosurgery – Universitas Sumatera Utara – Rumah Sakit Pusat Haji Adam Malik Medan

²Dept. of Neurosurgery – Universitas Pelita Harapan – Siloam Hospitals

INTRODUCTION - OBJECTIVE: Background Carotid cavernous fistula is an abnormal communication between carotid artery system and the cavernous system1 that can be categorized by trauma or spontaneous pathogenetically and direct or indirect angiographically2. The fistula will increase venous

pressure and change venous dynamics^{3,4} causing ocular congestion, raised intraocular pressure, exophthalmia, diplopia, decreased visual acuity, cranial nerve paralysis and glaucoma¹. CCF can be diagnosed clinically and radiologically. We report the effectiveness of balloon embolization for direct CCF.

METHOD: Case Report A 28-year-old male presented with severe epistaxis and severe headache. It was the third episode for that week. Two months before admission, the patient had a motorcycle accident caused by aneurysm rupture. The aneurysm had been clipped and VP shunt had been placed because of a complication of hydrocephalus. He also had a skull base fracture. On physical examination we found the patient was GCS 15 without neurological deficit and discet bruit on temples and eyes. There was no engorgement of conjunctival vessels. From the facts of physical findings and history of a skull base fracture, a carotid cavernous fistula (CCF) was suspected.

RESULTS: DSA showed there was a direct CCF on the C5 Clinoid segment of ICA5 and the cavernous sinus was draining into petrosal sinus. Embolization of CCF was done transarterially by using two detachable balloons. Post embolization DSA showed Obliteration of fistula and the patient clinically symptoms free. No ocular or temporal bruit was found.

CONCLUSIONS: Endovascular management has become treatment of choice for CCF with numerous options and technique^{6,7} and one of that choice is by transarterial balloon embolization.

EP-367[Miscellaneous]

CONGENITAL HYDROCEPHALUS ASSOCIATED WITH PROTEIN C DEFICIENCY. A CASE REPORT AND REVIEW OF THE LITERATURE

Kimiko Umemura¹, Hideo Hamada², Hayashi Nakamasa², Taketoshi Yoshida³, Shunro Endo², Satoshi Kuroda²

¹Department of Neurosurgery, Saiseikai Toyama Hospital, Toyama, Japan

²Department of Neurosurgery, Toyama University, Toyama, Japan

³Department of Pediatrics, Toyama University, Toyama, Japan

INTRODUCTION - OBJECTIVE: We know the ground for congenital hydrocephalus; 1) idiopathic reason, 2) genetic trouble, 3) aqueductal stenosis (include in infection and hemorrhage). But it is rare case of congenital hydrocephalus who is caused by protein C deficiency. Congenital protein C deficiency is now recognized as a genetic risk for macro and microvascular thrombosis. We can find some reports that shunt malfunction patients with protein C deficiency was caused after hemorrhagic events.

METHOD: We report a **CASE:** This baby was detected in congenital hydrocephalus and a little amniotic fluid at 33 weeks gestation with prenatal-echo. When she was 34 weeks and 5 days, she was found transient bradycardia by NST, thus, she was delivered by Caesarean operation urgently.

RESULTS: She was detected in intracranial hemorrhage and Obvious hydrocephalus at one day of age. Two days after, she had a huge purplish-red spot in her parietal head. We suspected and examined her of DIC or Purpura, after that we diagnosed her as protein C deficiency. She was operated external ventricle drainage, Ommayer reservoir, irrigating in her ventricle with neuro-endoscope. But we couldn't control her hydrocephalus.

CONCLUSIONS: It was rare case, but we should consider about protein C deficiency if we diagnosed fetal hydrocephalus. It is difficult to cure of them, but early diagnosis might be possible to help them.

EP-368[Miscellaneous]

SUPRASellar TERATOMA: A CASE REPORT

Andre Siahaan¹, Julius July², Iskandar Japardi¹

¹Neurosurgery Department, Faculty of Medicine, Universitas Sumatera Utara, Medan, Indonesia

²Neurosurgery Department, Faculty of Medicine, Universitas Pelita Harapan, Tangerang, Indonesia

INTRODUCTION - OBJECTIVE: Intracranial germ cell tumors are rare and account for only 0.3 to 3.4% of all intracranial tumors. Teratomas are part of these neoplasms. Intracranial teratomas are uncommon, and only discussed in case reports. Most intracranial germ cell tumors arise from midline structures, with the pineal gland as the most common followed by the suprasellar compartment.

METHOD: A 19 years old boy came with blindness on both eyes. Laboratory examination revealed decreased serum cortisol. Magnetic Resonance Imaging showed large intrasellar mass with considerable suprasellar extension and chiasmatic compression.

RESULTS: The patient underwent endonasal transphenoid surgery. The tumor was noted to have both cystic and solid components. The cystic component was thick and yellow. On the solid component, there was skin-like part and numerous hairs. Histopathology confirmed mature teratoma, with neither immature nor malignant part. The visual acuity was improved after operation.

CONCLUSIONS: Suprasellar mature teratomas are rare cases that mimic many other lesions. It is important to recognize this entity in differential diagnosis. There is no guideline regarding the management. A multimodal approach for treatment is recommended with complete surgical resection, radiotherapy, and chemotherapy.

EP-369[Neurooncologic Surgery]

INTRAVENTRICULAR MENINGIOMAS: MANAGEMENT STRATEGIES AND TREATMENT OPTIONS

Fares Nigim, Ahmed Bayoumi, Ekkehard Kasper

Beth Israel Deaconess Medical Center - Harvard Medical School

INTRODUCTION - OBJECTIVE: IVMs represent approximately 0.5-3.7% of all meningiomas (1, 2) and about 13-30% of intraventricularly encountered tumors. (3, 4) Due to their rarity, there are very few evidence-based studies available containing a large number of patients and addressing the overall survival (OS) and progression free survival (PFS) of IVMs.

METHOD: Here we report on selected patients, who had IVMs treated with different therapeutic strategies and we put this into the appropriate context providing a review of the literature discussing modern management issues of lesions in the lateral, 3rd, or 4th ventricle.

RESULTS: A total of 7 patients with IVMs were selected. Mean age was 59.9 years; there were 5-females and 2-males. 5/7 patients had meningioma in the lateral ventricle, and 2/7 had the lesion in the 4th ventricle. Most common symptoms were headache, vertigo, N/V, visual deficit, and ataxia. Three patients were managed with biopsy and single fraction radiosurgery (1600-cGy), three patients required craniotomy only, and one case was managed expectantly. Surgical mortality employing various approaches was 0%. Symptoms resolved after treatment. Histological analysis was WHO grade-I in 3/7 cases with two fibrillary and one transitional tumors and WHO grade-II in 3/7 (2 meningothelial and 1 transitional type tumors). There was no progression from benign to higher-grade tumor in any patients during the time of follow-up.

CONCLUSIONS: Symptomatic IVMs should be resected and most symptoms will resolve immediately after surgery. CK radiosurgery is another available technique in IVMs < 4 cm. Observation is management option in asymptomatic patients.

[EP-370]

SACRAL NERVE STIMULATION IN THE TREATMENT OF NEUROGENIC BLADDER DYSFUNCTION

Kisamedenov Nurlan, Chingiz Shashkin, Akshulakov Kuandykovich Serik

Department of functional neurosurgery, National Centre of Neurosurgery, Astana, Kazakhstan.

INTRODUCTION - OBJECTIVE: The purpose of this study – to improve the results of treatment of neurogenic bladder dysfunction. Treatment of neurogenic bladder dysfunction is still remaining as complicated and unsolved problem in numerous occasions. One of the most promising directions in the treatment of neurogenic bladder disorders is to recover the lost mechanism of urination by direct or indirect electrical stimulation of nerve fibers – a method of permanent sacral neuromodulation.

METHOD: For the first time in the Republic of Kazakhstan sacral neurostimulation we conducted in National Center for Neurosurgery, Astana, from 2014. 10 patients underwent surgical treatment with different urinary dysfunction and chronic pelvic pain syndrome.

RESULTS: Results of treatment of patients (n=10) showed high efficiency. Thus, in the syndrome of urge and frequent urination positive results of treatment after 6 months of implantation were observed in 79% of patients. Self-urination returned to 59% of patients with impaired bladder emptying. Patients with chronic pelvic pain syndrome noted the disappearance or reduction of intensity. Among such complications as pain at the implant site and the area of innervation of the sacral nerves was observed in 3%, periodic paresthesia in 5%; infection in 1%, the formation of seroma and hematoma in 1%.

CONCLUSIONS: Thus, sacral nerve stimulation is a highly effective treatment for patients with severe forms of dysfunction of the act of urination, and chronic pelvic pain syndrome. It is important to understand that the sacral nerve neuromodulation is an alternative, and often the only one possible treatment for these patients' categories. In our opinion sacral neurostimulation should be done in cases where the drug and other medical treatments are not effective.

Keywords: bladder dysfunction, sacral neurostimulation, urinary dysfunction, chronic pelvic pain syndrome.

EP-371 INDICATIONS AND COUNTERINDICATIONS OF COMPUTED TOMOGRAPHY IN CRANIOCEREBRAL TRAUMATIC AND NONTRAUMATIC LESIONS.

1,2Prof. A.V. Ciurea MD., PhD., MSc. Dr. h.c. Mult.

3V. Munteanu MD., PhD

4A. Mohan MD., PhD

1H. Moisa MD.

¹Carol Davila University School of Medicine, Department of Neurosurgery, Bucharest, Romania

²Sanador Medical Center Hospital, Department of Neurosurgery, Bucharest, Romania.

³"Bagdasar-Arseni" University Hospital, Department of Neurosurgery, Bucharest, Romania.

⁴Bihor County Emergency Hospital, Department of Neurosurgery, Oradea, Romania

BACKGROUND: The appearance of modern medical imaging technologies has shaped completely the diagnosis in neurosurgical pathology. The main investigative methods in use today are Computed Tomography with its derivatives (native, with contrast substance, bone window, 3D reconstructive CT, Angio-CT) and Magnetic Resonance Imaging (MRI), native, with contrast substance and angio-MRI.

MATERIALS AND METHODS:

For the traumatic craniocerebral pathology, the emergency investigative method which grants a maximum of efficiency at patient admission is the native CT-scan. If skull fractures are suspected the next option is 3D reconstructive CT-scan and if the lesions are more severe and intracerebral traumas are suspected another scanning option presents itself through CT-scanning with contrast substance. Any county hospital should have the logistics to provide its patients a CT-scan at admission for diagnostic and forensic reasons.

To determine the extent of the lesions it is important that the CT-scan should be repeated at 6, 12 or 24 hours after admission if necessary. Any patient with a head trauma must have a discharge CT-scan for control. The results of the CT-scan must be correlated with the patient's Glasgow score, conscience status and eventual existing injuries. In children, the abusive usage of CT-scans can lead to modifications of the eye lens. In these conditions a repeated clinical examination and a follow-up of all diagnostic elements might avoid a repeated CT-scan.

Last but not least, the Marshall scale (1991) must also be taken into account as it distinguishes focal and diffuse intracranial lesions while correlating them to the patient's status.

Magnetic resonance imaging (MRI) must not be neglected in traumatic injuries of the skull and brain as it represents a very powerful tool for long term follow-up and assessment of sequelae. Lesions present on MRI scans can also be correlated with post-traumatic epilepsy and neuropsychic modifications. Although computed tomography is a first line tool, magnetic resonance imaging is the tool of choice for long term follow up. The second greatest indication of Computed Tomography is subarachnoid hemorrhage (SAH) which raises the suspicion of a burst vascular aneurismal malformation and imposes the necessity of several other investigations to confirm the diagnosis. Computed tomography is the main tool of investigation in all cases with SAH and has to be correlated with the Fisher scale (1980). CT scanning in SAH has great advantages in assessing the prognosis of the patient and with the patient's follow up. CT angiography is currently and extremely valuable means of diagnosis for aneurysms. Cases in which CT angiography surpassed digital subtraction angiography are not little. In the intracranial tumoral pathology computed tomography has only an orientative part. CT scanning in brain tumors is generally used for screening purposes. Computed tomography is unable to provide the surgeon with significant data regarding adjacent structures, tumor positioning and thus is irrelevant for surgical planning.

The elective investigation is magnetic resonance imaging (MRI). This allows for a definitive diagnosis and therapeutical strategy. In such a situation computed tomography is used only for post-op follow up of hemorrhage in the tumoral bed, ischemia or edema.

CONCLUSIONS: We consider that computed tomography has clear indications in the traumatic pathology, but this method must not be used abusively in non-traumatic lesions.

KEYWORDS: Computed tomography (CT-scan), Magnetic resonance imaging (MRI), 3D reconstruction CT, head trauma, craniocerebral injury, subarachnoid hemorrhage (SAH).

EP-372 GAMMA KNIFE RADIOSURGERY FOR LARGE VESTIBULAR SCHWANNOMA'S

D. M. ten Berge, P. E. J. Hanssens, G. N. Beute, S. T. Lie, S. Leenstra, B. van der Pol, H. B. Verheul Dept. Neurosurgery and Gamma Knife center Tilburg, The Netherlands

INTRODUCTION: Radiosurgery is a widely accepted treatment modality for small to medium sized vestibular schwannoma's (VS). However, for large VS, surgery is usually advised. Until now there is no well-defined volumetric cut off point for radiosurgery and because of this, our advice to patients with large VS is often ambiguous. In some cases of large VS, symptoms of mass effect are absent and radiosurgery may be an option to consider. The possibility of transient swelling, which presumably causes symptoms related to increased mass effect, is the main argument against radiosurgery in these cases. However, to what extent this phenomenon is clinically relevant, i.e. necessitating, surgery, is not known, and is the subject of this study.

METHODS: We retrospectively studied the volumetric patterns and side effects after Gamma Knife radiosurgery for large VS, defined as tumors with a volume of 10 cc or more. The main reasons to treat patients with large VS with radiosurgery were presence of functional hearing, patient preference and medical conditions that excluded open surgery. From January 2004 up till now we included 24 patients with a median tumor volume of 12,2 cc (range 10,0-31,1). Median follow up was 45 months (range 7-117). In general, a dose of 11-13 Gy was prescribed to the isodose covering 99-100% of the target volume.

RESULTS: In total 3 patients (13%) needed an intervention related to swelling after radiosurgery. In 2 cases (8%) resection was necessary 3 months post radiosurgery due to transient swelling with

concomitant symptoms (gait disturbance). Both were cystic tumors, which increased in size 84% and 46% respectively (leading to volumes of 19 and 15 cc.). There was one case of transient volumetric growth over 2 years of 43% leading to hydrocephalus necessitating a third ventriculostomy.

In one case the tumor showed growth 4 years after an initial response of 35% volume reduction on which resection followed. Of the remaining patients only 10% showed a mean transient volumetric increase of 13% (12-14%), without clinical sequelae. In contrast, we noticed pronounced responses of up to 94% volume reduction. At the latest follow up scans, the mean volume was 65% of the initial volume during treatment.

There where no new facial and/or trigeminal nerve deficits after radiosurgery. Pre-existing trigeminal nerve dysfunction was common (14 patients); it normalized in 7, and improved in 2 cases.

Of the patients that still experienced functional hearing prior to radiosurgery (12 patients); the majority (6 patients) reported stable hearing, 3 reported decreased hearing and 1 patient reported hearing improvement after radiosurgery, 2 patients lost their hearing after salvage resection. **CONCLUSION:** These results show that transient swelling necessitating surgery occurs in a limited number of patients. In the majority of cases significant volume reduction can be achieved. Radiosurgery is a valid option in patients with large VS, without clinical symptoms related to tumor mass. The variable responses ranging from rapid swelling to significant volume reduction warrant further research to the factors underlying this variability. This knowledge might improve patient selection.

EP-374 DIAGNOSTICS AND TREATMENT OF A BRAIN ABSCESS.

Nazarov M. K. Berdiyev R. N., Gulmurodov R. R., Sattorov A.I

Republican scientific and clinical center of pediatrics and children's surgery Dushanbe, Tajikistan.

INTRODUCTION: Brain abscess remains so far the reason of a lethal outcome more than at one third of patients. The large number of postoperative pyo-inflammatory complications and outcomes with rough neurologic deficiency, and also often developing in the residual period of surgical treatment progressing encephalopathy will remain. At children of 60% of a brain abscesses are connected with the congenital heart diseases, being accompanied blood dumping from right to left. Complications of inflammatory character quite often define an outcome of a craniocerebral injury. One of them are brain abscesses after a heavy craniocerebral injury. Prevention and treatment of brain abscesses remain one of complex and actual challenges of modern neurosurgery.

OBJECTIVE: to study features of a course of abscess of a brain at patients after a heavy craniocerebral injury. **Methods:** The analysis of treatment of 25 patients with brain abscess is carried out. To all patients was made treatment – removal of brain abscess was carried out. Patients were aged from 3x years till 65 years. Men (70,2%) able-bodied age prevailed. When collecting the anamnesis of a disease focused attention on the transferred craniocerebral injury. All patient carried out brain KT with studying of volume of a pathological substratum, a condition of ventricular system, dynamics of development of hypostasis of a brain, the phenomena of ischemia, size the subarakhnoid of cracks and tanks of basis of a brain. Also crops of CIF liquid, purulent separated of the wound, separated of drainages were made.

RESULTS: Manifestation of a clinical picture depended on a stage of a disease, a background and age of the patient. At 13% of patients the all-brain symptomatology, at 7% - all-brain symptomatology prevailed. 12 patients (60%) had single-chamber abscesses, multichamber at 4 (20%), multiple abscesses at 2(10%). Brain abscesses arisen within the first 3 months after a trauma (early) observed at 14 (70%) patients. Abscesses arisen in 3 months after a trauma (late) observed at 6 (30%) patients. In a phase of clinical subcompensation in a hospital of 9(45%) the patients, a moderate clinical decompensation - 8(40%), a rough decompensation – 3 (15%). Total removal of abscess is made 10 (40%) to patients, 15 (60%) the patient, considering the expressed clinical symptomatology, made punktsionny depletion of abscess with active drainage.

CONCLUSION: Danger of development the kraniotserebralnykh of pyoinflammatory complications at patients with a craniocerebral trauma depending on weight of a trauma proves need of carrying out purposeful actions warning these terrible complications. Tactics of treatment of brain abscess after a head injury is defined by a disease stage, expressiveness neurologic and the vital violations. It is necessary to give preference in treatment of brain abscesses to a method of total removal of abscess with a capsule.

KEYWORDS: Brain abscess, craniocerebral injury.

EP-376 COMPONENT ANALYSIS OF CENTRAL NERVOUS SYSTEM MALIGNANT TUMORS DYNAMICS IN ECOZONE OF KAZAKHSTAN.

Yerzhan B. Adilbekov

National Centre for Neurosurgery, Astana, Kazakhstan

INTRODUCTION: Analysis of morbidity with MT CNS in the studied ecological zone in the dynamics showed a slight increase in crude indicator, with a total increase of $T = 0.420 / 0000$, the growth rate depended mainly on the changes associated with the risk of getting sick ($\Sigma = \Delta P = +0.360 / 0000$). Ecological zone of Kazakhstan health outcomes associated primarily with demographics. Dynamics of the total population of ecozone since 2003 tended to grow and average annual growth rate was $TPA = 2.3$

THE AIM OF RESEARCH: To study the peculiarities of morbidity with malignant tumor of central nervous system in general, according to genital and age particular qualities in our republic.

MATERIAL AND METHODS. Retrospective research for the period 2003-2010. The data of cancer institutions in republic (table 7) and the statistics on population number of Kazakhstan Republic Agency are used. According to the generally accepted methods of medico-biological statistics, we

found out the extensive, age (ARI), rough (CR), standard in age – ASR – (WORLD – WS) and equalized indices (EI) of disease and its trends.

RESULTS AND DISCUSSION: The annual crude rate of MT CNS of all population in Kazakhstan was equal to $3.6 \pm 0.1\%$ (95% CI= $3.4-3.8\%$). The crude index of MT CNS within all population in dynamics increased from $3.14 \pm 0.15\%$ (2003) to $3.57 \pm 0.15\%$ (2010). At alignment of this indicator the tendency to growth was established, and annual rate of growth made $T=+1.6\%$ (figure 1).

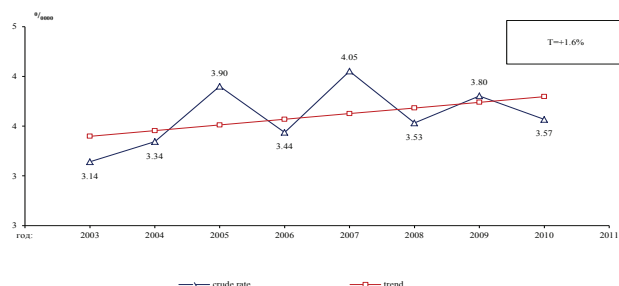


Figure 1 – The rough index dynamics of morbidity with malignant tumors of central nervous system in Kazakhstan for 2003-2010. The standardized indices of morbidity with MT CNS of all population of republic were different. But we have found out, that the most common for Kazakhstan was the world standard – $3.57 \pm 0.100/0000$ (95% CI= $3.37-3.760/0000$) because it was exactly the same as the rough index. The annual African standard was equal to $2.89 \pm 0.080/0000$ (95% CI= $2.73-3.050/0000$), and the European standard compounded $4.25 \pm 0.120/0000$ (95% CI= $4.02-4.480/0000$). The analysis of 95% CI standard indices has showed that they weren't imposed at each other. In dynamics the equalized standard indices had the tendency to grow and the annual rates of increase were the following: the world – $T=+1.9\%$; the European – $T=+2.2\%$; the African – $T=+1.0\%$ (figure 2).

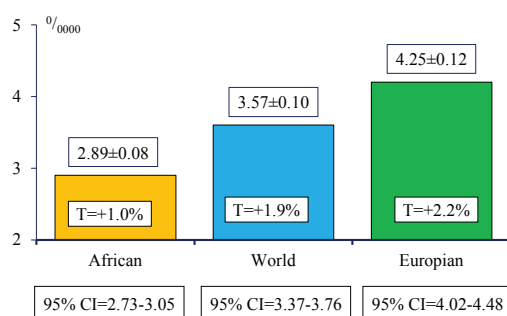


Figure 2 – Standardized indices of morbidity with malignant tumors of central nervous system of all population in Kazakhstan for 2003-2010

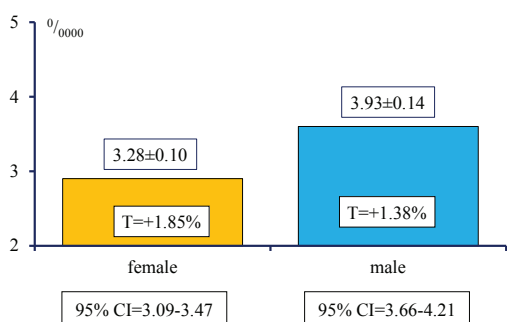


Figure 3 – Annual indices of morbidity of male and female population with MT CNS in the Republic of Kazakhstan for 2003-2010

Age groups, sex	Both		Male		Female	
	P±m	95% CI	P±m	95% CI	P±m	95% CI
To 30	1.57±0.08	1.41-1.72	1.68±0.12	1.44-1.91	1.45±0.06	1.34-1.56
30-39	2.97±0.17	2.64-3.30	3.31±0.23	2.85-3.76	2.65±0.13	2.39-2.91
40-49	4.92±0.16	4.59-5.24	5.53±0.21	5.13-5.94	4.36±0.20	3.97-4.75
50-59	9.37±0.38	8.62-10.12	11.16±0.67	9.84-12.47	7.91±0.23	7.45-8.36
60-69	9.94±0.47	9.01-10.87	12.39±0.70	11.01-13.78	8.29±0.57	7.17-9.40
70 +	5.12±0.55	4.05-6.19	6.68±0.49	5.73-7.63	4.37±0.66	3.08-5.65

Genital related peculiarities of MT CNS morbidity in Kazakhstan. The annual index of morbidity with MT

CNS in Kazakhstan made $3.93 \pm 0.140/0000$ (95% CI= $3.66-4.210/0000$) at men and $3.28 \pm 0.100/0000$ (95% CI= $3.09-3.470/0000$) at women. The differences were statistically significant ($p < 0.05$) (figure 3). In the dynamics the crude index of morbidity with MT CNS of the male population has grown and the annual rate of growth made $T=+1.38\%$. The women's indices of MT CNS morbidity have changed from $2.92 \pm 0.190/0000$ (2003) to $3.45 \pm 0.200/0000$ in 2010 and at equalizing the data we have also found their tendency to growing ($T=+1.85\%$).

The age-related peculiarities of MT CNS morbidity in Kazakhstan. The appearing and circulation of MT CNS as well as many other MT depend on the age of the population, because the age of a person is the most substantial risk factor. Thus, among all the population younger 30 years the index of MT CNS morbidity made $1.57 \pm 0.080/0000$ (95% CI= $1.41-1.720/0000$). Comparing with this group we can see that in group of people 30-39 years old the level of morbidity has increased in 1.9 times years and compounded $2.97 \pm 0.170/0000$ (95% CI= $2.64-3.300/0000$) (table 1). Table 1. Annual age indices of MT CNS morbidity of population in Kazakhstan for 2003 -2010

Compared to data of 30-39 years old group, at the age of 40-49 the frequency increased in 1.7 times and became $4.92 \pm 0.160/0000$ (95% CI= $4.59-5.240/0000$). At the age of 50-59 the morbidity rate made $9.37 \pm 0.380/0000$ (95% CI= $8.62-10.120/0000$) which is 1.9 times higher than at the age of 40-49. Further in 60-69 years the index of MT CNS morbidity has increased in 1.1 times, in comparison with the previous age group – $9.94 \pm 0.470/0000$ (95% CI= $9.01-10.870/0000$). In the age group of 70 and older the index was $5.12 \pm 0.550/0000$ (95% CI= $4.05-6.190/0000$), that is in 1.9 times lower than at the age of 60-69. Thus, the number of patients with MT CNS in ecological zone Kazakhstan increases. The growth is mainly based on to the expense of the population growth, the joint effect of changes in population size and age structure, changes in the risk of getting sick, the joint effect of changes in the risk of getting sick, and the age structure of the population. The results of the component analysis of the dynamics of MT CNS in ecological zone of Kazakhstan recommended to use while planning anticancer activities.

EP-377 RECONSTRUCTIVE SURGERY IN CRANIOBASAL LESIONS COMPLICATED WITH LONG-TERM CSF LEAKAGE

Okhlopov V., Potapov A., Kravchuk A., Likhterman L., Kapitanov D, Gavrilov A. The Burdenko Neurosurgical Institute, Moscow, Russia

OBJECTIVES: Results of surgical treatment of long-term basal CSF leakage depending on the type of intervention are presented.

MATERIAL AND METHODS: 253 patients aged 3-71 years (mean 27,6) were operated from 1988 to 2013. CSF leakage was complicated by meningitis in 44,8% of all cases. Time between CSF leakage occurrence and surgery varied from one month to 25 years, average 2,7 years. We used autologous tissues alone for plastic reconstruction in all patients. 135 of them were operated with the application of fibrin-thrombin glue.

RESULTS: Intracranial intervention was combined with recurrent lumbar punctures following surgery - 46 cases; CSF leakage recurrence was revealed in 10 observations (21,7%). Later on (136 cases) methods of intra- and postoperative external drainage of the lumbar CSF (average - 8 days) were used. CSF leakage recurrence was marked in 15 cases (11,1%). In the first 17 cases we performed percutaneous drainage installation; 23,5% of meningitis in this series. By a «long-tunnel» method of the CSF drainage (119 patients) meningitis was observed in 6 patients (5,1%). In 5 cases, when CSF leakage was combined with intracranial hypertension, the skull base plasty was carried out together with the shunting operation; CSF leakage recurrence was marked in 2 cases (40%). CSF fistula closure was performed by the transnasal approach in 51 cases; CSF leakage recurrence was marked in 8 cases (15,7%). Shunting operation alone was performed in 15 patients. CSF leakage recurrence with decreased CSF leakage volume was marked in 3 cases (20%).

CONCLUSION: Best results of surgical treatment of long-term basal CSF leakage with the verified CSF fistula were achieved by using combination of intracranial intervention and intra- and postoperative CSF drainage.

KEY WORD: CSF leakage, skull base plasty, CSF leakage recurrence, CSF drainage, meningitis

EP-378 ROLE OF CISTERNOSTOMY IN MICROSURGICAL APPROACH TO HYPERTENSIVE DEEP NUCLEAR BLEED: SHORT TERM OUTCOME EVALUATION IN CENTRAL PART OF NEPAL

Dr Balaji Srinivas S, Dr Iype Cherian, Dr Karuna Tamrakar
Department of Neurosurgery, College of Medical Sciences, Bharatpur, Nepal.

BACKGROUND AND PURPOSE: Although effectiveness of surgical evacuation of hypertensive deep nuclear bleed remains controversial, this paper mainly focuses on our preliminary experience and additional role of cisternostomy, and short term outcome evaluation after trans-sylvian trans-insular evacuation of hypertensive deep nuclear bleed.

MATERIAL AND METHODS: In between August 2012 to October 2013, 31 surgically managed patients with hypertensive deep nuclear bleed were reviewed retrospectively. Among them, 24 patients underwent trans-sylvian trans-insular evacuation of hematoma and 7 patients underwent trans-cortical evacuation. With our experience of cisternostomy in traumatic brain injury, we performed cisternostomy in some patients where total evacuation of the hematoma was not done so as to make brain lax and sometimes it helped in preventing further injury to the brain parenchyma while attempting total evacuation.

RESULTS: 11 were males and 13 were females. Age ranged between 35- 70 years with mean age of 53.54 years. Volume of hematoma as measured by $a \times b \times c/2$ method in computed tomography scan ranged from 48 - 105 ml (mean volume 64.67 ml). 8 were hypertensive patients taking antihypertensive medications on irregular basis. 5 cases had icus of intracranial hemorrhage despite taking regular antihypertensive medications. Remaining 11 had never taken medications before. 7/15 was the lowest GCS score and the highest score observed was 13/15 on arrival to emergency room. 19 cases showed near total evacuation of hematoma on repeated scan taken after 24 hours of surgery. 2 patients with putaminal bleed underwent re-evacuation on the second post-operative day. 2 patients died on the third and fourth postoperative day respectively due to myocardial infarction. 1 patient died due to repeated hematoma collection due to coagulopathy on the ninth postoperative day. Modified Rankin Score (MRS) during discharge was 4 in 7 cases and 10 cases obtained score 3 and 4 cases obtained MRS score of 2. In 6-month clinical follow up, 8 cases attained MRS score 4, 6 cases scored MRS score 3 and 4 cases scored MRS 4. We lost clinical follow up in remaining 3 cases.

CONCLUSIONS: Although precise surgical skill is required for microsurgical dissection of sylvian fissure, this technique not only depicts the accurate anatomical orientation in sylvian fissure, but also helps in preserving the overlying eloquent cortex in frontal and temporal lobes and subsequently reduces the mortality and morbidity rates in patients with hypertensive nuclear bleed. Performing craniostomy also helps in preservation of cortical function but needs further study.

REFERENCES:

1. Lye Cheria, Ghuo Yi, Sunil Munakomi. Craniostomy-replacing the age old decompressive hemicraniectomy? p. 781-790 in 2nd edition of Essential Practice of Neurosurgery (WFNS), 2009, Access, Nagoya-Japan.
2. Inglese M et al. Clinical significance of dilated Virchow Robin spaces in mild traumatic brain injury. Brain Inj. 2006 Jan;20(1):15-21
3. Jeffrey J. Iliff, Ming huan Wang, Maiken Nedergaard et al. A Paravascular Pathway Facilitates CSF Flow Through the Brain Parenchyma and the Clearance of Interstitial Solutes, including Amyloid β . Sci Transl Med. 2012 August 15; 4(147): 147ra111.

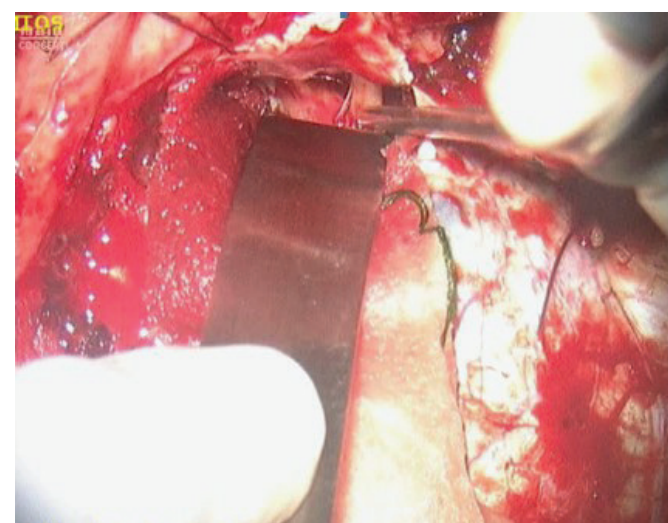
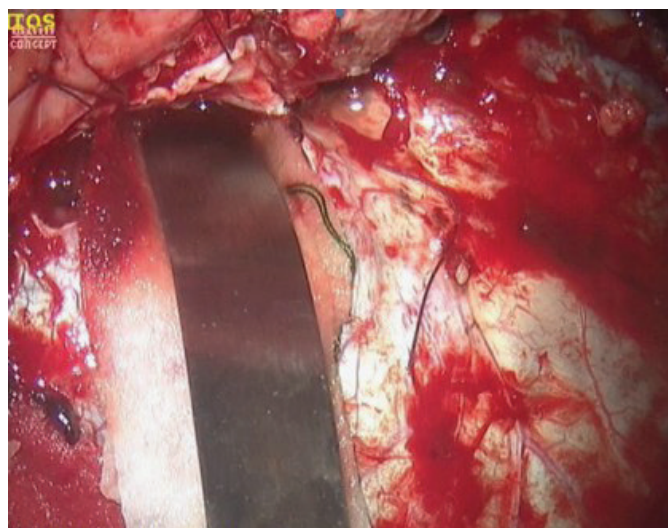
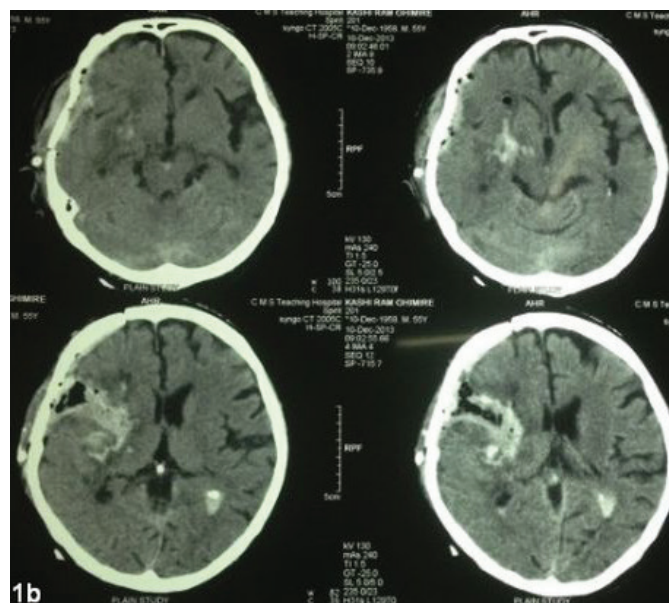
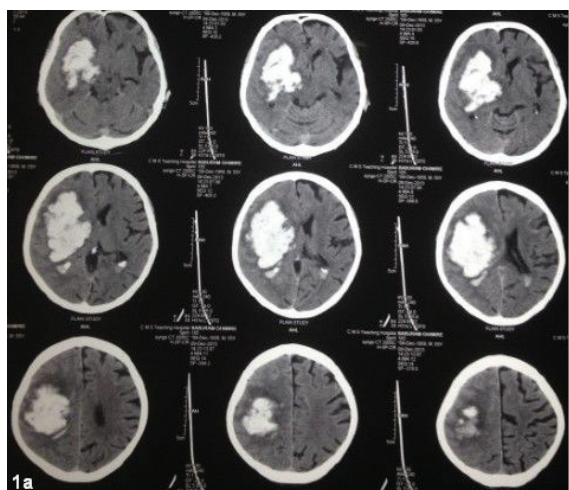


Fig 2a and 2b. CT of brain showing deep nuclear hematoma and postoperative scan of complete evacuation

Fig.3. Intra-operative view after dural opening and subfrontal retraction

Fig.4. Intraoperative view of opening the interoptic cistern

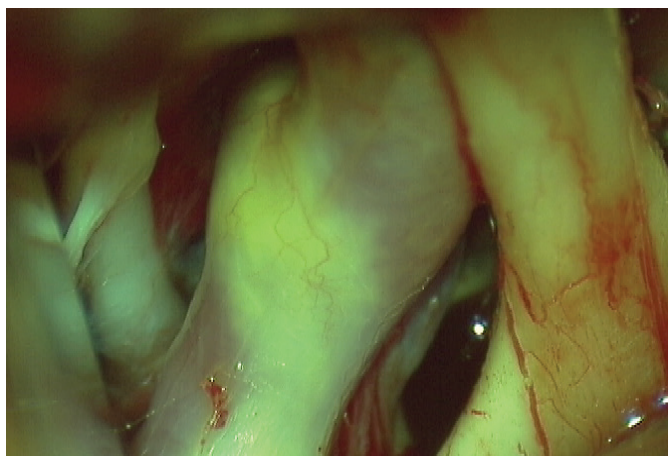


Fig. 5. Intraoperative view of optico-carotid and lateral carotid space

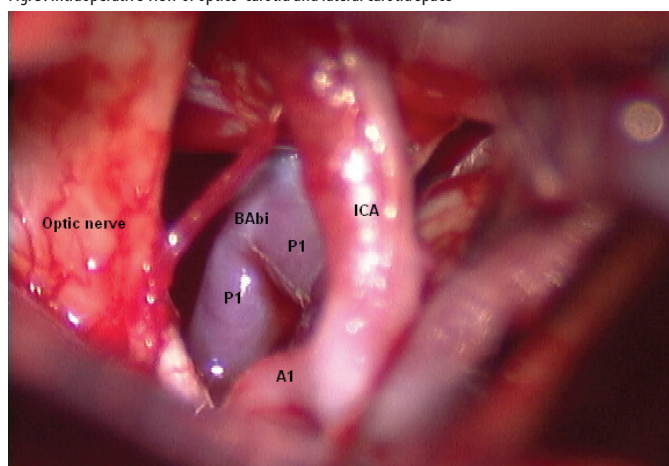


Fig. 6. Intraoperative view of Interpeduncular and pre-pontine cistern with basilar artery

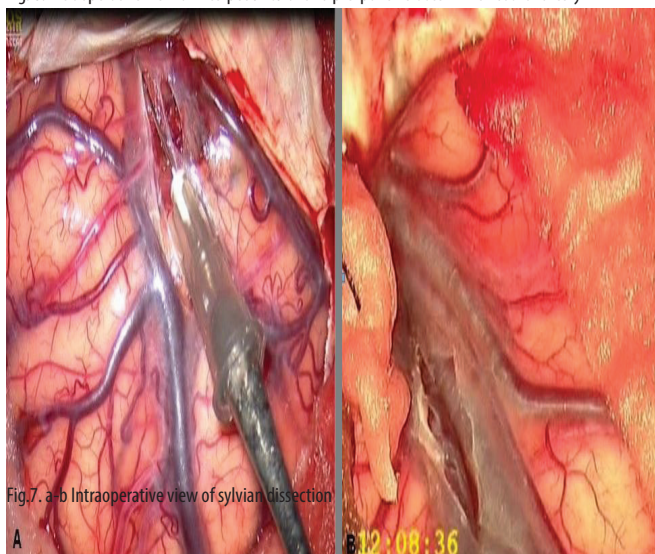


Fig.7. a-b Intraoperative view of sylvian dissection

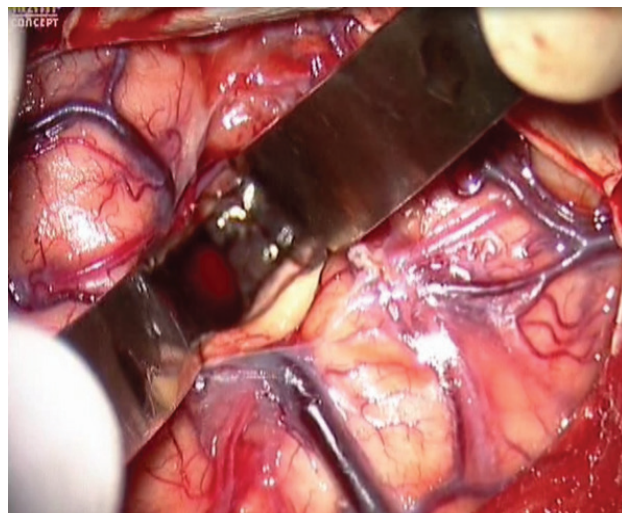
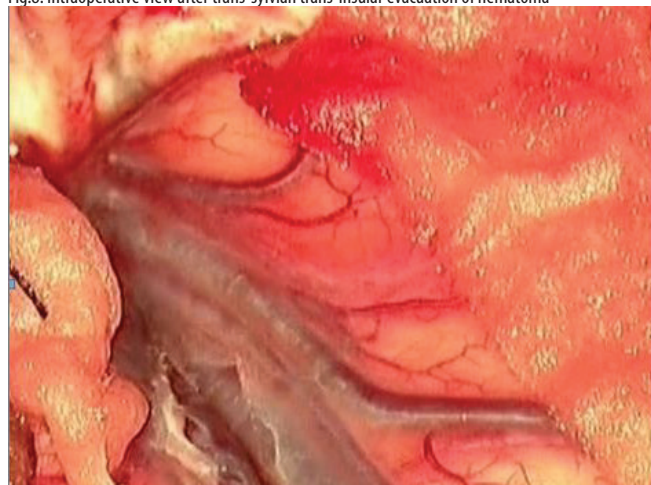


Fig.8. Intraoperative view after trans-sylvian trans-insular evacuation of hematoma



НОВОСТИ НАУКИ

"Семейная" премия за "GPS" в мозге открыла нобелевскую неделю - 2014

Премия по физиологии или медицине за 2014 год присуждена за открытие клеток, которые составляют систему позиционирования мозга. Ее лауреатами стали исследователи Джон О'Киф и супруги Май-Бритт и Эдвард Мозеры.

Нобелевская неделя-2014 началась в Стокгольме в понедельник объявлением лауреатов высшей научной награды по медицине или физиологии. Премию разделили между собой американо-британский ученый Джон О'Киф (John O'Keefe) и супруги Май-Бритт и Эдвард Мозеры (May-Britt and Edward Moser) из Норвегии, выяснившие, как устроена внутренняя "навигационная система" животных и человека.

Результаты этих работ, помимо фундаментального понимания, как действует "карта местности" в нашем мозге, помогут в понимании причин тяжелых недугов, таких как болезнь Альцгеймера, и даже пригодятся при создании роботов-андроидов, умеющих самостоятельно ориентироваться на местности, полагают эксперты.

В истории Нобелевской премии уже были случаи, когда ее получали супруги. Пьер и Мария Кюри в 1903 году удостоились награды по физике, а в 1935 году их дочь Ирен Кюри с мужем Фредериком Жолио были отмечены наградой в области химии. В 2014 году пришел час "семейной" премии по медицине.

Наш внутренний навигатор

О'Киф и Мозеры удостоены Нобелевской премии за открытие клеток, которые составляют систему позиционирования мозга. О'Киф получит одну половину премии, а супруги Мозеры – другую.

Работы новых лауреатов позволили ответить на вопросы, каким образом мы знаем, в какой точке пространства находимся, как находим путь из одного места в другое и как эта информация запоминается и воспроизводится в зависимости от месторасположения, отмечается в пресс-релизе Нобелевского комитета.

В 1971 году О'Киф открыл в головном мозге крыс так называемые клетки места, которые всегда активировались, когда животные находились в том или ином месте помещения, где проводились эксперименты. О'Киф пришел к выводу, что эти клетки формируют в мозге крыс своего рода карту комнаты.

В 2005 году Мозеры обнаружили другой ключевой компонент нашей "системы GPS" – координатные нейроны, которые создают внутреннюю мозговую систему координат.

Вместе и клетки места, и координатные нейроны отвечают за определение местоположения и навигацию. Именно эти клетки страдают при нейродегенеративных болезнях, связанных с потерей ориентации в пространстве. Знание о том, как устроена система позиционирования в мозге, поможет лечить эти нарушения.

Путь к андроидом будущего

Результаты работ О'Кифа и Мозеров могут помочь в создании роботов-андроидов нового поколения, использующих принципы работы головного мозга животных и человека, считает руководитель отдела эпигенетики Института общей генетики имени Вавилова профессор Сергей Киселев.

"Нобелевская премия вручается за то, что научное открытие дало или может дать человечеству в технологическом плане. Так вот в технологическом плане подобные исследования (выполненные нынешними лауреатами – ред.) дают возможность сделать большой шаг в познании себя, своего мозга и в создании каких-либо робототехнических устройств", – сказал Киселев в эфире телеканала "Россия 24". Он напомнил, что один из новых лауреатов, О'Киф, занимается вопросами приложения данных нейробиологических исследований к искусственным системам.

По словам Киселева, для развития робототехники "надо менять логику построения информационных систем", "подсмотрев" необходимые решения у природы.

"И если мы научимся так же эффективно воспроизводить эти вещи вне организма, конечно же, это даст большие технологические преимущества", – отметил ученый. В частности, клетки, которые составляют "навигационную систему" в головном мозге животных и человека, можно будет использовать в системах управления у роботов, полагает Киселев. "Конечно, это варианты не сегодняшнего, а завтрашнего дня", – уточнил ученый.

Церемония награждения лауреатов пройдет по традиции 10 декабря в день кончины основателя Нобелевских премий – шведского предпринимателя и изобретателя Альфреда Нобеля (1833-1896).

Источник: РИА Новости / www.ria.ru

Алфавитный указатель

А

- Abbas Amirjamshidi 35
 Abd Al Aziz A. El Nekady 73
 Abdallah Anas 28, 79, 80, 81, 84, 91, 106, 108,
 121, 131, 133, 137, 139, 140
 Abdul Aziz Yusoff 41
 Abdul Hafid Bajamal 33, 56
 Abdul Karim Msaddi 28, 131
 Abdul Nasser Khader Omer Thabet 46
 Abdulla Muhammad Qassim 92
 Abdullah Emre Taçyıldız. 84, 108, 122, 131, 141, 142
 Abdullah Topcu 47
 Abdurakhmon Norov Ubaydullaevich 133
 Abdusattarov Komiljon 43
 Abel Mitsuo Takey 73, 132, 153
 Abu Saleh Md Abu Obaida 52
 Abukwedat Loay 131
 Acar Feridun 75, 142
 Acar Göksemin 142
 Adilbekov Yerzhan Boranbaevich 149, 150
 Adilet Azretovich Yernazarov 154
 Adnan Johari Siregar 62
 Adnan Khan 46
 Adnan Ozturk 53
 Adrian Zosim Bodiu 111
 Agrawal Deepak 147
 Agzamov Istam 69
 Agzamov Mansur 69
 Ahmad Fawad Pirzad 37
 Ahmed Abdullah Elfiki 30, 42, 56
 Ahmed Al Ayouty 138
 Ahmed El Fiki 36
 Ahmed El Fiki 92
 Ahmed Elsayed Sultan 124
 Ahmed Mohamed Zaater 56
 Ahmed Mostafa Yehya 73
 Ahmed Sultan 96
 Ahmediyev Makhmud 61
 Ahmet Murat Musluman 141
 Aikaterini Panteli 47
 Ailin Chen 34, 44, 52
 Ailin Chen 92, 93
 Aj Sabbagh 30
 Ajay Choudhary 88
 Akbari Nader 76
 Akhmediyev Mahmud Mansurovich 112
 Akhmediyev Makhmud M 113
 Akhmediyev Tokhir M 113
 Akhmerova Larisa 62
 Akhmetov Kanat 51, 75
 Akhmetzhanov Vadim 135
 Akshulakov Serik 32, 53, 71, 72, 75, 157, 159
 Aktas Ozgur 126, 129
 Alataş Ibrahim 122, 141
 Aldiyarova Nurgul 72
 Aleinikov Viktor 38, 130, 131
 Alexandra R Kunz 55
 Alexeev Andrey G 95
 Alexeev Sergey 66, 68
 Alfawareh Mohamed 138
 Ali Alper Takmaz 27
 Ali Ayyad 27, 40
 Ali Ender Ofluoğlu 28, 37, 131, 137
 Ali Hikmat Aziz 139
 Ali Kıvanç Topuz 74
 Ali Mumtaz 144, 145, 154
 Alias Azmi 117
 Alibekov Y.B. 160
 Alican Tahta 53
 Aliev Mansur Abdukholikovich 29, 49
 Alihodjaeva Gulnara 61
 Almusrea Khaled 138
 Alp Harun 150, 152
 Altay Sencer 53
 Altibaev Uygun 43, 61, 65
 Altinel Faruk 29
 Altuğ Filiz 135
 Amelin Mikhail E 69
 Amir Azarhomayoun 35
 Amirjamshidi Abbas 37, 42
 Amirqul Shodiev Shodievich 84
 Ammirati Mario 46
 Amr Al Shehaby 138
 Anant Mehrotra 73, 98
 Anas Abdallah 37, 41
 Anas I Dyab 124
 Andrasoni Zorinela 23



Andreev Dmitrii Nikolaevith.....	23, 33
Anil Kumar Singh.....	35
Aniruddh Kumar Purohit	111
Antonov Gennadiy	106
Aoiuj Lassaad.....	122
Aras Yavuz	141
Arata Tomiyama.....	36
Ardian Hana.....	25
Ardıç Nejdet	77, 143
Arik Deniz	72
Arnaut Mohamed	68
Arslanova Zera Enverovna	112
Arslantas Ali	72
Arun K Srivastava.....	73, 98
Arvanitakis Dimitrios.....	141
Asadullaev Ulugbek.....	43, 61, 65
Asghari Masod	75
Ashrapov Jamshid	112
Asifur Rahman Bijou	117
Asiltürk Murad.....	41, 84, 91, 106, 108
Aslan Serkan	127
Aslanova Malika	126
Asra Al Fauzi.....	33, 56
Astafieva Ludmila	66
Ateş Özkan	78
Athanasios Konstantinos Zisakis	111
Atul Goel	27, 33
Auezova Raushan	72
Avramov Toni	23
Avyasov Rashid.....	28, 37, 41
Avyasov Rashid.....	79, 108, 131, 137, 140
Awadhesh K Jaiswal.....	73, 98
Ayça Arslanhan	55
Aydin Aydoseli	53
Aydin Emre Hasan	24
Aydin Ilhan.....	28
Aydin Ilhan.....	79, 80, 84, 91, 108, 121, 122, 137, 140, 141, 142
Aydin Yunus	141
Aydoseli Aydin	141
Ayman Al Banyan	30
Ayyad Ali.....	25, 48, 77, 108, 111
Azarhomayoun Amir	37, 42
Azmin Kass Rosman.....	31, 155

В

Baba Ahmed Rabea	111
Babahanov Bakhodir	43
Badar Uddin Ujjan	127
Badra Abzouzi	111
Bainan Xu.....	97, 100
Bajamal Abdul Hafid	24
Bajamal Zaky.....	140
Bakradze Lasha.....	115
Bakthavachalam Ramesh	125
Balaji Srinivas S	161
Balgopal Karmacharya	52
Bari Ehsan.....	61
Baritchii Adriana.....	32
Barroiher Lisa	25
Bartosh Elena P.....	69
Başarslan Kağan	150
Baykara Eyüp.....	77
Bayoumi Ahmed.....	159
Begmanov Timur Adilovich.....	116
Behari Sanjay	73
Beibei Mao.....	119, 141
Bekzod Abdullaevich Saidov	144
Belhachmi Adil	79
Belik Alexandr Anatolievich	117
Belsan Tomas	43
Benes Vladimir.....	43
Berdikhodjayev Mynzhylky.....	34, 141
Berdiyev R.N.....	160
Berestov Vadim.....	34, 99
Bernard Florian	31
Bernhard Hirt.....	47
Berthold Christophe	25
Betül Güler.....	28, 37, 41
Bhargava Pranshu	91
Bilal Khan Afridi.....	39, 53, 96, 144, 146
Bin Dai.....	141
Bin Xu.....	27
Binod Gharti	52
Bo Liu	40
Boboev Jalolidin	84, 85
Bobylev Alexandr Gennadevich.....	66
Bodapati Chandramowliswara.....	123
Bogdanovich Igor	106

<i>Boon Seng Liew</i>	31
<i>Bouali Sofiene</i>	122
<i>Boubaker Adenane</i>	122
<i>Bouhoula Asma</i>	122
<i>Boyalı Osman</i>	141
<i>Bragina Olga</i>	56
<i>Brahim El Mostarchid</i>	79, 119
<i>Bum Jun Kim</i>	109
<i>Burak Hasan Gündüz</i>	137
<i>Buzunov Alexei</i>	62, 63
<i>Byeong Yeon Choi</i>	105
<i>Bykov Roman A.</i>	95

C

<i>Carlo Antonio Todaro</i>	38
<i>Caspani</i>	29
<i>Cavlak Uğur</i>	135
<i>Cavusoglu Halit</i>	141
<i>Celal Özbek Çakır</i>	27
<i>Cem Atabey</i>	74
<i>Cerasti Davide</i>	29
<i>Cesur Fatih</i>	41, 81, 91, 108, 131, 137
<i>Cetin Eyup</i>	129
<i>Chandra Anil</i>	91
<i>Chandramowliswara Bodapati</i>	37
<i>Chandramowliswara Prasad Bodapati</i>	129
<i>Chang Il Ju</i>	32, 124
<i>Chao Sun</i>	26, 34, 92, 93
<i>Chaoyong Xiao</i>	80
<i>Chee Pin Chee</i>	142
<i>Chen Ailin</i>	26
<i>Chen Jian</i>	33
<i>Chen Wu</i>	97
<i>Chen Yanming</i>	26
<i>Chen Yong Yan</i>	109
<i>Chen Yongyan</i>	157
<i>Chernenko Oksana G.</i>	113
<i>Chernov Mikhail</i>	45
<i>Chernov Sergey</i>	67
<i>Chernykh Elena</i>	26, 85
<i>Chernykh Vadim</i>	85
<i>Chinchaladze Lili</i>	115
<i>Chischina Nina</i>	67
<i>Chobulov S.</i>	33
<i>Choi Woo Jin</i>	23
<i>Christos Kelesis</i>	111
<i>Chuan He</i>	102
<i>Chuhonskij Andrey I.</i>	44
<i>Chul Hoon Chang</i>	105
<i>Chun Po Yen</i>	47
<i>Chunfa Qian</i>	157
<i>Cihan Altin</i>	29
<i>Cirak Bayram</i>	75
<i>Civlan Serkan</i>	77, 134, 142
<i>Condrea Eugeniy</i>	67, 99
<i>Conrad Jens</i>	77
<i>Constanta Dumitru Bodiu</i>	111
<i>Cooroush Gharegozli</i>	44
<i>Corrado Iaccarino</i>	29, 73
<i>Csokay Andras</i>	55

Ç

<i>Çalışkan Tezcan</i>	78
<i>Çeliker Duygu</i>	117, 130
<i>Çeliker Özkan</i>	77, 117
<i>Çirak Bayram</i>	130
<i>Çirak Musa</i>	127
<i>Çitişlı Veli</i>	78, 134, 135, 143
<i>Çoşkun Erdal</i>	117

D

<i>Dacosta Leodante</i>	110
<i>Dalia Mofreh Elsakka</i>	55, 156
<i>Dangmurenjiafu Geng</i>	40
<i>Daniel Carvalho Kirchhoff</i>	73, 132, 153
<i>Danilin Vasily</i>	113
<i>Danilov Valeriy I.</i>	95
<i>Daoud Esam</i>	68
<i>Darbar Aneela</i>	63
<i>Davide Nasi</i>	73
<i>Deepak Agrawal</i>	87, 88
<i>Denis E Bragin</i>	56
<i>Denis E Bragin</i>	91
<i>Denisov Ilya</i>	86
<i>Deniz Konya</i>	55
<i>Dentzel Dmitry</i>	99
<i>Dewan Shamsul Asif</i>	28
<i>Dierk Fritz Bodo Kirchhoff</i>	73, 132, 153

<i>Dikhtyar Yuri</i>	51
<i>Dilorom Murodova</i>	61
<i>Dilshod Mamadaliev</i>	44
<i>Dimostheni Artemisia</i>	64
<i>Dinesh K Shukla</i>	73
<i>Dingwei Peng</i>	97
<i>Diusheev Buranbek Djamgyrchievich</i>	76, 82, 83
<i>Djumanov Kamaliddin</i>	129
<i>Dmitriev Alexander</i>	67
<i>Dodier Phillip</i>	40, 48, 111
<i>Don Oleg</i>	23, 116
<i>Dong Ho Kim</i>	87
<i>Dong Jun</i>	107
<i>Dong Jun Lim</i>	109
<i>Dong Xiaofeng</i>	74
<i>Dongwoo John Chang</i>	40
<i>Doskaliev Aidos</i>	71, 72, 75
<i>Dubovoy Andrei Vladimirovich</i>	40, 97
<i>Duschanov Temur</i>	112

E

<i>Eddie Tan</i>	53
<i>Edoardo Picetti</i>	29
<i>Edwin M Nemoto</i>	56, 91
<i>Egamberdiev Rakhmon</i>	43, 61, 65, 145
<i>Ehab Mohamed Eissa</i>	30
<i>Eiji Kohmura</i>	46
<i>Eilami Owrang</i>	139
<i>Eka Julianta Wahjoepramano</i>	158
<i>Ekkehard Matthias Kasper</i>	25
<i>Eko Agus Subagio</i>	140
<i>Elgohari Mohamed Elmenshawi</i>	112
<i>Elizbarashvili Irma</i>	68
<i>Eljebbouri Brahim</i>	79, 119
<i>Emad Aboud</i>	40
<i>Emel Erhan</i>	28
<i>Emel Erhan</i>	79, 80, 81, 84, 91, 106, 108, 121, 131, 133, 137, 139, 140
<i>Emre Abdullah Taçyıldız</i>	79, 80
<i>Emre Hasan Aydın</i>	72, 88
<i>Enchev Yavor</i>	23
<i>Ender Gedik</i>	27
<i>Endo Shunro</i>	159
<i>Erhan Emel</i>	37, 41

<i>Eshkuvvatov Gayrat E.</i>	48
<i>Esin Gezmis</i>	29
<i>Eskerova A. A.</i>	132
<i>Esra Arun Özer</i>	118, 119
<i>Eutychios Archontakis</i>	111
<i>Evran Sevket</i>	26
<i>Evsukov Alexey</i>	42, 67

F

<i>Fabio Furukawa Okuda</i>	73, 132, 153
<i>Fahmida Arab Mallah</i>	26
<i>Fangye Li</i>	97, 100
<i>Fariborz Ghaffarpasand</i>	88
<i>Farzin Navid</i>	76
<i>Faz Muhammad Faris</i>	24
<i>Feng Guan</i>	119, 141
<i>Feng Ling</i>	109
<i>Feras K Haddad</i>	124
<i>Feridun Acar</i>	47
<i>Feyza Karagoz Guzey</i>	126, 129
<i>Filipenko Maxim</i>	62
<i>Firman Adi Sanjaya</i>	140
<i>Florian H Ebner</i>	47, 64
<i>Florian Ioan Stefan</i>	23, 32
<i>Florian Roser</i>	64
<i>Fomichev Dmitry</i>	66, 68, 69
<i>Fossi Francesca</i>	29, 153
<i>Fouad Mohamed Ghareeb</i>	55
<i>Franco Servadei</i>	29
<i>Frank Hertel</i>	31
<i>Froio Elisabetta</i>	73
<i>Fuyu Wang</i>	97
<i>Fzhenghui Sun</i>	97

G

<i>G Bhaskar</i>	104
<i>Galiev Ibragimbek</i>	51, 140
<i>Galimzhan Mamirbekovich Yelikbayev</i>	154
<i>Ganesh Kumar Manoharan</i>	107
<i>Ganjeifar Babak</i>	123
<i>Gavrilov A.</i>	142, 161
<i>Gavronina Oxana</i>	31, 48
<i>Gazzaz Miloudi</i>	79
<i>Gee Teak Sheng</i>	155

<i>George Hadjigeorgiou</i>	111	<i>Halikulov Elbek Sh.</i>	127
<i>George Markogianakis</i>	111	<i>Halimov A. R.</i>	158
<i>George Psilovassilopoulos</i>	111	<i>Hamada Hiedeo</i>	159
<i>Ghadirpour Reza</i>	73, 132, 153	<i>Hammadi Firas</i>	25, 27, 40, 48, 77, 108, 111
<i>Ghanem Salman Al Sulaiti</i>	46	<i>Hanaei Sara</i>	27
<i>Gholamreza Bahadorkhan</i>	84	<i>Hany Abdelhamid Fikry Eldawoody</i>	109
<i>Ghorbel Mohamed</i>	94	<i>Hao Ding</i>	82
<i>Gibran Aditiara Wibawa</i>	140	<i>Hao Li</i>	27
<i>Giese Alf</i>	25, 27, 48, 77, 108, 111	<i>Haritonov D.G.</i>	7
<i>Gladishev Stanislav</i>	106	<i>Harjinder Singh Bhatoe</i>	35, 42
<i>Glaser Martin</i>	25, 108	<i>Haroon Pillay</i>	81
<i>Gloria L Statom</i>	56, 91	<i>Harsan Harsan</i>	158
<i>Göçmen Selçuk</i>	117, 134, 142	<i>Hasan Burak Gündüz</i>	37, 41, 80, 81, 84, 91, 108
<i>Goel Atul</i>	23, 76, 83, 107	<i>Hashmi Fauzan</i>	61
<i>Gökçedağ Akın</i>	28, 121, 131, 133, 137, 139, 140	<i>Havryliv Taras</i>	44, 68
<i>Gökhan Reşitoğlu</i>	27	<i>Haydarov Ulugbek</i>	43
<i>Göksel Güven</i>	74	<i>Hazim Mostafa Kamal</i>	42
<i>Göksemin Acar</i>	47	<i>He Sheng Xue</i>	109
<i>Gong Mingjie</i>	33	<i>Hee Jin Yang</i>	38
<i>Gopal Raman Sharma</i>	41, 47, 109	<i>Heng Zhao</i>	95
<i>Gorbatykh Anton</i>	34, 99	<i>Herlan Stephan</i>	47
<i>Gormolysova Ekaterina</i>	67	<i>Hertel Frank</i>	25
<i>Grigolashvili M. A.</i>	132	<i>Hideaki Ueno</i>	36
<i>Grzyb Sebastian</i>	78	<i>Hidehito Kimura</i>	46
<i>Guangtong Zhu</i>	119, 141	<i>Hideo Osada</i>	36
<i>Gudumac Veronica</i>	111	<i>Hiroaki Namatame</i>	83
<i>Guilin Li</i>	102	<i>Hiroyasu Kamiyama</i>	107
<i>Guive Sharifi</i>	44, 70, 75, 76	<i>Hitay Yucel</i>	126, 129
<i>Gulam Mustafa Faisal</i>	104	<i>Ho Shin</i>	32
<i>Güler Betül</i>	79, 80, 81, 84, 91, 106, 108, 121, 131, 133, 137, 139, 140	<i>Ho Shin</i>	124
<i>Gulmurodov R.R.</i>	160	<i>Hong Xiao</i>	82
<i>Güneş Müslüm</i>	79, 80, 84, 91, 108, 131	<i>Hong Yi Liu</i>	82
<i>Gunness Nitish</i>	25	<i>Hongqi Zhang</i>	102, 109
<i>Guodong Liu</i>	44, 52	<i>Hongyi Liu</i>	80
<i>Guohua Xi</i>	88	<i>Horinek Daniel</i>	43
<i>Gürbüz Sabri</i>	78	<i>Hossain Mohammad</i>	127
<i>Guru Prasad</i>	98	<i>Hossam Abdelhakim Elnoamany</i> ..	129, 133, 136, 140
<i>Güzey Deniz</i>	127	<i>Hossam Ibrahim Maaty</i>	34
<i>Guzhin Vladimir</i>	40	<i>Hosseinali Khalili</i>	88
H		<i>Howard</i>	Peter 110
<i>Habibi Zohreh</i>	139	<i>Hu Xinhua</i>	81, 83
<i>Halepa Roman</i>	42	<i>Hua Qing Du</i>	82
		<i>Hua Yan</i>	82
		<i>Huang Qi Jiu</i>	109

Hui Huang	119, 141
Hurramovich Feruz Babahanov	133
Husch Andreas	31
Hussain Ramzan	144
Hyeun Sung Kim	32, 124

I

I Gde Anom Ananta Yudha	92
Iaccarino Corrado	73, 132, 153
Iakimov Iurii Alekseevich	117
Ibatova Syrdankyz	122
İbrahimoglu Muhammet	134
Ibrayeva S. E.	132
Igissinov Nurbek	157
Ilhan Aydın	37, 41
Iliev Bogomil	23
Ilke Ali Gurses	53
Imam Syed	145
Imangozhaeva Asem Toleybekovna	149
Indharty S.	56
Ingorokva Giorgi	48, 63
Ippili Kaushal	123
Ippolitov E.	33
Iqra Patoli	55
Irfan Nawaz	92
Irimescu Iulian	23
Ishmukhametov Rashid	94, 96
Iskanov Abay	122
Isler Cihan	126, 129
Ismailova Rano A.	61, 112, 126, 144
Ismoilov Athamjon	43
Ismoilov Obidkhon	43
Iv Vycheth	145
Ivanchenko Alexey N	128, 132, 135
Ivanov Mikhail	62, 69
Ivanova Natalia	72
Izgi Nail	53, 141

J

Jabbari Reza	75, 76, 149
Jafari Armin	76
Jafri Malin Abdullah	41
Jahangiri Armin	76
Jalesi Maryam	75, 76

Jamantayeva Botagoz	155
Jamshid Mardanov Jahongirovich	42
Janelidze Marine	48, 99
Jang Kun Soo	23
Japardi I.	56
Japardi Iskandar	158, 159
Jaspreet Singh Dil	107
Jaweed Mohammad	155
Jemel Hafedh	122
Jeon Ki Hyun	23
Jeong Se Jin	23
Ji Min Ling	53, 92
Jian Tu	141
Jian Wang	45
Jieshi Liu	87
Jin Hoon Park	28 91
Jin Hu	88
Jinbing Zhao	81, 88
Jiyanov Ibrohim	43
Johari Siregar Adnan	155
John Mylonakis	111
Jong Huat Tee	41
Jong Il Kim	109
Ju Chang Il	23
July Julius	159
Jun Dong	43, 74
Jun Pan	67
Junhui Huang	156
Junpei Oda	107

K

Kachiev Nurlan Tolobekovich	83
Kadashev Boris	66, 69
Kai Zhou	40
Kaimak Tatyana	94
Kakimzhanov Zh. Kh.	132
Kalevski S.K.	7
Kalinin Pavel	66, 68, 69
Kalinovskii Anton	67
Kaliyev Assylbek	34, 141
Kalkabaev Zh. K.	132
Kamel Bouaita	111
Kameneva Marina	56
Kamiyama Hiroyasu	143

<i>Kamlesh Singh Bhaisora</i>	98	<i>Kim Kwan Tae</i>	23
<i>Kamola Ikramova Shuhratovna</i>	84	<i>Kim Seok Won</i>	23
<i>Kapitanov D.</i>	142, 161	<i>Kim Sergey</i>	113
<i>Kaplan Ibrahim</i>	150, 152	<i>Kimihiro Nagatani</i>	36
<i>Karaarslan Numan</i>	78	<i>Kiriek Natalia Anatolievna</i>	115
<i>Karakouti Anna</i>	141	<i>Kisaev Yermek Valerevich</i>	149
<i>Karchalova Ainur</i>	62, 63	<i>Kisamedenov Nurlan</i>	159
<i>Karibay Serik</i>	51	<i>Kishida Yugo</i>	25
<i>Karibay Serik</i>	75, 76, 135, 140	<i>Kislitsin Dmitry</i>	34, 99
<i>Kariev Gayrat</i>	43, 46	<i>Kiss Attila</i>	23
<i>Kariev Gayrat M.</i>	65, 66, 127, 144	<i>Kissayev Yermek</i>	38
<i>Karimbaev Shuhrat</i>	43	<i>Kissayev Yermek Valerevich</i>	130, 131, 150
<i>Karpov Eugeny Mikhailovich</i>	115	<i>Klimov Vladimir Sergeevich</i>	42, 67, 129
<i>Karuna Tamrakar</i>	161	<i>Kocaoglu Murat</i>	75, 77, 117, 134, 142
<i>Kasper Ekkehard</i>	159	<i>Kocaoglu Sarper</i>	126, 129
<i>Kassis Sebouh</i>	131	<i>Kochkor Tolonovich Mendibaev</i>	55
<i>Kato Yoko</i>	158	<i>Kojiro Wada</i>	29, 36
<i>Katsuji Shima</i>	28	<i>Kolesnikov Nikolai</i>	62
<i>Kauynbekova Sholpan M.</i>	128, 132	<i>Kondev Toni</i>	23
<i>Kavлак Erdoğān</i>	135	<i>Konovalov Nikolai Alexandrovith</i>	23, 33
<i>Kaya Cihan</i>	75	<i>Korpinar Sefika</i>	26
<i>Kazuya Fujii</i>	36	<i>Korucu Mustafa</i>	75, 130, 134
<i>Ke Sai</i>	45	<i>Kosmachev Mikhail</i>	116
<i>Kemal Hepgul</i>	53	<i>Kosumo Noda</i>	107
<i>Kemelbekov Kanatzhan Saukhanbekovich</i> ...	115, 116	<i>Koutentakis Dimitrios</i>	141
<i>Kentaro Mori</i>	29, 36	<i>Kravchuk A.</i>	33
<i>Kenzhebaev Sayat K.</i>	132	<i>Kravchuk Alexander</i>	142, 161
<i>Kenzhina Klara</i>	155	<i>Krivoshapkin Alexey</i>	34, 99
<i>Kerimbayev Talgat</i>	38, 130, 131	<i>Krivoshapkina Liubov</i>	62, 63
<i>Ketabchi Ibrahim</i>	37	<i>Kuanishev Erbol</i>	72
<i>Khabarova Elena</i>	31, 48	<i>Kulikova Elena</i>	48
<i>Khabir Ahmed</i>	55	<i>Kulmirzayev Marat</i>	157
<i>Khachatryan William</i>	23, 116	<i>Kumar Ashish</i>	110
<i>Khachiashvili Mamuka</i>	99	<i>Kun Soo Jang</i>	32, 124
<i>Khaled M F Saoud</i>	138	<i>Kun Yang</i>	80
<i>Khalepa Roman</i>	67	<i>Kurbanov Ulugbek</i>	90
<i>Khalid Mahmood Sukhera</i>	31	<i>Kurnosov Alex</i>	68, 69
<i>Khan Zahid</i>	145	<i>Kuroda Satoshi</i>	159
<i>Khinikadze Mirza</i>	48, 99	<i>Kurov Oleg Mihailovich</i>	66
<i>Khraisat Wesam</i>	124	<i>Kutin Maxim</i>	66, 68, 69
<i>Ki Hyun Jeon</i>	32, 124	<i>Kuzibaev Jamshid</i>	86
<i>Kim Aleksandr</i>	23, 39, 106, 116	<i>Kwan Tae Kim</i>	32, 124
<i>Kim Andrey Afansevich</i>	87	<i>Kyung Soo Min</i>	87
<i>Kim Hyeun Sung</i>	23		

L

<i>Laaguili Jawad</i>	79	<i>Mahmoud Al. Yamany</i>	36
<i>Ladislau Steiner</i>	47	<i>Mahmoud Taha</i>	114
<i>Lan Qing</i>	31, 74	<i>Maidannyk Oleg</i>	34
<i>Larionov Peter</i>	62	<i>Majer Catalin</i>	28
<i>Latyshev E.</i>	33	<i>Majer Catalin</i>	131
<i>Laxmi Narayan Gupta</i>	88	<i>Makhambaev Gabit D.</i>	128
<i>Lazarev Valeriy</i>	106	<i>Makhambetov Yerbol</i>	32, 34, 141
<i>Lee Seung Myung</i>	23	<i>Makhkamov Kozim</i>	86
<i>Lekhner Andrei</i>	62	<i>Malika Yahiaoui</i>	111
<i>Leplina Olga</i>	26	<i>Malisheva Tat'yna A.</i>	113
<i>Letyagin German</i>	113	<i>Mamadaliyev Abdurakhmon Mamatkulovich</i>	65, 144
<i>Liang Xing Dai</i>	43	<i>Mamadaliyeva Saodat Abdurakhmonovna</i>	144
<i>Liang Xu</i>	34, 44	<i>Mamanazarov Kurbon</i>	90
<i>Liangfu Zhou</i>	88	<i>Mambetova Gulnara Sharipbekovna</i>	149
<i>Liew Boon Seng</i>	62, 155	<i>Mamytov Mitalip</i>	69, 71, 72
<i>Ligang Chen</i>	87	<i>Mandler Robert</i>	31
<i>Likhterman Leonid</i>	142, 161	<i>Manoharan Subramanian</i>	107
<i>Liming Qiu</i>	92	<i>Maqsood Ahmed</i>	30
<i>Liu Guo Dong</i>	31, 74	<i>Marcos S Tatagiba</i>	47, 64
<i>Liu Hongyi</i>	53, 81, 83, 109, 157	<i>Mark Gerad Anthony</i>	125
<i>Liu Rui</i>	25	<i>Maryam H Esfehani</i>	43
<i>Liu Xiang Xiang</i>	109	<i>Maziar Motiee</i>	43
<i>Liu Yong</i>	81, 83	<i>Mazzi Giorgio</i>	73
<i>Liu Yong Yong</i>	109	<i>Mazzini Elisa</i>	73
<i>Loay Abukwedat</i>	28	<i>Md Moshir Rahman</i>	52
<i>Lokendra Singh</i>	99	<i>Md Moshir Rahman</i>	51
<i>Loparev Eugeniy</i>	42, 67	<i>Md. Ruhul Kuddus</i>	38, 140
<i>Lortkipanidze Maka</i>	115	<i>Megumi Takahashi</i>	83
<i>Luchansky Vsevolod Vyacheslavovich</i>	86, 115	<i>Mehmet Nusret Demircan</i>	74
<i>Luiz Paulo Alves</i>	73, 132, 153	<i>Mehmet Osman Akcakaya</i>	53
<i>Luo Zheng Xiang</i>	109	<i>Mehrdad Hosein Zadeh</i>	75
<i>Lv Zhu Hai</i>	109	<i>Mehrnoush Gorjian</i>	47
<i>Lype Cherian</i>	161	<i>Melidi Evstafiy</i>	31, 48
<i>Lytvynenko Andriy</i>	34	<i>Melih Üçer</i>	84

M

<i>M Sandeep</i>	104	<i>Melnichuk Sergey</i>	106
<i>M.a. Jagadish</i>	37	<i>Mendibaev Kochkor Tolonovich</i>	105, 133
<i>Ma Jun</i>	157	<i>Michelle Cheng</i>	95
<i>Ma Jun Jun</i>	109	<i>Mihai Iosif Gavriluc</i>	111
<i>Maggi Massimo</i>	73, 132, 153	<i>Mikhail Y Volodiukhin</i>	95
<i>Mahadevan Anand</i>	25	<i>Miklashevich Eduard</i>	106
<i>Mahambaev Gabit D.</i>	132	<i>Mirlan Jeenbekovich Sulaimanov</i>	55
		<i>Mirzabaev Marat Jumabekovich</i>	85
		<i>Mirzabayev Marat</i>	86
		<i>Mishinov Sergey</i>	26

Mitalip Mametovich Mamytov	55
Mitroshin Georgiy	106
Mityukov Alexandr Evgenevich	66
Miyata Shiro	143
Moahamed Sahraoui	111
Mohamad Zohair Shakir.....	45
Mohamd A Alhosban	124
Mohamed Ahmed Fahmy Mohamed Mostafa Zeid.	73, 145
Mohamed Ibrahim Refaat	56
Mohamed Mamdouh Salama	30
Mohamed Natheer Saeid.....	39
Mohamed Zaher Boudawara.....	94
Mohammad Idris Khan	39, 96
Mohammad Jaweed	31, 62
Mohammad Samadian.....	44, 70
Mohammed El Esawey El Fiki.....	101
Mohammed Mohammed El Rhmany.....	101
Mohammed Nuruzzaman Mohammed Nuruzzaman	
Mohammed Nuruzzaman	144
Mohammed Saffari Mohammed Haspani	117
Mohsen Nouri.....	35, 37, 43
Mohsin Qadeer	55
Moisak Galina	45
Moon Young Choi.....	28
Moraitis Vasilios	141
Moshiur Rahman	38
Mostofa Zaman Chowdhury.....	127
Motti Luisa.....	73, 132
Mou Seop Lee	87
Mousavinejad Seyedali	149
Muhammad Arifin Parenrengi	27
Muhammad Idris Khan	146
Muhammad Irfan Butt.....	154
Muhammad Shahzad Shamim	55, 127
Muhammad Tariq Imtiaz.....	30, 36
Muhammad Waqas	55, 63
Mukhamedov Akmaljon	112
Muminov Abdurashid.....	126
Muminov Murod	137
Mumtaz Ali	39, 42, 53, 96
Mumtaz Ali Shah	146
Munusamy Thangaraj	125
Murad Asiltürk.....	37
Murat Şakir Ekşi.....	55

Müslüm Güneş	37, 41
Mustafa Levent Uysal	37, 41
Mustafa Levent Uysal	79, 84, 91, 108, 131
Mustafayev Baglan	76
Mustafin Khalit	53, 75

N

Naafa Ioualalen	111
Najm Us Saqib	29
Najmiddin Norkulov Uralovich	84
Nakamasa Hayashi	159
Nakao Ota	107
Naoki Otani	29, 36
Nasi Davide	132
Nazaralieva Eleonora Tuuganbaevna	76
Nazarov M.K.	160
Ndraha Eveline.....	158
Nejat Farideh	27
Nemirovskiy Alexandr M	95
Nesterenko Leonid Haritonovich.....	66
Netuka David	43
Nguyen Minh Tu	37
Nguyen Thanh Binh	37
Ni Lanchun	33
Nicoli Davide.....	73
Nidal H Khasawneh.....	124
Nigim Fares	159
Nikolaeva Anna I.	69
Nilam Khadka	47
Nima Derakhshan	88
Noda Kosumo	143
Norov Abdurakhmon	137
Nouri Mohsen.....	158
Novikov M.	33
Nowak Karol	78
Nur Altinors	29
Nur Setiawan Suroto.....	33
Nurgalyev Kuat Bulatovich.....	149, 155

O

Oda Junpei	143
Odnobludova Ekaterina V.....	44
Ofluoğlu Ender	133
Oğuz Iskender Turan	127

<i>Ojha Balkrishan</i>	91
<i>Okhlopkov Vladimir</i>	33, 142, 161
<i>Okladnikov Gennadii Ivanovich</i>	66
<i>Olenbay Gabit</i>	71
<i>Olyushin Victor</i>	45
<i>Omidvar Rezaie</i>	44, 70
<i>Orlov Kirill</i>	34, 99
<i>Orlov Yuriy A.</i>	113
<i>Ornek Mustafa</i>	129
<i>Osman Nuri Turkmenoglu</i>	141
<i>Ostanin Alexander</i>	26, 85
<i>Ota Nakao</i>	143
<i>Otarashvili Irakli</i>	48, 63
<i>Othman Walid</i>	131
<i>Ouerchefani Naoufel</i>	94
<i>Ovsyannikov Konstantin Sergevich</i>	40, 97
<i>Ozbek Zuhtu</i>	24
<i>Ozcan Gayretli</i>	53
<i>Ozdemir Mevci</i>	75
<i>Ozdilmac Ahmet</i>	141

Ö

<i>Ösün Arif</i>	150, 152
<i>Özcan Tarım</i>	27
<i>Özdemir Mevci</i>	77, 130
<i>Özdemir Nail</i>	69, 118, 119
<i>Özden Erhan Sofuoğlu</i>	28, 37, 41, 84, 91, 108, 137, 140
<i>Özkan Çeliker</i>	47
<i>Özkan Ümit</i>	150, 152
<i>Özkan Yasemin</i>	127
<i>Öztürk Akın</i>	81, 84, 121, 140
<i>Öztürk Enis</i>	127
<i>Öztürk Onur</i>	141

P

<i>Pan Jun</i>	39
<i>Panchenko V.</i>	33
<i>Park Kee</i>	145
<i>Parluk Oleg</i>	85
<i>Parsa Khosro</i>	75
<i>Pascarella Rosario</i>	73, 153
<i>Pastukhova Elena</i>	145
<i>Pawan Kumar</i>	47

<i>Peev N.A.</i>	7
<i>Pendyurin Ivan Victorovich</i>	66
<i>Peng Hu</i>	102
<i>Penglai Zhao</i>	81
<i>Pereira Lorenza</i>	73, 132, 153
<i>Perfilev Artem Michalvich</i>	40, 97
<i>Perfilev Sergey</i>	128
<i>Perfilyev Andrey M.</i>	69
<i>Petrak Alex</i>	46
<i>Phonin Vjacheslav</i>	85
<i>Pillay Haroon</i>	131
<i>Pipchenko Denis Sergeevich</i>	82
<i>Pisanello Anna</i>	73, 132
<i>Plavskiy Pavlo N.</i>	113
<i>Polat Sarper</i>	79, 80, 84, 108, 122, 141, 142
<i>Polishchuk Mykola</i>	46
<i>Popugaev Konstantin</i>	69
<i>Poshataev Kirill</i>	116
<i>Potapov A.</i>	33
<i>Potapov Alexander</i>	142, 161
<i>Prabin Shrestha</i>	55
<i>Prakash Bista</i>	47
<i>Pralaya Kishore Nayak</i>	144
<i>Praveen K.v</i>	137
<i>Premjit Ray</i>	104
<i>Priyamvadha Kovai</i>	35
<i>Pronkina Natalia</i>	85
<i>Pulat Akin Sabanci</i>	53, 141
<i>Pulivendhan Sellamuthu</i>	40

Q

<i>Qiang Huang</i>	43, 75
<i>Qing Lan</i>	26, 34, 43, 44, 52, 92, 93
<i>Qing Zhu</i>	26, 34, 44, 52, 92, 93
<i>Qingjiu Huang</i>	157
<i>Quintana Leonidas</i>	32
<i>Qurbonov Yorqin</i>	145

R

<i>Rabandiyarov Marat</i>	122
<i>Rabi N Sahu</i>	73
<i>Rabi Narayan Sahu</i>	98
<i>Rabinovoch Samuil</i>	85
<i>Radu Safta</i>	67

<i>Rahman Habibur</i>	127
<i>Rahman Moshiur</i>	140
<i>Rahmat Harun Haron</i>	40
<i>Rainer Rink</i>	31
<i>Raja Annasamy</i>	107
<i>Rajabov Mukhsin</i>	137
<i>Rajiv Kumar Jha</i>	47
<i>Rakhmatullayeva Dono Salhitdinovna</i>	99
<i>Rakhmon Egamberdiev</i>	43
<i>Ram Kumar Menon</i>	41, 119, 137
<i>Ramandeep Singh Dang</i>	91
<i>Ramazan Durmaz</i>	88
<i>Rami Y Alqroom</i>	124
<i>Ramina Kristofer</i>	64
<i>Ramponi Vania</i>	73, 153
<i>Raziye Atar</i>	26
<i>Razlinda Zainal Hasnan</i>	117
<i>Razmahnina Angelika</i>	42
<i>Reza Ghadirpour</i>	29, 73
<i>Reza Jabbari</i>	44, 70
<i>Rezaie Omidvar</i>	75, 149
<i>Riadh Rebai</i>	94
<i>Richard F Keep</i>	88
<i>Riskeldiev Nurzhan</i>	72
<i>Rizwan Ahmed Khan</i>	31
<i>Rm Pandey</i>	87
<i>Robert Ahmed Khan</i>	38, 52, 140
<i>Rodrigo Gusmao Coimbra</i>	73, 132, 153
<i>Rogov Dmitry</i>	48
<i>Rohadi Rohadi</i>	56
<i>Röhrig Andreas</i>	158
<i>Rokuya Tanikawa</i>	107
<i>Romano Antonio</i>	132, 153
<i>Rong Xie</i>	95
<i>Roser Florian</i>	47
<i>Rosman Azmin Kass</i>	62
<i>Rossella Sabadini</i>	73
<i>Rotariu Andrei Farcas</i>	32
<i>Rouzbeh Shams Amiri</i>	37
<i>Ruhul Quddus</i>	52
<i>Rui Zhang</i>	80, 157
<i>Rui Zhao</i>	27
<i>Russell J Andrews</i>	32, 36
<i>Ryskeldiev Nurzhan</i>	71, 75

<i>Ryskeldyev Nurgan</i>	53
<i>Rzaev Djamil</i>	42, 48
<i>Rzaev Jamil Afetovich</i>	67, 97

S

<i>S I M Khairun Nabi Khan</i>	52
<i>Saad Akhtar Khan</i>	61
<i>Saedinejad Zaker</i>	139
<i>Saeed Saeednia</i>	43
<i>Safi Ur Rehman</i>	32
<i>Safta Radu</i>	99
<i>Sagatbekova Zhanerke Erkinovna</i>	149
<i>Saidov Bekzod</i>	43
<i>Saiful Azl</i>	31
<i>Sailike Duishanbai</i>	40
<i>Saini Renu</i>	147
<i>Saito Kiyoshi</i>	25
<i>Sakız Damlanur</i>	127
<i>Sakuma Jun</i>	25
<i>Salami Mohcine</i>	119
<i>Samadian Mohammad</i>	75, 76, 149
<i>Sang Hyung Lee</i>	38
<i>Sang Koo Lee</i>	56
<i>Sang Youl Lee</i>	28, 91
<i>Sanjay Behari</i>	98
<i>Sanjeev Dua</i>	35
<i>Sanjeev Kumar Akula</i>	129
<i>Sapkota Shabal</i>	155
<i>Saqib Kamran Bakhshi</i>	55, 127
<i>Sarkar Saumitra</i>	116
<i>Sarper Polat</i>	37
<i>Satirou Azuma</i>	83
<i>Sato Taku</i>	25
<i>Satoru Takeuchi</i>	29, 36, 107
<i>Satoshi Tomura</i>	36
<i>Sattorov A.I.</i>	160
<i>Saydullo Sharifbaev</i>	43
<i>Se Hoon Kim</i>	109
<i>Se Jin Jeong</i>	32, 124
<i>Sebouh Kassis</i>	28
<i>Seema Sharafat</i>	42
<i>Selami Çağatay Önal</i>	27
<i>Selçuk Göçmen</i>	47, 74
<i>Selesnev Pavel</i>	34, 99

Sencer Altay	141	Siahaan Andre	159
Senem Alkan Özdemir	118, 119	Sibgatullina Dina	67
Şenol Serkan	150, 152	Siedlecki Zygmunt	78
Senturk Salim	24	Silky Chotai	39, 46, 67
Seok Won Kim	32, 124	Sim Khairun Nabi Khan	38, 140
Serdar Cevik	26	Sirojiddin Norkulov Najmiddinovich	84
Serra Silvia	73	Siyi Wanggou	156
Servadei Franco	73, 132, 153	Sk Sader Hossain	28
Seung Chul Rhim	28	Smagulov Faizulla	34, 141
Seung Myung Lee	32, 124	Smejanovich Arnold F.	44
Seyed Ali Mousavinejad	44, 70, 75, 76	Smejanovich Vitali A.	44
Seyithanoglu Mehmet Hakan	26	Smigelsky Alexandr	69
Seyyit Kagan Basarslan	152	Smolanka Andriy	46
Shalashvili George	48, 99	Smolanka Volodymyr	44, 46, 68
Shalinder Aul	40, 97	Smuczynski Wojciech	78
Shamsul Alam	100, 102	Sniegocki Maciej	78
Shanko Yuri G.	44	Sondey Bansal	88
Shapovalov Aleksandr	116	Songtao Qi	39, 67
Sharad S Rajamani	108	Songul Meltem Can	141
Sharad S Rajamani	29, 52	Sook Young Sim	109
Sharafat Seema	145	Soyibov Ibrohim Eshmuhamadovich	85
Sharifi Guive	75, 76, 149	Spekov Azat	32
Sharipov Oleg	66, 68, 69	Stankevich Sergey K.	44
Shashkin Chingiz	32, 141, 142, 159	Stauroula Lyra	111
Shaverskyi Andrii V.	113	Stupak Evgeniy	62
Shayakhmetov Timur	34, 99	Stupak Vjacheslav	26, 62, 63, 85
Shaykhmetov Nail G	95	Subagio Eko Agus	24
Shen He	31, 74	Sufianov Albert Akramovich	52, 117
Shenghui Liao	156	Sun Tao	31, 74
Sherif Rashad	96	Sung Bae Park	38
Shevela Ekaterina	85	Sung Gun Lee	28
Shi Jinglong	33	Sung Kon Ha	109
Shi Wei	33	Surdin Dmitry	71
Shima Shahjouei	27	Suresh Nair Narayanan Nair ..	25, 33, 52, 81, 83, 111
Shin Ho	23	Suryanarayanan Bhaskar	88
Shiro Miyata	107	Svadosky Alexander	40
Shivender Sobti	88	Syed Abdul Jaleel Kirmani	104
Shkarubo Alexei Nikolaevith	23, 33, 66, 68	Syed Faaiz Enam	55, 63
Shmigesky Alexandr	68	Syed Ul Abrar Bukhari	92
Shpekov Azat	34, 141	Sysoeva Anna	113
Shree Kumar Dinesh	53, 125	Sze Kiat Sim	41
Shuhrat Halikov Ashurovich	41	Szostak Mateusz	78
Shuyuan Yue	61		

T

Tabidze Irina	99
Taha Mahmoud	67
Takeuchi Satoru	143
Tamer Hassan Mohammed.....	96, 109, 101
Tamer Ibrahim Metwally.....	96, 101
Tanikawa Rokuya	143
Tanin Andrey L.....	44
Tankacheyev Ramil.....	51, 135, 140
Tao Hong	109
Tarula Erick	25
Tas Abdurrahim.....	126, 129
Teak Sheng Gee.....	31
Teddy Apriawan	56
Teltaev Daniyar.....	53, 72, 75
Thien Ady	125
Thomas Tommy	56
Timirgaz Valerii	67, 99
Titov Sergei	62
Tiv Virak	145
Tofael Hossain Bhuiyan	127
Toidze Irakli.....	48, 99
Tolga Turan Dundar.....	26
Tommy Thomas	158
Topcu Abdullah	117, 130
Torre Gabriella	73
Toshiyuki Tsuboi.....	107
Touch Sokret	145
Trendafilov Plamen	23
Tsikarishvili Vladimir.....	48, 68, 99
Tsuboi Toshiyuki	143
Tufan Azmi.....	126, 129
Tuhtamurodov Javlon.....	43, 61
Tümkaya Funda	143
Tuncay Ateş.....	27
Turabekov Nurjan.....	87
Turganbaev Bakytbek	38
Tursynov Nurtas I.	130, 132
Tutayeva Aigerim Aitbayevna.....	115, 116
Tuychiboy Mansurhonovic Abdullaev	55
Tyagi Isha	73
Tyrinova Tamara	26

U

Ufuk Berber	74
Ulitin Alexey	69
Ullah Akram.....	144
Umemura Kimiko	159
Umirserigov Batirbay	86
Ünal Ayşe	135
Urunbayev Yermek	38, 130, 131
Usman Muhammad.....	39
Usmonov Laziz Aminovich.....	46, 84, 85, 144
Uzhakova Elena.....	67

Ü

Üçer Melih	81, 84, 121, 122, 140, 141, 142
------------------	---------------------------------

V

Vaclav Masopust.....	43
Vamsi Krishna Yerramneni	111
Varun Kshetry.....	46
Vasileios George Varsos	111
Vasilenko Ivan Igorevich	42, 67, 129
Vasilevich Eduard N.	44
Vatansever Mustafa	126, 129
Venkata Ramesh Chandra Vemula	37, 123, 129
Veryaskina Yulia	62
Viaroli Edoardo.....	73, 153
Vinodh Vayara Perumall	40
Vk Kamal	87
Volkan Murat Ünal	69, 118, 119
Volkodav Oleg Vladimirovich	113
Von Gi Kim	116
Voznyak Oleksandr	34

W

Waleed Abbass Ahmed	34, 87
Walid I Attia	138
Walid Othman	28
Wang Ernest.....	92
Waqas Muhammad	127
Wasem Aziz.....	109
Wei Miao	81
Wei Shi	27
Wen Jun Shen.....	27

Wen Liu	80
Wenbin Zhang.....	80
Wenzheng Li.....	156
Wester Knut	119
Woo Jin Choi.....	32, 124

X

Xiang Liu.....	80
Xianrui Yuan	156
Xiaochuan Sun	87
Xiaoping Yi	156
Xiaoxing Xiong	95
Xiaoyu Li.....	109
Xing Wu	88
Xinglong Zhi	102
Xinhua Hu	80, 157
Xuehai Wu.....	88
Xuejun Li.....	156

Y

Ya Hua.....	88
Yakubov Jahingir	61, 65
Yakubov Jahogir	43
Yaman Mesut Emre.....	24
Yaman Onur	69
Yang Hua	83
Yang Kun	53, 81, 83
Yang Victor.....	110
Yangdong He	88
Yanming Chen.....	34, 92, 93
Yaodong Zhao.....	46
Yaşar Bayri.....	55
Yashbir Dewan	35
Yasser Ismail Orz	36
Yavuz Aras	53
Yelikbayev Galimzhan Mamirbekovich.....	115, 116
Yener Akyuva.....	27
Yeong Seob Chung	38
Yeoung Jin Jung	105
Yerezhepekov Baurzhan	38, 130, 131
Yevsyukov Alexey Vladimirovich	129
Yew Chin Tan.....	41
Yi Jin	88
Yi Jun Cheng.....	82

Yi Liu	39, 67
Yigit Mehmet	26
Yilmaz Adem	141
Yilmaz Atilla.....	49
Ying Mao	88
Yirgin Hakan	127
Yirui Sun	88
Yoko Kato.....	35
Yong Jiang.....	87
Yongxin Wang.....	40
Yoshida Taketoshi	159
Yoshikazu Okada	148
Young Gyu Kim	87
Young Je Son.....	38
Young Seok Park	87
Yrysov Keneshbek	38, 69, 71, 72
Yrysova Mirgul	72
Yu Jian.....	88
Yuanjie Zou	80
Yucel Murat	126, 129
Yugay Igor Aleksandrovich.....	112
Yuhai Zhang	80
Yuldashev Ravshan M.....	123
Yutaka Ohtsubo.....	83
Yuxiang Gu.....	27

Z

Zahid Khan.....	42
Zainy Hamzah.....	27
Zakhridin Ashurov	43
Zamira Makhmudova	44
Zamroni Achmad.....	140
Zelenkov Petr Vladimirovitch.....	33
Zengliang Wang	40
Zhailaubayeva Aida Serikkanovna.....	158
Zhang Wen Bin	109, 157
Zhang Yan Song.....	109
Zhang Zhijun	31, 74
Zhao Penglai	148
Zharassov Alibek.....	122
Zhe Xue	100
Zhenghe Chen	45
Zhenghui Sun	100
Zhengxiang Luo	81, 148

Zhi Chen	88
Zhimulev Igor	62
Zhiqiang Hu.....	141
Zhongping Chen.....	45
Zhuang Kang	141
Zhuhai Lv	80
Zhumadildina Aigerim	75, 158
Zhuravlev Vladimir A.....	44
Zinchenko Svetlana Arturovna.....	113
Zorinela Andrasoni.....	32
Zotov Alexander.....	67
Zou Yuan Jie.....	109
Zou Yuanjie	53, 83
Zuhtu Ozbek.....	72, 88
Zyabchenko Vadim I.	113

А

Абедимова Р.А.	16
Акчурина Я.Е.	16
Акшулаков С.К.	3

Б

Бондарева И.В.,	16
-----------------------	----

И

Имангожаева А.Т.....	11
----------------------	----

К

Кисаев Е.В.	11
Кисамеденов Н.Г.	3

М

Мамбетова Г.Ш.....	11
Михайлова Н.В.	16

Н

Нургалиев К.Б.....	11
--------------------	----

С

Савинов С.В.....	16
Сагатбекова Ж.Е.	11
Синицына Т.Н.	16
Ситников И.Ю.	16

У

Утебеков Ж.Е.	16
--------------------	----

Информация для авторов

При направлении статьи в редакцию необходимо соблюдать следующие правила:

- ❖ **Индекс УДК:** Индекс УДК помещают отдельной строкой слева.
- ❖ **Сведения об авторах помещают перед заглавием статьи:**
Имя автора (инициалы и фамилия);
Ученое звание, ученая степень;
Должность или профессию;
Место работы (наименование учреждения или организации, населенного пункта);
Наименование страны (для иностранных авторов).
- ❖ **Заглавие публикуемого материала:** Не допускается включать в заглавие публикуемого материала название раздела, подраздела, цикла, где он публикуется.
- ❖ **Подзаголовочные данные:** Сведения о типе публикуемого материала, в том числе формулировки «Обзор литературы», «Обзор...» в обзорных публикациях, помещают после заглавия публикуемого материала
- ❖ **Резюме:** Резюме приводят на языке текста публикуемого материала и помещают перед текстом, после заглавия и подзаголовочных данных.
Для оригинальных статей резюме должно включать следующие краткие разделы: введение, методы исследования, результаты и заключение.
К каждой статье прилагается резюме на казахском, русском и английском языках. Резюме на русском языке (если статья на русском) помещается перед текстом, а на казахском и английском - в конце текста статьи. Соответственно резюме на казахском помещается в начале статьи на казахском, а на русском и английском - в конце текста статьи.
Каждое резюме должно содержать ключевые слова (от 3 до 6 слов). Текст Резюме должен быть максимально информативным и отражать, прежде всего, основные результаты вашей работы. Оптимальный объем Резюме – от 2/3 до 1 страницы. Приступая к написанию Резюме, помните, что для большого круга читателей все знакомство с вашей статьей ограничится прочтением ее названия и Резюме. Поэтому отнеситесь к Резюме как к чрезвычайно важной и ответственной работе. Обращайте особое внимание на квалифицированный перевод резюме на английский язык.
- ❖ **Ключевые слова:** Ключевые слова, помещают отдельной строкой непосредственно после заглавия, перед текстом публикуемого материала.
- ❖ **Текст:** Оригинальная статья должна состоять из введения, характеристики собственного материала и методов исследования, результатов и их обсуждения, заключения или выводов.
- ❖ **Приставительные библиографические списки:** В заглавии приставительного библиографического списка используют название «Список литературы». Список помещают после текста публикуемого материала. Все ссылки в списке последовательно нумеруются и располагаются по порядку упоминания в тексте. Библиографические ссылки в тексте статьи даются в квадратных скобках с номерами в соответствии со списком литературы. Список литературы оформить согласно ГОСТу 7.1–2003.
- ❖ **Оформление:** Статья должна быть напечатана шрифтом TimesNewRoman, размером 12, через 1,5 интервал. Формат файла –MicrosoftWord (расширение *.doc).
- ❖ **Объем статей:** Объем оригинальных статей и лекций, включая таблицы, рисунки, список литературы и резюме не должен превышать 10 стр., обзорных статей – 15 стр. Отдельные сообщения и заметки не должны превышать 5 стр.
- ❖ **Контактная информация:** Статья должна включать информацию об авторах, с которым редколлегия может вести переписку, их телефоны, адреса с почтовым индексом, электронные адреса.
- ❖ **Сокращения в статье:** Статья должна быть тщательно выверена автором. Сокращение слов, имен, названий (кроме общепринятых сокращений мер, физических, химических и математических величин и терминов) не допускается. Сокращения слов, терминов расшифровываются при первом упоминании в тексте. В резюме могут быть только общепринятые сокращения.
- ❖ **Требования к рисункам:** Все рисунки, используемые в статье, должны быть пронумерованы и подписаны. В тексте должно быть упоминание о каждом рисунке. Формат файла рисунка – TIFF (расширение *.tif). Программы, в которых выполнен рисунок – CorelDRAW 7,8 и 9, FreeHand 8 и 9. Режим – bitmap (битовая карта – черно-белое изображение без полутонов). Разрешение – 600 dpi (для черно-белых и штриховых рисунков), не менее 300 dpi (для цветных изображений, фотографий и рисунков с серыми элементами).
- ❖ Направление в редакцию работ, опубликованных в других изданиях или посланных в другие редакции, не допускается.
- ❖ Редакция оставляет за собой право не публиковать, не рецензировать и не возвращать авторам статьи, оформленные с нарушением вышеназванных правил. Всю ответственность за приведенные в статьях дозы лекарств, формулы, цифровые показатели несут авторы публикаций. Редакция также оставляет за собой право сокращать и редактировать статьи и иллюстративный материал. Все статьи рецензируются.

Статьи следует направлять по адресу:

010000, г. Астана, Левый берег реки Ишим, пр-т. Туран 34/1,
Национальный центр нейрохирургии, Редакция журнала
«Нейрохирургия и неврология Казахстана»,
Тел/факс: (7172) 51-15-94 (1326), моб. +7 701 359 49 72, +7 775 909 08 98
e-mail: nsnkkz@gmail.com